

Myxoid glioneuronal tumor: Histopathologic, neuroradiologic, and molecular features in a single center series

C. Caporalini^{a,*}, M. Scagnet^b, L. Giunti^c, V. Cetica^d, D. Mei^d, V. Conti^d, S. Moscardi^a, L. Macconi^e, F. Giordano^b, L. D'Incerti^e, L. Genitori^b, R. Guerrini^d, A.M. Buccoliero^a

^a Pathology Unit, Meyer Children's Hospital IRCCS, Viale Pieraccini 24, Florence 50100, Italy

^b Neurosurgery Unit, Meyer Children's Hospital IRCCS, Florence, Italy

^c Neuro-Oncology Unit, Department of Pediatric Oncology, Meyer Children's Hospital IRCCS, Florence, Italy

^d Neuroscience Department, Meyer Children's Hospital IRCCS, Florence, Italy

^e Radiology Unit, Meyer Children's Hospital IRCCS, Florence, Italy

ARTICLE INFO

Keywords:

Myxoid glioneuronal tumor

PDGFRA

Septum pellucidum

Dysembryoplastic neuroepithelial tumors

ABSTRACT

Background: Myxoid glioneuronal tumor (MGT) is a benign glioneuronal neoplasm recently introduced in the World Health Organization (WHO) classification of the central nervous system (CNS) tumors. MGTs are typically located in the septum pellucidum, foramen of Monro or periventricular white matter of the lateral ventricle. They were previously diagnosed as dysembryoplastic neuroepithelial tumors (DNT), showing histological features almost indistinguishable from classical cortical DNT. Despite that, MGTs have been associated with a specific dinucleotide substitution at codon 385 in the platelet-derived growth factor receptor alpha (*PDGFRA*) gene, replacing a lysine residue with either leucine or isoleucine (p. LysK385Leu/Iso). This genetic variation has never been described in any other CNS tumor.

Materials and methods: Thirty-one consecutive tumors, previously diagnosed as DNTs at the Meyer Children's Hospital IRCCS between January 2010 and June 2021 were collected for a comprehensive study of their clinical, imaging, pathological features, and molecular profile.

Results: In six out of the thirty-one tumors we had previously diagnosed as DNTs, we identified the recurrent dinucleotide mutation in the *PDGFRA*. All six tumors were typically located within the periventricular white matter of the lateral ventricle and in the septum pellucidum. We then renamed these lesions as MGT, according to the latest WHO CNS classification. In all patients we observed an indolent clinical course, without recurrence.

Conclusion: MGT represent a rare but distinct group of neoplasm with a typical molecular profiling, a characteristic localization, and a relative indolent clinical course.

Introduction

In 2018, Solomon et al. reported a hotspot mutation at codon p. Lys385 of *PDGFRA* in a specific subgroup of dysembryoplastic neuroepithelial tumors (DNT) originated in the septum pellucidum and periventricular white matter [1]. They renamed these entity myxoid glioneuronal tumors (MGTs). This specific *PDGFRA* variant has not been identified as solitary genetic driver in any other central nervous system (CNS) tumor entity to date. MGT is a rare neoplasm recently introduced in the World Health Organization (WHO) classification of CNS tumors [2]. To date less than 100 cases are reported in literature. MGT have a predilection for origin in the septum pellucidum but have also been observed in the genu of the corpus callosum and periventricular white matter of the lateral ventricle.

Headaches, emesis, seizures and behavioral disturbances are the most common clinical manifestations although, the presenting symptoms may vary [3].

At neuroimaging, these tumors show well-circumscribed margins, cystic features, and a discrete size (mostly 1 to 3 cm). On MRI they are mostly T1-hypointense and T2-hyperintense, with no contrast enhancement or restricted diffusion [3]; calcifications and multinodularity, which are common in cortical DNTs, are rare [4].

MGTs are mostly composed by a proliferation of oligodendrocyte-like cells embedded in a prominent myxoid stroma, and histologic features reminiscent of either DNT or rosette-forming glioneuronal tumor (RGNT) [2]. For long time these tumors have been misdiagnosed as DNT or DNT-like neoplasm of the septum pellucidum. However, MGTs lack the *BRAF* or *FGFR1* variants or rearrangements, gene fusions, or kinase

* Corresponding author.

E-mail address: chiara.caporalini@meyer.it (C. Caporalini).

Table 1
Clinical, molecular and histological features of myxoid glioneuronal tumor.

Patient ID	Diagnosis	Molecular profile	Age at diagnosis (years)	Sex	Tumor location	Presenting symptom	Extent of resection	Adjuvant therapy	Recurrence or progression	Additional treatment after recurrence or progression	Length of follow-up (years)
1	MGT	c.1288A>T e c.1289A>T (p.Lys385Leu)	2	M	Periventricular white matter of lateral ventricle	Seizures	GTR	No	No	No	10
2	MGT	c.1289A>T e c.1290G>A (p.Lys385Ile)	8	M	Septum pellucidum	Seizures	GTR	No	No	No	3
3	MGT	c.1288A>T e c.1289A>T (p.Lys385Leu)	8	F	Periventricular white matter of lateral ventricle	Seizures	GTR	No	No	No	6
4	MGT	c.1288A>T e c.1289A>T (p.Lys385Leu)	10	F	Septum pellucidum	Headaches	GTR	No	No	No	3
5	MGT	c.1288A>T e c.1289A>T (p.Lys385Leu)	19	M	Periventricular white matter of lateral ventricle	Seizures	STR	No	No	No	4
6	MGT	c.1288A>T e c.1289A>T (p.Lys385Leu)	14	M	Periventricular white matter of lateral ventricle	Incidental finding	GTR	No	No	No	1

MGT: Myxoid glioneuronal tumor; M: Male; F: Female; GTR: Gross total resection; STR: Sub-total resection.

Table 2
Clinical, molecular and histological features of dysembryoplastic neuroepithelial tumor.

Patient ID	Diagnosis	Molecular profile	Age at diagnosis (years)	Sex	Tumor location	Presenting symptom	Extent of resection	Adjuvant therapy	Recurrence or progression	Additional treatment after recurrence or progression	Length of follow-up (years)
1	DNT	WT	15	M	Foramen of Monro	Seizures	GTR	No	No	No	1
2	DNT	WT	11	F	T-P	Seizures	GTR	No	Yes	Surgery	4
3	DNT	WT	10	F	T	Seizures, aphasia	GTR	No	No	No	8
4	DNT	WT	18	F	T	Seizures	GTR	No	No	No	7
5	DNT	WT	9	M	T-P	Seizures	GTR	No	Yes	CHT-RT	9
6	DNT	WT	34	F	F	Seizures	GTR	No	No	No	1
7	DNT	WT	17	F	F	Seizures	GTR	No	No	No	2
8	DNT	WT	21	M	T	Seizures	STR	No	Yes	CHT	7
9	DNT	WT	6	M	F-P	Seizures	STR	No	Yes	Surgery	6
10	DNT	WT	11	M	F	Headaches, photophobia, loss of vision	GTR	No	Yes	Surgery	7
11	DNT	WT	22	F	T	Seizures	STR	No	Yes	Surgery	6
12	DNT	WT	11	F	T	Seizures	GTR	No	Yes	CHT-RT	6
13	DNT	WT	16	M	T	Seizures	STR	No	Yes	Surgery	14
14	DNT	WT	9	M	T	Headaches	GTR	No	No	No	4
15	DNT	WT	8	F	F	Seizures	GTR	No	No	No	4
16	DNT	WT	17	M	T-O	Seizures	STR	No	Yes	Surgery	4
17	DNT	WT	8	F	T	Seizures	STR	No	No	No	3
18	DNT	WT	2	M	F	Seizures	GTR	No	No	No	2
19	DNT	WT	24	F	F	Seizures	GTR	No	No	No	2
20	DNT	WT	11	F	F	Seizures	STR	No	Yes	Surgery - CHT	3
21	DNT	WT	22	M	T	Seizures	STR	No	Yes	Surgery	1
22	DNT	WT	18	F	T	Seizures	STR	No	Yes	Surgery	2
23	DNT	WT	17	M	T	Incidental finding	STR	No	Yes	Surgery	1
24	DNT	WT	2	F	T	Seizures	GTR	No	No	No	1
25	DNT	WT	18	F	T	Headaches	GTR	No	No	No	1

DNT: Dysembryoplastic neuroepithelial tumor; WT: Wild type; M: Male; F: Female; T: Temporal lobe; O: Occipital lobe; F: Frontal lobe; P: Parietal lobe; GTR: Gross total resection; STR: Sub-total resection; CHT: Chemotherapy; RT: Radiotherapy.

ter. PCR primers (forward: TGCTTGTTGAAACAAAATCCTTT; reverse: CAGGCTTCCTTGAAGACA) for exon 8 of *PDGFRA* gene (NM_006206) were designed using Primer3Plus (www.primer3plus.com). PCR amplification reactions were performed in 25 µl volume reaction according to the manufacturer’s instructions of HotStarTaq DNA polymerase (Qiagen GmbH), with 50 ng of DNA, 5 pmol/ul of each primers and a following cycle condition: 95°C x 15 min, 31 cycles of 93°C x 1 min, 55°C x 1 min, 72°C x 1 min; and 72°C x 10’ in the SimpliAmp™ Thermal Cycler (Applied Biosystems™, Waltham, MA, USA). Ampli-

fied PCR products were subjected to enzymatic purification using ExoSAP-IT™ (Affymetrix, Santa Clara, CA), directly sequenced on both strands with the Big Dye Terminator v3.1 Cycle Sequencing kit (Applied Biosystems™, Waltham, MA, USA) according to the manufacturer’s protocol in the SimpliAmp™ Thermal Cycler and run on the 3500 Dx Series Genetic Analyzer (Applied Biosystems™; Waltham, MA, USA).

All available brain imaging studies for each patient were reviewed by two expert neuroradiologists. MRIs were performed with T13D, ax-

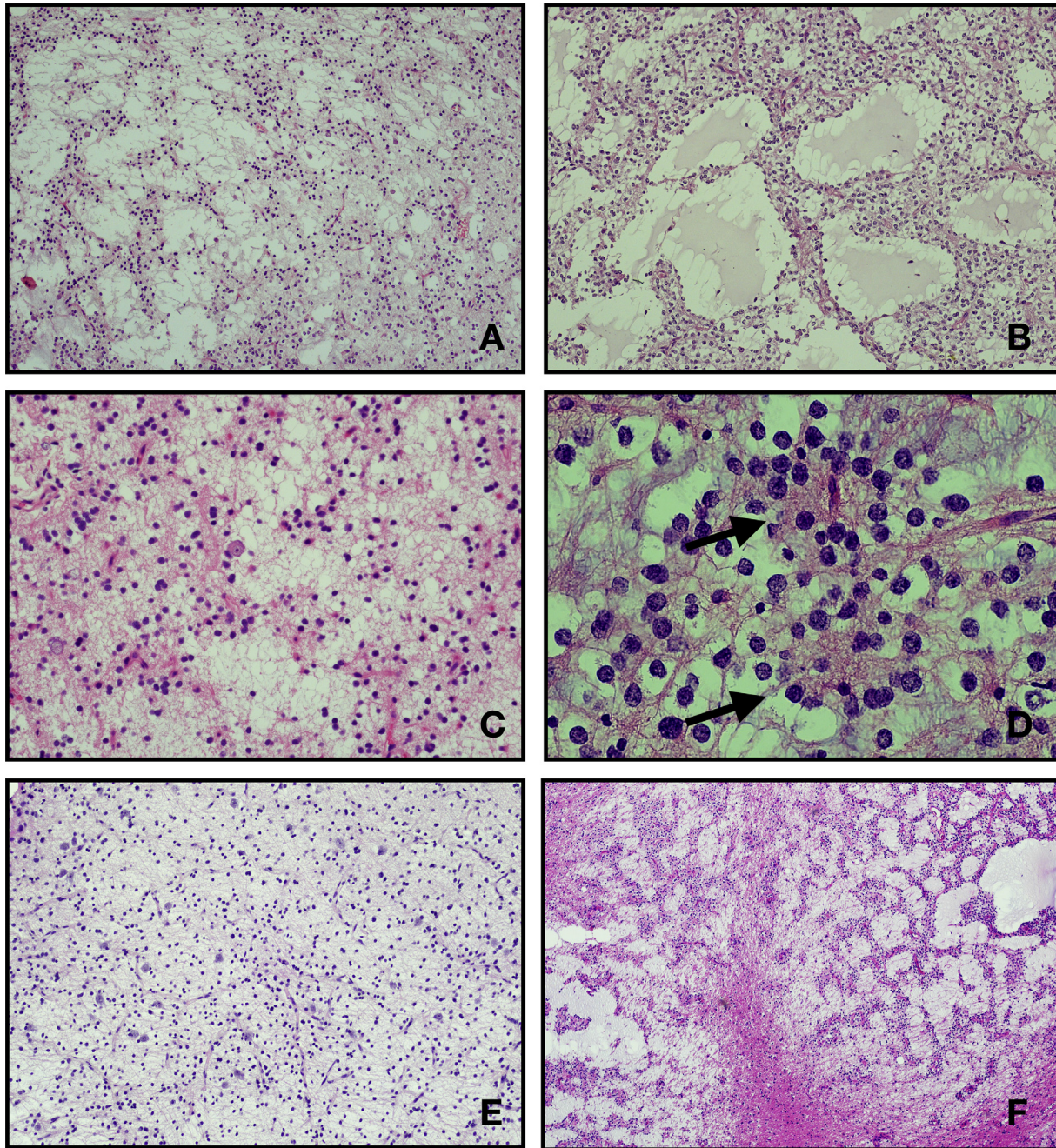


Fig. 2. Representative hematoxylin and eosin stained section of MGT reported in this series. All case show a low cellularity proliferation of oligodendrocyte-like cells with monotonous round to oval nuclei, small nucleoli, and scant to moderate eosinophilic cytoplasm within a mucin-rich stroma. The tumors mostly displayed a microcytic architecture (A, B, C, F: cases MGT#1, MGT#2, MGT#3, MGT#6). In some case the tumor cells are dispose to form strands and cords (F: case MGT#6). Scattered floating neurons are seen (A, C, E: cases MGT#1, MGT#3, MGT#5). Delicate rosettes could also be rarely found (D: case MGT#4).

ial and coronal T2 weighted sequences, axial FLAIR (Fluid attenuated inversion recovery) or FLAIR 3D weighted images and T13D post intravenous contrast. CT images were acquired with the helical technique and reconstructed on the three planes with MPR algorithm. The tumors were evaluated for location and radiological features both on MRI and TC images.

Results

Microscopic examination of the 31 tumors uniformly showed low-grade proliferation of small, round monotonous oligodendrocyte-like cells (OLCs) with oval nuclei, small nucleoli and scant to moderate

eosinophilic cytoplasm. A prominent myxoid stroma was present in all cases and floating neurons in an abundant mucinous matrix were seen at least focally in all tumors. Oligodendrocyte-like cells were strongly positive for Olig-2 and GFAP in all cases and all floating neurons were positive for NF and NeuN. CD34 immunoreactivity was limited to vascular endothelial cells only. BRAF V600E staining was negative in all cases. Proliferation index, evaluated with anti-Ki67 antibody, was uniformly low, ranging from <1% to 3%.

Genetic analysis of the recurrent *PDGFRA* p.Lys385 hotspot variants was positive in 6 out of 31 (19,35%) patients: five patients carried the c.1153_1154delAAinsTT (p.Lys385Leu) variant and one the c.1154_1155delAGinsTA (p.Lys385Ile) (Fig. 1).

Table 3
Imaging features of myxoid glioneuronal tumor.

Patient ID	Diagnosis	T1 signal	T2 signal	FLAIR signal	Contrast enhancement	Diffusion	Dissemination	Obstructive hydrocephalus	Parenchymal tumor involvement	Mineralization/Hemorrhage
1	MGT	Hypointense	Hyperintense	Hyperintense	None	Facilitated	None	Absent	Absent	None
2	MGT	Hypointense	Hyperintense	Hyperintense	None	Facilitated	None	Present, lateral ventricles	Present	None
3	MGT	Hypointense	Hyperintense	Hyperintense	None	NA	None	Present, lateral ventricles	Absent	None
4	MGT	Hypointense	Hyperintense	Hyperintense	None	Facilitated	None	Present, lateral ventricles	Absent	None
5	MGT	Hypointense	Hyperintense	Hyperintense	None	Facilitated	None	Absent	Present	None
6	MGT	Hypointense	Hyperintense	Hyperintense	None	Facilitated	None	Absent	Present	NA

MGT: Myxoid glioneuronal tumor; NA: Not available

Table 4
Imaging features of dysembryoplastic neuroepithelial tumor.

Patient ID	Diagnosis	T1 signal	T2 signal	FLAIR signal	Contrast enhancement	Diffusion	Dissemination	Obstructive hydrocephalus	Parenchymal tumor involvement	Mineralization/Hemorrhage
1	DNT	Hypointense	Hyperintense	Hyperintense	None	Facilitated	None	Present, lateral ventricles	Absent	None
2	DNT	NA	NA	NA	NA	NA	NA	NA	NA	NA
3	DNT	Hypointense	Hyperintense	Hyperintense	Yes	Not restricted	None	Absent	Present	Present
4	DNT	Hypointense	Hyperintense	Hyperintense	NA	Facilitated	None	Absent	Present	None
5	DNT	Hypointense	Hyperintense	Hyperintense	Yes	NA	None	Absent	Present	None
6	DNT	Hypointense	Hyperintense	Hyperintense	None	NA	None	Absent	Present	None
7	DNT	Hypointense	Hyperintense	Hyperintense	None	NA	None	Absent	Present	None
8	DNT	Hypointense	Hyperintense	Hyperintense	Yes	NA	None	Absent	Present	None
9	DNT	Hypointense	Hyperintense	Hyperintense	NA	NA	None	Absent	Present	None
10	DNT	NA	NA	NA	NA	NA	NA	NA	NA	NA
11	DNT	Hypointense	Hyperintense	Hyperintense	Yes	NA	None	Absent	Present	NA
12	DNT	Hypointense	Hyperintense	Hyperintense	None	Facilitated	None	Absent	Present	NA
13	DNT	Hypointense	Hyperintense	Hyperintense	None	Facilitated	None	Absent	Present	NA
14	DNT	Hypointense	Hyperintense	Hyperintense	None	Facilitated	None	Absent	Present	NA
15	DNT	Hypointense	Hypointense	Hypointense	None	Not restricted	None	Absent	Present	Present
16	DNT	Hypointense	Hyperintense	Hyperintense	None	NA	None	Absent	Present	Present
17	DNT	Hypointense	Hyperintense	Hyperintense	Yes	NA	None	Absent	Present	NA
18	DNT	Hypointense	Hyperintense	Hyperintense	None	Facilitated	None	Absent	Present	None
19	DNT	NA	NA	NA	NA	NA	NA	NA	NA	NA
20	DNT	Hypointense	Hyperintense	Hyperintense	None	NA	None	Absent	Present	NA
21	DNT	Hypointense	Hyperintense	Hyperintense	None	NA	None	Absent	Present	None
22	DNT	Hypointense	Hyperintense	Hyperintense	None	NA	None	Absent	Present	NA
23	DNT	Hypointense	Hyperintense	Hyperintense	None	Facilitated	None	Absent	Present	NA
24	DNT	NA	NA	NA	NA	NA	NA	NA	NA	NA
25	DNT	NA	NA	NA	NA	NA	NA	NA	NA	NA

DNT: Dysembryoplastic neuroepithelial tumor; NA: Not available

These six patients have a tumor located in the periventricular white matter of the lateral ventricle and in the septum pellucidum. Therefore, these six tumors were re-diagnosed as MGTs.

Clinical and surgical features of the 6 MGTs specimens are listed in Table 1. Clinical and surgical features of the 25 DNTs specimens are listed in Table 2.

In all MGTs mitotic figures were inconspicuous (absent or less than 1 per 10 high power fields). Neither necrosis nor vascular proliferation/hyperplasia was seen in any of these tumors. Rare neurocytic rosettes were observed (MGT#4). None of the MGTs in this series showed micro calcifications. Conversely, 6 DNTs (24%; DNT#3, DNT#10, DNT#11, DNT#15, DNT#18, DNT#22) showed at least focal micro calcifications (Fig. 2).

At neuroimaging, all MGT lesions in this series showed hypodensity at CT images while MR revealed weak hyperintensity in T2 and hypointensity in T1 (Fig. 3). No contrast enhancement or restricted diffusion was seen in any of the MGT patients. Calcifications and multinodularity, common features of cortical DNT, were absent in all. Obstruc-

tive hydrocephalus occurred in three out of six patients (50%) and in particular in all those whose tumor was located in the septum pellucidum. Prominent peritumoral edema was not observed. Pre-operative MRI features of the 6 MGTs and of the 25 DNTs are listed in Table 3 and Table 4 respectively.

Discussion

MGT, originally described and named by Solomon et al. in 2018, is a benign (WHO, grade 1) glioneuronal neoplasm [1]. To date less than 100 observations are available in the literature. These tumors, typically, arise in the periventricular region preferentially affecting the septum pellucidum, caudates nucleus, and foramina of Monro. They have an approximately equal sex distribution and predominantly occur in children and young adults, with a peak incidence in the second and third decades of life [2].

The six MGTs we describe in this series were in the typical arising sites, four in the periventricular white matter of the lateral ven-

tricle and two in the septum pellucidum. Another tumor in our series was located in the foramen of Monro, a typical site for MGT. We were not able to demonstrate the *PDGFRA* recurrent variant at p.Lys385 site in this case. This processed sample presents several critical points. It was one of the first sample collected in 2011, the extraction yield was very low compared to the other samples, and the quantitative and qualitative values are not optimal. This may have affected the PCR reaction, prevented the amplification of the mutant allele and its subsequent identification by sanger sequencing. The radiologi-

cal and histological characteristics of this tumor were indistinguishable from the other MGTs of this series. These features, combined with its localisation, may suggest that this tumor could be considered a MGT too.

The age of the patients ranged from 2 to 19 years, including the first available observation under the age of 3 years. The slight predominance we observed in males (4/6) is too small to be relevant.

PDGFRA activation is known to be a frequent genetic driver in many human tumor types including MGTs [1,6]. Different recurrent missense

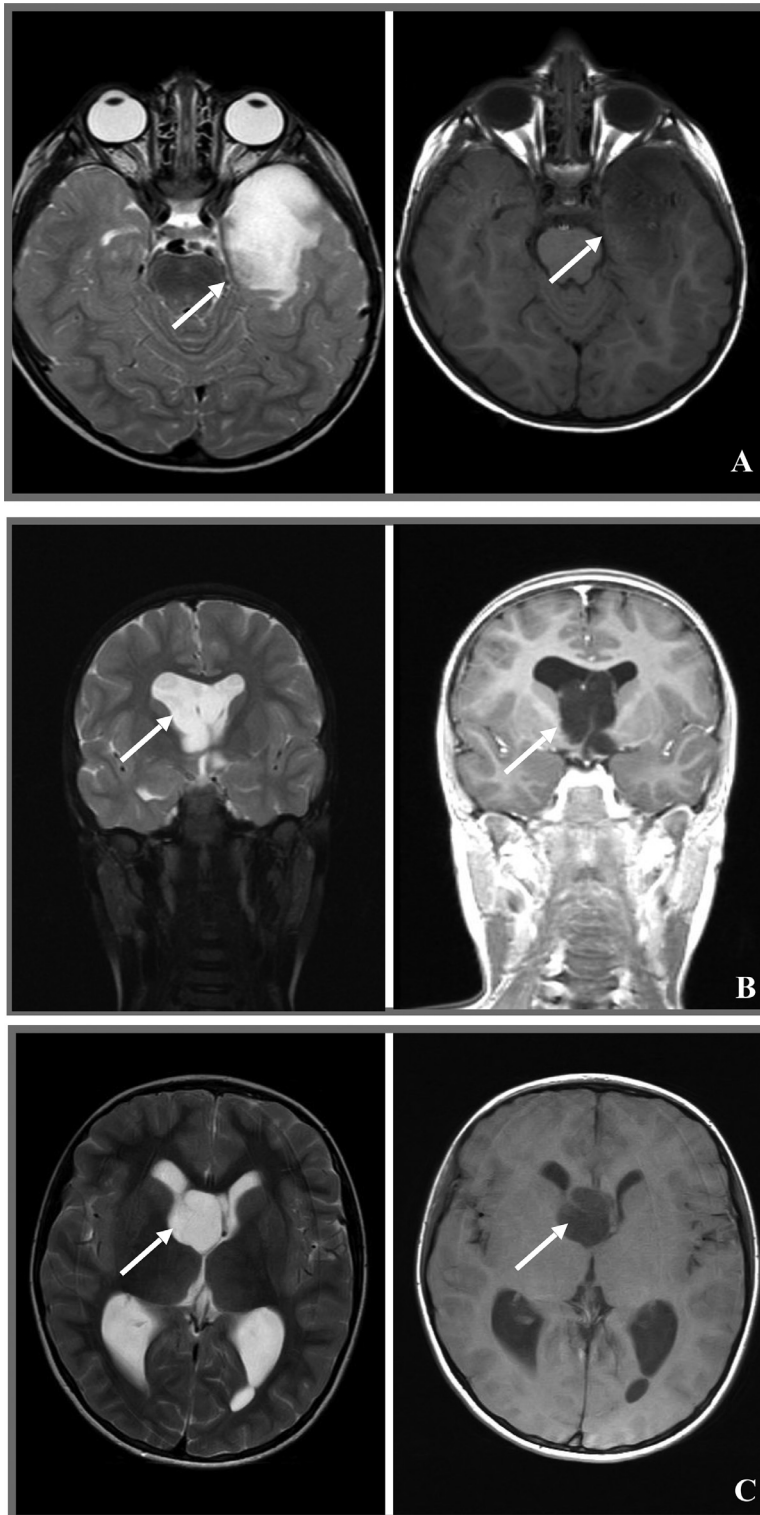
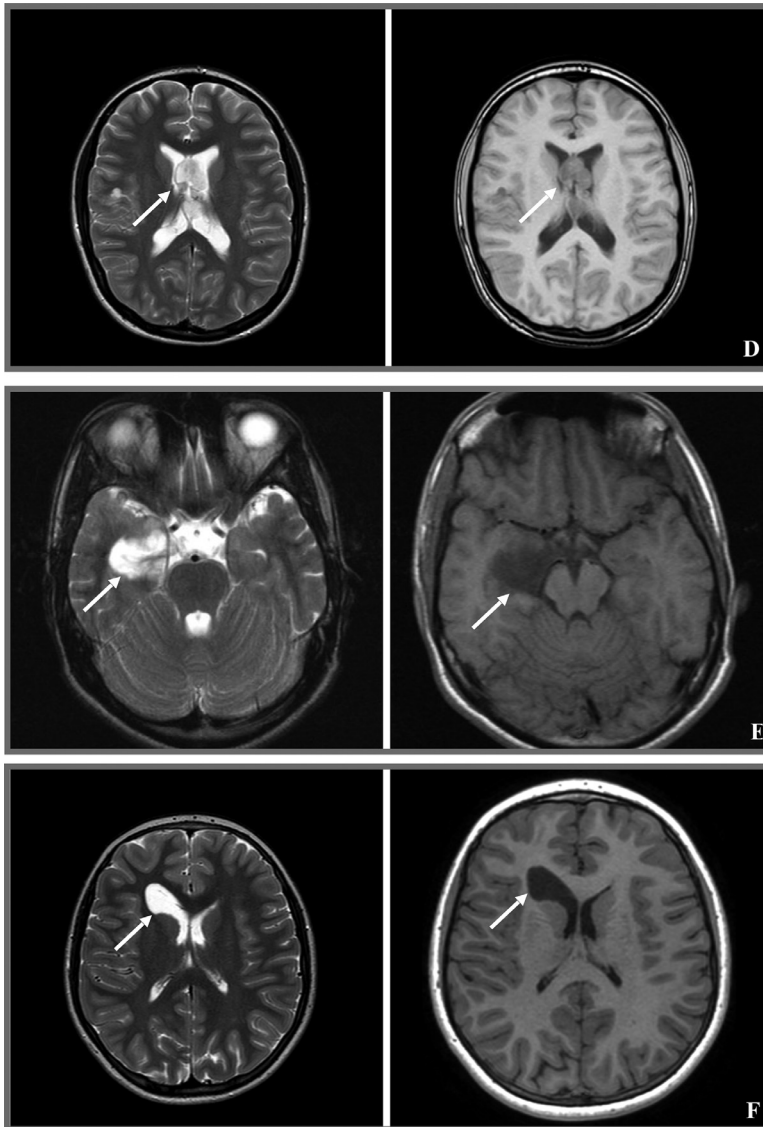


Fig. 3. Neuroradiologic features of MGTs reported in this series. All cases displayed a lesion with hyperintense signal in T2-weighted images and with hypointense signal in T1-weighted images, without contrast enhancement. (A: MGT#1; B: MGT#2; C: MGT#3; D: MGT#4; E: MGT#5; F: MGT#6).



variants in *PDGFRA* have been identified in paediatric and adult tumors, such as the p. Cys235Tyr, p.Glu229Lys, and p.Tyr288Cys in glioblastoma and recently, the variants at codon p.Lys385 (p.Lys385Leu and p.Lys385Ile), proved to be highly specific to MGT. The high specificity of this genetic variants has been also sustained by methylation studies which suggested a distinctive methylation profile in tumors harboring an alteration at p. Lys385 residue [7]. The p. Lys385 residue falls in one of the immunoglobulin-like C2 domains in the extracellular ligand-binding portion of the receptor tyrosine kinase and the recurrent p. Lys385Leu/Ile variants are predicted to cause constitutive activation of the intracellular kinase domain [1]. We identified 5 samples (MGT#1, MGT#3, MGT#4, MGT#5, and MGT#6) carrying the dinucleotide change c.1153_1154delAAinsTT leading to the p. Lys385Leu substitution and one sample (MGT#2) carrying the c.1154_1155delAGinsTA leading to the p. Lys385Ile substitution. None of those variants were present in GnomAD (<https://gnomad.broadinstitute.org/>) or in HGMD (*Human Gene Mutation Database*, <http://www.hgmd.cf.ac.uk>). The c.1154_1155delAGinsTA variants was reported in the somatic COSMIC database (Catalogue of Somatic Mutations in Cancer, <http://cancer.sanger.ac.uk/cosmic>) associated with astrocytoma grade IV (COSM505847) [8].

Histopathologically, cortical DNTs and MGTs are indistinguishable, as they show delicate microcytic architecture, floating neurons, and ho-

momorphous oligodendrocyte-like cells embedded in a myxoid matrix [4,2]. In contrast to classical DNTs, MGTs lack histologic aspects of multinodularity and calcifications are very rarely described. Sign of histological malignancy, such as a brisk mitotic activity, necrosis, and/or vascular proliferation are not reported. Differential diagnosis, beyond DNT, should include low-grade gliomas and low grade glioneuronal tumors such as pilocytic astrocytoma, ganglioglioma, and rosette-forming glioneuronal tumor. Therefore, a careful histological examination, a small panel of immunohistochemical markers and the demonstration of the specific *PDGFRA* p. Lys385 mutations at the molecular level should be considered to differentiate an MGT from its potential mimics.

Our series confirms previously reported MRI features with hypointense appearance in T1 and hyperintense signal in T2 [3]. Most of the MGTs have a cyst-like appearance and show high intensity FLAIR signal, especially in the periphery of the cyst. In line with previous reports, in none of our patients contrast enhancement or restricted diffusion were seen [9]. Calcifications, a common feature of cortical DNTs have never been observed. Obstructive hydrocephalus occurred in the two patients with tumors centered in the septum pellucidum and in the one whose tumor was centered in the periventricular white matter. The other patients did not show sign of obstructive hydrocephalus. The main differential diagnosis at neuroimaging should consider colloid cysts, ganglioglioma, pilocytic astrocytomas, subependymomas and central neuro-

cytomas [10]. Colloid cysts are midline lesions, while MGTs generally are more eccentrically located [9]. Ganglioglioma and pilocytic astrocytoma are, conversely to MGTs, contrast enhancing in almost instance. Sub ependymomas are rare tumors, typically of the middle-aged to elderly patients. These are solid glial lesions with a central hyperintense signal on the FLAIR image [11]. Central neurocytomas show calcifications in about 50% of patients and a variable and heterogeneous post-gadolinium enhancement.

Clinically, MGTs have an indolent or benign clinical behavior [2]. The majority of these tumors have been successfully treated by surgery only, with no relapse during follow-up. Only a subset of tumors tend to recur locally or disseminate along the ventricular system after resection but despite this they continue to be associated with indolent behavior [5].

In our series, most MGTs (5/6) were treated with gross total surgical resection and only one patient (1/6, 17%) received a sub-total resection. None of our patients experienced a MGT recurrence at follow-up, confirming a good outcome in these patients.

In conclusion, MGT is a rare low-grade glioneuronal neoplasm are typically located in the septum pellucidum, periventricular white matter of the lateral ventricle or foramen of Monro. They exhibit a typical MRI profile, with no contrast enhancement. MGT are histologically almost indistinguishable from DNT but are unique from a molecular perspective as they are the only CNS tumor entities carrying the *PDGFRA* mutation as solitary genetic driver to date. Surgical resection is the treatment of choice and is associated with a good outcome even if rare disseminated or recurrent lesions have been reported.

The correct integration of the clinical, imaging, morphological and, possibly, molecular data is fundamental for a correct diagnosis.

This study was made possible in part due to The Children's Brain Tumor Network (CBTN).

Declaration of Competing Interest

None.

CRediT authorship contribution statement

C. Caporalini: Conceptualization, Writing – original draft, Writing – review & editing. **M. Scagnet:** Supervision. **L. Giunti:** Data curation. **V. Cetica:** Data curation, Formal analysis, Supervision. **D. Mei:** Data curation, Formal analysis, Supervision. **V. Conti:** Data curation, Formal analysis, Supervision. **S. Moscardi:** Data curation. **L. Macconi:** Supervision. **F. Giordano:** Supervision. **L. D'Incerti:** Supervision. **L. Genitori:** Supervision. **R. Guerrini:** Writing – review & editing. **A.M. Buccoliero:** Conceptualization.

References

- [1] D.A. Solomon, A. Korshunov, M. Sill, D.T.W. Jones, M. Kool, S.M. Pfister, X. Fan, S. Bannykh, J. Hu, M. Danielpour, R. Li, J. Johnston, E. Cham, T. Cooney, P.P. Sun, N.A. Oberheim Bush, M. McDermott, J. Van Ziffle, C. Onodera, J.P. Grenert, B.C. Bastian, J.E. Villanueva-Meyer, M. Pekmezci, A.W. Bollen, A. Perry, Myxoid glioneuronal tumor of the septum pellucidum and lateral ventricle is defined by a recurrent *PDGFRA* p.K385 mutation and DNT-like methylation profile, *Acta Neuropathol.* 136 (2) (2018) 339–343, doi:10.1007/s00401-018-1883-2.
- [2] WHO Classification of Tumours Editorial Board, *Central Nervous System Tumours. Lyon (France): International Agency for Research on Cancer, 6, 5th ed., WHO Classification of Tumours Series; WHO, Geneva, Switzerland, 2021.*
- [3] C.G. Lucas, J.E. Villanueva-Meyer, N. Whipple, N.A. Oberheim Bush, T. Cooney, S. Chang, M. McDermott, M. Berger, E. Cham, P.P. Sun, A. Putnam, H. Zhou, R. Bollo, S. Cheshier, M.M. Poppe, K.M. Fung, S. Sung, C. Glenn, X. Fan, S. Bannykh, J. Hu, M. Danielpour, R. Li, E. Alva, J. Johnston, J. Van Ziffle, C. Onodera, P. Devine, J.P. Grenert, J.C. Lee, M. Pekmezci, T. Tihan, A.W. Bollen, A. Perry, Solomon DAMyxoid glioneuronal tumor, *PDGFRA* p.K385-mutant: clinical, radiologic, and histopathologic features, *Brain Pathol.* 30 (3) (2020) 479–494, doi:10.1111/bpa.12797.
- [4] M. Thom, A. Toma, S. An, L. Martinian, G. Hadjivassiliou, B. Ratilal, A. Dean, A. McEvoy, S.M. Sisodiya, S. Brandner, One hundred and one dysembryoplastic neuroepithelial tumors: an adult epilepsy series with immunohistochemical, molecular genetics, and clinical correlations and a review of the literature, *J. Neuropathol. Exp. Neurol.* 70 (10) (2011) 859–878, doi:10.1097/NEN.0b013e3182302475.
- [5] B.K. Kleinschmidt-DeMasters, J. Chiang, A.M. Donson, T. Borges, A. Gilani, Myxoid glioneuronal tumor, *PDGFRA* p.K385L-mutant, arising in midbrain tectum with multifocal CSF dissemination, *Brain Pathol.* 32 (1) (2022) e13008, doi:10.1111/bpa.13008.
- [6] C.K.M. Ip, P.K.S. Ng, K.J. Jeong, S.H. Shao, Z. Ju, P.G. Leonard, X. Hua, C.P. Vellano, R. Woessner, N. Sahni, K.L. Scott, G.B. Mills, Neomorphic *PDGFRA* extracellular domain driver mutations are resistant to *PDGFRA* targeted therapies, *Nat. Commun.* 9 (1) (2018) 4583, doi:10.1038/s41467-018-06949-w.
- [7] J.C.H. Chiang, J.H. Harreld, R. Tanaka, X. Li, J. Wen, C. Zhang, D.R. Boué, T.M. Rauch, J.T. Boyd, J. Chen, J.C. Corbo, T.W. Bouldin, S.W. Elton, L.L. Liu, D. Schofield, S.C. Lee, J.P. Bouffard, M.M. Georgescu, R.H. Dossani, M.A. Aguiar, R.A. Sances, A.G. Saad, F.A. Boop, I. Qaddoumi, D.W. Ellison, Septal dysembryoplastic neuroepithelial tumor: a comprehensive clinical, imaging, histopathologic, and molecular analysis, *Neuro. Oncol.* 21 (6) (2019) 800–808, doi:10.1093/neuonc/noz037.
- [8] J. Schwartzentruber, et al., Driver mutations in histone H3.3 and chromatin remodelling genes in paediatric glioblastoma, *Nature* 482 (7384) (2012) 226–231, doi:10.1038/nature10833.
- [9] C. Zamora, M. Castillo, From dysembryoplastic neuroepithelial tumors to myxoid glioneuronal tumors, a new entity, *AJNR Am. J. Neuroradiol.* 42 (11) (2021) E77–E78, doi:10.3174/ajnr.A7273.
- [10] B.L. Baisden, D.J. Brat, E.R. Melhem, M.K. Rosenblum, A.P. King, P.C. Burger, Dysembryoplastic neuroepithelial tumor-like neoplasm of the septum pellucidum: a lesion often misdiagnosed as glioma: report of 10 cases, *Am. J. Surg. Pathol.* 25 (4) (2001) 494–499, doi:10.1097/0000478-200104000-00009.
- [11] E.O. Narvaez, B.S.Y. Inada, P. de Almeida, L.F. Freitas, M.D. Soldatelli, D.M.C. Costa, V.H.R. Marussi, C.S. Campos, J.L. Vitorino Araujo, H. Carrete Junior, L.L.F. do Amaral, Myxoid glioneuronal tumor - report of three cases of a new tumor in a typical location and review of literature, *BJR Case Rep.* 7 (4) (2021) 20200139, doi:10.1259/bjrcr.20200139.