

# New signs of skeletal trauma in the Upper Paleolithic *Principe* from Arene Candide Cave (Liguria, Italy) bear novel insights into the circumstances of his death

Vitale Stefano Sparacello<sup>1</sup>, Irene Dori<sup>2</sup>, Nico Radi<sup>3</sup>, Patrizia Garibaldi<sup>4</sup>, Irene Molinari<sup>4</sup>, Julien Riel-Salvatore<sup>5</sup>, Claudine Gravel-Miguel<sup>5,6</sup>, Marta Zunino<sup>7</sup>, Fabio Negrino<sup>8</sup> & Elisabetta Starnini<sup>9</sup>

1) *Università degli Studi di Cagliari, Dipartimento di Scienze della Vita e dell'Ambiente, Cagliari, Italy*  
e-mail: vitale.sparacello@unica.it

2) *Università degli Studi di Firenze, Dipartimento di Biologia, Firenze, Italy*

3) *Soprintendenza Archeologia Belle Arti e Paesaggio per la Liguria, Genova, Italy*

4) *Museo Civico di Archeologia Ligure, Genova, Italy*

5) *Université de Montréal, Department of Anthropology, Montréal, Canada.*

6) *New Mexico Consortium, Los Alamos, USA*

7) *Grotte di Toirano, Toirano, Savona, Italy*

8) *DAFIST - Dipartimento di Antichità, Filosofia, Storia, Università degli Studi di Genova, Genova, Italy*

9) *Dipartimento di Civiltà e Forme Del Sapere, Università di Pisa, Pisa, Italy*

**Summary** - *Despite ample evidence that Paleolithic humans hunted large and dangerous carnivores, such as lions, leopards, and bears, skeletal evidence of negative interactions with wild fauna is extremely rare in the Homo sapiens paleobiological record. To date, the only individual for whom an animal attack has been hypothesized based on their pattern of traumatic lesions is the Gravettian adolescent buried at Arene Candide Cave in Liguria (Northwestern Italy; 27,900-27,300 cal BP) nicknamed Il Principe (The Prince) due to the rich grave goods placed in the burial. Since its excavation in 1942, it was noted that this individual was missing part of the mandible and half of the left clavicle, leading to the hypothesis of an attack by a large animal, likely a bear. However, this claim was never fully investigated. We reanalyzed these lesions and systematically examined the skeleton for additional evidence to reconstruct the manner and circumstances of death. Our analysis confirmed the perimortem nature of the mandibular and shoulder lesions and identified other possible fractures related to the violent event in the cranium, dentition, and possibly the cervical spine. Additional perimortem trauma, including a linear marking on the left parietal and a puncture mark in the fibula, supports the hypothesis of animal mauling. Given the overall traumatic pattern, a bear attack - Ursus arctos or Ursus spelaeus - remains the most plausible explanation. The study also revealed that the Principe had sustained traumatic injuries to his feet - a fracture of the left little toe and osteochondritis dissecans in the right talus - which support the hypothesis that prehistoric foragers experienced limited survival following lower limb injuries. Despite the thoraco-facial trauma and disfiguring wounds, the microscopic analysis suggests that the Principe survived for a few days. The violent event and the long agony may have been reflected in the elaborate burial, following the presumed Gravettian use of formally burying exceptional individuals and exceptional events.*

**Keywords** - *Animal attack, Human-bear interaction, Perimortem trauma, Tooth mark, Gravettian, Violence in prehistory.*

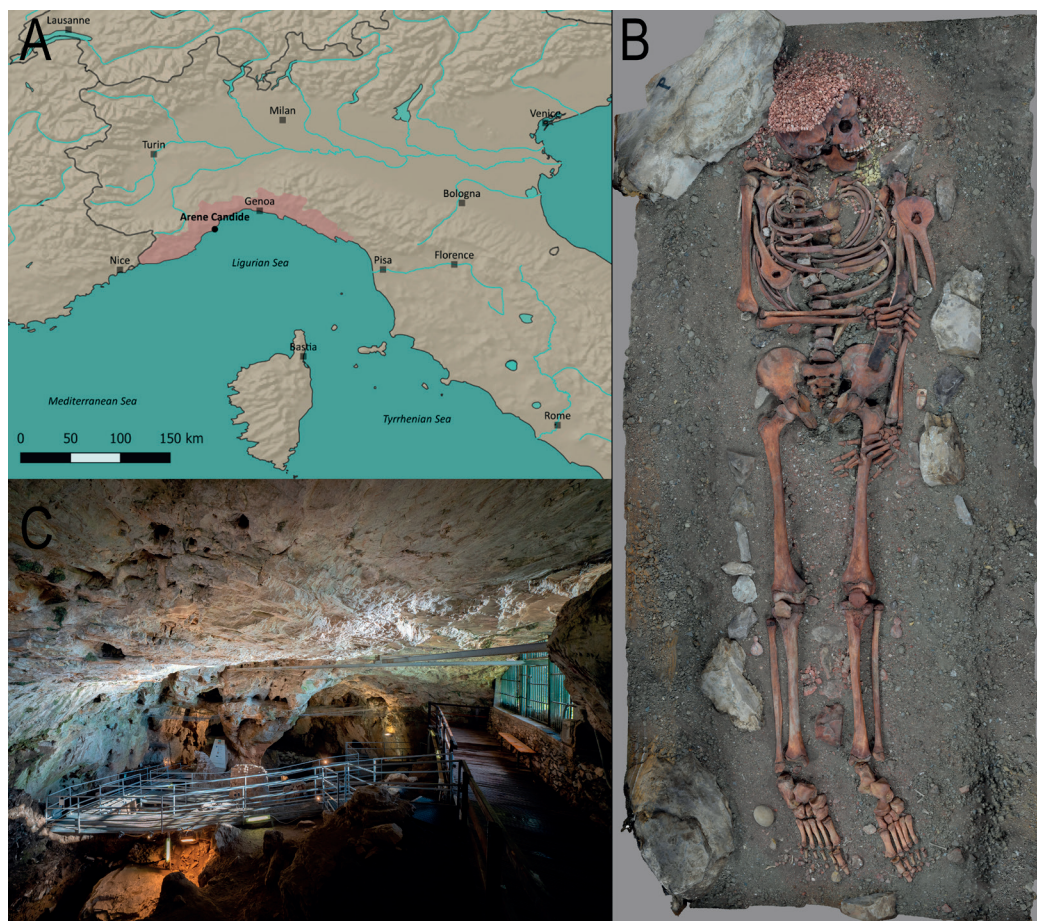
## Introduction

Skeletal evidence of trauma in the fossil record of prehistoric hunter-gatherers is abundant, and has been mostly explained as the result of accidents (such as falls) or interpersonal violence [Trinkaus and Zimmermann 1982; Trinkaus 2005, 2015; Belcastro et al. 2010; Trinkaus and Buzhilova 2012; Estabrook and Frayer 2014; Sala et al. 2015a,b, 2016; Lahr et al. 2016 (but see Stojanowski et al. 2016); Beier et al. 2018a,b; Chevalier 2019; Knüsel et al. 2023; Sparacello et al. 2023a,b, 2025; Wu and Trinkaus 2015; Wu et al. 2011]. Negative interactions with wild animals are more rarely considered when discussing the possible origin of injuries (Berger and Trinkaus 1995; Trinkaus 2012), although different Pleistocene *Homo* species hunted large and dangerous fauna, including bears and carnivores such as lions (e.g. Münzel and Conard 2004; Kitagawa et al. 2012; Daujeard et al. 2016; Romandini et al. 2018; Russo et al. 2023). Direct evidence of lethal attacks by predators is limited to a Neanderthal parietal fragment from Cova Negra (Spain) for the genus *Homo*, and two cases for australopithecines (Brain 1981; Berger 2006). Most evidence of humans (and other fossil hominins) consumed by carnivores is indirectly based on finding human skeletal remains showing gnaw marks in faunal assemblages accumulated by predators (review in Daujeard et al. 2016). In the Pleistocene *Homo sapiens* record, a bear attack or a “bad hunt” was hypothesized for *l’homme du Bichon* (Neuchâtel, Switzerland; 13,560–13,770 cal. BP; Chauvière 2008; Jones et al. 2015), a young adult associated with the skeletal remains of a bear. However, while there was evidence that the bear was hunted, the interpretation of some signs of trauma in the human skeleton remained inconclusive (Chauvière 2008). The only individual from the Upper Paleolithic for which an animal attack was hypothesized based on the pattern of skeletal trauma is the Gravettian adolescent buried at Arene Candide Cave in Liguria (northwestern Italy) nicknamed *Il Principe* (“The Prince”).

The Arene Candide Cave is one of the most important archaeological sites in the western Mediterranean, thanks to the richness of its

archaeological layers spanning the Mid-Upper Paleolithic to the Metal Ages. Numerous burials have been unearthed therein since the second half of the 19th century, including the Epigravettian “necropolis” (ca. 12,900–11,600 cal BP; Sparacello et al. 2018, 2021), and more than a hundred Neolithic burials (ca. 7300–6300 cal BP; Sparacello et al. 2019, 2020). The *Principe* (catalogued as Arene Candide 1; Alciati et al. 2005; Sparacello et al. 2018) was a primary and undisturbed burial containing an adolescent (age estimates range from 14–15 to 16.4–16.7 years old; Paoli 1974; Sergi et al. 1974; Cowgill 2008; Lewis et al. 2024) dated to ca. 27,900–27,300 cal BP (OxA-10700 23440±190 years BP; Pettitt et al. 2003; Riel-Salvatore et al. 2018), which represents one of the most spectacular examples of Gravettian funerary behavior in Italy (Holt and Formicola 2008; Riel-Salvatore and Gravel-Miguel 2013). The skeleton lay supine on a bed of red ochre, with hundreds of perforated shells and several deer canines forming a sort of head-dress, along with several ivory pendants, four antler *bâtons percés* (Molari 1994; Rigaud 2001), and a large (23 cm long) *stampien zoné* flint blade (Arrighi and Borgia 2008; Onoratini et al. 2011) held in his right hand (Fig. 1, large format image in SI 1). Recent work has demonstrated that, contrary to previous assertions that it had been procured hundreds of kilometers away (Solas et al. 2016), the ochre used in the burial was of local origin (Rellini et al. 2025). This indicates that the grave goods associated with the *Principe* combined rare, exotic items and material that would have been immediately available near the site.

The *Principe* was discovered during the fourth excavation campaign by Luigi Bernabò Brea, Luigi Cardini, and Virginia Chiappella on May 1<sup>st</sup>, 1942. The grave was recovered at the base of a unit Cardini dubbed the 5<sup>th</sup> hearth of the site’s Pleistocene deposits, corresponding to Level P10 in the site’s synthetic stratigraphy compiled by Bernabò Brea and Cardini (Bietti and Molari 1994). This level is a few thousand years older than the burial itself, which corresponds in age to overlying Level P9, a fact that is the result of the occupants of Level P9 having dug a shallow pit to



**Fig. 1** – A: Geographic location of Arene Candide in northern Italy, with the Liguria region highlighted in red. B: Zenital view of the “Il Principe” burial, as displayed at the Museo di Archeologia Ligure, Genova Pegli. The photogrammetric model was created for this study. C: a view of the eastern hall of Arene Candide Cave.

inter the *Principe* in Level P10 (Riel-Salvatore et al. 2018, 2023). Geoarchaeological and micromorphological investigations reveal that both levels P9 and P10 comprise mainly alternating, partially folded lenses of black and red sediment caused by shifts in accumulations of bat or bird guano and reddened iron-rich deposits that accumulated under conditions of arid periglacial climate associated with only punctual, episodic use of the cave by humans (MacPhail et al. 1994; Rellini et al. 2013). This provides circumstantial evidence that the burial of the *Principe* probably marks the

moment in which the Arene Candide were established as a ritually important landmark for the foragers of the region, as also indicated by the recovery of other decorated items in coeval Gravettian deposits (Riel-Salvatore et al. 2018, 2023; see also Riel-Salvatore and Gravel-Miguel 2013).

From the moment he was discovered, it was proposed that the *Principe* had suffered a significant traumatic event around the time of death (Cardini 1942). The field diaries report damage to the left scapula, left humeral head, the lack of the lateral portion of the left clavicle (May 16<sup>th</sup>,



**Fig. 2** – Left, the area affected by the thoraco-facial trauma, with the reconstructed cap of shells and the lump of yellow ochre below the mandible, as displayed today. Right, excavation picture of the same area (Archives of the Soprintendenza Archeologia Belle Arti e Paesaggio per la Liguria, Genova, Italy).

diaries of the fourth campaign), and the absence of a portion of the mandible (May 19<sup>th</sup>). Of the left half of the mandible, only the superior portion of the ascending ramus was present, the mandibular condyle still in articulation with the temporal. The right portion of the mandible was complete from the ascending ramus to the first molar, while the other teeth of the right hemimandible – from LRP2 to LRI1 – sat in a damaged alveolar fragment, with the lower portion of the mandibular body, including the mental eminence, missing (Fig. 2). Damage to the cervical vertebrae was also reported (Cardini 1942). Moreover, a large lump of yellow ochre was placed in the vacant hole left by the missing or damaged skeletal elements: between the neck, the left shoulder, and the mandible. Cardini hypothesized that the purpose of the yellow ochre was to “cover the vast lesion that must have horribly disfigured the deceased” (translation from

Cardini 1942, p.21) or to take advantage of the cauterizing properties of this substance. Sergi and colleagues hypothesized that the young man may have been attacked by a bear or a big cat (Sergi et al. 1974, p.21). Over the years, the idea that this Gravettian adolescent was killed during a hunting accident has become the prevailing narrative in local museum displays and publications intended for the general public. However, the lesions were never described in detail in a dedicated publication, nor have the manner and circumstances of his death been properly discussed based on this evidence. Additionally, in a review on Italian Upper Paleolithic burials, it was reported that the lesions in the *Principe* had begun to heal, implying that death may not have been immediate (Mussi et al. 1989). However, the basis for this claim was not explicitly detailed, nor was the vitality of the lesions and the timing of healing critically examined. This assertion was subsequently repeated

in later publications (Mussi 2001; Pettitt 2012), contributing to ongoing uncertainty regarding the precise circumstances of the *Principe's* death, particularly among the international scientific community, which may not have access to the original Italian sources.

In this paper, we report on our recent observations made on the Arene Candide 1 skeleton more than 80 years after its discovery: we documented the lesions reported in the literature and analyzed them under magnification, and we systematically investigated the skeleton in search of further elements that could add to the reconstruction of the manner and circumstances of death. In particular, we aimed at: 1) documenting the fractures and assessing their compatibility with perimortem trauma, as opposed to taphonomic damage; 2) replicating and properly documenting the observations made in previous studies regarding a commencement of the healing process; 3) searching for other lesions that would be expected in the context of an animal attack, such as bite and scratch marks; 4) analyzing the resulting pattern of injuries and determining the plausibility of the animal attack hypothesis as opposed to other kinds of trauma.

## Materials and methods

The Arene Candide 1 burial is on display at the *Museo di Archeologia Ligure* of Genova Pegli. Therefore, observations were made on bones *in situ* by momentarily removing selected elements from the display. Skeletal elements were visually analyzed under optic magnification and photographed with Nikon™ AF-S DX Micro Nikkor 40mm f/2.8G and Laowa Venus Optics 25mm f/2.8 2.5-5x Ultra Macro lenses. With the latter lenses, photo stacking of ca. 30 images per subject was performed using Helicon Focus 8 (© Helicon Soft Ltd 2000).

Three-dimensional surface models of selected elements were created via photogrammetry and structured light scanning (3D surface models are available online in the MorphoSource project “The Arene Candide

3D Database” <https://www.morphosource.org/projects/00000C206?locale=en>). Due to the ubiquitous coverage of red ochre and the risk of irreparably compromising the integrity of the surface, it was not possible to take silicon impressions of the lesions for study under SEM or confocal microscope. Owing to similar curatorial reasons, some skeletal elements (such as ribs, thoracic and lumbar vertebrae) were not removed from the display and therefore were not examined.

Several sources were employed to recognize the origin of numerous taphonomic marks left on the skeletal remains of the *Principe* (Haglund and Sorg 1997; Pokines and Symes 2014; Fernández-Jalvo and Andrews 2016; Schotsmans et al. 2017). For fractures, since we could not apply histological methods (Cappella and Cattaneo 2019), we relied on macroscopic features. Fractures on fresh (or “green”) bone, which typically occur peri-mortem, are characterized by smooth, curved surfaces, spiral or oblique fracture angles (often around 45°), and the presence of plastic deformation or hinging due to retained collagen and moisture content (Villa and Mahieu 1991; Sauer 1998; Wedel and Galloway 2014). In contrast, fractures on dry bone – commonly associated with postmortem, taphonomic breakage – tend to have right-angled or transverse break planes, sharp or jagged edges, irregular outlines, and brittle fracture surfaces lacking any plastic deformation. Additionally, dry bone fractures may exhibit differential coloration at the break edge compared to the surrounding surface. Distinguishing between taphonomic breakage and fractures on fresh bone is critical in this kind of archaeological forensic investigations, however its interpretation should be cautious because a variety of taphonomic processes could mimic fresh bone fractures, especially if they occurred not long after burial (Sauer 1998; Knüsel 2005; Ubelaker and Montaperto 2014; e.g. Sparacello et al. 2023a).

Recognizing signs of carnivore activity is equally important in this context. Both teeth and claws can leave an array of different marks on bones, which are classified based on their appearance and depth. Tooth marks on bone

surfaces are typically categorized as pits, punctures, scores, and furrowing (Maguire et al. 1980; Haynes 1980; Binford 1981; see review in Sala and Arsuaga 2018). Pits and punctures result from the pressure exerted by a tooth against the cortical surface of the bone; the distinction between them lies in depth: punctures penetrate the cortical bone, while pits do not (Sala et al. 2014b). Scores are elongated grooves created by the dragging of a tooth cusp across the bone surface, generally exhibiting a U-shaped cross-section with a flat base. Furrowing, on the other hand, is associated with carnivore gnawing behavior and involves the removal of cancellous bone tissue. This type of damage can vary in intensity, ranging from light to heavy, depending on the extent of the cancellous bone that has been extracted (Haynes 1982). In contrast, claw marks – though less common – are generally more superficial and linear, lacking the depth or crushing associated with tooth impressions, and may occur in parallel sets indicative of grasping or scratching behavior (Haynes 1983; see Sala et al. 2024). Different papers report metric data on tooth mark analyses of several taxa, allowing for an attempt to identify the animal responsible for the marks (review in Sala and Arsuaga 2018). However, the wide variety of analytical methodologies applied, particularly concerning the metric parameters of tooth marks, can sometimes complicate direct comparisons between archaeological specimens and existing published data (Sala and Arsuaga 2018).

## Results

### *A new look at known lesions*

Before being re-assembled in the display at the *Museo di Archeologia Ligure* shortly after the end of the Second World War, the skeleton was restored with ample use of different types of resin and glue. This makes the visual examination of certain bone fractures and possible lesions very difficult to impossible; the following observations should be considered tentative and interpreted with caution.

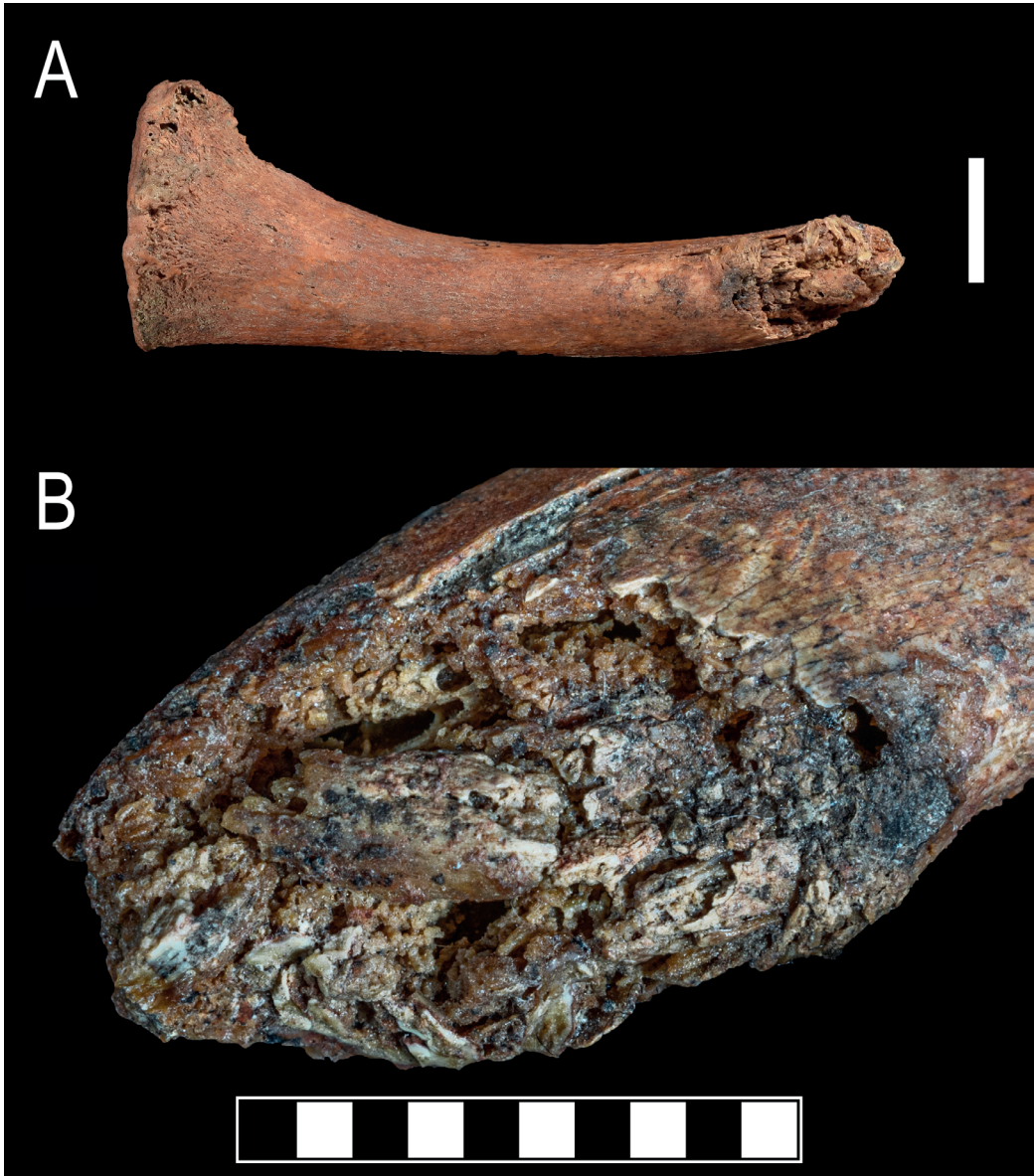Possible perimortem comminuted fractures were reported by Cardini at the left humeral midshaft during excavation (May 19<sup>th</sup>, 1942); however, the thorough restoration of the area makes it impossible to examine. From what can be surmised from the excavation photos, the fracture margins seem most compatible with taphonomic damage, as they appear jagged, lack curvilinear or spiral fractures, and the fractured cortical bone appears lighter than the surface (Fig. SI2; Sauer 1998; Knüsel 2005; Ubelaker and Montaperto 2014). Similarly difficult is a systematic evaluation of craniofacial fractures, which could be expected if part of the mandible was indeed lost due to trauma. Excavation pictures show the fractures before restoration only on the right side of the cranium. The fractures on the right parietal seem to have occurred on dry bone, given their straight appearance with abrupt changes in direction, and were probably caused by the weight of the stones and sediment placed on the cranium (Figs. 2 and SI3). No excavation pictures allow for an evaluation of the fractures on the left side of the cranium, which can therefore only be evaluated on the restored specimen. On this side, fractures follow a pattern that can be observed in the context of massive craniofacial trauma (Fig. SI4a,b; cf. Fig. 1 in Ueda et al. 2021; cf. cover image of Grauer 2023): departing from a depressed area above the glabella and the left supraciliary arch, radiating fractures extend vertically, following an area of weaker buttressing proposed by experimental research (Gurdjian et al. 1953; Gurdjian 1975; Galloway and Wedel 2014, p.142), and horizontally through the frontal, as seen in various cases of blunt force trauma (e.g. Sparacello et al. 2023 and references therein). In the left occipital, an area delimited by a vertical curvilinear fracture and the temporomastoid and parietal sutures appears plastically depressed (Fig. SI4c, d; cf. Kimmerle and Baraybar 2008, p.158). The margins of these fractures appear sharp and curvilinear as would be expected in a context of perimortem trauma; however, the heavy use of plaster and glue hampers a more detailed analysis, and makes it impossible to evaluate the presence

of beveling. To confirm this interpretation, it would be necessary to apply techniques enabling a more detailed assessment of lesion margins and patterns, such as high-resolution computed tomography and segmentation based on density contrasts (e.g. [Wo et al. 2011](#); [Kranioti 2015](#); [Coqueugniot et al. 2020](#); [Sala et al. 2024](#)).

Early publications reported damage to the left shoulder (humeral head, clavicle, and scapula), cervical vertebrae, and mandible ([Cardini 1942](#); [Sergi et al. 1974](#)). [Cardini \(1942\)](#) also mentioned a crushed upper left maxillary molar. Due to curatorial reasons, the scapula could not be unearthed from the reconstruction of the burial on display; however, the portion that emerges from the soil does not show signs of trauma. All the cervical vertebrae are fractured in the anterior and left portion, and portions of the body and transverse process are missing. When the vertebrae are articulated, the pattern of bone loss is coherent amongst segments, and is compatible with a single agent exerting damage on the neck region (Fig. SI5). Similar injuries have been reported in clinical literature as a consequence of violent compression of the spine during motor vehicle accidents and falls, resulting in the crushing of several adjacent vertebral bodies (e.g. [El-Faramawy et al. 2012](#); [McMordie et al. 2023](#)). However, determining whether the damage is of taphonomic or perimortem origin – or even the vitality of the lesions ([Cappella and Cattaneo 2019](#)) – is challenging due to the glues and consolidants used in this region (probably during the excavation), which hardened the fine soil that filled the trabecular bone. Thanks to field documentation, we can observe that the damage was present at the time of the excavation (Fig. 2): the picture as well as the diaries, which are very detailed regarding the clearing of this part, do not support the presence of a taphonomic agent that could have produced the damage, such as a rock wedged in the area around the neck.

Clearer evidence on the nature of the bony damage comes from the humeral and especially clavicular damage. The clavicle displays a transverse irregular breakage with collapsed margins, while the humeral head is partially missing.


Although taphonomic loss of trabecular bone is present in the humeral head, high magnification imagery shows the smoothing and rounding of trabeculae that were most likely broken around the time of death and resorbed by the osteoclastic activity initiated by the inflammatory reaction ([Cappella and Cattaneo 2019](#); Fig. SI6). Another insight into the vitality of the lesions comes from the presence of unevenly distributed new bone formations, which are limited to the spongy bone and do not extend for more than a couple of millimeters in thickness (Fig. SI6). This is particularly evident in the clavicle, where this limited bone formation incorporates fragments of crushed bone (Figs. 3 and SI7). High-magnification images reveal resorption and remodeling of the original trabeculae, with newly formed woven bone seamlessly continuous with their surfaces, underscoring the structured, biologically mediated process of osteogenesis distinct from amorphous deposition of carbonate concretions such as *Mondmilch* (carbonate spherulites) formations (Figs. 4 and SI7-9; cf. [Kramar 2008](#)). In the cortical bone, only slight bone resorption can be appreciated, and the complete absence of proliferative bony reaction indicates that the observed process is not the result of initial subperiosteal new bone formation ([Boyd 2018](#)) – indeed no callus can be observed – but in fact constitutes an example of inter-trabecular bone formation ([Sandberg and Aspenberg 2016](#)). This healing process is specific to cancellous bone healing, and – as opposed to endochondral ossification typical of shaft fractures – acts via membranous bone formation following inflammation, with mesenchymal cell condensing forming osteoid, which becomes woven bone. This process is limited to a couple of millimeters from the damaged trabeculae, but it occurs quickly as the entire volume around the wounded area undergoes osteoid formation ([Diamond et al. 2007](#); [Aspenberg and Sandberg 2013](#); [Chen et al. 2015](#); [Sandberg and Aspenberg 2016](#)). Experimental studies show that a few millimeters hole drilled into cancellous bone can be filled with new tissue in less than a week, about three times faster than endochondral healing of shaft fractures ([Sandberg and Aspenberg 2016](#)).



**Fig. 3** – A: Superior view of the remaining portion of the left clavicle; scale in cm. B – Detail of the crushed area, showing intertrabecular ossification; scale in mm.

The observation of similar bony reactions in the largest portion of the surviving mandible (the right portion) – which displays a transverse irregular breakage with collapsed margins, similar to the clavicular damage – is hampered by the

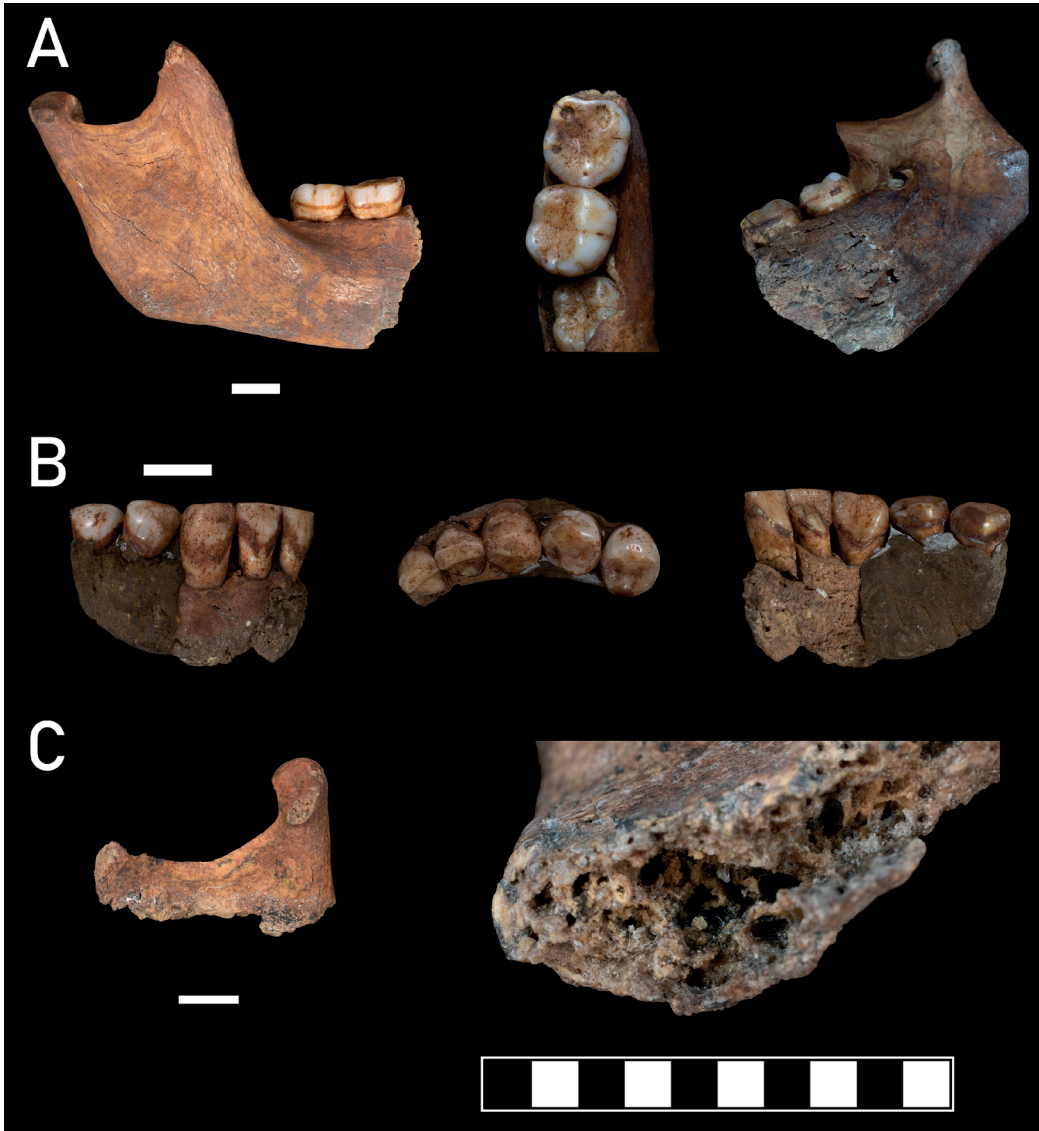heavy use of consolidants and plaster. However, intertrabecular bone formation can be observed in the preserved portion of the left mandibular ramus, albeit it was difficult to document due to the morphology of the area (Fig. 5).



**Fig. 4** – The crushed portion of the left clavicle; high-magnification images obtained through macro-photography and photo stacking. **A:** The crushed area with squares indicating the magnified portions. **B:** magnification of the area indicated by the red rectangle, showing rounded margins of the cortical bone, including of the embedded fragment, and intertrabecular ossification; **C:** further magnification of B, showing resorption and remodeling of trabeculae, and newly-formed woven bone seamlessly continuous with their surfaces; **D:** magnification of the area indicated by the blue rectangle, showing woven bone forming below and embedding the crushed fragments of cortical bone.

The only tooth showing significant damage is the upper left second molar (ULM2), with a missing crown due to a complete fracture while the roots remained in the alveolus (Fig. SI10). The other preserved teeth are in a good state of conservation, showing only minor taphonomic cracking. The resins and glue used for the restoration were also applied to all dental crowns, embedding soil and yellow ochre beneath the adhesive layer. The same treatment has been applied to the roots of ULM2, making it challenging to observe the fracture and determine whether it occurred during the individual's life, perimortem, or postmortem (due to taphonomic or excavation damage). However, considering the presence of ochre on the occlusal

surfaces of the roots and its abundance on the posterior teeth of the same arch, a postmortem origin can be excluded. Furthermore, it should be noted that Cardini observed the absence of the dental crown in 1942, which indicates that the damage is not related to excavation. Based on what we observed, the absence of the crown does not appear to be due to dento-alveolar pathological conditions such as caries, but rather the result of a tooth trauma at the level of the cervix. The gloss observable on the root's surfaces do not associate with masticatory or extra-masticatory wear, but instead with the presence of consolidants. The absence of wear thus suggests that the dental trauma likely occurred around the time of death.



**Fig. 5** – The surviving mandibular and dental elements. **A:** Right portion of the mandible, showing the buccal view, the occlusal view of the molars, and a lingual view of the fractured area; scale in cm. **B:** Surviving anterior dentition, in labial, occlusal, and lingual views; scale in cm. **C:** Surviving fragment of the left mandibular ramus (scale in cm), and in detail the fractured area (scale in mm).

*New evidence: grooves and puncture marks*

Hundreds of small and microscopic grooves, scratches, and punctures dot the cranium of AC 1 which, like the rest of the skeleton, is covered with a layer of ochre and various types of glues,

plasters, and hardened soil. Most of these traces can be attributed to taphonomic processes, while others are probably due to handling after initial restoration. In particular, a set of linear marks in the frontal and parietal bones could be mistaken

for cutmarks, but closer observation showed that both the bone and the plaster were scratched by the same marks, confirming its recent origin (Figs. SI11-12). We hypothesize that the damage occurred shortly after the restoration, probably due to the use of a craniometer (e.g. White and Toth 1989).

However, one linear mark on the left parietal, about 10 mm long and 1.8-2.2 mm wide, with a U-shaped section and depth of about 1 mm (Figs. 6 and SI13), appears compatible with a perimortem lesion. Plastic deformation of the cortical surface, with the formation of a rounded edge, is visible in the inferior margin of the mark (with respect to the anatomy of the cranium; Fig. 6b, lower arrow, and Fig. SI13). No trace of bone remodeling can be discerned.

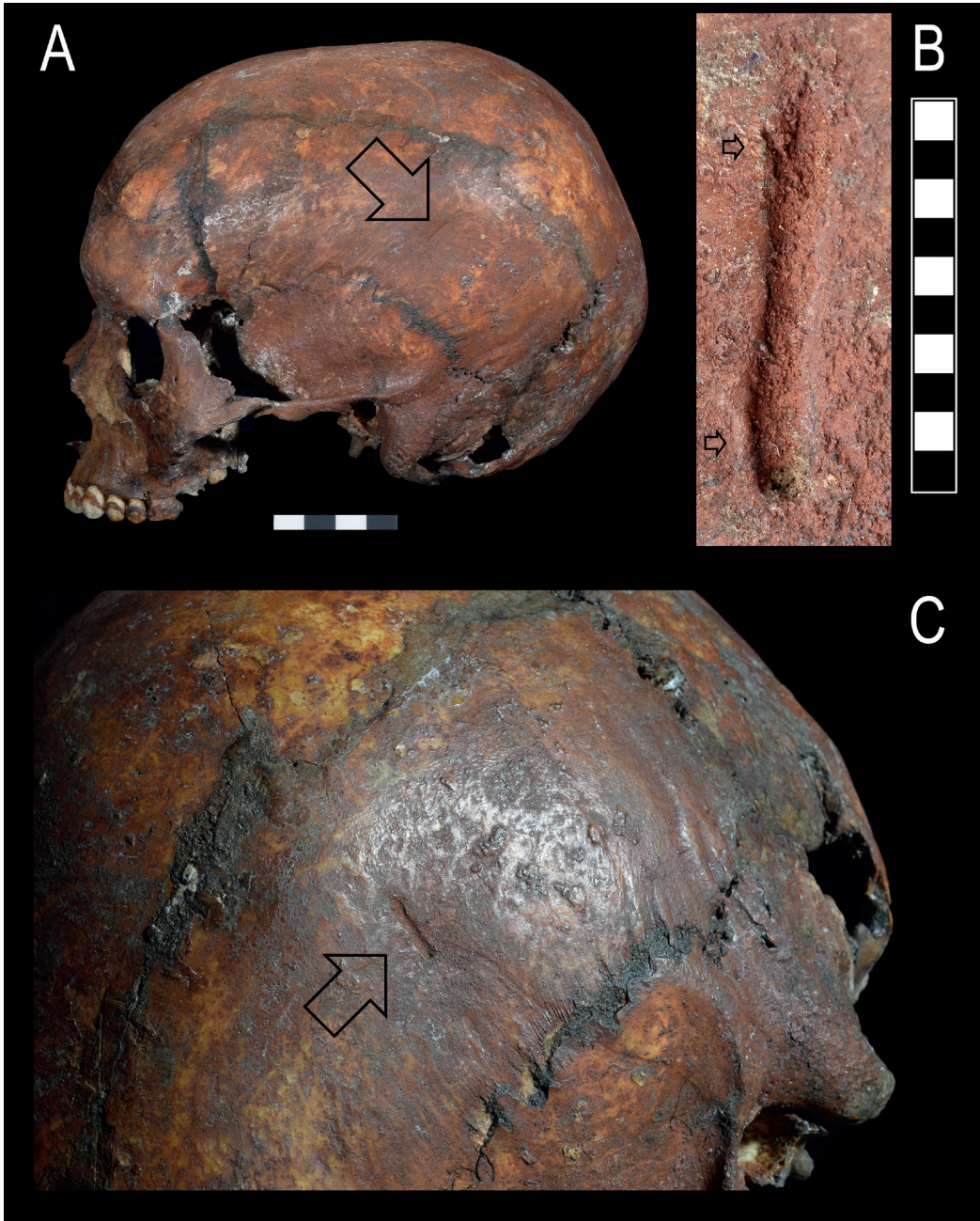
The shape of the groove is not compatible with the action of knapped lithic instruments, as it lacks the sharp V-shaped cross-section and the characteristic slicing of the cortical surface into planar facets along one or both edges, which are typically produced by stone tools (Greenfield 1999; e.g. Sparacello et al. 2025). Insect and root activity is also unlikely, given that the mark is a single, relatively large, regular, linear groove and lacks the multiple irregular etchings, branching patterns, and surface erosion commonly associated with such biogenic agents (Behrensmeyer 1978; Kaiser 2000; Backwell et al. 2012; Fernández-Jalvo and Andrews 2016). Abrasion by dragging can be excluded as well, due to the constant width and U-shaped morphology of the lesion, and to the fact that Arene Candide is an undisturbed primary deposition. Scavenging by a carnivore can be also excluded given that the mark was found below the undisturbed covering of shells that formed a sort of headdress in the *Principe* (Figs. 2 and SI3).

Still, carnivore activity remains the most likely explanation. It can be hypothesized that the mark represents a score (i.e., a groove that does not affect the cancellous bone; Sala et al. 2014) produced either by the cusp of a tooth or by a claw swipe. Differentiating between these possibilities is challenging, as both interpretations present issues due to the isolated nature of the mark and

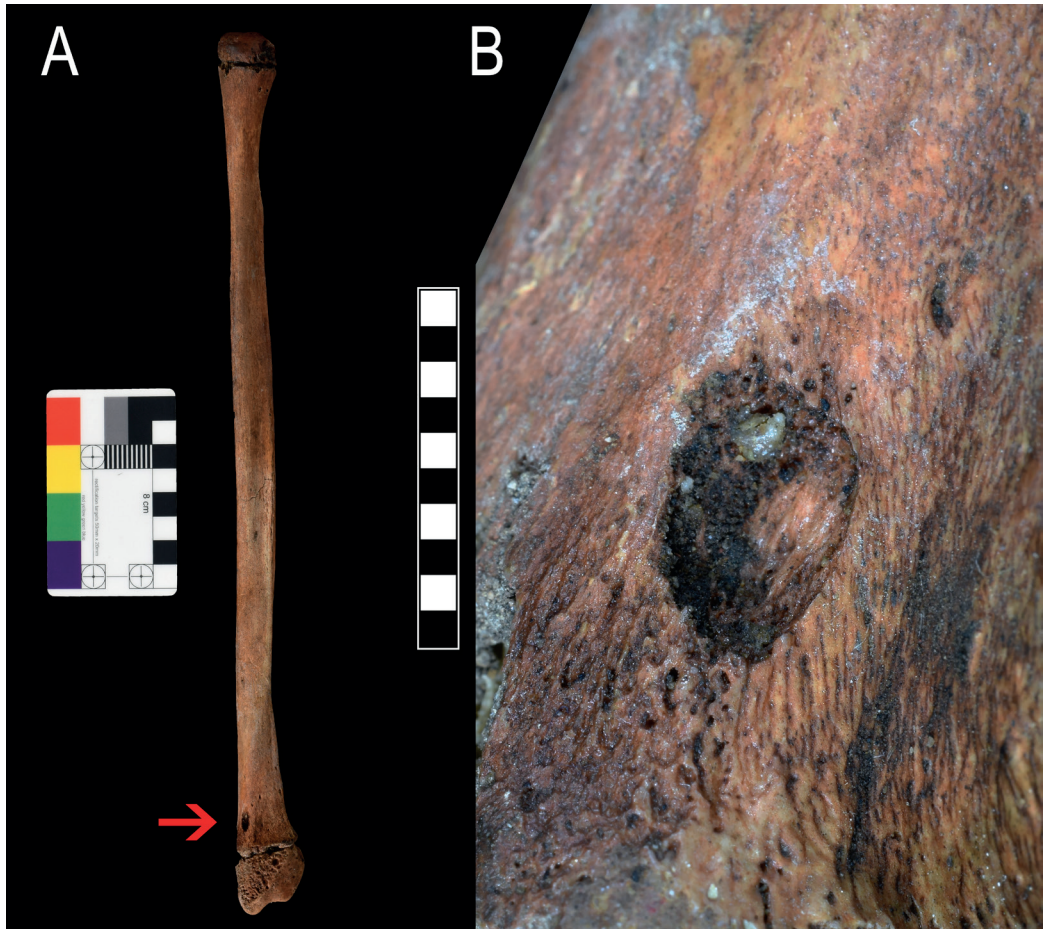
the impossibility of cleaning and analyzing its ochre-filled bottom to determine whether striations are present. The breadth of the groove falls within the range of scores measured on thin cortical bone attributed to carnivore tooth marks, including bears, in the hominin assemblage from Sima de los Huesos (Sala et al. 2014; see also Sala and Arsuaga 2018, 2024). However, the dimensions of the scores present significant overlap, making it impossible to use size as a criterion for taxonomic identification (Selvaggio and Wilder 2001; Domínguez-Rodrigo and Piqueras 2003; Sala et al. 2014). A claw swipe is another tentative explanation (e.g. Sala et al. 2024), as the groove is isolated and cannot be compared with additional data beyond its width. The presence of a frayed or bifurcated termination at one end of the score (the upper end with respect to the anatomy of the cranium; Figure 6b, upper arrow, and Figure SI13) appears more compatible with a claw mark, as keratin claws are more prone to flexing, splintering, or catching on the bone surface, producing irregular or split traces, whereas scores caused by dental cusps are expected to leave more regular and sharply defined terminations. However, albeit carnivore activity is the most likely interpretation, the identification of the groove as a claw swipe remains highly tentative and cannot be definitely confirmed without further microscopic analysis.

The mark described above crosses another longer, shallower, and sinuous groove that runs from the mid-parietal to the beginning of the zygomatic process in the left temporal bone (Fig. 6c). This is the impression of the parietal branch of the superficial temporal artery and vein, a relatively common anatomical trait. Similar intersecting grooves are present in the right portion of the frontal, where one could expect to see uncommonly large non-metric traits in the form of frontal grooves and foramina (Fig. SI11, red arrow; Mann et al. 2016, p.16; Sparacello et al. 2023a).

Away from the cranium, in the lateral aspect of the distal right fibula, a teardrop-shape depression can be observed (7.8 mm length, 5.2 mm maximum width, ca. 2 mm maximum depth),



**Fig. 6** – The linear groove in the left parietal. **A:** Left view of the cranium; the arrow indicates the position of the groove; scale in cm. **B:** magnification of the groove; scale in mm. The top arrow indicates the frayed appearance of one end of the groove, while the bottom arrow indicates the margin that show a plastic rounding of the cortical bone. **C:** Another view of the groove, indicated by the arrow, showing the intersecting vascular impression.



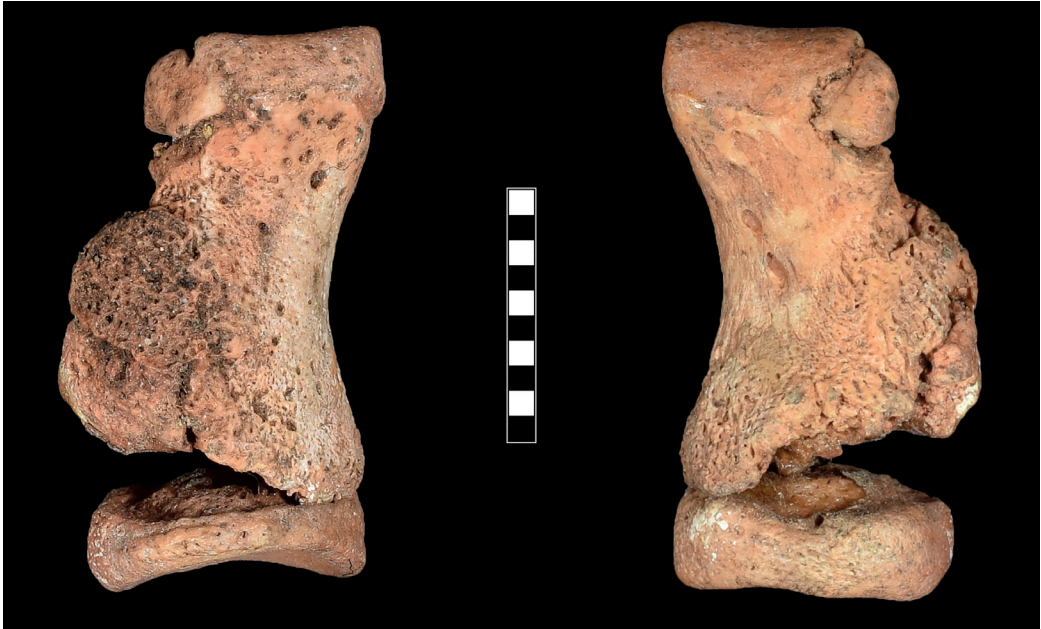**Fig. 7** – A: The location of the puncture mark in the right fibula; scale in cm. B: Magnification of the puncture mark; scale in mm.

with depressed cortical bone covering its bottom and walls (Fig. 7). Similar lesions can be caused by taphonomic processes, such as small pebbles pressed against the cortical bone, more commonly during trampling events in coarse sediments. However, the burial appears undisturbed, and no other sign of trampling is present in the skeleton (such as striae and drag marks). Furthermore, under optical magnification it is possible to observe the initial rounding of the exposed trabecular bone due to the inflammatory process (Fig. 7). This perimortem lesion does not show other signs of healing and appears to have

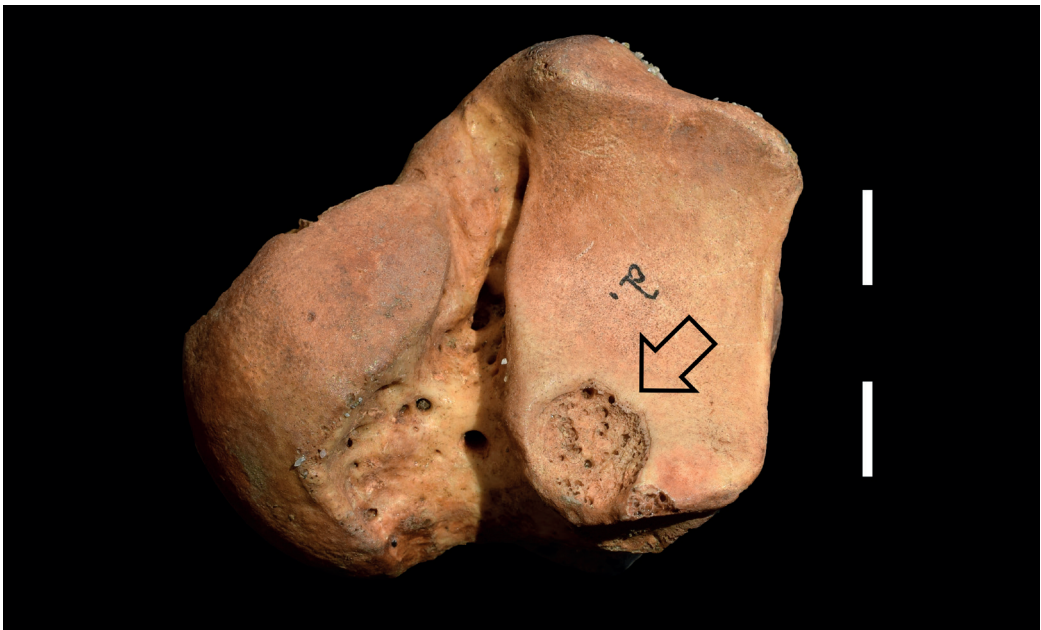been created by vertical compression by a cone-shaped object, such as a tooth (cf. Fernández-Jalvo and Andrews 2016).

#### *Other previously undocumented lesions*

The left fifth proximal pedal phalanx presents a healing fracture, with the formation of a relatively large hard callus (Fig. 8). Rather than a complete shaft fracture, it appears to have been a crushing fracture that involved the lateral and proximal portion of the phalanx diaphysis, while the proximal epiphysis remained undamaged. Conversely, the lateral aspect of the distal



**Fig. 8** – Proximal fifth left pedal phalanx, evidencing the traumatic lesions and callus formation; scale in mm. Left, dorsal view; right, plantar view.



**Fig. 9** – Inferior view of the right talus. The arrow indicates the position of the lesion compatible with osteochondritis dissecans. Scale in cm.

epiphysis is damaged. Phalangeal fractures are quite common in the literature and are usually due to “stubbing” the toe against an immovable object; treatment usually consists in strapping the affected toe to the adjacent one (e.g. Waters et al. 2020). Based on the appearance of the bony callus, the healing process was in the “consolidation” phase (e.g. Lovell 1997), i.e. the injury occurred from a few weeks to a few months before death.

The right talar anteromedial calcaneal articular surface shows a round (diameter ca. 10 mm) defect of the cortical bone that exposes heavily remodeled cancellous bone (Fig. 9). The appearance is consistent with osteochondritis dissecans, a lesion of the cartilage and underlying subchondral bone, that is usually due to trauma and repetitive, excessive compression of the joint, and occurs more frequently in adolescents and young adults, especially males (Resnick 1995, p.3589; Ortner 2003; Yanagisawa et al. 2021). After the lesion occurs, a necrotic free body of cartilage and bone is formed, which plugs the lesion or becomes loose into the joint cavity, causing discomfort and pain. Most of these lesions occur in the knee joint, while the subtalar joint is rarely affected (Elias et al. 2007; Yanagisawa et al. 2021).


## Discussion

The examination of the lesions visible in the cranium and postcranium of the *Principe* of Arene Candide suggests that this young forager suffered from a massive perimortem shoulder and maxillofacial trauma, which resulted in the loss of part of the left mandible, clavicle and humeral head, and probably in fractures to the cervical spine, and to the left portion of the frontal and occipital bones. We can assume that other minor perimortem lesions – such as the linear markings in the left parietal, dental avulsion, and the bite mark in the fibula – occurred in the same circumstances. Several other small damages and marks can be observed throughout the skeleton but are less clear and may have been significantly obscured by the restoration processes. Overall,

when considering the nature and pattern of the most obvious lesions, they depict a realistic scenario of fatal mauling by a large carnivore. Other interpretations – such as a fall from height or interpersonal violence – are either lacking or appear less parsimonious. In fact, the *Principe* does not display other lesions that would be expected in a fall, such as forearm and leg fractures (e.g. Sparacello et al. 2023a,b), and neither falls nor interpersonal violence would explain the marks attributed to carnivore activity and the apparent loss of bone tissue in the shoulder and mandible.

Considering the fauna present in the Italian peninsula in the Late Pleistocene (Gliozzi et al. 1997; Petronio et al. 2011), and especially the faunal findings at Arene Candide (Cassoli and Tagliacozzo 1994), the *Principe* may have been attacked by a brown bear (*Ursus arctos*), a cave bear (*Ursus spelaeus*), a leopard (*Panthera pardus*) or a cave lion (*Panthera spelaea*). In layer P9, which corresponds to the time in which the *Principe* lived, skeletal elements belonging to both cave bears and leopards were found (Cassoli and Tagliacozzo 1994: 137; Alhaique 1994, p.265). However, a secure taxonomic identification of the attacker based on the measurements and characteristics of the grooves and punctures found on the *Principe* is impossible at this stage, given their isolated nature and the overlap in measurements reported in studies of carnivore activity on bone (e.g. Selvaggio and Wilder 2001; Sala et al. 2014). The dimensions of the pit recorded on the right fibula of the *Principe* are comparable with cave bear predation marks from Bäsura Cave (Toirano, 15 km west of Arene Candide Cave; width between 5.1-7 mm; Zunino et al. 2022), with those attributed to modern brown bears *Ursus arctos* (Sala and Arsuaga 2013), and with *Ursus deningeri* from Sima de los Huesos (Sala et al. 2014; see also Sala and Arsuaga 2018). However, they also overlap with the ones left by leopards and other big cats (Selvaggio and Wilder 2001; Domínguez-Rodrigo and Piqueras 2003).

The groove observed in the left parietal of the *Principe*, which we tentatively attributed to a claw



**Fig. 10** – Scratch marks attributed to claws of *Ursus spelaeus* on the wall of the Bàsura Cave (Toirano, Liguria).

swipe, bears a striking resemblance with some of the shorter grooves in Cranium 5 from Sima de los Huesos, which presents several longer parallel grooves, some of which even conflated (Sala et al. 2024). These were attributed to bear claw marks, but in that case the interpretation could take into account, in addition to the width of the grooves, the distance between them and the comparison with bear marks found in the cave (Sala et al. 2024). In the case of the *Principe*, the taxonomical attribution is more challenging; still, the lesion does display similarities with claw marks left by *Ursus spelaeus* in the walls of Bàsura Cave (Fig. 9). Big cat claw marks appear to leave more superficial traces, although more experimental research is needed (Rothschild et al. 2013). The attribution of the lesion to a claw swipe, and a more informed taxonomic attribution, could be improved only through microscopic analysis using a confocal microscope; however, this is

currently not possible due to preservation concerns, as it would require cleaning the remains of their ochre layer and taking silicone impressions.

Although microscopic analysis is not available, the overall pattern of traumatic lesions could add to the plausibility of the bear attack hypothesis. The clinical literature provides abundant evidence of traumatic lesions due to a bear attack, several of which are observed in the *Principe*. Different species of bear appear to display different patterns of initial attack, the brown bear reportedly using the “face bite” more frequently (e.g. Tough and Butt 1993), while the paw smack to the face and torso is more commonly reported for Asiatic species (e.g. Oshima et al. 2018; Patil et al. 2019). However, both modalities of attack result primarily in fractures to the face and cranium, occurring both in fatal and non-fatal negative encounters (Tough and Butt 1993; Dhar et al. 2008; Rasool et al. 2010;

Atreya et al. 2016; Ghezta et al. 2019; Patil et al. 2019). Fractures to the mandible are often reported (Ghezta et al. 2019; Vashistha et al. 2019; Yang et al. 2022), including – importantly – cases of partial bone loss (Govila et al. 1989). Deep cranial scarring due to claws and teeth are common (e.g. Oshima et al. 2018; Yilzmar et al. 2021), and both claws and teeth can result in penetrating head injuries (e.g. Hayashi et al. 2003; Ryan et al. 2014). In addition to cranial trauma, fractures to the shoulder, chest, and the upper limb similar to the ones observed in the *Principe* are commonly reported in victims of bear attacks (e.g. Dhar et al. 2008; Ghezta et al. 2009; Gudmannsson and Berge 2019), as well as bite marks at the extremities (Oshima et al. 2018). Additionally, the reason for the attack can be defense or predation (e.g. Tough and Butt 1993; Floyd 1999; Oshima et al. 2018), with the latter presenting a higher frequency of postmortem bites (as determined from hemorrhagic traces in soft tissue; Oshima et al. 2018). Although similar injuries are reported in the case of tiger and leopard attacks, in these cases there is a greater emphasis on neck transfixing injuries rather than cranial and thoracic trauma (e.g. Hejna 2010; Pathak et al. 2013; Bhandari et al. 2019; Agarwal et al. 2021). This makes the general pattern of trauma in Arene Candide 1 more compatible with a bear attack. However, given that different carnivores can result in similar patterns of trauma, especially when examining dry bone (Arilla et al. 2014; Sala and Arsuaga 2018), it is currently difficult to further reconstruct the circumstances around the death of the young *Principe* beyond a “large carnivore attack, probably a bear”.

At some point before death, the *Principe* also suffered from traumatic lesions in the foot (fractured fifth toe) and ankle (osteochondritis dissecans of the talus). A common complication of a fractured little toe is persistent pain and deambulatory difficulties (Hatch et al. 2003), while osteochondritis dissecans to the subtalar joint can produce a sharp and impairing pain when the subject attempts to sprint (e.g. Yanagisawa et al. 2021). It would be highly speculative to

infer that these injuries played a direct role in the *Principe*'s death. However, it has been noted that evidence of long-term survival after lower limb injuries is rare in prehistoric foragers (Berger and Trinkaus 1995; Trinkaus 2011, 2012; Cowgill et al. 2015; Sparacello et al. 2023b; but see Holt et al. 2002) compared to healed upper limb fractures (Trinkaus 2005, 2015; Chevalier 2019; Sparacello et al. 2023a), suggesting that highly-functional lower limbs were crucial for these highly mobile foragers.

After the attack, the young forager survived for some time before eventually succumbing to his injuries. Estimating the timing of survival from skeletonized remains is notoriously difficult, even in a forensic context, given the numerous factors affecting bone healing (especially age; Boyd 2018). In Arene Candide 1, the initial rounding of trabeculae and cortical bone is discernible, new bone formation is visible using macrophotography but was limited to the intertrabecular space, while subperiosteal new bone formation (SPNBF) had not begun. In adults, macroscopic traces of healing have been reported after at least one week after injury (dry bone; Sauer 1998) or not earlier than 19 days (dry bone; Cattaneo et al. 2010); absorption of cortical bone adjacent to the lesion commences 4-7 days after injury (De Boer et al. 2015). Healing in juveniles has been estimated to be at least twice faster than in adults (review in Boyd 2018); osseous repair in young infants may be visible macroscopically as early as 4 days since injury (results from dry bone; Love et al. 2011), but in other infants, only rounding of the fracture margin was observed in the same time span (results from dry bone; Boyd 2018). In juveniles, SPNBF has been reported as early as 4-10 (radiographic data; O'Connor and Cohen 1987, 1998) or 7-10 days since injury (radiographic data; Merten et al. 1994) but features visible on dry bone are often radiographically not visible (review in Mays 2018). However, most literature focuses on cortical healing and the formation of soft and hard callus; the rate of healing in subadult trabecular bone has not been estimated to date using forensic cases (e.g. Love et al. 2011, p.87) but has been theorized

to be faster than cortical healing (Ogden 1990). This was confirmed in recent analyses on human adult radial biopsies (Aspenberg and Sandberg 2013) and murine models (Bernhardsson et al. 2015), the latter showing that the volume of a cylinder with a diameter of 1.1 mm and length of 2.5 mm were already completely filled with bone by one week since injury. No earlier measuring points were taken, but we can expect that some bone deposition occurred after a few days (see also Aspenberg and Sandberg 2013). Intertrabecular bone formation, although limited to a couple of millimeters from damaged cancellous bone, has been estimated to be about three times faster than endochondral healing (Sandberg and Aspenberg 2016). Based on this, we estimate that the *Principe* may have survived 48, possibly 72 hours after his injuries. However, it must be emphasized that, in absence of studies on the variability and specifically on the timing of intertrabecular ossification in adolescents, this estimate is tentative. Future experimental and clinical studies on intertrabecular ossification, as well as the application of more advanced histological methods on the *Principe* (De Boer et al. 2015; Cappella and Cattaneo 2019; Schwab et al. 2023; Winter-Buchwalder et al. 2024) may further refine our estimate.

Given the extent of the bone injuries, it is surprising that this adolescent forager survived even for this brief time. The bite or paw smack that fractured the mandible and the clavicle, likely the cranial vault, and possibly the cervical vertebrae, must have fortuitously spared major blood vessels (jugular vein, carotid and subclavian arteries) which would have caused a rapid death through hemorrhage and would have been difficult to treat without modern medicine. Given the estimated survival time, death may have occurred due to secondary brain injury, internal hemorrhage, or multiple organ failure, as is often the case within the first days post severe cranial trauma (Sobrinho and Shafi 2013). It has been suggested that the yellow ochre found in the burial around the wounded area may have been a cauterizing agent, probably because ochre was used for this purpose in ancient societies, amongst many other medical

uses (e.g. Metwaly et al. 2021). However, beyond the successful prevention of immediate exsanguination, it is difficult to infer the treatments that the group – which was probably present or close at the time of attack – may have attempted in an effort to save the life of the *Principe* (e.g. Sparacello et al. 2023a).

What can be observed is that the *Principe*'s group invested significant time and resources in his funerary treatment. The inclusion in the burial of ornaments composed of hundreds of pierced shells, carved *bâtons percés*, and objects made of exotic materials (e.g. mammoth ivory pendants, and the *stampien zoné* flint from the French Vaucluse region used for the large blade; Molari 1994; Rigaud 2001; Onoratini et al. 2011) closely parallels what has been seen in the Sunghir burials which rank among the richest ever found for the Gravettian (Trinkaus and Buzhilova 2012, 2018). The flint blade, in particular, has been considered a “prestige” item, and was found in several elaborate burials from the Grimaldi Caves at the Balzi Rossi (Onoratini et al. 2011).

Given the exceptional nature of the burial, a princely nickname was attributed in modern times to the inhumed adolescent, a label that reflects early preconceptions and simplistic explanations linking the richness of Upper Paleolithic graves to the individual's social status in life, with the “Prince” presumed to be a prominent figure in a proto-hierarchical society (Carr 1995; cf. Binford 1971; Saxe 1970). More recent research, however, strongly refutes the idea that formal burials during the Mid-Late Upper Paleolithic were based on social standing defined by vertical or hereditary societal structures. Instead, the funerary record of the Gravettian and Epigravettian periods shows a striking overrepresentation of individuals who suffered traumatic deaths or display congenital pathological conditions (as reviewed by Trinkaus 2018). This pattern has led to the hypothesis that formal burial was afforded based on the necessity to ritually contain and sanction these “exceptional events and exceptional people” (e.g. Formicola 2007; Pettitt 2010; Trinkaus and Buzhilova 2012; Sparacello et al. 2018, 2021).

Although tentative, the scenario that could be depicted by this study aligns well with this theory: the violent death involving disfiguring loss of tissue (e.g. Ghezta et al. 2018; Rasool et al. 2010), likely caused by an animal typically regarded as prey, combined with the young age (and presumably immature appearance, based on the puberty stage he had reached; Lewis et al. 2024), and prolonged agony endured for days, may be considered an “exceptional event” requiring ritual sanctioning. While it is not possible to speculate on the meaning of the apparent “syntax” expressed by the placement of items and bodies in Gravettian burials – such as the blade in the case of the *Principe* (see also the position of the individuals in the Dolní Věstonice and Barma Grande triple burials; Formicola 1990, 2007; Formicola et al. 2001) – his burial undeniably adds to the evidence of extremely rare occurrences “buried” in the Gravettian funerary record. This further supports the idea that the skeletal corpus from this period is composed of highly selected individuals.

## Conclusions

About eighty years after the discovery, the reexamination of the skeletal remains of the Principe from Arene Candide Cave yielded new and surprising results. Our study confirmed the perimortem nature of the mandibular and shoulder injuries, which were first noted in the 1940s, and uncovered additional potential fractures in the cranium, the dentition, and the cervical spine, which are consistent with a massive thoracic and craniofacial trauma. Further evidence of perimortem trauma uncovered in this study, such as a linear groove in the cranium and a puncture mark in the fibula, supports the hypothesis of carnivore involvement. The overall traumatic pattern observed in this individual resembles injuries typically documented in modern motor vehicle accidents, but in the prehistoric context examined here is more plausibly attributed to a large animal mauling, likely by a bear. Although additional analyses – such as computed tomography and

confocal microscopy – would be required to refine the taxonomic identification of the attacker, these are not feasible at this stage. Finally, the identification of antemortem foot lesions – including a fracture of the fifth toe and talar osteochondritis dissecans – supports the hypothesis that prehistoric foragers experienced limited survival following lower limb injuries.

The *Principe* was left with numerous fractures and disfiguring loss of bone and tissue. Previous observations suggested that death was not immediate, but did not discuss the evidence for this claim. Our analysis highlighted the beginning of the process of intertrabecular ossification, while subperiosteal new bone formation and callus formation had not commenced. This allows for a rough estimate of survival time, which probably consisted in a couple of days, before eventual death.

The rich formal burial accorded to the *Principe* may reflect a need to ritually sanction an exceptionally negative event. This interpretation aligns with numerous studies noting the improbably high prevalence of pathologies and trauma in the Late Upper Paleolithic funerary record (especially Gravettian and Epigravettian), which likely represents a highly selected subset of individuals.

## Acknowledgements

*Vitale Sparacello was funded by the Fondazione di Sardegna 2022 project TRA.DIS.CO. (CUP F73C23001620007). Irene Dori was funded by DM247 2022 MUR Italy Investment 1.2 “Funding projects presented by young researchers”, grant number MSCA\_0000035, project “IEPDA”. The authors would like to thank Erica Ceccarelli for assistance during data collection. We are grateful to Vincenzo Formicola, Brigitte Holt, Giuseppe “Cisque” Vicino, and Maria Tagliafico for their input and continuous support. Thanks to Daniele Arobba from the Museo Archeologico del Finale, and to Marta Conventi and Stefano Costa from the Soprintendenza Archeologia Belle Arti e Paesaggio per la Liguria, Genova, Italy. Thanks to Matteo Romandini for his suggestions and to Giorgio Lai for photo post-processing.*

## Data Availability Statement

All data are provided in the manuscript and Supplementary Information. Three-dimensional surface models of selected skeletal elements are available in the repository MorphoSource (<https://www.morpho-source.org/projects/00000C206>).

## Author Contribution

VSS designed the study. VSS, ID, NR conducted the paleopathological assessment. MZ, NR, and VSS analyzed the taphonomic signs. ID conducted the dental evaluation. ES, FN, JRS, CGM, PG and IM contributed to the archaeological contextualization. VSS wrote the first draft, which was discussed and integrated by all the authors.

## References

- Agarwal P, Dhiman A, Rashid N, et al (2021) Head and neck injuries after leopard attack: presentation and management. *Chin J Traumatol* 24:389-393. <https://doi.org/10.1016/j.cjtee.2021.01.003>
- Alciati G, Pesce Delfino V, Vacca E (2005) Catalogue of Italian fossil human remains from the Palaeolithic to the Mesolithic. *J Anthropol Sci Suppl* 84:1-184.
- Alhaique F (1994) Taphonomic analysis of the faunal remains from the "P" and "M" layers of the Arene Candide (Savona, Italy). *Quat Nova* 4:263-295.
- Arilla M, Rosell J, Blasco R, et al (2014) The "bear" essentials: actualistic research on *Ursus arctos arctos* in the Spanish Pyrenees and its implications for paleontology and archaeology. *PloS One* 9:e102457. <https://doi.org/10.1371/journal.pone.0102457>
- Arrighi S, Borgia V (2008) Gravettian burial rites: functional analysis of the lithic grave goods. In: Anati E (ed) *Prehistoric Art and Ideology, Proceedings XV Congress U.I.S.P.P., Lisbon 2006, BAR Int Ser 1872:13-20*.
- Aspenberg P, Sandberg O (2013) Distal radial fractures heal by direct woven bone formation. *Acta Orthop* 84:297-300. <https://doi.org/10.3109/17453674.2013.792769>
- Atreya A, Kanchan T, Nepal S, et al (2016) Bear-inflicted injuries – a report from Nepal. *Med Leg J* 84:94-96. <https://doi.org/10.1177/0025817216630479>
- Backwell LR, Parkinson AH, Roberts EM, et al (2012) Criteria for identifying bone modification by termites in the fossil record. *Palaeogeogr Palaeoclimatol Palaeoecol* 337-338:72-87. <https://doi.org/10.1016/j.palaeo.2012.03.032>
- Baliga SD, Urolagin SB, Balihallimath LJ (2012) Bear attack injury to maxillofacial region: report of 3 cases and review of management. *J Oral Maxillofac Sur Med Pathol* 24:198-203. <https://doi.org/10.1016/j.ajoms.2011.08.005>
- Behrensmeyer AK (1978) Taphonomic and ecologic information from bone weathering. *Paleobiology* 4:150-162. <https://doi.org/10.1017/S0094837300005820>
- Berger TD (2006) Brief communication: predatory bird damage to the Taung type-skull of *Australopithecus africanus* Dart 1925. *Am J Phys Anthropol* 131:166-168. <https://doi.org/10.1002/ajpa.20415>
- Berger TD, Trinkaus E (1995) Patterns of trauma among the Neandertals. *J Archaeol Sci* 22:841-852. [https://doi.org/10.1016/0305-4403\(95\)90013-6](https://doi.org/10.1016/0305-4403(95)90013-6)
- Beier J, Anthes N, Wahl J, et al (2018a) Prevalence of cranial trauma in Eurasian Upper Paleolithic humans. *Am J Phys Anthropol* 174:268-284. <https://doi.org/10.1002/ajpa.24163>
- Beier J, Anthes N, Wahl J, et al (2018b) Similar cranial trauma prevalence among Neanderthals and Upper Paleolithic modern humans. *Nature* 563:686-690. <https://doi.org/10.1038/s41586-018-0696-8>
- Belcastro MG, Condemi S, Mariotti V (2010) Funerary practices of the Iberomaurusian population of Taforalt (Tafoughalt, Morocco, 11-12,000BP): the case of Grave XII. *J Hum Evol* 58:522-532. <https://doi.org/10.1016/j.jhevol.2010.03.011>
- Bhandari K, Haque IB, Khanal B, et al (2019) Maxillofacial injuries in bear, tiger, and jackal attacks. *Craniofacial Trauma Reconstr* 3:e1-e5. <https://doi.org/10.1055/s-0039-1678671>

- Bietti A, Molari C (1994) The Upper Pleistocene deposit of the Arene Candide cave (Savona, Italy): general introduction and stratigraphy. *Quat Nova* 4:9-27.
- Binford LR (1971) Mortuary Practices: their study and their potential. *Am Antiq* 25:6-29. <https://doi.org/10.1017/S0081130000002525>
- Binford LR (1981) *Bones: Ancient Men and Modern Myths*, Academic Press, London.
- Brain CK (1981) *The Hunters or the Hunted?* Chicago University Press, Chicago.
- Cardini L (1942) Nuovi documenti sull'antichità dell'uomo in Italia: reperto umano del Paleolitico superiore nella Grotta delle Arene Candide. *Razza e Civiltà* 3:5-25.
- Cappella A, Cattaneo C (2019) Exiting the limbo of perimortem trauma: a brief review of microscopic markers of hemorrhaging and early healing signs in bone. *Forensic Sci Int* 302:109856. <https://doi.org/10.1016/j.forsciint.2019.06.014>
- Carr C (1995) Mortuary practices: their social, philosophical-religious, circumstantial, and physical determinants. *J Archaeol Method Theory* 2:105-200. <https://doi.org/10.1007/BF02228990>
- Cassoli PF, Tagliacozzo A (1994) I macromammiferi dei livelli tardopleistocenici delle Arene Candide (Savona, Italia): considerazioni paleontologiche e archeozoologiche. *Quat Nova* 4:101-262.
- Cattaneo C, Cappella A (2017) Distinguishing between peri- and post-mortem trauma on bone. In: Schotsmans EMJ, Márquez-Grant N, Forbes SI (eds) *Taphonomy of human remains: Forensic analysis of the dead and the depositional environment*, First ed., John Wiley & Sons Ltd., New York, p. 352-368. <https://doi.org/10.1002/9781118953358.ch23>
- Chauvière F-X (ed) (2008). *La grotte du Bichon : Un site préhistorique des montagnes neuchâtelaises* (Archéologie neuchâtelaise, No. 42), Office et musée cantonal d'archéologie de Neuchâtel. ISBN 978-2-940347-41-4.
- Chen WT, Han da C, Zhang PX, et al (2015) A special healing pattern in stable metaphyseal fractures. *Acta Orthop* 86:238-42. <https://doi.org/10.3109/17453674.2014.1003127>
- Chevalier T (2019) Trauma in the upper limb of an Upper Paleolithic female from Cavignone cave (Liguria, Italy): etiology and after-effects in bone biomechanical properties. *Int J Paleopath* 24:94e107. <https://doi.org/10.1016/j.ijpp.2018.10.001>
- Coqueugniot H, Dutailly B, Dutour O (2020) The third dimension in palaeopathology: How can three-dimensional imaging by computed tomography bring an added value to retrospective diagnosis? *Int J Osteoarchaeol* 30:538-550. <https://doi.org/10.1002/oa.2881550>
- Cowgill LW (2008) *The ontogeny of recent and Late Pleistocene human postcranial robusticity*, Ph.D. Dissertation, Washington University in St Louis.
- Cowgill LW, Mednikova MB, Buzhilova AP, et al (2015) The Sungghir 3 Upper Paleolithic juvenile: pathology versus persistence in the Paleolithic. *Int J Osteoarchaeol* 25:176e187. <https://doi.org/10.1002/oa.2273>
- Daujeard C, Geraads D, Gallotti R, et al (2016) Pleistocene hominins as a resource for carnivores: a c. 500,000-year-old human femur bearing tooth-marks in North Africa (Thomas Quarry I, Morocco). *PLoS One* 11:e0152284. <https://doi.org/10.1371/journal.pone.0152284>
- Dhar SA, Butt MF, Farooq M, et al (2008) Pattern of orthopaedic injuries in bear attacks: report from a tertiary care centre in Kashmir. *Injury* 39:249-255. <https://doi.org/10.1016/j.injury.2007.07.028>
- Diamond TH, Clark WA, Kumar SV (2007) Histomorphometric analysis of fracture healing cascade in acute osteoporotic vertebral body fractures. *Bone* 40:775-80. <https://doi.org/10.1016/j.bone.2006.10.009>
- El-Faramawy A, El-Menyar A, Zarour A, et al (2012) Presentation and outcome of traumatic spinal fractures. *J Emerg Trauma Shock* 5:316-20. <https://doi.org/10.4103/0974-2700.102381>
- Elias I, Zoga AC, Morrison WB, et al (2007) Osteochondral lesions of the talus: localization and morphologic data from 424 patients using a novel anatomical grid scheme. *Foot Ankle Int* 28:154-61. <https://doi.org/10.3113/fai.2007.0154>

- Estabrook VH, Frayer DW (2014) Trauma in the Krapina Neandertals: violence in the Middle Palaeolithic? In: Knüsel CJ, Smith MJ (eds) *The Routledge handbook of the bioarchaeology of human conflict*, Routledge, London, p. 67-89. <https://doi.org/10.4324/9781315883366>
- Fernández-Jalvo Y, Andrews P (2016) *Atlas of taphonomic identifications. 1001+ images of fossil and recent mammal bone modification*, Springer, New York. <https://doi.org/10.1007/978-94-017-7432-1>
- Formicola V (1990) The triplex burial of Barma Grande (Grimaldi, Italy). *Homo* 39:130-143.
- Formicola V (2007) From the Sunghir children to the Romito dwarf: aspects of the Upper Paleolithic funerary landscape. *Curr Anthropol* 48:446-453. <https://doi.org/10.1086/517592>
- Formicola V, Pontrandolfi A, Svoboda J (2001) The Upper Paleolithic triple burial of Dolní Věstonice: pathology and funerary behavior. *Am J Phys Anthropol* 115:372-379. <https://doi.org/10.1002/ajpa.1093>
- Galloway A, Wedel VL (2014) Bones of the skull, the dentition, and osseous structures of the throat. In: Wedel VL, Galloway A (eds) *Broken Bones. Anthropological analysis of blunt force trauma*, Charles C Thomas, Springfield, p. 133-160.
- Ghezta NK, Bhardwaj Y, Ram R, et al (2019) Incidence pattern of bear-inflicted injuries to the maxillofacial region – soft and hard tissue injuries, their management, and sequelae. *J Oral Maxillofac Surg* 77:1043.e1-1043.e15. <https://doi.org/10.1016/j.joms.2018.12.029>
- Gliozzi E, Abbazzi L, Ambrosetti PG, et al (1997) Biochronology of selected mammals, molluscs and ostracods from the Middle Pliocene to the Late Pleistocene in Italy. The state of the art. *Riv Ital Paleontol S* 103: 369-388. <http://doi.org/10.13130/2039-4942/5299>
- Govila A, Rao GSS, James JH (1989) Primary reconstruction of a major loss of lower jaw by an animal bite using a “rib sandwich” pectoralis major island flap. *Br J Plast Surg* 42:101-103. [https://doi.org/10.1016/s0007-1226\(89\)90124-0](https://doi.org/10.1016/s0007-1226(89)90124-0)
- Grauer AL (ed) (2023) *The Routledge handbook of paleopathology*, Routledge, London.
- Greenfield HJ (1999) The origins of metallurgy: distinguishing stone from metal cut-marks on bones from archaeological sites. *J Archaeol Sci* 26:797-808. <http://doi.org/10.1006/jasc.1998.0348>
- Gudmannsson Þ, Berge J (2019) The forensic pathology of fatal attacks by the large mammals inhabiting the Nordic wilderness – a literature review. *J Forensic Sci* 64:976-981. <https://doi.org/10.1111/1556-4029.13994>
- Gurdjian ES, Webster JE, Lissner HR (1953) Observation on prediction of fracture site. *Radiology* 60:226-235.
- Gurdjian ES (1975) *Impact head injury, mechanistic, clinical and preventive correlations*, Charles C Thomas, Springfield, IL.
- Haglund WD, Sorg MH (1997) *Forensic taphonomy. The postmortem fate of human remains*, CRC Press, Boca Raton.
- Hatch RL, Hacking S (2003) Evaluation and management of toe fractures. *Am Fam Physician* 68:2413-2418.
- Hayashi Y, Fujisawa H, Tohma Y, et al (2003) Penetrating head injury caused by bear claws: case report. *J Trauma* 55:1178-1180. <https://doi.org/10.1097/01.ta.0000025324.27227.d4>
- Haynes G (1980) Evidence of carnivore gnawing on Pleistocene and recent mammalian bones. *Paleobiology* 6:341-351.
- Haynes G (1982) Utilization and skeletal disturbances of North American prey carcasses. *Artic* 35:266-281.
- Haynes G (1983) A guide for differentiating mammalian carnivore taxa responsible for gnaw damage to herbivore limb bones. *Paleobiology* 9:164-172.
- Hejna P (2010) A fatal leopard attack. *J Forensic Sci* 55:832-834. <https://doi.org/10.1111/j.1556-4029.2010.01329.x>
- Holt BM, Formicola V (2008) Hunters of the ice age: the biology of upper paleolithic people. *Yrbk Phys Anthropol* 51:70-99. <https://doi.org/10.1002/ajpa.20950>
- Holt BM, Fornaciari G, Formicola V (2002) Bone remodeling following a lower leg fracture in the 11,000-year-old hunter-gatherer from Vado all'Arancio (Italy). *Int J Osteoarchaeol* 12:402-406. <https://doi.org/10.1002/oa.639>

- Jones E, Gonzalez-Forbes G, Connell S, et al (2015) Upper Palaeolithic genomes reveal deep roots of modern Eurasians. *Nat Commun* 6:8912. <https://doi.org/10.1038/ncomms9912>
- Kaiser TM (2000) Proposed fossil insect modification to fossil mammalian bone from Plio-Pleistocene hominid-bearing deposits of Laetoli (Northern Tanzania). *Ann Entomol Soc Am* 93:693-700. [https://doi.org/10.1603/0013-8746\(2000\)093\[0693:PFIMTF\]2.0.CO;2](https://doi.org/10.1603/0013-8746(2000)093[0693:PFIMTF]2.0.CO;2)
- Kimmerle EH, Baraybar JP (2008) Skeletal trauma – Identification of injuries resulting from human rights abuse and armed conflict, CRC Press, New York. <https://doi.org/10.1201/9781420009118>
- Kitagawa K, Krönneck P, Conard NJ, et al (2012) Exploring cave use and exploitation among cave bears, carnivores and hominins in the Swabian Jura, Germany. *J Taphon* 10:439-461. <http://doi.org/10.13140/RG.2.1.4106.0321>
- Knüsel CJ (2005) The physical evidence of warfare – subtle stigmata? In: Parker Pearson M, Thorpe IJN (eds) *Warfare, Violence and Slavery*, Archaeopress, Oxford, p. 49-65.
- Knüsel CJ, Thibault A, Villotte S (2023) A cranial injury from the earliest Gravettian at the Cro-Magnon rock shelter (Vézère Valley, Dordogne, southwest France). *J Hum Evol* 177:103329. <https://doi.org/10.1016/j.jhevol.2023.103329>
- Kramar C (2008) L'état de santé de l'homme du Bichon. In: Chavière F-X (ed) (2008) *La grotte du Bichon: Un site préhistorique des montagnes neuchâtelaises* (Archéologie neuchâtelaise, No. 42), Office et musée cantonal d'archéologie de Neuchâtel. Dossier 5. ISBN 978-2-940347-41-4.
- Kranioti E (2015) Forensic investigation of cranial injuries due to blunt force trauma: current best practice. *Res Rep Forensic Med Sci* 5:25-37 <https://doi.org/10.2147/RRFMS.S70423>
- Lahr MM, Rivera F, Power RK, et al (2016) Inter-group violence among early Holocene hunter-gatherers of West Turkana, Kenya. *Nature* 529:394-398. <https://doi.org/10.1038/nature16477>
- Lewis ME, French JC, Rossoni-Notter E, et al (2024) An assessment of puberty status in adolescents from the European Upper Paleolithic. *J Hum Evol* 198:103577. <https://doi.org/10.1016/j.jhevol.2024.103577>
- Love JC, Derrick SM, Wiersema JM (2011) *Skeletal atlas of child abuse*, Springer/Humana Press, New York.
- Lovell NC (1997) Trauma analysis in paleopathology. *Am J Phys Anthropol* 104:139-170. [https://doi.org/10.1002/\(SICI\)1096-8644\(1997\)25+%3C139::AID-AJPA6%3E3.0.CO;2-%23](https://doi.org/10.1002/(SICI)1096-8644(1997)25+%3C139::AID-AJPA6%3E3.0.CO;2-%23)
- MacPhail RI, Hater J, Hillson S, et al (1994) The Upper Pleistocene deposits at Arene Candide: soil micromorphology of some samples from the Cardini 1940- 42 excavations. *Quat Nova* 4:79-100.
- Maguire JM, Pemberton D, Collett MH (1980) The Makapansgat limeworks grey breccia: hominids, hyaenas, hystricids or hillwash? *Palaeontologia Africana* 23:75-98.
- McMordie JH, Viswanathan VK, Gillis CC (2025) Cervical spine fractures overview, StatPearls [Internet], StatPearls Publishing, Treasure Island (FL). <https://www.ncbi.nlm.nih.gov/books/NBK448129/>
- Metwaly AM, Ghoneim MM, Eissa IH, et al (2021) Traditional ancient Egyptian medicine: a review. *Saudi J Biol Sci* 28:5823-5832. <https://doi.org/10.1016/j.sjbs.2021.06.044>
- Molari C (1994) The industry on bone of the Pleistocene layers from the Arene Candide Cave (Savona, Italy). *Quat Nova* 4:297-340.
- Münzel SC, Conard NJ (2004) Change and continuity in subsistence during the Middle and Upper Palaeolithic in the Ach Valley of Swabia (south-west Germany). *Int J Osteoarchaeol* 14:225-243. <https://doi.org/10.1002/oa.758>
- Mussi M, Frayer DW, Macchiarelli R (1989) Les vivants et les morts. Les sépultures du Paléolithique supérieur en Italie et leur interprétation. In: Hershkovitz I (ed) *People and Culture in Change, Part I*, BAR Int Ser 508, Oxford, p. 435-458.
- Ogden JA (1990) Biology of chondro-osseous repair. In: Ogden JA (ed) *Skeletal Injury in the Child*, 2<sup>nd</sup> ed, WB Saunders, Philadelphia, p. 175-198.

- Onorati G, Simon P, Negrino F, et al (2011) Du sud de la montagne de Lure aux sépultures de Grimaldi: le silex zoné stampien dit "du Lague". Un matériau de prestige du Paléolithique supérieur liguro-provençal. *Bull Mus Monaco* 51:51-74.
- Oshima T, Ohtani M, Mimakasa S (2018) Injury patterns of fatal bear attacks in Japan: a description of seven cases. *Forensic Sci Int* 286:e14-e19. <https://doi.org/10.1016/j.forsciint.2018.02.021>
- Paoli G (1974) Età e statura del giovane paleolitico delle Arene Candide, atti della XVI Riunione Scientifica IIPP (Liguria, 3-5 novembre 1973), Istituto Italiano di Preistoria e Protostoria, Firenze, p.121-129.
- Pathak H, Borkar J, Dixit P, et al (2013) Fatal tiger attack: a case report with emphasis on typical tiger injuries characterized by partially resembling stab-like wounds. *Forensic Sci Int* 232:e1-e4. <https://doi.org/10.1016/j.forsciint.2013.08.003>
- Patil SB, Mody NB, Kale SM, et al (2019) A review of 48 patients after bear attacks in Central India: demographics, management and outcomes. *Indian J Plast Surg* 48:60-65. <https://doi.org/10.4103/0970-0358.155267>
- Petronio C, Bellucci L, Marinetto E, et al (2011) Biochronology and palaeoenvironmental changes from the Middle Pliocene to the Late Pleistocene in Central Italy. *Geodiversitas* 33:485-517. <http://doi.org/10.5252/g2011n3a4>
- Pettitt PB (2010) *The Palaeolithic origin of human burial*, Routledge, London. <https://doi.org/10.4324/9780203813300>
- Pettitt PB, Richards MP, Maggi R, et al (2003) The Gravettian burial known as the Prince ('Il Principe'): new evidence for his age and diet. *Antiquity* 77:15-19. <http://doi.org/10.1017/S0003598X00061305>
- Pokines JT, Symes SA (2014) *Manual of forensic taphonomy*, Boca Raton, CRC Press.
- Rasool A, Wani AH, Darzi MA, et al (2010) Incidence and pattern of bear maul injuries in Kashmir. *Injury* 41:116-119. <https://doi.org/10.1016/j.injury.2009.07.077>
- Rellini I, Firpo M, Martino G, et al (2013) Climate and environmental changes recognized by micromorphology in Paleolithic deposits at Arene Candide (Liguria, Italy). *Quat Int* 315:42-55. <https://doi.org/10.1016/j.quaint.2013.05.050>
- Rellini I, Martino G, Cabella R, et al (2025) A multimethod analysis for tracing Gravettian red ochre provenance at Arene Candide Cave (NW Italy). *J Quat Sci* 40:36-52. <https://doi.org/10.1002/jqs.3670>
- Resnick D (1995) Osteochondroses. In: Resnick D (ed) *Diagnosis of bone and joint disorders*, 3<sup>rd</sup> ed, Saunders, Philadelphia, p. 3559-3610.
- Riel-Salvatore J, Gravel-Miguel C (2013) Upper Paleolithic mortuary practices in Eurasia: a critical look at the burial record. In: Tarlow S, Nilsson Stutz L (eds) *The Oxford handbook of the archaeology of death and burial*, Oxford University Press, Oxford, p. 303-346.
- Riel-Salvatore J, Gravel-Miguel C, Maggi R, et al (2018) New insights into the Paleolithic chronology and funerary ritual of Caverna delle Arene Candide. In: Cristiani E, Borgia V (eds) *Palaeolithic Italy: Advanced studies on early human adaptations in the Apennine Peninsula*, Sidestone Press, Leiden, p. 335-355.
- Riel-Salvatore J, Gravel-Miguel C, Maggi R, et al (2023) A synthesis of recent research in the Paleolithic deposit of Caverna delle Arene Candide (Finale Ligure, SV). *Riv Sci Preist* 73:585-600.
- Rigaud A (2001) Les bâtons percés: décors énigmatiques et fonction possible, *Gallia Préhist* 43:101-151. <http://doi.org/10.3406/galip.2001.2176>
- Romandini M, Terlato G, Nannini N, et al (2018) Bears and humans, a Neanderthal tale. Reconstructing uncommon behaviors from zooarchaeological evidence in southern Europe. *J Archaeol Sci* 90:71-91. <https://doi.org/10.1016/j.jas.2017.12.004>
- Rothschild BM, Bryant B, Hubbard C, et al (2013) The power of the claw. *PLoS One* 8:e73811. <https://doi.org/10.1371/journal.pone.0073811>
- Russo G, Milks A, Leder D, et al (2023) First direct evidence of lion hunting and the early

- use of a lion pelt by Neanderthals. *Sci Rep* 2023 13:16405. <https://doi.org/10.1038/s41598-023-42764-0>
- Ryan K, Betts MW, Oliver-Lloyd V, et al (2014) Identification of pre-contact polar bear victim at native point, Southampton Island, Nunavut, using 3D technology and virtual zooarchaeology collection. *Arctic* 67:493-510. <http://doi.org/10.14430/arctic4429>
- Sala N, Arsuaga JL (2013) Taphonomic studies with wild brown bears (*Ursus arctos*) in the mountains of northern Spain. *J Archaeol Sci* 40:1389-1396. <https://doi.org/10.1016/j.jas.2012.10.018>
- Sala N, Arsuaga JL (2018) Regarding beasts and humans: a review of taphonomic works with living carnivores. *Quat Int* 466:131-140. <http://dx.doi.org/10.1016/j.quaint.2016.03.011>
- Sala N, Arsuaga JL, Martínez I, et al (2014) Carnivore activity in the Sima de los Huesos (Atapuerca, Spain) hominin sample. *Quat Sci Rev* 97:71-83. <http://dx.doi.org/10.1016/j.quascirev.2014.05.004>
- Sala N, Arsuaga JL, Martínez I, et al (2015a) Breakage patterns in Sima de los Huesos (Atapuerca, Spain) hominin sample. *J Archaeol Sci* 55:113-121. <https://doi.org/10.1016/j.jas.2015.01.002>
- Sala N, Arsuaga JL, Pantoja-Pérez A, et al (2015b) Lethal interpersonal violence in the Middle Pleistocene. *PLoS One* 10:e0126589. <https://doi.org/10.1371/journal.pone.0126589>
- Sala N, Pantoja-Pérez A, Arsuaga JL, et al (2016) The Sima de los Huesos crania: analysis of the cranial breakage patterns. *J Archaeol Sci Rep* 72:25-43. <https://doi.org/10.1016/j.jas.2016.06.001>
- Sala N, Pantoja-Pérez A, Gracia A, et al (2024) Taphonomic-forensic analysis of the hominin skulls from the Sima de los Huesos. *Anat Rec* 307:1-19. <https://doi.org/10.1002/ar.24883>
- Sandberg OH, Aspenberg P (2016) Intertrabecular bone formation: a specific mechanism for healing of cancellous bone. *Acta Orthop* 87:459-465. <https://doi.org/10.1080/17453674.2016.1205172>
- Saos T, Khatib S, De Lumley H, et al (2016) Étude minéralogique des colorants de la sépulture de 'La Dame du Cavillon'. In: Lumley H (ed) *La grotte du Cavillon: Sous la falaise des Baoussé Roussé, Grimaldi, Vintimille, Italie*, CNRS Edition, Paris, p. 627-691.
- Sauer NJ (1998) The timing of injuries and manner of death: distinguishing among antemortem, perimortem and postmortem trauma. In: Reichs KJ (ed) *Forensic Osteology: Advances in the Identification of Human Remains*, 2<sup>nd</sup> ed, Charles C. Thomas, Springfield, p. 321-332.
- Saxe AA (1970) Social dimensions of mortuary practices, Unpublished Ph.D. dissertation, University of Michigan, Ann Arbor.
- Schotsmans EMJ, Márquez-Grant N, Forbes SL (2017) Taphonomy of human remains. *Forensic analysis of the dead and the depositional environment*, John Wiley & Sons, Oxford. <https://doi.org/10.1002/9781118953358>
- Schwab N, Galtés I, Winter-Buchwalder M, et al (2023) Osteonal microcracking pattern: a Potential vitality marker in human bone trauma. *Biology* 12:399. <https://doi.org/10.3390/biology12030399>
- Selvaggio MM, Wilder J 2001. Identifying the involvement of multiple carnivore taxa with archaeological bone assemblages. *J Archaeol Sci* 28, 465-470. <https://doi.org/10.1006/jasc.2000.0601>
- Sergi S, Parenti R, Paoli G (1974) Il giovane paleolitico della Caverna delle Arene Candide. *Mem IIPU* 2:13-38.
- Sobrinho J, Shafi S (2013) Timing and causes of death after injuries. *Proc (Bayl Univ Med Cent)* 26:120-123. <https://doi.org/10.1080/08998280.2013.11928934>
- Sparacello VS, Rossi S, Pettitt PB, et al (2018) New insights on Final Epigravettian funerary behavior at Arene Candide Cave (western Liguria, Italy). *J Anthropol Sci* 96:161-184. <https://doi.org/10.4436/jass.96003>
- Sparacello VS, Dori I, Rossi S, et al (2021) New human remains from the Late Epigravettian necropolis of Arene Candide (Liguria, northwestern Italy): direct radiocarbon evidence and inferences on the funerary use of the cave during the Younger Dryas. *Quat Sci Rev* 268:107131. <https://doi.org/10.1016/j.quascirev.2021.107131>

- Sparacello VS, Mottes E, Dori I, et al (2023a) A history of violence in the Mesolithic female skeleton from Mezzocorona-Borgonuovo (Trento, northeastern Italy). *Quat Sci Rev* 311:108149. <https://doi.org/10.1016/j.quascirev.2023.108149>
- Sparacello VS, Goude G, Varalli A, et al (2023b) Human remains from Arma di Nasino (Liguria) provide novel insights into the paleoecology of early Holocene foragers in northwestern Italy. *Sci Rep* 13:16415. <https://doi.org/10.1038/s41598-023-40438-5>
- Sparacello VS, Panelli C, Rossi S, et al (2019) The re-discovery of Arma dell'Aquila (Finale Ligure, Italy): new insights on Neolithic funerary behavior from the sixth millennium BCE in the north-western Mediterranean. *Quat Int* 512:67-81. <https://doi.org/10.1016/j.QUAINT.2019.02.003>
- Sparacello VS, Thun Hohenstein U, Boschini F, et al (2025) Projectile weapon injuries in the Riparo Tagliente burial (Veneto, Italy) provide early evidence of Late Upper Paleolithic intergroup conflict. *Sci Rep* 15: 14857. <https://doi.org/10.1038/s41598-025-94095-x>
- Stojanowski CM, Seidel AC, Fulginiti LC, et al (2016) Contesting the massacre at Nataruk. *Nature* 539:E8-E10. <https://doi.org/10.1038/nature19778>
- Tough SC, Butt JC (1993) A review of fatal bear maulings in Alberta, Canada. *Am J Forensic Med Pathol* 14:22-27. <https://doi.org/10.1097/00000433-199303000-00005>
- Trinkaus E (2005) The upper limb remains. In: Trinkaus E, Svoboda JA (eds) *Early modern human evolution in Central Europe: the people of Dolní Věstonice and Pavlov*, Oxford University Press, Oxford, p. 380-418.
- Trinkaus E (2011) Late Pleistocene adult mortality patterns and modern human establishment. *Proc Natl Acad Sci USA* 108:1267-1271. <https://doi.org/10.1073/pnas.1018700108>
- Trinkaus E (2012) Neandertals, early modern humans, and rodeo riders. *J Archaeol Sci* 39:3691-3693. <https://doi.org/10.1016/j.jas.2012.05.039>
- Trinkaus E (2015) The appendicular skeletal remains of Oberkassel 1 and 2. In: Giemsch L, Schmitz RW (eds) *The Late Glacial burial from Oberkassel Revisited*, Verlag Phillip von Zabern, Darmstadt, p. 75-132.
- Trinkaus E, Buzhilova AP (2012) The death and burial of Sunghir 1. *Int J Osteoarchaeol* 22:655-666. <https://doi.org/10.1002/oa.1227>
- Trinkaus E (2018) An abundance of developmental anomalies and abnormalities in Pleistocene people. *Proc Natl Acad Sci USA* 115:11941-11946. <https://doi.org/10.1073/pnas.1814989115>
- Trinkaus E, Buzhilova AP (2018) Diversity and differential disposal of the dead at Sunghir. *Antiquity* 92:7-21. <https://doi.org/10.15184/aqy.2017.223>
- Trinkaus E, Zimmerman MR (1982) Trauma among the Shanidar Neandertals. *Am J Phys Anthropol* 57:61-76. <https://doi.org/10.1002/ajpa.1330570108>
- Ubelaker DH, Montaperto KM (2014) Trauma interpretation in the context of biological anthropology. In: Knüsel CJ, Smith MJ (eds) *The Routledge handbook of the bioarchaeology of human conflict*, Routledge, New York, p. 25-38. <https://doi.org/10.4324/9781315883366>
- Ueda S, Okamoto N, Seki T, et al (2021) A large gastric rupture due to blunt trauma: a case report and a review of the Japanese literature. *J Surg Case Rep* 1:1-3. <https://doi.org/10.1093/jscr/rjaa521>
- Vashistha A, Singh M, Kaur G, et al (2019) Bear maul injury in maxillofacial region: a case report. *The Traumaxilla* 1:22-25. <http://doi.org/10.1177/2632327319881071>
- Villa P, Mahieu E. 1991. Breakage patterns of human long bones. *J Hum Evol* 21:27-48. [https://doi.org/10.1016/0047-2484\(91\)90034-S](https://doi.org/10.1016/0047-2484(91)90034-S)
- Waters PM, Skaggs DL, Flynn JM (2020) *Rockwood and Wilkins' fractures in children*, 9<sup>th</sup> ed, Wolters Kluwer, Philadelphia.
- Wedel VL, Galloway A (2014) *Broken Bones. Anthropological analysis of blunt force trauma*, Charles C Thomas, Springfield.
- White TD, Toth N (1989) Engis: Preparation damage, not ancient cutmarks. *Am J Phys Anthropol* 78:361-367. <https://doi.org/10.1002/ajpa.1330780305>
- Winter-Buchwalder M, Schwab N, Galtés I, et al (2024) Microcracking pattern in fractured

- bones: new approach for distinguishing between peri- and postmortem fractures. *Int J Legal Med* 138:35-42. <https://doi.org/10.1007/s00414-022-02875-1>
- Wu XJ, Trinkaus E (2015) Neurocranial trauma on the late archaic human remains from Xujiayao, northern China. *Int J Osteoarchaeol* 25:245-252. <https://doi.org/10.1002/oa.2283>
- Wu XJ, Schepartz LA, Lui W, et al (2011) Antemortem trauma and survival in the late Middle Pleistocene human cranium from Maba, South China. *Proc Natl Acad Sci USA* 108:19558-19562. <https://doi.org/10.1073/pnas.1117113108>
- Yanagisawa Y, Ishii T, Yamazaki M (2021) Bilateral osteochondritis dissecans of the talar posterior calcaneal articular surface in a professional soccer player: a case report. *J Orthop Case Rep* 11:55-58. <https://doi.org/10.13107/jocr.2021.v11.i03.2086>
- Yilmaz A, Hosukler E, Erkol Z, et al (2021) Old female case who died as a result of bear attack. *Med Sci* 10:623-626. <https://doi.org/10.5455/medscience.2020.08.174>
- Zunino M, Starnini E, Arobba D, et al (2022) New insights into taphonomic analysis of the Upper Pleistocene *Ursus spelaeus* bone deposits from Bàsura Cave. *J Quaternary Sci* 37:1-15. <https://doi.org/10.1002/jqs.3417>

Associate Editor, Fabio Di Vincenzo



This work is distributed under the terms of a Creative Commons Attribution-NonCommercial 4.0 Unported License <http://creativecommons.org/licenses/by-nc/4.0/>

