

Images in Clinical Hematology

Bone marrow involvement in small cell lung cancer



Giuseppe G. Loscocco ^{a,b,*}, Matteo Piccini ^a, Sara Bencini^b, Federica Vergoni^{a,b}

^a Azienda Ospedaliero-Universitaria Careggi (AOU Careggi), Florence, Italy

^b University of Florence, Florence, Italy

ARTICLE INFO

Article history:

Received 1 June 2020

Accepted 20 July 2020

Available online 4 August 2020

A 67-year-old-woman with a 35-pack-years smoking history, presented to our Institution complaining of progressive dyspnea, chest discomfort, gingival bleeding and unintentional weight loss of 8 kg in the past month. Physical examination was unremarkable except for a left supraclavicular lymphadenopathy and laboratory data showed severe neutropenia (neutrophils $0.18 \times 10^9/L$, normal value 1.5×7.5) and thrombocytopenia (platelets $8 \times 10^9/L$, normal value 140–440), anemia (hemoglobin 7.7 g/dL, normal value 12–14), high serum lactate dehydrogenase level (2942 U/L, normal value 135–214) and hyperuricemia (10.4 mg/dL, normal value 3.5–7). Iodine-based contrast computed tomography scan (CT) of the chest and abdomen showed an anterior mediastinal mass and hilar adenopathy with perivascular and peribronchial growth (Figure 1A). Bone marrow (BM) aspirate documented a massive infiltration of monomorphic atypical medium sized cells with the following features: tendency for non-cohesive growth, high nuclear to cytoplasmic ratio with scanty cytoplasm, fine chromatin pattern and inconspicuous nucleoli (Figure 1B). Flow-cytometry revealed the presence of an aberrant, SSC^{high} cell population (>90% of all nucleated cells) negative for CD45, CD16, CD13, CD33, CD34, CD38, CD5, CD7, CD3, CD4, CD8, CD19, CD10, CD20, CD22, HLA-DR, positive for CD117 and CD15 and strongly positive for CD56 (Figure 1C), suggestive for non-

hematopoietic origin. BM histopathology showed a massive infiltration by these atypical cells (Figure 1D). Immunohistochemical analyses documented positivity for CD56, thyroid transcription factor 1 (TTF-1), synaptophysin and chromogranin A (Figure 1E–H). Taken together, these morphological, clinical and pathological features were consistent with a BM involvement of a primitive neuroendocrine tumour of the lung. Fine needle aspiration biopsy of the mediastinal mass led to the diagnosis of small cell lung cancer (SCLC). Two weeks later, the patient died due to pneumonia before being able to initiate a treatment.

SCLC accounts for approximately 15% of all malignant tumors of the lung and its occurrence is strikingly related to cigarette smoking. At the time of diagnosis many patients have an extensive-stage disease with clinical evidence of metastases. In these cases, despite therapeutic progress, the prognosis remains poor. BM involvement has been frequently documented in SCLC,^{1,2} but BM biopsy it is not routinely performed as part of the staging process. However, such a massive BM involvement with morphological and clinical features mimicking a hematopoietic neoplasm, such a high-grade lymphoma, is seldomly reported. In these cases, BM immunophenotype and histopathology can represent a valuable tool for differential diagnosis.

* Corresponding author at: Department of Experimental and Clinical Medicine, University of Florence, Italy.

E-mail address: giuseppelosoccog@gmail.com (G.G. Loscocco).

<https://doi.org/10.1016/j.htct.2020.07.003>

2531-1379/© 2020 Associação Brasileira de Hematologia, Hemoterapia e Terapia Celular. Published by Elsevier Editora Ltda. This is an open access article under the CC BY-NC-ND license (<http://creativecommons.org/licenses/by-nc-nd/4.0/>).

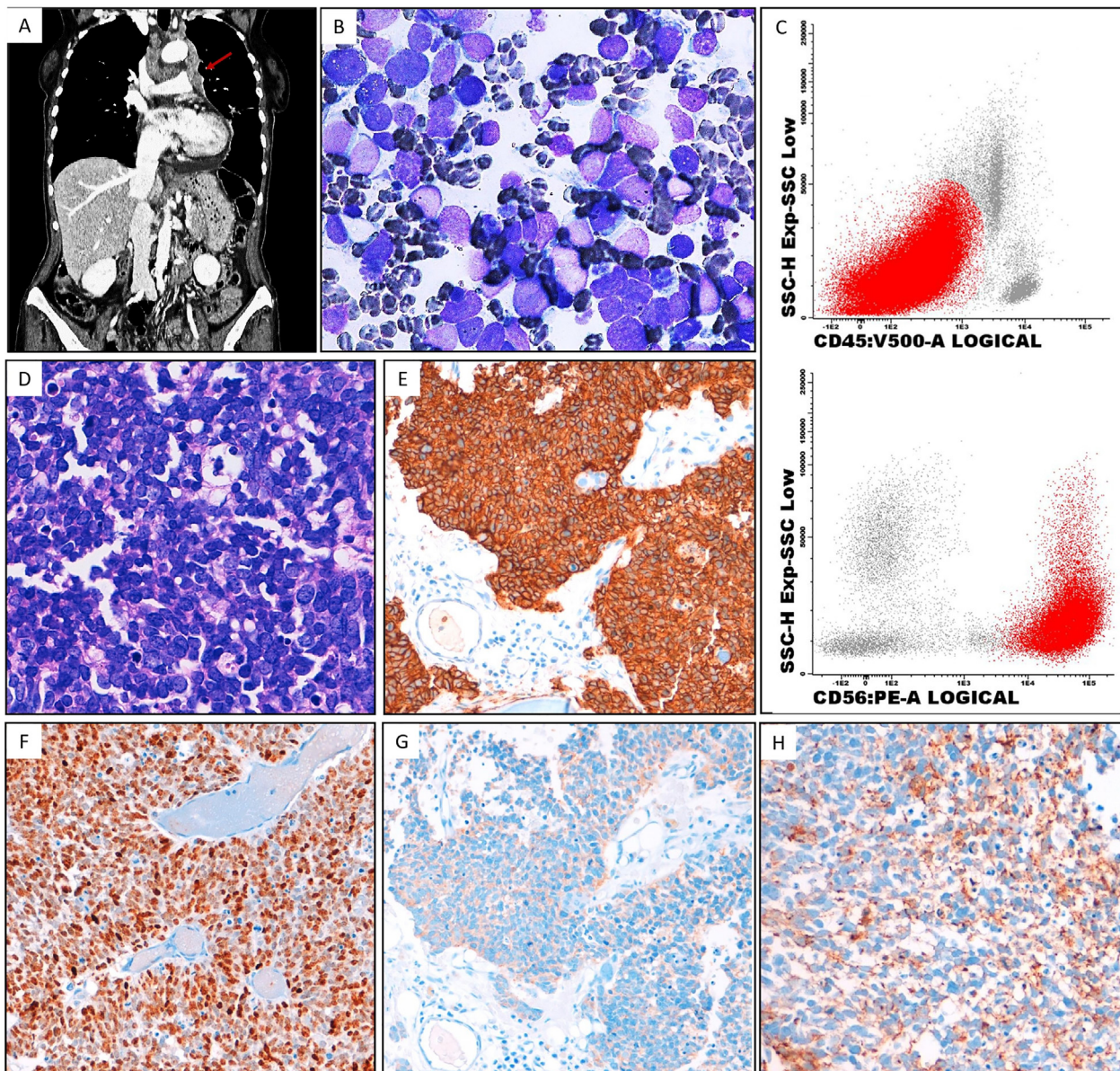


Figure 1 – The contrast CT-scan highlights anterior mediastinal mass (A, red arrow). In B the bone marrow (BM) aspirate (May-Grunwald-Giemsa, $\times 100$) shows a massive infiltration of monomorphic atypical medium sized cells. In C representative dot plots from flow cytometry analysis show abnormal neoplastic cells (highlighted in red colour) with high side scatter signal negative for CD45 and strongly positive for CD56. BM biopsy reveals the same atypical cells (D, Hematoxylin and Eosin, $\times 50$) positive for CD56 (E) TTF-1 (F), synaptophysin (G) and chromogranin A (H).

Conflicts of interest

The author declares no conflicts of interest.

REFERENCES

1. Tritz DB, Doll DC, Ringenberg QS, Anderson S, Madsen R, Perry MC, et al. Bone marrow involvement in small cell lung cancer. *Clinical significance and correlation with routine laboratory variables.* *Cancer.* 1989;63(4):763–6.
2. Trillet-Lenoir VN, Arpin D, Brune J. Bone marrow metastases detection in small cell lung cancer. A review. *Anticancer Res.* 1994;14(6B):2795–7.