

Amyloid

The Journal of Protein Folding Disorders

ISSN: 1350-6129 (Print) 1744-2818 (Online) Journal homepage: www.tandfonline.com/journals/iamy20


Left atrial strain identifies early cardiac involvement in variant transthyretin amyloidosis

Matteo Serenelli , Elisa Gardini , Stefania Marazia , Alessandro Barbarossa , Alberto Cipriani , Anna Cantone , Beatrice Dal Passo , Federico Sanguettoli , Rita Pavasini , Matteo Arzenton , Gianluca Campo , Andrea Zaccaro , Emiliano Rossi , Gioele Fabbri , Enrico Monti , Carmine Pizzi , Erika Pedio , Federico Guerra , Giulio Sinigiani , Alberto Aimò , Michele Emdin, Francesco Cappelli, Federica Colio & Simone Longhi

To cite this article: Matteo Serenelli , Elisa Gardini , Stefania Marazia , Alessandro Barbarossa , Alberto Cipriani , Anna Cantone , Beatrice Dal Passo , Federico Sanguettoli , Rita Pavasini , Matteo Arzenton , Gianluca Campo , Andrea Zaccaro , Emiliano Rossi , Gioele Fabbri , Enrico Monti , Carmine Pizzi , Erika Pedio , Federico Guerra , Giulio Sinigiani , Alberto Aimò , Michele Emdin, Francesco Cappelli, Federica Colio & Simone Longhi (07 May 2026): Left atrial strain identifies early cardiac involvement in variant transthyretin amyloidosis, *Amyloid*, DOI: [10.1080/13506129.2026.2663922](https://doi.org/10.1080/13506129.2026.2663922)

To link to this article: <https://doi.org/10.1080/13506129.2026.2663922>

 View supplementary material [↗](#)

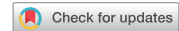 Published online: 07 May 2026.

 Submit your article to this journal [↗](#)

 Article views: 49

 View related articles [↗](#)

 View Crossmark data [↗](#)



Left atrial strain identifies early cardiac involvement in variant transthyretin amyloidosis

To the Editors

VARIANT transthyretin amyloidosis (ATTRv) is an infiltrative multisystem disorder caused by mutations in the transthyretin (TTR) gene, presenting with cardiac, neurological, or mixed phenotypes [1]. As disease awareness increases, the number of identified mutation carriers is expected to rise. Early diagnosis of ATTRv enables family screening and identification of individuals with subclinical involvement, thereby facilitating the initiation of disease-modifying therapies.

However, no evidence-based guidelines currently define the optimal follow-up of carriers or the timing for treatment initiation. There is a critical unmet need to better delineate the presymptomatic disease trajectory before the onset of overt cardiac amyloidosis, as no validated imaging- or biomarker-based screening criteria currently exist for identifying cardiac involvement in asymptomatic carriers.

Bone scintigraphy and cardiac magnetic resonance (CMR) are the most widely used imaging modalities for detecting cardiac amyloid deposition [2], yet both are costly, time-consuming, and not universally available, and repeated bone scintigraphy raises concerns regarding cumulative radiation exposure.

The aim of our study was to test if echocardiography—particularly speckle-tracking analysis of left atrium (LA) and left ventricle (LV)—can reliably detect early cardiac involvement in TTR mutation carriers.

This was a multicenter, cross-sectional study involving consecutive patients with a known TTR gene mutation, followed at seven specialized amyloidosis outpatient clinics. All enrolled patients underwent a bone scintigraphy within six months of an echocardiographic evaluation. Patients were excluded if they had an abnormal electrocardiogram (EKG), history of atrial fibrillation, cardiac hypertrophy—defined as interventricular septal or posterior wall thickness >11 mm in males and >10 mm in females—or suboptimal echocardiographic image quality precluding speckle-tracking analysis (Supplementary Appendix).

The tracers used for bone scintigraphy were either technetium-99m 3,3-dicarboxypropane-1,1-diphosphonate (DPD) or technetium-99m hydroxymethylene diphosphonate (HMDP) based on local availability.

Cardiac uptake was defined as having a Perugini score ≥ 1 at bone scintigraphy.

All echocardiographic examinations were analyzed by a central core lab, offline with the TomTec Imaging Systems platform. Echocardiographic measures were performed in accordance with EACVI guidelines and left atrial strain values reported as absolute values [3]. Bone scintigraphy exams were analyzed locally. To account for multiple comparisons, *p*-values were adjusted using the Benjamini–Hochberg false discovery rate (FDR) procedure, with a prespecified FDR threshold of 0.05. Univariate logistic regression was used to test the association between echocardiographic variables and cardiac uptake. A sensitivity analysis was conducted excluding patients carrying the p.Phe84Leu and the p.Val50Met TTR variants, to account for the risk of false-negative results in patients with this specific mutation [4,5] (Supplementary Appendix). The study was conducted in accordance with the Declaration of Helsinki, and all patients provided informed consent for anonymized data use.

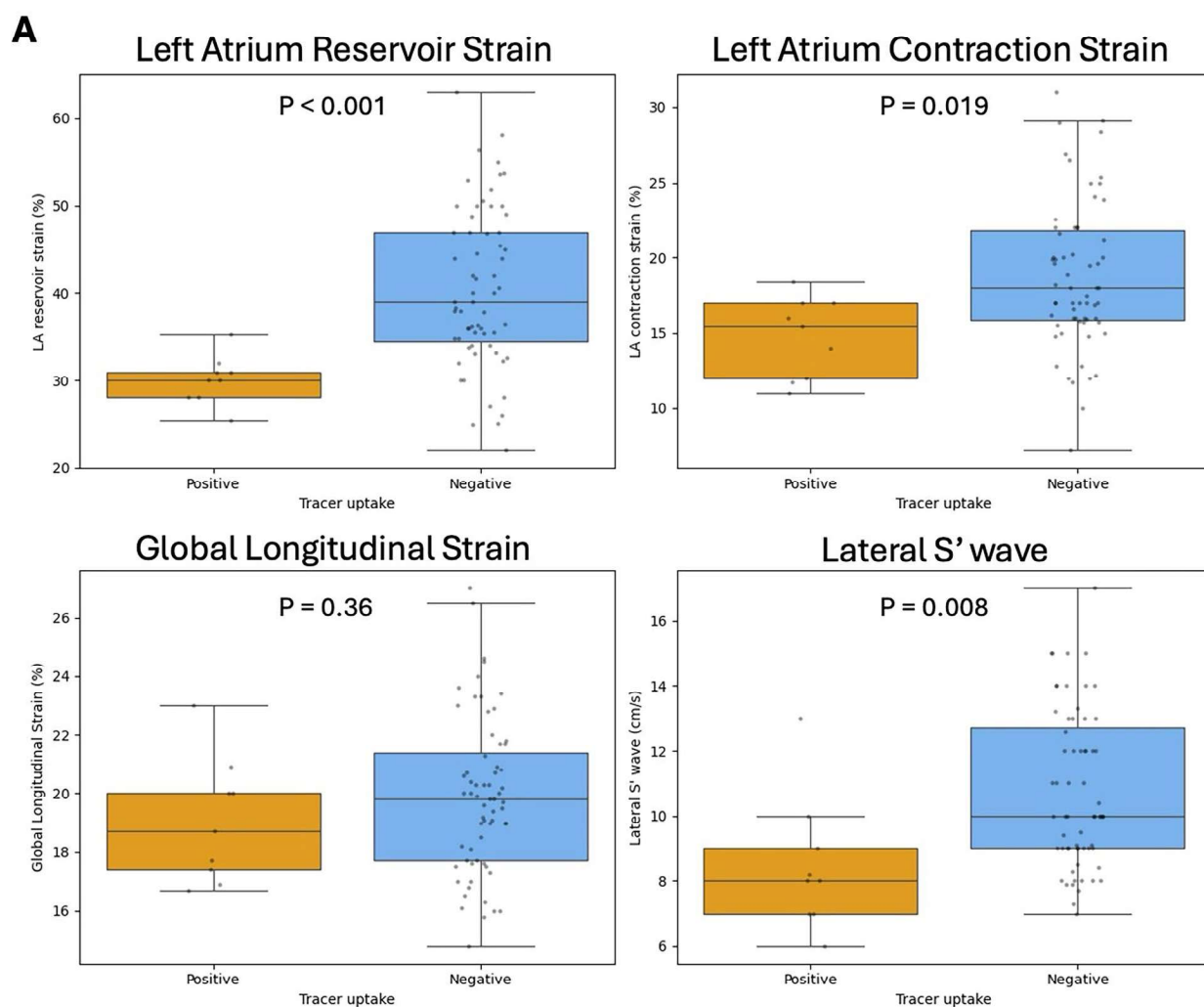
A total of 74 carriers were enrolled in the study. The most frequent TTR variant was p.Ile88Leu (54.0%), followed by p.Phe84Leu (13.5%), p.Val50Met (10.8%), p.Val144Ile (9.4%), and p.Ala69Thr (4.0%). Nine carriers showed cardiac tracer uptake ($n=3$ score 1, $n=4$ score 2, and $n=2$ score 3).

Patients with and without cardiac uptake at bone scintigraphy were comparable in terms of baseline clinical characteristics (Supplementary Appendix). No significant differences were observed in age (40.4 vs. 47.4 years; $p=.56$), sex (51 vs. 44% male; $p=.72$), hypertension (17 vs. 22%; $p=.70$) and body mass index (BMI) (25.1 vs. 24.6 kg/m²; $p=.74$). No patient had a history of carpal tunnel syndrome or lumbar canal stenosis.

Patients were comparable in terms of LV mass index (66.4 vs. 71.1 g/m²; $p=.45$), LVEF (63.7 vs. 65.1%; $p=.33$), E/A ratio ($p=.27$) and E/e' ratio ($p=.11$). Left and right atria volumes did not reveal significant differences (LAVi 22.5 vs. 26.8 ml/m²; $p=.11$ and RAVi 17.9 vs. 19.1 ml/m²; $p=.54$) while LASr and LASct were significantly lower in patients with cardiac uptake (30.1 vs. 40.5%; $p=.001$ and 14.7 vs. 18.7%; $p=.019$, respectively) (Figure 1(A)).

Similarly, lateral mitral annular S' wave velocity was significantly lower in patients with cardiac tracer uptake (8.5 vs. 10.7 cm/s; $p=.008$), whereas LV GLS did not differ significantly between the two groups (-18.7 vs. -19.8%; $p=.36$).

At univariable analysis, each 1%-point decrease in LASr was associated with a significantly higher likelihood of cardiac tracer uptake (OR 1.24; 95% CI 1.10–1.41; $p=.001$), with excellent discriminatory



B

Univariate logistic regression for prediction of positive tracer uptake				
	OR	95% CI	p-value	AUC
LA reservoir strain – 1% decrease	1.24	1.10 - 1.41	0.001	0.88
LA contraction strain – 1% decrease	1.26	1.06 - 1.50	0.008	0.76
Lateral S' wave – 1 cm/s decrease	1.85	0.93 - 3.68	0.078	0.78

Figure 1. Main echocardiographic differences according to cardiac tracer uptake at bone scintigraphy (A) and univariate logistic regression for prediction of positive tracer uptake (B).

performance (AUC 0.88) (Figure 1(B)). Similarly, each 1%-point decrease in LASct was associated with an increased probability of cardiac uptake (OR 1.26; 95% CI 1.06–1.50; $p=.008$), although with more modest discrimination (AUC 0.76). An LASr cutoff value of 32% yielded a sensitivity of 0.89 and a specificity of 0.86, whereas an LASct threshold of 17% provided comparable sensitivity (0.89) but substantially lower specificity (0.52). Lateral S' wave did not predict cardiac uptake at univariate logistic regression ($p=.078$). Exclusion of p.Val50Met and p.Phe84Leu mutations from the cohort did not change the main results (Supplementary Appendix).

Our analysis shows that LAS impairment can suggest early cardiac involvement in patients with TTR gene pathogenic variants. Traditional parameters of LV systolic and diastolic function remained similar between patients with and without cardiac uptake. This strongly supports the emerging concept of atrial cardiomyopathy as a primary and early feature of cardiac amyloidosis, rather than a secondary consequence of ventricular dysfunction [6]. This 'atria-first hypothesis' is substantiated by histopathological evidence showing that the atria are among the earliest sites of amyloid deposition, a process that can precede significant ventricular changes [6].

The deterioration of atrial function, particularly LASr may represent early and sensitive marker of cardiac disease, paralleling the uptake of bone tracers. LAS has already been identified as a relevant marker in cardiac amyloidosis, particularly in patients with manifest ATTR-CM, where it is markedly impaired and has been associated with adverse clinical outcomes, including an increased risk of cerebrovascular events [7,8]. Our findings extend the existing evidence on LAS by highlighting its potential role in a cohort of asymptomatic ATTRv mutation carriers evaluated at a preclinical stage of disease.

The clinical implications of identifying this early-stage atrial cardiomyopathy are profound. Atrial dysfunction is not merely a marker of tissue infiltration but is itself a critical pathophysiological substrate that increases the risk of major adverse clinical events [8]. An established atrial cardiomyopathy is known to promote atrial fibrillation, intracardiac thrombus formation, and thromboembolic events, including stroke, even in the absence of documented AF [9]. Therefore, early detection of LASr impairment could serve as a tool for risk stratification, identifying individuals who may benefit from closer surveillance and earlier initiation of disease-modifying therapies.

Repeated bone scintigraphy carries low but non-negligible radiation exposure, and CMR is

logistically more complex and expensive for routine screening of a large population of asymptomatic carriers. Based on our results, we propose that speckle-tracking analysis, and specifically LASr, could serve as a cost-effective, non-invasive, and readily available first-line screening tool. This positions LASr as a potential gatekeeper for more advanced imaging. A potential clinical pathway for asymptomatic TTR mutation carriers could include annual echocardiography with atrial strain analysis, integrated with serial assessment of cardiac biomarkers, particularly NT-proBNP and cardiac troponins. A documented and progressive decline in LASr and/or a significant rise in biomarkers, even in the presence of preserved conventional ventricular parameters, would trigger referral for confirmatory imaging (e.g. bone scintigraphy or CMR) to confirm amyloid deposition and quantify the disease burden, thereby facilitating timely therapeutic intervention. Any imaging-based surveillance strategy should therefore be interpreted within a multimodal framework that includes longitudinal biomarker monitoring, which currently represents a more established and widely accessible tool for early detection and risk stratification [10,11].

The cross-sectional design and relatively small cohort size warrant confirmation in larger, prospective, longitudinal studies, in which cardiac biomarkers should also be systematically and uniformly measured to allow a more comprehensive contextualization of echocardiographic findings. Furthermore, echocardiographic analyses were performed in a centralized core laboratory, ensuring methodological consistency but potentially limiting the generalizability of our findings to routine clinical practice, where inter-observer variability and differences in acquisition protocols may be greater.

Author contributions

CRedit: **Matteo Serenelli**: Conceptualization, Data curation, Formal analysis, Investigation, Methodology, Writing – original draft; **Elisa Gardini**: Data curation, Investigation, Writing – review & editing; **Stefania Marazia**: Data curation, Investigation, Writing – review & editing; **Alessandro Barbarossa**: Data curation, Investigation, Writing – review & editing; **Alberto Cipriani**: Writing – review & editing; **Anna Cantone**: Investigation, Writing – review & editing; **Beatrice Dal Passo**: Investigation, Writing – review & editing; **Federico Sanguettoli**: Writing – review & editing; **Rita Pavasini**: Methodology, Writing – review & editing; **Matteo Arzenton**: Writing – review & editing; **Gianluca Campo**: Supervision, Writing – review & editing; **Andrea Zaccaro**: Investigation, Writing – review & editing; **Emiliano Rossi**: Investigation, Writing – review & editing; **Gioele Fabbri**: Data curation, Investigation, Methodology, Writing – review & editing; **Enrico Monti**: Writing – review & editing;

Carmine Pizzi: Writing – review & editing; **Erika Pedio:** Data curation, Investigation, Writing – review & editing; **Federico Guerra:** Writing – review & editing; **Giulio Sinigiani:** Investigation, Writing – review & editing; **Alberto Aimo:** Writing – review & editing; **Michele Emdin:** Writing – review & editing; **Francesco Cappelli:** Investigation, Writing – review & editing; **Federica Colio:** Investigation, Writing – review & editing; **Simone Longhi:** Investigation, Supervision, Writing – review & editing.

Disclosure statement

No potential conflict of interest was reported by the author(s).

Funding

No external funding was received for this study.

ORCID

Michele Emdin  <http://orcid.org/0000-0002-8541-1962>

References

- [1] Rapezzi C, Quarta CC, Obici L, et al. Disease profile and differential diagnosis of hereditary transthyretin-related amyloidosis with exclusively cardiac phenotype: an Italian perspective. *Eur Heart J*. 2013;34(7):520–528. doi:10.1093/eurheartj/ehs123.
- [2] Rapezzi C, Aimo A, Serenelli M, et al. Critical comparison of documents from scientific societies on cardiac amyloidosis. *J Am Coll Cardiol*. 2022;79:1288–1303.
- [3] Badano LP, Kolas TJ, Muraru D, et al. Standardization of left atrial, right ventricular, and right atrial deformation imaging using two-dimensional speckle tracking echocardiography: a consensus document of the EACVI/ASE/Industry Task Force to standardize deformation imaging. *Eur Heart J Cardiovasc Imaging*. 2018;19(6):591–600. doi:10.1093/ehjci/jev042.
- [4] Musumeci MB, Cappelli F, Russo D, et al. Low sensitivity of bone scintigraphy in detecting Phe64Leu mutation-related transthyretin cardiac amyloidosis. *JACC Cardiovasc Imaging*. 2020;13(6):1314–1321. doi:10.1016/j.jcmg.2019.10.015.
- [5] Azevedo Coutinho MC, Cortez-Dias N, Cantinho G, et al. The sensitivity of DPD scintigraphy to detect transthyretin cardiac amyloidosis in V30M mutation depends on the phenotypic expression of the disease. *Amyloid*. 2020;27(3):174–183. doi:10.1080/13506129.2020.1744553.
- [6] Goette A, Corradi C, Dobrev D, et al. Atrial cardiomyopathy revisited—evolution of a concept: a clinical consensus statement of the European Heart Rhythm Association (EHRA) of the ESC, the Heart Rhythm Society (HRS), the Asian Pacific Heart Rhythm Society (APHRS), and the Latin American Heart Rhythm Society (LAHRS). *Europace*. 2024;26(9):euae204. doi:10.1093/europace/eaue204.
- [7] Sinigiani G, De Michieli L, Porcari A, et al. Atrial electrofunctional predictors of incident atrial fibrillation in cardiac amyloidosis. *Heart Rhythm*. 2024;21(6):725–732. doi:10.1016/j.hrthm.2024.01.056.
- [8] Aimo A, Fabiani I, Giannoni A, et al. Multi-chamber speckle tracking imaging and diagnostic value of left atrial strain in cardiac amyloidosis. *Eur Heart J Cardiovasc Imaging*. 2022;24(1):130–141. doi:10.1093/ehjci/jeac057.
- [9] Vergaro G, Aimo A, Rapezzi C, et al. Atrial amyloidosis: mechanisms and clinical manifestations. *Eur J Heart Fail*. 2022;24(11):2019–2028. doi:10.1002/ejhf.2650.
- [10] Grandis M, Obici L, Luigetti M, et al. Recommendations for pre-symptomatic genetic testing for hereditary transthyretin amyloidosis in the era of effective therapy: a multicenter Italian consensus. *Orphanet J Rare Dis*. 2020;15(1):348. doi:10.1186/s13023-020-01633-z.
- [11] Guaraldi P, Allegri I, Ariatti A, et al. Monitoring patients and asymptomatic carriers with hereditary transthyretin amyloidosis: regional protocol of Emilia-Romagna ATTR working group. *Front Neurol*. 2025;16:1666318. doi:10.3389/fneur.2025.1666318.

Matteo Serenelli

Cardiovascular Institute, Azienda Ospedaliero-Universitaria di Ferrara, Ferrara, Italy

 matteoserenelli@gmail.com

Elisa Gardini

U.O. Cardiologia, Ospedale di Forlì, AUSL della Romagna, Forlì, Italy

Stefania Marazia

U.O.C. Cardiologia e U.T.I.C. Ospedale “Vito Fazzi”, Lecce, Italy

Alessandro Barbarossa

Department of Cardiovascular Sciences, Cardiology and Arrhythmology Clinic, Marche University Hospital, Ancona, Italy

Alberto Cipriani

*Department of Cardio-Thoraco-Vascular Sciences and Public Health, University of Padua, Padua, Italy
Cardiology Unit, University Hospital of Padova, Padua, Italy*

Anna Cantone, Beatrice Dal Passo, Federico Sanguetoli, Rita Pavasini, Matteo Arzenton and Gianluca Campo
Cardiovascular Institute, Azienda Ospedaliero-Universitaria di Ferrara, Ferrara, Italy


Andrea Zaccaro and Emiliano Rossi
*Cardiology Unit, St. Orsola Hospital, IRCCS Azienda
Ospedaliero-Universitaria di Bologna, Bologna, Italy*

Gioele Fabbri, Enrico Monti and Carmine Pizzi
*U.O. Cardiologia, Ospedale di Forlì, AUSL della Romagna,
Forlì, Italy*

Erika Pedio
*U.O.C. Cardiologia e U.T.I.C. Ospedale "Vito Fazzi", Lecce,
Italy*

Federico Guerra
*Cardiology and Arrhythmology Clinic, Marche University Hos-
pital, Marche Polytechnic University, Ancona, Italy*

Giulio Sinigiani
*Department of Cardio-Thoraco-Vascular Sciences and Public
Health, University of Padua, Padua, Italy*
Cardiology Unit, University Hospital of Padua, Padua, Italy

Alberto Aimò and Michele Emdin 
*Interdisciplinary Center for Health Sciences,
Scuola Superiore
Sant'Anna, Pisa, Italy*
*Cardiology Division, Fondazione Toscana Gabriele Monasterio,
Pisa, Italy*

Francesco Cappelli and Federica Colio
*Tuscan Regional Amyloidosis Centre, Careggi University Hospi-
tal, Florence, Italy*

Simone Longhi
*Cardiology Unit, St. Orsola Hospital, IRCCS Azienda
Ospedaliero-Universitaria di Bologna,
Bologna, Italy*

Received 15 January 2026; revised 2 March 2026; accepted 30
March 2026