

Occupational asthma in a fruit and vegetables vendor

A. BALDASSARRE, S. DRAGONIERI*, V. LUISI**, MARINA MUSTI, L. VIMERCATI

Medicina del Lavoro "B. Ramazzini" – Dipartimento Interdisciplinare di Medicina – Università degli Studi di Bari "Aldo Moro"

* Malattie dell'Apparato Respiratorio – Università degli Studi di Bari "Aldo Moro"

** Unità Operativa Complessa Medicina del Lavoro – Azienda Ospedaliero-Universitaria Consorziale Policlinico di Bari

KEY WORDS

Pleurotus ostreatus; occupational allergy and asthma

PAROLE CHIAVE

Pleurotus ostreatus; allergia ed asma occupazionale

SUMMARY

Background: *This study presents a case report of a woman running a fruit and vegetables market stall, occupationally exposed to mushroom spores, who developed asthmatic symptoms. Basidiospores are allergens that can give rise to sensitization and subsequently trigger an allergic reaction, such as contact dermatitis, rhino-conjunctivitis, asthma and hypersensitivity pneumonitis. Methods:* A 40-year-old atopic woman, who had worked at a market stall selling fruit and vegetables for the past 26 years in a small town market in southern Italy, came to our attention at the Occupational Medicine Unit, complaining of a 3-year history of dyspnoea, cough, and wheezing during autumn and winter. **Results:** Spirometry showed a severe mixed type respiratory deficit with a significant bronchodilator response obtained with salbutamol administration. Skin prick tests to common aeroallergens were negative. Prick-to-prick test with fresh *Pleurotus ostreatus* was positive. We evaluated the size of the skin wheals and compared them to the positive control according to the Skin Index. An on-the-spot inspection of her store was performed and environmental conditions were identified that did not allow a satisfactory air exchange. **Conclusions:** The clinical history and the results of the allergologic investigations, plus an on-the-spot inspection, permitted us to ascertain that this subject had developed occupational asthma due to *Pleurotus ostreatus* spores. We advised her to stop handling and selling mushrooms, and she has no longer suffered asthmatic symptoms, over seven years of follow-up, and regularly continued to work without needing to take anti-asthma drugs.

RIASSUNTO

«**Asma occupazionale in una lavoratrice addetta al commercio al dettaglio di frutta e verdura**». **Introduzione:** Questo studio presenta un caso di una lavoratrice addetta al commercio al dettaglio di frutta e verdura, professionalmente esposta a funghi, che ha sviluppato sintomi asmatici. Le basidiospore sono allergeni che possono determinare sensibilizzazione e successivamente scatenare una reazione allergica, come dermatite da contatto, rinocongiuntivite, asma e polmonite da ipersensibilità. **Metodi:** Una donna di 40 anni, atopica, impiegata da circa 26 anni nel commercio ortofrutticolo, dapprima come ambulante e successivamente presso un piccolo negozio in un mercato cittadino del sud Italia, è venuta all'attenzione della nostra Unità Operativa di Medicina del Lavoro, lamentando dispnea e tosse negli ultimi 3 anni nel periodo autunnale ed invernale. **Risultati:** L'esame spirometrico ha evidenziato un deficit respiratorio severo di tipo misto, con una significativa broncodilatazione dopo somministrazione di salbutamolo.

Pervenuto il 7.12.2015 - Revisione pervenuta il 3.2.2016 - Accettato il 29.2.2016

Corrispondenza: Antonio Baldassarre, Medicina del Lavoro "B. Ramazzini", Dipartimento Interdisciplinare di Medicina, Università degli Studi di Bari "Aldo Moro", Piazza Giulio Cesare 11, 70124 Bari - Tel. + 39 392 1686690 - Fax + 39 080 5478370

E-mail: antonio.baldassarre@uniba.it

*Gli Skin Prick Test sono risultati negativi ai comuni aeroallergeni. Il test Prick-to-prick con il fungo fresco Pleurotus ostreatus è risultato positivo. Abbiamo valutato le dimensioni dei pomfi cutanei, comparati con il controllo positive secondo lo Skin Index. Il sopralluogo del negozio ortofrutticolo ci ha consentito di verificare condizioni ambientali che non garantiscono un sufficiente ricambio d'aria. **Conclusioni:** La storia clinica ed i risultati degli accertamenti clinico-strumentali, unitamente ad un sopralluogo dell'ambiente di lavoro, ci ha permesso di diagnosticare un'asma professionale dovuta a spore di Pleurotus ostreatus. Non manipolando e non vendendo più funghi, come da noi consigliato, la lavoratrice gode a tutt'oggi di buone condizioni di salute.*

This study presents a case report of a woman working at a market stall selling fruit and vegetables, occupationally exposed to mushroom spores, who developed asthmatic symptoms.

Basidiomycetes, the most morphologically advanced of the fungi, include mushrooms, puffballs, bracket fungi and toadstools; *Pleurotus* species are characterized by a white spore print, attached to decurrent gills, often with an eccentric (off-center) stipe, or no stipe at all. They always grow on wood in nature, usually on dead standing trees or on fallen logs. *Pleurotus ostreatus*, a culinary-medicinal oyster mushroom, is one of the main edible basidiomycetes.

Pleurotus ostreatus is a white-rot wood decay fungus that has mycelia which kill and digest nematodes as a nitrogen source. It is commonly used in oriental stir-fry cooking as a delicacy, and also as a substitute for polystyrene packing and insulation material.

Basidiospores are allergens that can give rise to sensitization and subsequently trigger an allergic reaction, such as contact dermatitis, rhinoconjunctivitis, asthma and hypersensitivity pneumonitis (1, 3-5, 7, 8).

In 2008, a 40-year-old atopic woman, who had worked at a market stall selling fruit and vegetables for the past 26 years in a small town market in southern Italy, came to our attention at the Occupational and Preventive Medicine.

In the previous 3 years, during autumn and winter she had suffered dyspnoea, coughing, and wheezing.

She was hospitalized several times, with a discharge diagnosis of allergic bronchial asthma. Allergic sensitization was demonstrated to dust mites, grass and olive trees.

Several episodes requiring hospitalization followed over the next 10 years, and she was prescribed

bronchodilators and Allergen-specific immunotherapy (hyposensitization) against *Olea europaea* (olive) and *Dermatophagoides pteronyssinus*, but showed little benefit in terms of the prevention or reduction of symptoms.

During autumn 2006, after transferring her business as street vendor to a small local store (15 square metres), she suffered a further worsening of the respiratory deficit.

In 2008 she was hospitalized in day-hospital regimen at the Division of Occupational Medicine and discharged with a diagnosis of bronchial asthma due to exposure to edible mushroom spores.

She had not connected her respiratory symptoms to her working conditions and environments, and she continued to work during the assessment of her clinical conditions. She could eat all foodstuffs without any ill effects.

The blood tests revealed marked eosinophilia in the differential count (19.6%, normal range 2-3%). Chest radiography was normal.

Spirometry showed a severe obstructive type respiratory deficit: FVC 1.4 L (44.5% theoretical value - t.v.), FEV1 0.95 L (35% t.v.), PEF 3.74 L/s (57.9% t.v.), FEV1/FVC% 67.8% (82.9% t.v.). A significant bronchodilator response was obtained with 400 µg salbutamol administration: FVC 2.2 L (70% t.v.) FEV1 1.7 L (62.7% t.v.), PEF 4.6 L/s (71% t.v.), FEV1/FVC% 77.2% (94.4% t.v.).

All respiratory function tests were performed by the same operator, the patient in sitting position with her nose closed by a clip, following the American Thoracic Society (ATS) Guidelines.

Skin prick tests to common aeroallergens were negative (including common environmental molds like *Aspergillus fumigatus*, *Alternaria alternata*, *Penicillium notatum*, and *Candida albicans*), *Dermatophagoides farinae* and *Dermatophagoides pteronissinus*.

Prick-to-prick test with fresh *Pleurotus ostreatus* was positive (+++). We ran the test using the fresh mushroom *Pleurotus ostreatus*. The test is currently performed by scarifying, or by dipping the lancet in the food, and then directly pricking the patient’s skin. The patient was in clinical remission, symptom-free for at least 4 weeks and not taking antihistamines and corticosteroids for at least one week.

The test took a few minutes and subsequent reading of the skin reaction was carried out after 15 minutes, objectively assessing the size of skin wheals. We kept patient under observation for at least one hour after the end of the diagnostic procedure, to monitor the possible occurrence of local or systemic adverse events.

As positive control we used Histamine 6.0 mg/mL that is a clear, colourless, sterile solution. It consists of Histamine dihydrochloride 10 mg/mL, Sodium chloride 0.5%, Sodium bicarbonate 0.275%, and Glycerin 50.0% (v/v) as a preservative.

For the negative control we used a Sterile 50% (v/v) Glycerine dilution.

We evaluated the size of the skin wheals and compared them to the histamine dihydrochloride reaction (positive control) according to the Skin Index (table 1).

ImmunoCAP IgE tests were positive to Cat dandruff (1.41 kUA/l), *Aspergillus fumigatus* (1.23 kUA/l), Kiwi (0.9 kUA/l), *Cladosporium herbarum* (0.8 kUA/l), *Penicillium notatum* (0.55 kUA/l), Loglierella (0.55 kUA/l), Mushrooms (champignon 0.51 kUA/l), Latex (0.23 kUA/l), Dog dandruff (0.16 kUA/l); ImmunoCAP total IgE resulted 3065 kU/l.

Serum was sampled and sent to the R&D Department-Bial-Aristegui of Bilbao for EAST (En-

zymatic Allergo Sorbent Test) testing for the specific IgE levels to *Pleurotus ostreatus*, that uses a colorimetric signal rather than the radioactive signal of the RAST test.

To measure the specific IgE levels against *Pleurotus ostreatus* four different kinds of protein extracts were used: the first from the *Pleurotus ostreatus* spores, a home-made *Pleurotus ostreatus* spore extract (10% w/v) (Bial-Aristegui, Bilbao, Spain), and the other three were obtained using samples collected from different parts of the climate control system of the *Pleurotus ostreatus* cultivation room (inflow air duct, outflow air duct and ventilator sample) with an air sampler (Air Sentinel).

Basidiospores were obtained from basidiocarps and, within 4 to 6 hours of harvesting each basidiocarp was set up for spore collection.

The mushroom cap was placed, hymenial surface down, on Whatman No. 1 filter paper and covered with either filter paper or aluminum foil to retain high humidity and reduce airflow to obtain the spore print. After 24 to 48 hours, the caps were removed, and the resulting spore deposits were harvested by scraping the filter paper gently with a spatula. They were eluted with ion-depleted water and lyophilized. Spores were suspended in 0.125 mol/L of ammonium bicarbonate buffer, pH 8.1, and homogenized in a Braun homogenizer. The homogenate was then centrifuged (70.000 g), and the supernatant was lyophilized, to maintain the allergenic potency of the extract. The dry weight of each spore extract was finally adjusted with diluent (2, 7, 8).

Table 2 shows the results of the EAST tests, which demonstrated extremely high serum IgE levels against *Pleurotus ostreatus* spores (100 kU/L, Class 4) (6).

Table 1 - Skin wheals evaluation

| Size | Reaction | Skin wheals compared to histamine reaction | Result |
|----------|----------|--|----------|
| < ¼ cm | - | equal to negative control | Negative |
| ¼ - ½ cm | + | From ½:1 to ¼:1 compared to histamine dihydrochloride reaction | Negative |
| ½ - 1 cm | ++ | Up to ½:1 compared to histamine dihydrochloride | Negative |
| 1 - 2 cm | +++ | From 1:1 to 2:1 compared to histamine dihydrochloride | Positive |
| > 2 cm | ++++ | > 2:1 to 4:1 or more compared to histamine dihydrochloride | Positive |

Table 2 - EAST test results

| N. | Allergenic Source (Protein extracts) | Specific IgE level Serum | |
|--------------------------|---|-----------------------------|-------|
| | | kU/L | Class |
| <i>Pleurotus</i> samples | | | |
| 1 | Spores (10% w/v) | 100 | 4 |
| 2 | Inflow air duct | 9,6 | 3 |
| 3 | Outflow air duct | 15,2 | 3 |
| 4 | Ventilator | 6,2 | 3 |

Immuno-blotting performed with the spore extracts revealed IgE-binding bands, ranging from ~22 to ~90 kDa. Immuno-blotting- inhibition studies were carried out using the air sample extract as the solid phase. A specific IgE-binding (~67 kDa) band, present in the negative control, disappeared when the serum was pre-incubated with spore extracts.

Peak Expiratory Flow (PEF) was recorded four times a day, fifteen days prior to the cessation of exposure to *Pleurotus ostreatus* spores at work and, out of work, in the following days with therapy administration. This evaluation revealed a marked improvement in lung function, further confirming the laboratory findings (figure 1).

An on-the-spot inspection of her store was performed and environmental conditions were identi-

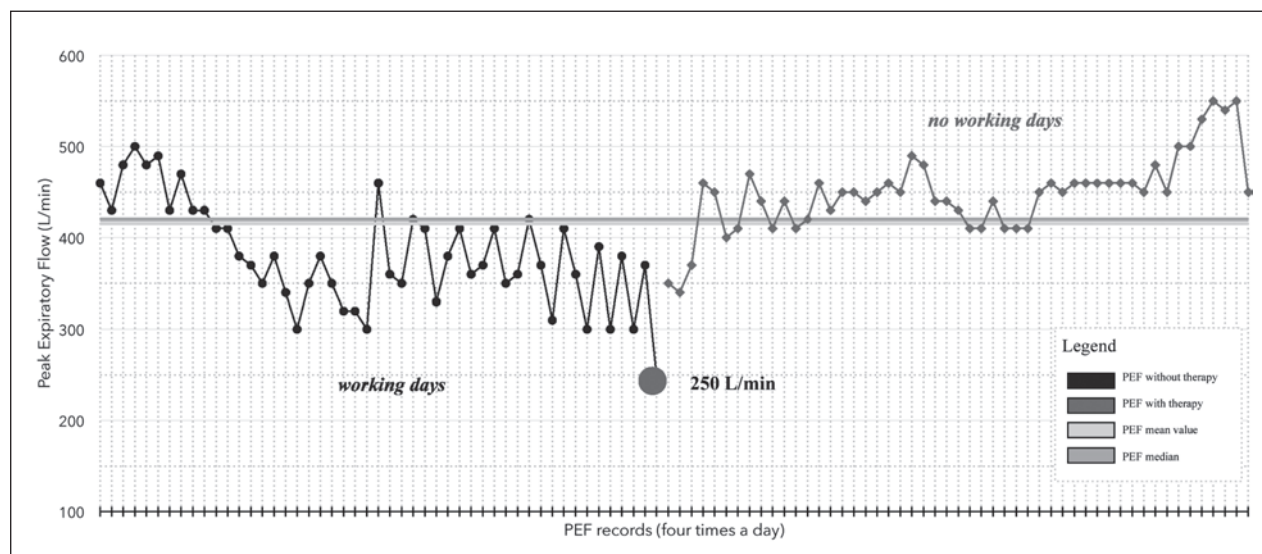
fied that did not allow a satisfactory air exchange, namely windows unsuitable for air circulation and no ventilation systems.

After our diagnosis, and complying with the suggestion to avoid selling mushrooms, over the following 7 years of follow-up, the patient no longer suffered asthmatic symptoms and regularly continued to work without needing to take anti-asthma drugs. Nevertheless, we advised her to keep bronchodilators with her in case of need.

In conclusion, the clinical history and the results of the allergologic investigations permitted us to ascertain that this subject had developed occupational asthma due to *Pleurotus ostreatus* spores, which has rarely been reported in the literature.

The importance of this report lies in the difficulty of diagnosis, as illustrated by the failure of the Pulmonary Diseases units to make an accurate diagnosis in the 3 years before our observation, stressing the crucial role played by the Occupational Medicine in establishing the diagnosis and taking over the management of the health and safety of this worker.

The diagnosis made it possible to take action in terms of prevention of the onset, and hence no exacerbation, of symptoms, by totally refraining from handling and selling mushrooms.

**Figure 1** -

NO POTENTIAL CONFLICT OF INTEREST RELEVANT TO THIS ARTICLE WAS REPORTED

REFERENCES

1. Helbling A, Reese G, Horner WE, Lehrer SB: Current aspects of fungal spores allergy. *Schweiz Med Wochenschr* 1994; *124*: 885-892
2. Horner WE, Ibanez MD, Liengswangwong V, et al: Characterization of allergens from spores of the oyster mushroom, *Pleurotus ostreatus*. *J Allergy Clin Immunol* 1988; *82*: 978-986
3. Mori S, Nakagawa-Yoshida K, Tsuchihashi H, et al: Mushroom worker's lung resulting from indoor cultivation of *Pleurotus ostreatus*. *Occup Med* 1998; *48*: 465-468
4. Rosina P, Chierigato C, Schena D: Allergic contact dermatitis from *Pleurotus* mushroom. *Contact Dermatitis* 1995; *33*: 277-278.
5. Saikai T, Tanaka H, Fuji M, et al: Hypersensitivity pneumonitis induced by the spore of *Pleurotus eryngii* (Eringi). *Intern Med* 2002; *41*: 571-573
6. Vereda A, Quirce S, Fernández-Nieto M, et al: Occupational asthma due to spores of *Pleurotus ostreatus*. *Allergy* 2007; *62*: 211-212
7. Weber NS, Smith AN: A field guide to southern mushrooms. Ann Arbor, Mich, University of Michigan Press, 1985: 280
8. Weissman DN, Halmepuro LJ, Salvaggio E, Lehrer SB: Antigenic/allergenic analysis of basidiomycete cap, mycelia, and spore extracts. *Int Arch Allergy Appl Immunol* 1987; *84*: 56-61.

ACKNOWLEDGEMENTS: Authors wish to thank Borja Bartolomé, MD, and the staff of R&D Department-Bial-Arístegui of Bilbao