

See discussions, stats, and author profiles for this publication at: <https://www.researchgate.net/publication/329887045>

Giant myxoid neurofibroma of the hip causing bone erosion: A case report

Article in *Clinical Cases in Mineral and Bone Metabolism* · May 2018

DOI: 10.11138/ccmbm/2018.15.2.271

CITATIONS

0

READS

38

6 authors, including:



Federico Sacchetti

Università di Pisa

24 PUBLICATIONS 2 CITATIONS

[SEE PROFILE](#)



Marco De Gori

Università degli Studi "Magna Græcia" di Catanzaro

28 PUBLICATIONS 193 CITATIONS

[SEE PROFILE](#)



Antonio D'Arienzo

Università di Pisa

28 PUBLICATIONS 76 CITATIONS

[SEE PROFILE](#)



Stefano Grossi

Università di Pisa

6 PUBLICATIONS 0 CITATIONS

[SEE PROFILE](#)

Some of the authors of this publication are also working on these related projects:



Foot and Ankle [View project](#)



tka planning [View project](#)

Giant myxoid neurofibroma of the hip causing bone erosion: a case report

Federico Sacchetti¹
 Marco De Gori^{1,2}
 Antonio D'Arienzo¹
 Stefano Grossi¹
 Fabio Cosseddu¹
 Rodolfo Capanna¹

¹ Department of Orthopaedic and Trauma Surgery, University of Pisa, Italy

² Department of Orthopaedic and Trauma Surgery, "Magna Graecia" University of Catanzaro, Italy

Address for correspondence:

Federico Sacchetti
 Department of Orthopaedic and Trauma Surgery
 University of Pisa
 Via Paradisa 2
 56124 Pisa, Italy
 E-mail: federico.sacchetti1989@gmail.com

Summary

Myxoid neurofibroma (MN) is a rare tumor originating from the nerve sheet.

It commonly occurs as a solitary cutaneous or subcutaneous mass within 5 cm of diameter; deep-seated lesions are extremely rare, unless they are associated to neurofibromatosis. We report a case of a deep-seated, sporadic, giant MN of the hip causing bone erosion. The patient was asymptomatic, being the diagnosis incidental. A soft tissue sarcoma was initially suspected on imaging basis, and the diagnosis of MN was finally carried out with a core specimen biopsy. Due to its unusual features, a total hip prosthesis is planned in order to obtain complete excision of the mass.

KEY WORDS: orthopedics; oncology; neurofibromas; bone erosion.

Introduction

Myxoid neurofibroma (MN) is a benign cutaneous or subcutaneous tumor originating from the nerve sheet. In its most frequent presentation, neurofibroma occurs as a solitary cutaneous or subcutaneous mass, that peaks between the third and fourth decades of life; still very unusual ones can be found in deep seated positions of the extremities (1). Unusual variants, i.e. massive and plexiform neurofibromas, can be

described as deep lesions but exclusively associated with neurofibromatosis (NF) with nearby tissues infiltration (4, 5). Clinical presentation of localized neurofibromas usually consists of a painless slow growing mass. On magnetic resonance imaging (MRI), myxoid neurofibroma usually appears as a fusiform well defined mass that not exceed 5 cm in diameter. Sometimes, a continuity with neural structure can be seen in masses arising from the major nerves; *fascicular* and *target* signs are usually seen. Atrophy of muscle depending on the nerve involved in the lesion is not uncommon. On contrast-enhanced images, major lesion can show central, peripheral or non-homogeneous contrast enhancement (2, 3, 6). We report a case of a deep-seated, sporadic, giant MN of the hip causing bone erosion.

Case presentation

A 73-year-old male was admitted to our Institution following the accidental detection of a mass of his left thigh, discovered on MRI assessment prior to prostatectomy. Patient's medical, developmental, and family histories were likewise unremarkable; the patient showed no sign of NF, nor satisfied clinical criteria for NF diagnosis (7). MRI showed a 145×76×67mm mass located in the anterolateral aspect of the hip, seated in a deep, juxta-articular position, with an isointense signal to muscle on T1-weighted images, a non-homogeneous high signal on T2-weighted images, and a non-homogeneous contrast enhancement (Figures 1, 2, 3). The neoplasm was seated laterally to the iliopsoas tendon, posteriorly to the rectus femoris muscle, medially to the vastus lateralis muscle and anteriorly to the femoral diaphysis; proximal third of the vastus intermedius muscle appeared to be involved by direct invasion or reactive edema. The mass surrounded the left femoral neck causing its thinning and a cortical erosion, thus suggesting an aggressive soft tissue sarcoma.

Computed tomography (CT) scans showed a solid mass with intense contrast enhancement resulting in a thinned femoral neck and anterior cortical thickening referred to periosteal reaction (Figure 4), and bone scintigraphy showed an uptake on the left femoral neck (Figure 5). A reactive synovitis of the hip was also suspected. A core specimen biopsy was then performed, and histological examination showed a MN. Such result was discussed with the patient, and both risks and benefits of a surgical treatment were considered. A complete excision of the mass was therefore proposed, together with a total hip arthroplasty.

Discussion

We report an exceptional case of isolated, deep-seated MN that was not associated to NF1 and caused erosion of the

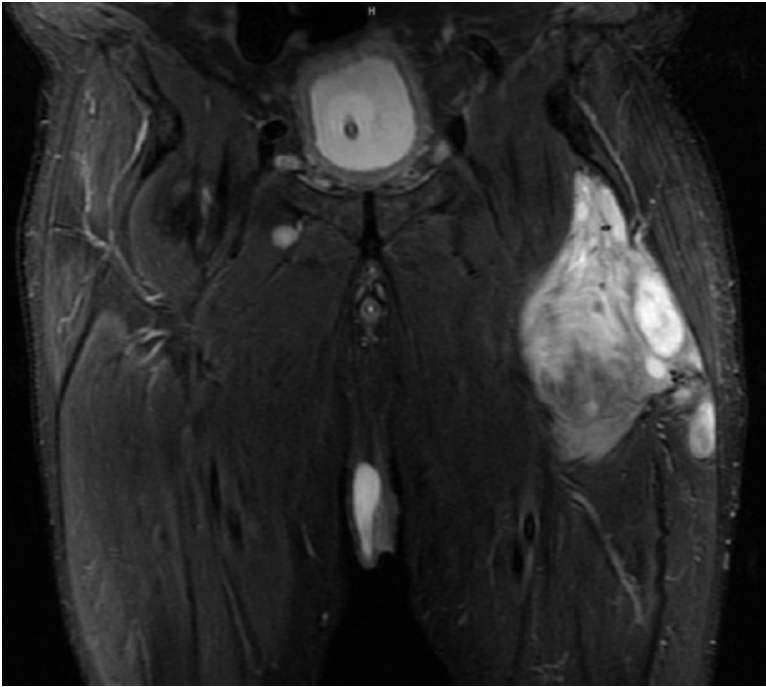


Figure 1 - Mass on MRI, we can see great dimensions, deep position and vastus intermedius involvement (coronal STIR images).

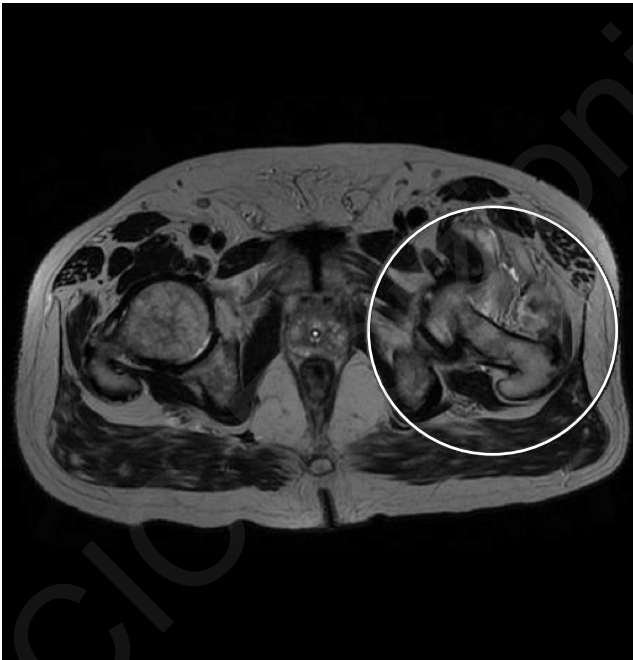

Figure 2 - Stick appearance of femoral neck on MRI. T2 weighted images.

contiguous bone. Overall, 22 cases of isolated MNs have been reported to date (Table 1), but to the best of our knowledge only 3 of them were seated in a deep position (8, 19, 21). In all reviewed cases (8-21), surgical excision was treatment of choice, in two of them recurrence was reported (10, 19), in one case due to incomplete excision.

Two distinctive characteristics of our case are noteworthy. First, as far as we know this is the very first case of MN of

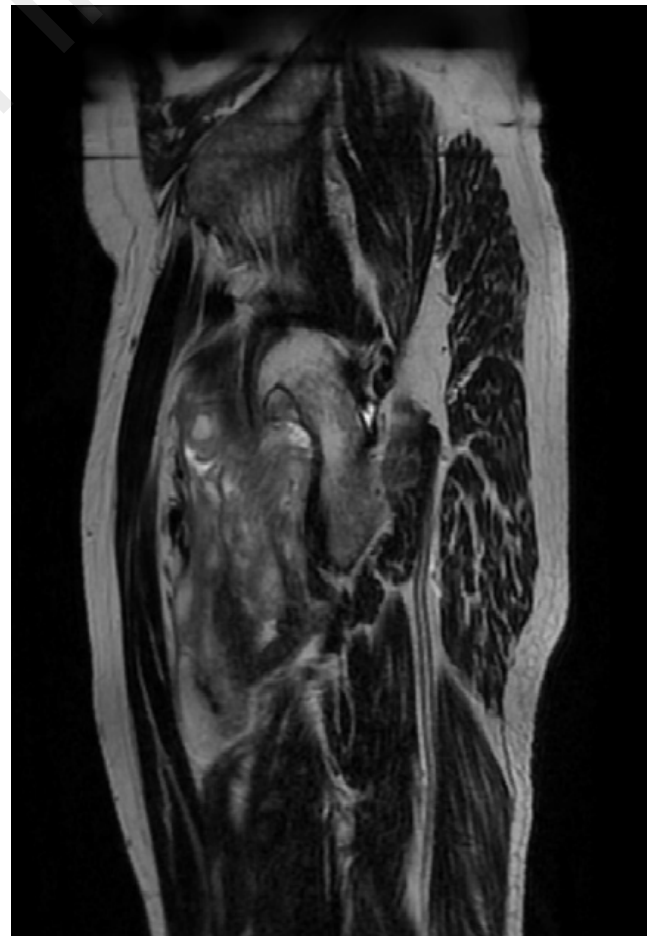


Figure 3 - Sagittal T2 FRFSE sequence: circumferential thinning of femoral neck caused by mass compression.

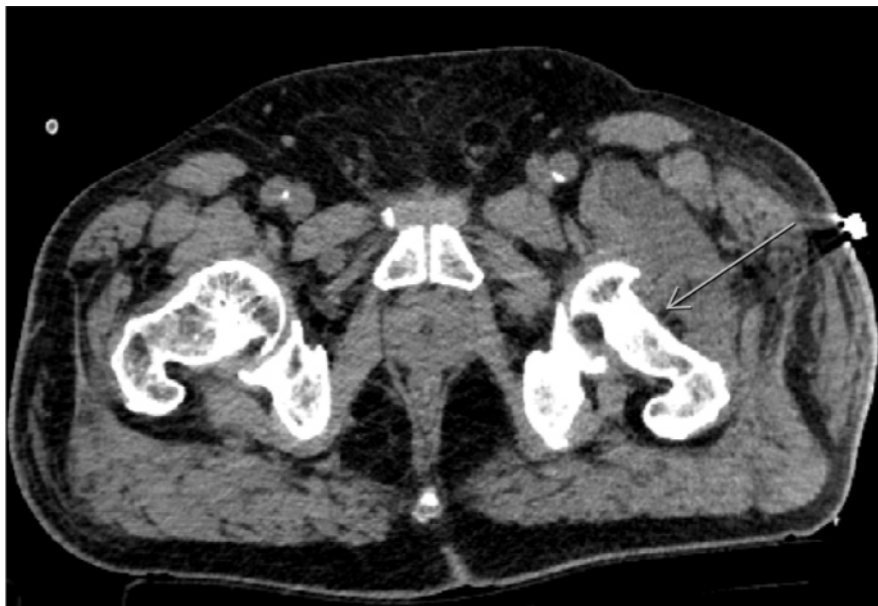

Figure 4 - Axial TC image where we can observe femoral neck thinning (arrow).

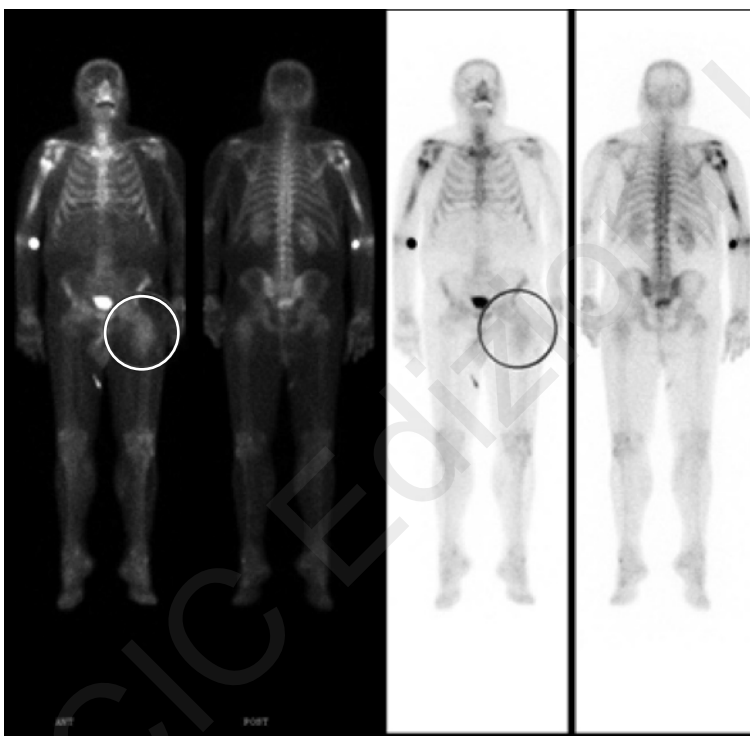

Figure 5 - Bone scintigraphy: uptake of left hip.

the hip even described. Moreover, this is a giant, 14-cm-long, MN, still the current available literature often refers to 5 cm as the maximum theoretical size of sporadic MNs (3). Bone erosion was reported in only one article (8), in which an intramuscular growth of a forearm MN was described; however, since no imaging is available, no further, exact data about bone involvement were provided. Differently, our radiological findings of complex, circumferential bone involvement with femoral neck deformation are extremely unusual, since sporadic MN usually is a well-defined mass that does

not infiltrate nearby tissues. For the ongoing reason, our original suspicion diagnosis was inclined to a locally aggressive soft tissue sarcoma; so, our experience suggests that a “stick” femoral neck and aggressive bone invasion can also be associated to MN. Therefore, due to its variety, MN should be considered in the differential diagnoses of a large scale of clinical and radiological masses presentation. Data about this very rare and aggressive MNs should be collected in specialized centers to get more information about treatment and outcomes of this kind of neoplasms.

Table 1 - Cases of isolated MNs reported in literature.

Title	Authors	Site	Bone erosion	Treatment	Results
Myxoid neurofibroma treated with Mohs micrographic surgery.	Trieu D et al, 2015	Skin/nose	NO	Surgical Excision (SE)	12 months Follow Up (FU) No recurrences (NR)
Solitary Myxoid Neurofibroma of the Palm.	Kane PM et al, 2015	Hand	NO	SE	12mFU NR
Myxoid neurofibroma of the thumb.	Hocar O et al, 2012	Thumb	NO	SE	18M FU NR
Solitary myxoid neurofibroma of the soft palate.	Choi JS et al, 2011	Palate	NO	SE	nd
Myxoid Neurofibromas of the External Ear Canal: A Case Report.	Maryam YK et al, 2015	Ext. ear canal	NO	SE	nd
Myxoid neurofibroma in a child. An asymptomatic nodule on the finger.	Patrizi A et al, 2011	Skin	NO	nd	nd
Solitary Giant Intramuscular Myxoid Neurofibroma Resulting in an above Elbow Amputation.	Chennakeshaviah G et al, 2012	Humerus	YES	amputation	nd
Isolated neurofibroma of the orbit with extensive myxoid changes: a clinicopathologic study including MRI and electron microscopic findings.	Kottler UB et al, 2004	Orbit	NO	SE incomplete?	24mFU Stable remnant
Periungual myxoid neurofibroma.	Gmyrek RF et al, 2002	Skin	NO	SE	nd
Myxoid neurofibroma of the testis.	Livolsi VA et al, 1977	Testis	NO	SE	12 m FU No recurrences
A rare tumor of the sciatic nerve-myxoid neurofibroma. A case report.	Smola MG et al, 1992	Sciatic nerve	NO	SE	24m FU No recurrences
Unusual form change of the nasal tip. Solitary, myxoid neurofibroma of the nasal tip.	Karapantzos I et al, 1999	Nasal tip	NO	nd	nd
Myxoid neurofibroma of the renal sinus.	Borrego J et al, 1995	Renal sinus	NO	SE proposed	
Subungual myxoid neurofibroma on the thumb.	Baran R et al, 2001	Finger subungueal	NO	SE	nd
Myxoid neurofibroma of the nasal vestibule.	Knaster J et al, 1985	Nasal vestibule	NO	nd	nd
Periurethral myxoid neurofibroma.	Eidelman A et al, 1981	Periurethral	NO	SE	1 recurrence 48 months No recurrence 72 months recurrence
Myxoid neurofibroma: an unusual presentation.	Ponce-Olivera RM et al, 2008		NO	SE incomplete	
Nerve sheath myxoma of the hyponychium.	Cribier B et al, 2013	Fingernail	NO	SE	nd
A rapidly growing benign intrathoracic neurofibroma after lung lobectomy.	Maeda M et al, 2000	Intrathoracic	NO	SE	12mFU NR
Benign peripheral nerve sheath tumors (neurofibromas) of the lacrimal gland.	McDonald P et al, 1983	2 cases Lacrimal gland	NO	1 SE 2 SE	1: 24mFU NR 2: nd

References

- Graadt Van Roggen JF, Hogendoorn PCW, Fletcher CDM. Myxoid tumours of soft tissue. *Histopathology*. 1999;35(4):291-312. <http://doi.org/10.1046/j.1365-2559.1999.00835.x>.
- Woertler K. Tumors and Tumor-Like Lesions of Peripheral Nerves. *Seminars in Musculoskeletal Radiology*. 2010;14(5):547-558.
- Petscavage-Thomas JM, Walker EA, Logie CI, Clarke LE, Duryea DM, Murphey MD. (3441). Soft-Tissue Myxomatous Lesions: Review of Salient Imaging Features with Pathologic Comparison. 1:964-981. <http://doi.org/10.1148/rg.344130110>.
- Pinheiro FS, Rothner AD, Moodley M, Zahka KG. Massive Soft Tissue Neurofibroma (Elephantiasis Neuromatosa): Case Report and Review of Literature. *Journal of Child Neurology*. 2015;30(11):1537-1543. <http://doi.org/10.1177/0883073815571635>.
- Korf BR. Plexiform neurofibromas. *Am J Med Genet*. 1999 Mar 26;89(1):31-37.
- Walker EA, Fenton ME, Salesky JS, Murphey MD. Magnetic resonance imaging of benign soft tissue neoplasms in adults. *Radiol Clin North Am*. 2011 Nov;49(6):1197-1217, vi. doi: 10.1016/j.rcl.2011.07.007.
- Weiss SW, Goldblum JR. *Enzinger and Weiss, Soft Tissue Tumours*. 4th edition. St. Louis, Mo, USA: Mosby-Harcourt Health Sciences Company.

8. Gururajaparasad Chennakeshavia, Sunila Ravishankar, Rangaswamy Maggad, Manjunath GV. Solitary Giant Intramuscular Myxoid Neurofibroma Resulting in an above Elbow Amputation. Hindawi Publishing Corporation Case Reports in Pathology. Volume 2012. Article ID 353215, 3 pages doi: 10.1155/2012/353215.
9. Koosha MY, Daud MK, Hamdan AH. Myxoid Neurofibromas of the External Ear Canal: A Case Report. 2015;70(2):102-103.
10. Tirado-Sanchez A, Peniche-Castellanos A, Peniche-Rosado J, Mercadillo-Perez P, Ponce-Oliviera R. Myxoid neurofibroma: An unusual presentation. Indian Journal of Dermatology. 2008. <https://doi.org/10.4103/0019-5154.39742>.
11. Hocar O, Madhar M, Akhdari N, Rais H, Belaabidia B, Fikry T, Amal S. Neurofibrome myxoïde du pouce. Chirurgie de La Main. 2012;31(4):217-219. <https://doi.org/10.1016/j.main.2012.07.007>.
12. Kane PM, Gaspar MP, Rekant MS. Solitary Myxoid Neurofibroma of the Palm. Journal of Hand and Microsurgery. 2015;7(December):8-11. <https://doi.org/10.1007/s12593-015-0200-8>.
13. Histiocytoma F, Bilici S, Yigit O, Taskin U. Recurrence of a Simultaneous Tumor of the Parotid Gland and Scalp Skin Malignant Brucella melitensis Infection Within Warthin Tumor of the Parotid Gland. 2011;22(5):1898-1979. <https://doi.org/10.1097/SCS.0b013e31822ea630>.
14. Mcdonald P, Jakobiec FA, Hornblass A, Iwamoto T. Benign Peripheral Nerve Sheath Tumors (Neurofibromas) of the Lacrimal Gland. Ophthalmology. 1983;90(12):1403-1413. [https://doi.org/10.1016/S0161-6420\(83\)34365-34367](https://doi.org/10.1016/S0161-6420(83)34365-34367).
15. Results AR, Surg CM. (n.d.). Myxoid Neurofibroma Treated With Mohs Micrographic Surgery. American Society for Dermatologic Surgery. 166-168.
16. Cribier B, Baran R, Varini J. Myxome des gaines nerveuses de l'hyponychium Nerve sheath myxoma of the hyponychium. Annales de Dermatologie et de Venereologie. 2013;140(8-9):535-539. <https://doi.org/10.1016/j.annder.2013.04.074>.
17. Kottler UB, Conway RM, Schlötzer-Schrehardt U, Leonard M, Conway RM, Schlötzer-Schrehardt U, Holbach LM. Isolated neurofibroma of the orbit with extensive myxoid changes: A clinicopathologic study including MRI and electron microscopic findings Case report Isolated neurofibroma of the orbit with extensive myxoid changes: A clinicopathologic study including MRI and electron microscopic findings. 2009;6830 (September 2015). <https://doi.org/10.1076/orbi.23.1.59.28993>.
18. Report C. Subungual Myxoid Neurobroma on the Thumb * Lichen Sclerosus et Atrophicus Appearing in Old Scars of Burns from Welding Sparks. 2001:2-4.
19. Eildeman A, Reif R. Periurethral myxoid neurofibroma. The journal of Urology. 1981; 0022-5347/81/1255-0746\$02.00/0.
20. Virginia A. Livolsi, Martin Schiff. Myxoid Neurofibroma of the testis. The journal of Urology. 1977;vol 118.
21. Smola Von MG, Ratschek M, Hoflehner H. A rare tumor of the sciatic nerve-myxoid neurofibroma. A case report. Handchir Mikrochir Plast Chir.1992 Mar;24(2):84-87.