



Radiofrequency on the liver remnant after liver resection to reach the haemostasis not otherwise achievable with conventional techniques



Benedetta Pesi^{a,*}, Francesca Leo^a, Gadiel Liscia^a, Giovanni Alemanno^a, Daniela Zambonin^a, Massimo Falchini^b, Giacomo Batignani^a

^a Digestive Surgery Unit, Department of Surgery and Translational Medicine, University of Florence Medical School, Careggi University Hospital, Florence, Italy

^b Diagnostic and Interventional Radiology Unit, University of Florence Medical School, Careggi University Hospital, Florence, Italy

ARTICLE INFO

Article history:

Received 14 February 2013

Accepted 18 February 2013

Available online 4 April 2013

Keywords:

Radiofrequency

Haemostasis

Liver resection

Intra-operative bleeding

ABSTRACT

INTRODUCTION: During liver resection, in some case of inflamed, steatotic or neo-vascularized liver parenchyma, reaching of haemostasis on the liver resection surface could be very difficult for the surgeon because of the presence of fragile tissue that does not allows the proper placement of stitches, and the conventional method fail.

PRESENTATION OF CASE: The authors describe a novel technique in which, after a formal liver resection, liver haemostasis is achieved using radiofrequency energy on the resected surface. A patient affected by a hystiocytic sarcoma localized on the VI-V and IVa segments was scheduled for liver resection. During the resection a diffuse bleeding from the resected surface started with little success obtained with conventional method. So we decided to use the coagulative necrosis generated by the radiofrequency, using a cool type cluster needle, hand-piece with 3 needle, bending 2 needles in a way resembling a "fork", to reach a complete and definitive haemostasis.

DISCUSSION: Haemostasis remains a critical issue in liver surgery not only for the catastrophic effect of haemorrhage but also because it is correlated to complications rate and to survival. The coagulative necrosis generated by the radiofrequency could be used to facilitate the creation of a necrotic plane to be transected.

CONCLUSION: The use of the radiofrequency energy, delivered through needles, is suggested when the conventional techniques fail to reach a proper haemostasis after a liver resection or, to consider its use, prior to resect the liver in presence of fragile parenchyma.

© 2013 Surgical Associates Ltd. Published by Elsevier Ltd. All rights reserved.

1. Introduction

Haemostasis on the liver resection surface is usually achieved using suture ligations, clips, coagulation (either mono or bipolar), argon beam coagulation and haemostatic agents in many preparations such as sponge, powder or sealant glue.

When proper haemostasis can not be achieved a mattress suture or "u" stitches using pledges that compress the parenchyma may be used.

On a normal liver texture or even in presence of a cirrhotic liver, post-resection haemostasis is usually achieved using the above mentioned techniques. Some cases, most rare, of inflamed, steatotic or neo-vascularized liver parenchyma may represent a challenge for the surgeon in order to obtain a proper haemostasis after a liver resection. The engorged fragile tissue in fact, does not allow

conventional placement of sutures in these situations and the others techniques may fail as well, despite their correct utilization.

Recently a new kind of bloodless liver resection has been described using radiofrequency (RF) energy delivered in the liver parenchyma by means of cooled-tip needles.¹ RF is able to seal all kinds of vessels and bile-ducts near the needle tip then, if multiple needles are placed in row, a necrotic plane may be created where a scalpel may cut through in a bloodless field.^{2,3}

We describe here a novel technique in which the post-resection liver haemostasis is achieved using RF energy on the resected surface.

2. Presentation of the case

A 69 years old man affected by a hystiocytic sarcoma with multiple liver tumours localized on the anterior segments (VI-V and IVa) was scheduled for liver resection. On the opening of the abdomen through a bilateral subcostal incision we performed a Pringle manoeuvre resecting the affected segments as for an anterior hepatectomy using Kelly-crush technique using silk tie and clips. After the releasing of the clamps for liver reperfusion after an

Abbreviation: RF, radiofrequency.

* Corresponding author at: Careggi Hospital, Digestive Surgery Unit, Largo Brambilla 3, 50134 Florence, Italy. Tel.: +39 055 7947449; fax: +39 055 7947449.

E-mail address: benedettaps@gmail.com (B. Pesi).

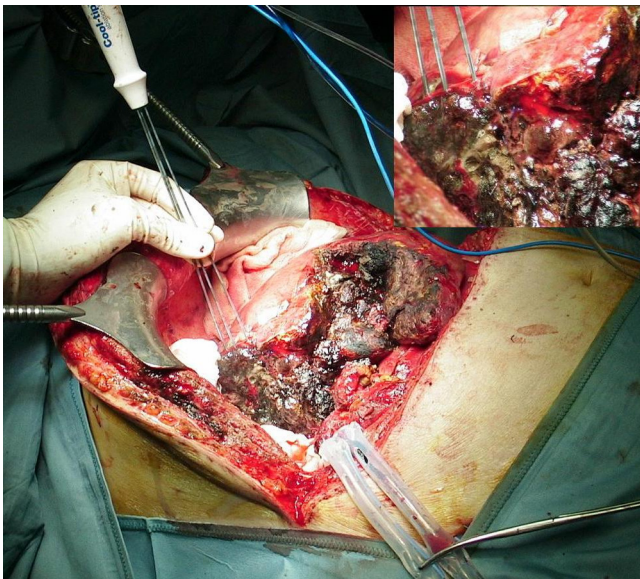


Fig. 1. Intra-operative view of the radiofrequency energy delivered on the resected surface by means of a hand-piece multiple needles bent in a way resembling a “fork”.

ischaemia time of 30 min, a diffuse bleeding from the resected surface started with little success obtained with conventional method such as prolene stitches, argon beam coagulation, coagulator agents and glues. A Pringle manoeuvre lasting 5 min was re-used twice in order to better place the stitches. The manoeuvre was followed by 10 min of de-clamping time. Since bleeding was ongoing we decided to perform a packing that was removed 48 h later. At re-operation there was no blood in the abdominal cavity but after the removal of the packing the resected surface started to bleed again. We decided then to resect also the right posterior segments where the bleeding seemed to come from, completing a formal right hemihepatectomy. Legating and cutting the right hepatic artery, and right hepatic vein. The parenchyma belonged to segment VII and VIII was then removed using Kelly-crush technique legating and clipping small vessels in the main fissure under Pringle manoeuvre lasting 20 min. Upon reperfusion we were in the same conditions as in the previous procedure because of the continuous bleeding from the resected surface. We used again stitches, argon beam and coagulants/glue without definitive bleeding control. This time it was possible to place a row of “U” stitches through the liver parenchyma 1 cm. apart from the resected surface. The “U” stitches were placed using PTFE pledges that, when tied, compressed the parenchyma. With this technique the bleeding reduced but did not stop and for this reason we had to pack again the liver. At this point, we decided to use a radiofrequency for tissue coagulation and for this purpose we used a cool type cluster needle (RF-cool type needle, Valleylab, USA) hand-piece with 3 needle, bending 2 needles in a way resembling a “fork” with every needle spaced from 1 cm apart from the other (Fig. 1).

Needle were connected to a radiofrequency generator (Cool Tip RF system, Valleylab, USA) with energy output ranging from 0 to 200 Watts. Automated algorithm of energy output is modulated on tissue impedance variation; increasing impedance related to reduce energy delivered.

The tip of the needle is maintained cooled by continuous saline perfusion to preserve tissue from scarring with optimal energy diffusion to the surrounding tissue.

The needles were fixed in the liver parenchyma 1 cm apart from the resected surface and 3 cm deep creating 2 cm of necrotic liver tissue along the resected surface. It took four applications of 10 min each to reach a complete and definitive haemostasis that

allowed us to close the abdominal wall in a bloodless field. Patient slowly recovered from the operation and left the hospital 15 days later with a low output bile fistula that took 1 month to heal.

3. Discussion

Haemostasis remains a critical issue in liver surgery not only for the catastrophic effect of haemorrhage but also because it is correlated to complications rate and to survival.⁴ Even though thorough knowledge of liver anatomy is mandatory for liver resection there are many technical options to choose in order to reduce the bleeding during liver resection.⁵ There are a variety of dissector devices, ties, clips, staplers, coagulation (mono or bipolar, argon) and coagulant agents or glues. Recently a new technique has been proposed to resect the liver parenchyma in a bloodless field.¹ This technique derives from the experience gained with thermal ablation of liver tumours and is based upon the coagulative necrosis generated by the radiofrequency that is able to seal small to medium size blood vessels and bile ducts even though some concerns remain about the its safety and postoperative complications.⁶ This technique is currently indicated particularly for peripheral resections creating a necrotic plane to be transected simply with a scalpel without bleeding at all. To facilitate the creation of a necrotic plane where cut through and to prevent unwanted injures a new hand piece has been described with multiple bipolar needles placed in a row which is described as safer.³

Furthermore, recently, RF has been used with the aim to treat bleeding from liver injuries in an experimental model.⁷

4. Conclusion

We suggest the use of the radiofrequency energy, delivered through multiple needles, when the conventional techniques fail to reach a proper haemostasis after a liver resection or, to consider its use, prior to resect the liver in presence of inflamed or neo-vascularized parenchyma.

Conflict of interest

None.

Funding

None.

Consent

Written informed consent was obtained from the patient for publication of this case report and accompanying images. A copy of the written consent is available for review by the Editor-in-Chief of this journal on request.

Author contributions

All authors contributed to this work: B.P., F.L., collected the data, B.P., F.L., G.L., G.A., D.Z., analyzed the data, B.P., F.L., M.F. and G.B. wrote the manuscript, G.B. obtained informed consent and supervised all the manuscript.

References

- Weber JC, Navarra G, Jiao LR, Nicholls JP, Jensen SL, Habib NA. New technique for liver resection using heat coagulative necrosis. *Annals of Surgery* 2002;236(5):560–3.
- Haghighi KS, Wang F, King J, Daniel S, Morris DL. In-line radiofrequency ablation to minimize blood loss in hepatic parenchymal transection. *American Journal of Surgery* 2005;190(1):43–7.

3. Pai M, Jiao LR, Khorsandi S, Canelo R, Spalding DR, Habib NA. Liver resection with bipolar radiofrequency device: Habib 4X. *HPB (Oxford)* 2008;**10**(4):256–60.
4. Poon RT, Fan ST, Lo CM, Liu CL, Lam CM, Yuen WK, et al. Improving perioperative outcome expands the role of hepatectomy in management of benign and malignant hepatobiliary diseases: analysis of 1222 consecutive patients from a prospective database. *Annals of Surgery* 2004;**240**(4):698–708.
5. Poon RT. Current techniques of liver transection. *HPB (Oxford)* 2007;**9**(3):166–73.
6. Mitsuo M, Takahiro T, Yasuko T, Masayasu A, Katsuya O, Nozomi S, et al. Radiofrequency (RF)-assisted hepatectomy may induce severe postoperative liver damage. *World Journal of Surgery* 2007;**31**(11):2208–12.
7. Yao P, Gunasegaram A, Ladd LA, Daniel S, Morris DL. An experimental study of the treatment of liver injury with InLine RFA. *HPB (Oxford)* 2007;**9**(1):37–41.

Open Access

This article is published Open Access at scimedirect.com. It is distributed under the [IJSCR Supplemental terms and conditions](#), which permits unrestricted non commercial use, distribution, and reproduction in any medium, provided the original authors and source are credited.