



UNIVERSITÀ
DEGLI STUDI
FIRENZE

FLORE

Repository istituzionale dell'Università degli Studi
di Firenze

**INTERDENTAL PAPILLA MANAGEMENT. A REVIEW AND
CLASSIFICATION OF THE THERAPEUTICAL APPROACHES**

Questa è la Versione finale referata (Post print/Accepted manuscript) della seguente pubblicazione:

Original Citation:

INTERDENTAL PAPILLA MANAGEMENT. A REVIEW AND CLASSIFICATION OF THE THERAPEUTICAL APPROACHES / G. PINI PRATO; R. ROTUNDO; P. CORTELLINI; C. TINTI; R. AZZI. - In: THE INTERNATIONAL JOURNAL OF PERIODONTICS & RESTORATIVE DENTISTRY. - ISSN 0198-7569. - ELETTRONICO. - 24:(2004), pp. 246-255.

Availability:

This version is available at: 2158/22048 since:

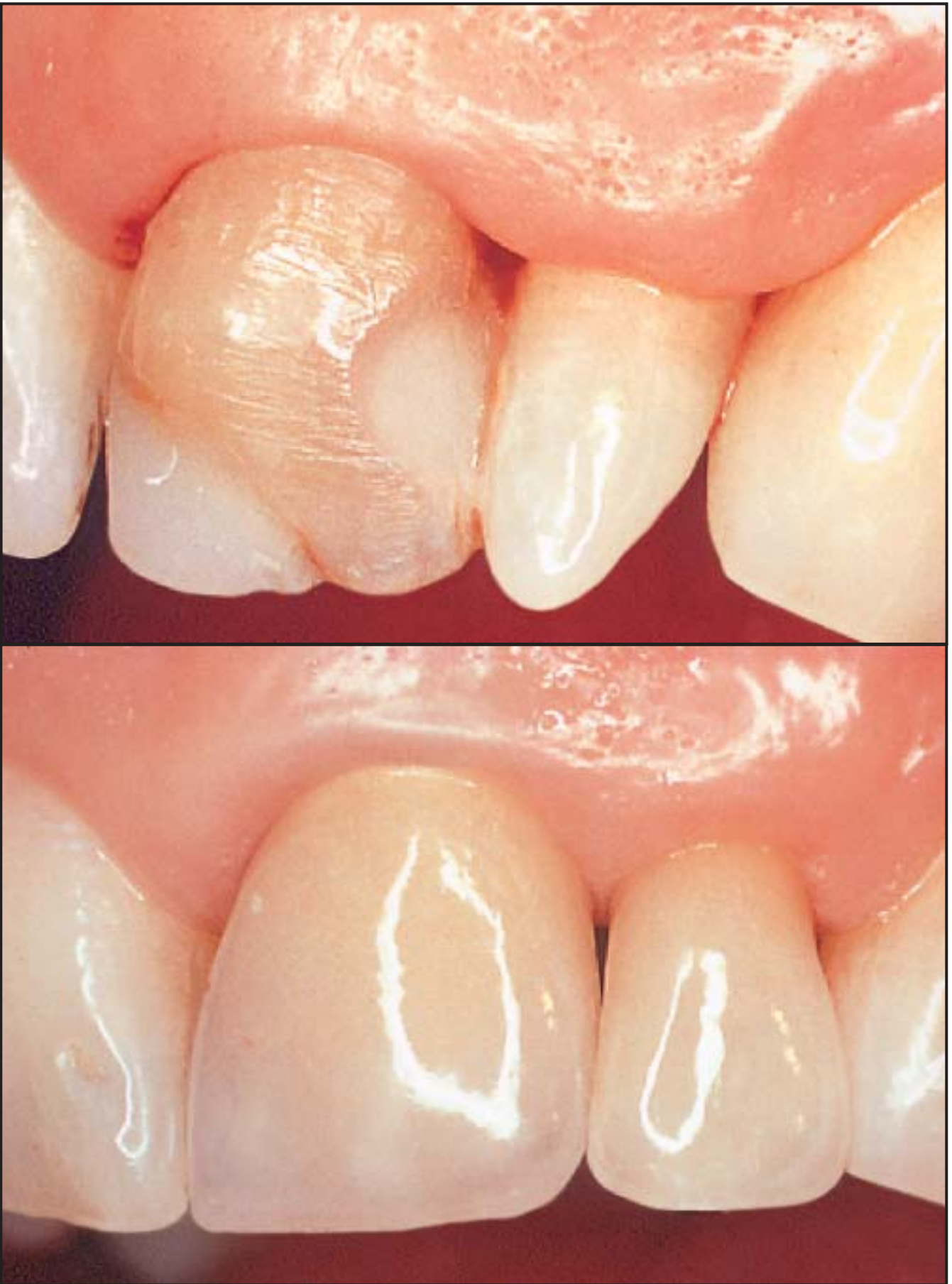Terms of use:

Open Access

La pubblicazione è resa disponibile sotto le norme e i termini della licenza di deposito, secondo quanto stabilito dalla Policy per l'accesso aperto dell'Università degli Studi di Firenze (<https://www.sba.unifi.it/upload/policy-oa-2016-1.pdf>)

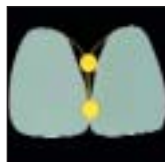Publisher copyright claim:

(Article begins on next page)



COPYRIGHT © 2004 BY QUINTESSENCE PUBLISHING CO, INC. PRINTING OF THIS DOCUMENT IS RESTRICTED TO PERSONAL USE ONLY. NO PART OF THIS ARTICLE MAY BE REPRODUCED OR TRANSMITTED IN ANY FORM WITHOUT WRITTEN PERMISSION FROM THE PUBLISHER.

Interdental Papilla Management: A Review and Classification of the Therapeutic Approaches



Giovan Paolo Pini Prato, MD, DDS*
 Roberto Rotundo, DDS**
 Pierpaolo Cortellini, MD, DDS***
 Carlo Tinti, MD, DDS****
 Robert Azzi, DDS*****

Several reasons contribute to the loss of interdental papillae and the establishment of "black triangles" between teeth. The most common reason in the adult population is loss of periodontal support because of plaque-associated lesions. However, abnormal tooth shape, improper contours of prosthetic restorations, and traumatic oral hygiene procedures may also negatively influence the outline of the interdental soft tissues. Several surgical and nonsurgical techniques have been proposed to treat soft tissue deformities and manage the interproximal space. The nonsurgical approaches (orthodontic, prosthetic, and restorative procedures) modify the interproximal space, thereby inducing modifications to the soft tissues. The surgical techniques aim to recontour, preserve, or reconstruct the soft tissue between teeth and implants. This review categorizes the various approaches in different clinical situations. (Int J Periodontics Restorative Dent 2004;24:246–255.)

*Professor, Dental School, University of Florence, Italy.

**Fellow Researcher, Dental School, University of Florence, Italy.

***Reader, Department of Periodontology, Eastman Dental Institute, University College London.

****Visiting Professor, Dental School, University of Florence, Italy.

*****Associate Clinical Professor, Department of Periodontology, University of Paris VII.

Correspondence to: Dr Giovan Paolo Pini Prato, Viale Matteotti 11, 50121 Florence, Italy. e-mail: gpini@tin.it

The absence or loss of the interdental papilla is one of the most concerning aspects in the decision-making process of clinicians and in gaining acceptance from the patient. This condition may create esthetic impairments, phonetic problems, and food impaction.^{1,2}

Characterization of the interdental space and papilla

Interdental space

The interdental space is a physical space between two adjacent teeth. Its form and volume are determined by the morphology of the teeth. The interdental space is composed of four pyramidal embrasures: cervical, occlusal, buccal, and lingual³ (Fig 1). The apex of each pyramid ends at the contact point or area of two adjacent teeth. The lingual, buccal, and occlusal pyramids are empty, while the cervical one is occupied by the interdental papilla. On a sagittal plane, the projection of the occlusal pyramid shows a slightly open angle,

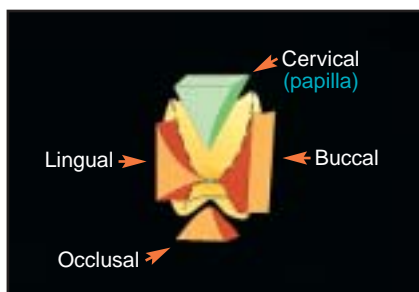


Fig 1 Interdentalspace is composed of cervical, occlusal, buccal, and lingual pyramids. Apices of pyramids end at contact point.

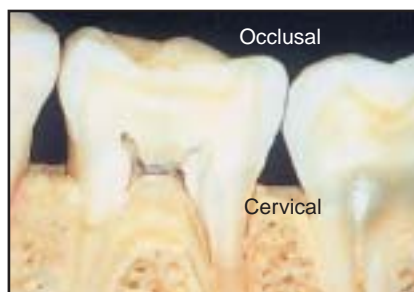

Fig 2 On a sagittal plane, projection of occlusal pyramid shows a slightly open angle, whereas projection of cervical one shows an acute angle.

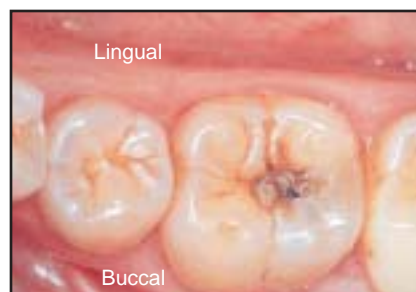


Fig 3 On an occlusal plane, projection of buccal pyramid shows an open angle, whereas projection of lingual one shows an acute angle.

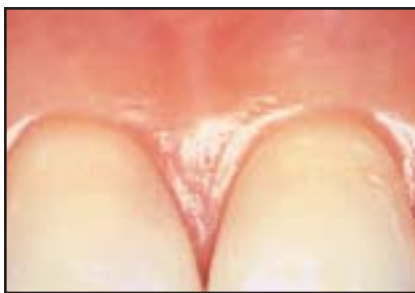
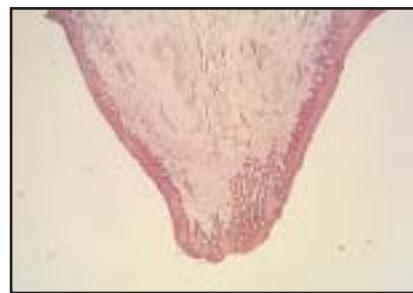
Fig 4 (left) Clinical aspect of interdental papilla.

Fig 5 (right) Histologic aspect of interdental papilla (hematoxylin-eosin stain; original magnification $\times 80$).



whereas the projection of the cervical one shows an acute angle (Fig 2). On an occlusal plane, the projection of the buccal pyramid shows an open angle, whereas the projection of the palatal one shows an acute angle (Fig 3). A point or area of contact near the occlusal plane and located buccally tends to open the angle of the occlusal and buccal pyramids. On the other hand, a point or area of contact situated in the middle third of the crown makes narrower occlusal and buccal pyramids. This reduces the cervical pyramid and favors food retention. These morphologic characteristics must be taken into consideration when

restorative approaches are performed.

Interdental papilla

The cervical pyramid is occupied by the interdental gingival papilla (Fig 4). The interdental papilla is formed by a dense connective tissue covered by oral epithelium (Fig 5). The contact relationships between the teeth, width of the approximal tooth surfaces, and course of the cemento-enamel junction (CEJ) determine its shape. In the anterior region, the buccal apex of the papilla reaches the apex of the palatal/lingual one in

correspondence to the contact point. In the premolar/molar region, the teeth have wide approximal contact surfaces; therefore, the buccal and palatal/lingual aspects of the papilla are separated by a concavity known as the "col." A human observational study correlated the presence or absence of the interproximal papilla with the vertical distance between the contact point and crest of bone.¹ When the tissue fills the embrasure completely, the papilla is considered to be present. When the space is visible apical to the contact point, the papilla is deemed missing. When the vertical distance from the contact point to the crest of bone is

5 mm or less, the papilla is present almost 100% of the time. When the distance is 6 mm or more, the papilla is usually missing.

Classification of the loss of interdental papilla

Several conditions modify the interproximal space; as a consequence, the morphology of the interdental papilla may be impaired. Abnormal tooth shape, improper contours of prosthetic crowns or restorations, traumatic interproximal hygiene procedures, and especially periodontal diseases may cause loss of the interdental papilla.

A classification for the loss of papilla height was proposed by Nordland and Tarnow.⁴ This classification is based on three anatomic landmarks: interdental contact point, facial apical extent of the CEJ, and interproximal coronal extent of the CEJ. Four classes were identified:

- Normal: Interdental papilla fills the embrasure to the apical extent of the interdental contact point/area.
- Class I: The tip of the interdental papilla lies between the interdental contact point and the most coronal extent of the interproximal CEJ.
- Class II: The tip of the interdental papilla lies at or apical to the interproximal CEJ but coronal to the apical extent of the facial CEJ.
- Class III: The tip of the interdental papilla lies level with or apical to the facial CEJ.

Treatment

Several efforts have been undertaken to treat and restore the missing interproximal papilla. If the loss of papilla is related to soft tissue damage only, reconstructive techniques are able to restore it completely. If the loss of interdental papilla is caused by severe periodontal disease with interproximal bone resorption, complete reconstruction is generally not achieved. Different surgical and nonsurgical approaches are proposed in the periodontal literature to provide satisfactory interdental papilla reconstruction.

Nonsurgical approaches

Correction of traumatic oral hygiene procedures. In case of damage to the interdental papilla produced by traumatic flossing, interproximal hygiene procedures must be initially discontinued and successively modified. Reepithelialization of the traumatic lesion can restore the papilla completely.⁵

Restorative/prosthetic restorations. Abnormal tooth shape may contribute to a "missing" papilla, and an appropriate restorative technique is indicated to favor the creeping of the interdental tissues. In case of incisors with an incisal edge much wider than the cervical third, the contact point is located coronally. In this situation, the cervical pyramid of the interdental space is increased and the papilla does not fill the space

completely. By a restorative/prosthetic reshaping of the contours of the teeth, the contact point may be lengthened and located more apically; the embrasure is reduced, allowing coronal displacement of the interdental gingiva^{2,6,7} (Fig 6).

Orthodontic approach. In the presence of diastema, the contact point is lacking, and therefore the classification criteria of Nordland and Tarnow cannot be applied. In this condition, the interdental papilla may be apparently absent, and it may create both esthetic and phonetic problems. In situations of periodontal health, the interproximal gingival tissue is firmly attached to the teeth and alveolar bone. An orthodontic approach is indicated in these situations.² The aim is to reduce the diastema and create a contact point between the adjacent teeth, without periodontal attempts to build up the missing papilla (Fig 7a). In fact, the proper closure of the diastema causes some degree of coronal creeping of the interproximal gingival tissue. Orthodontic closure of the interdental space should be attained with a bodily movement of the two adjacent teeth (Fig 7b). In fact, a mesiodistal divergence of the roots would lead to a coronal location of the contact point. As a consequence, the interproximal papilla will not fill the interdental space and the esthetic problem would not be solved. When a diastema is due to periodontal disease, the orthodontic closure of the diastema can be performed after the resolution of

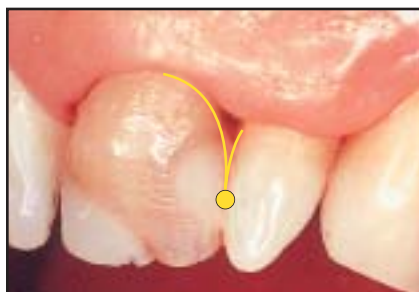

Fig 6a By restorative/prosthetic rehabilitation, contact point may be lengthened and located more apically, allowing coronal displacement of interdental gingiva.

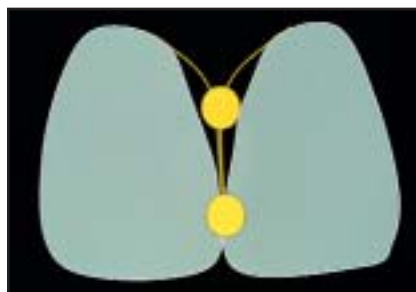

Fig 6b Schematic movement of contact point.

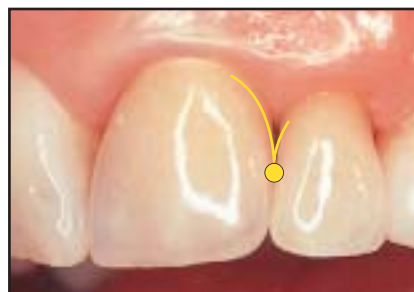

Fig 6c Final result of prosthetic reshaping of the lateral incisor, with consequent coronal displacement of the interdental gingiva. (Courtesy of Dr L. Vanini.)

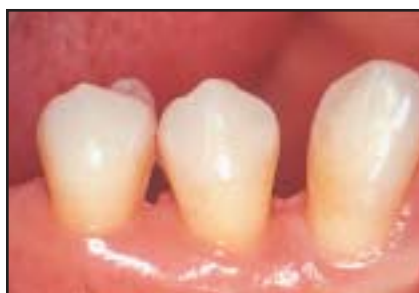
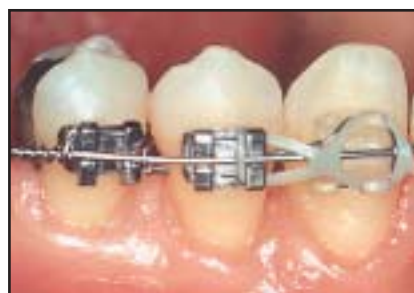
Fig 7a (left) Modification of interdental space by means of orthodontic treatment: clinical case before therapy.

Fig 7b (right) Closure of diastema causes coronal creeping of interproximal gingival tissue.



the inflammation. In these cases, interdental papilla reconstruction is not the main goal of the comprehensive treatment plan.

Repeated curettage of the papilla. A case report study⁸ describes a non-surgical approach to recreate papillae destroyed by necrotizing gingivitis. Repeated scaling/root planing and curettage of the papillary tissue were performed every 15 days for 3 months. This instrumentation may induce a proliferative hyperplastic inflammatory reaction of the papilla (Fig 8). Some new regenerated papillae were observed, while others did not respond.

Surgical approaches

Because of the esthetic value of the interproximal papilla, especially in young patients, several surgical techniques have been described to prevent and/or solve the esthetic impairments.

Papilla recontouring. In the presence of gingival enlargement, the excess tissue should be eliminated to remodel the soft tissue architecture. In cases of drug-induced hyperplasia, idiopathic gingival hyperplasia, etc, a gingivectomy may be performed. Gingivectomy associated with a free gingival graft may be indicated in

case of localized gingival lesions, such as peripheral giant cell granuloma.

Papilla preservation. Specific surgical approaches have been reported to prevent or reduce an excessive apical displacement of the gingival margin in the treatment of periodontal defects.

Takei et al⁹ propose a new surgical approach called the papilla preservation technique. The buccal aspect of the flap is designed with a sulcular incision around each tooth, with no incisions made through the interdental papilla. The lingual/palatal flap design consists

of a sulcular incision along the lingual or palatal aspect of each tooth, with a semilunar incision across each interdental papilla. This incision dips apically from the line angles of the tooth so that the papillary incision line is at least 5 mm from the gingival margin. This allows the interdental tissue to be dissected from the lingual/palatal aspect so that it can be elevated intact with the facial flap. After treatment of the bony defect, the buccal flap, including the palatal/lingual aspect of the papilla, is repositioned. The palatal/lingual papilla is sutured with the palatal/lingual flap (Fig 9).

To optimize the clinical results in terms of attachment/bone gains and soft tissue preservation, Cortellini et al¹⁰ published a modification of Takei et al's technique as a new approach for interproximal regenerative procedures (the modified papilla preservation technique). A horizontal incision is performed on the buccal papillary tissue at the base of the papilla. A full-thickness palatal flap, which includes the interdental papilla, is elevated. A buccal full-thickness flap is elevated with vertical releasing incisions and/or periosteal incisions, when needed. A barrier membrane is positioned to cover the defect. The interdental tissues are repositioned and sutured to completely cover the membrane. A horizontal internal crossed mattress suture is placed beneath the mucoperiosteal flaps between the base of the palatal papilla and the buccal flap. This suture relieves all the tension of the flaps. A second suture (vertical internal mattress

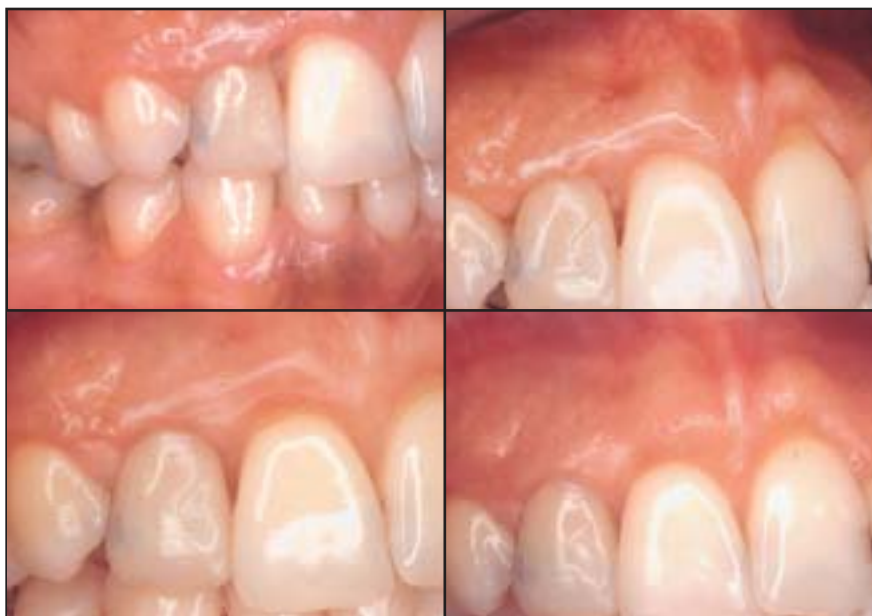

Fig 8 Top left: Loss of interdental papilla between maxillary lateral and central incisors. Repeated curettage of the interdental papilla was performed every 15 days. (Courtesy of Prof M. Caffabriga.) Top right: Same case after 1 month. Bottom left: Same case after 2 months. Bottom right: Same case after 3 months. Complete regeneration of the interdental tissue is achieved.

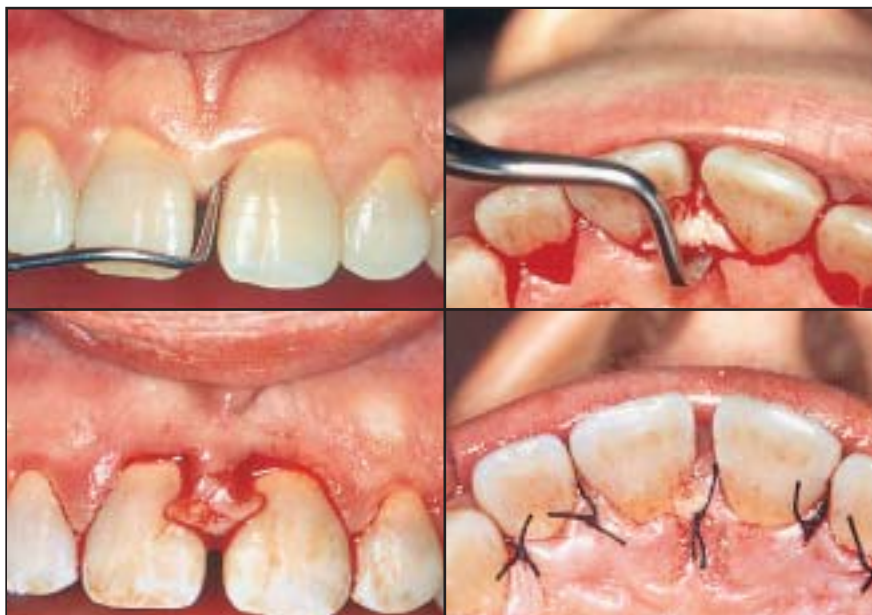

Fig 9 Top left: Papilla preservation technique: interproximal defect in a young patient. Top right: Palatal incision at the base of the papilla allows for elevation of a flap that includes the papilla itself. Bottom left: Palatal papilla is maintained. Bottom right: Palatal papilla is sutured in its original position.

suture) is placed between the buccal aspect of the interproximal papilla and the most coronal portion of the buccal flap to ensure primary closure (Fig 10). This technique is applicable in wide interdental spaces (> 2 mm), especially in the anterior dentition. This technique allows for achieving primary closure of the tissue and preserving the papilla in 75% of cases. These results may be improved using a microsurgical approach.¹¹

In 1999, Cortellini et al¹² proposed the simplified papilla preservation flap (SPPF). It is initiated with an oblique incision across the defect-associated papilla, from the gingival margin at the buccal line angle of the involved tooth to the midinterproximal portion of the papilla under the contact point of the adjacent tooth. A full-thickness palatal flap, including the papilla, and a split-thickness buccal flap are then elevated. After application of a barrier membrane, the interdental tissues are positioned and sutured to obtain primary closure of the interdental space. A horizontal internal mattress suture (offset mattress suture) runs from the base of the keratinized tissue at the midbuccal aspect of the tooth not involved by the defect to a symmetric location at the base of the lingual/palatal flap. This suture allows the coronal positioning of the buccal flap. The interdental tissues above the membrane are then sutured to obtain primary closure. The SPPF is applicable in narrow interdental spaces (≤ 2 mm).

Papilla reconstruction. After elimination of the inflammation, specific

techniques have been proposed to reconstruct the interdental tissues.

A case report¹³ describes a surgical technique to reconstruct the interdental papilla combining a pedicle flap with papilla preservation. In correspondence to the lost interproximal papilla, a palatal split-thickness flap is dissected and labially elevated. The flap is folded on itself and sutured to create the new papilla. A periodontal dressing is applied on the palatal aspect only to support the papilla.

In 1996, Han and Takei⁶ proposed an approach based on the use of a semilunar incision placed in the alveolar mucosa of the interdental area. Intrasulcular incisions connect with the semilunar incision to allow the elevation of a split-thickness flap and the coronal displacement of the gingivopapillary unit. A subepithelial free gingival connective tissue graft is placed beneath the coronally positioned interdental tissue (Fig 11). The authors claim that the procedure may be repeated a second and third time after 2 to 3 months of healing to reach the goal of papilla reconstruction.

Some authors propose three different techniques in case reports. The first procedure aims to reconstruct the interdental papilla using a buccal and palatal split-thickness flap and a connective tissue graft. An envelope split-thickness flap is elevated buccally and palatally to place the connective tissue graft harvested from the tuberosity area. The graft is trimmed to the desired size and shape and fit under the flaps to provide more bulk in the papillary

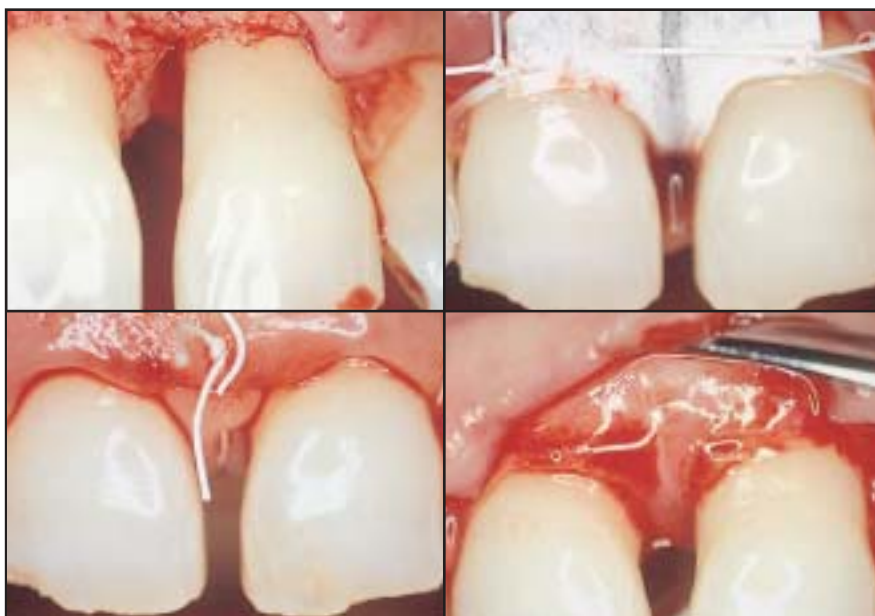

Fig 10 Top left: Modified papilla preservation technique: initial incisions, flap elevation, and defect debridement. Top right: Nonresorbable membrane is shaped and positioned onto defect. Bottom left: Palatal papilla is sutured. Bottom right: Newly formed tissue at reentry procedure 6 weeks later.

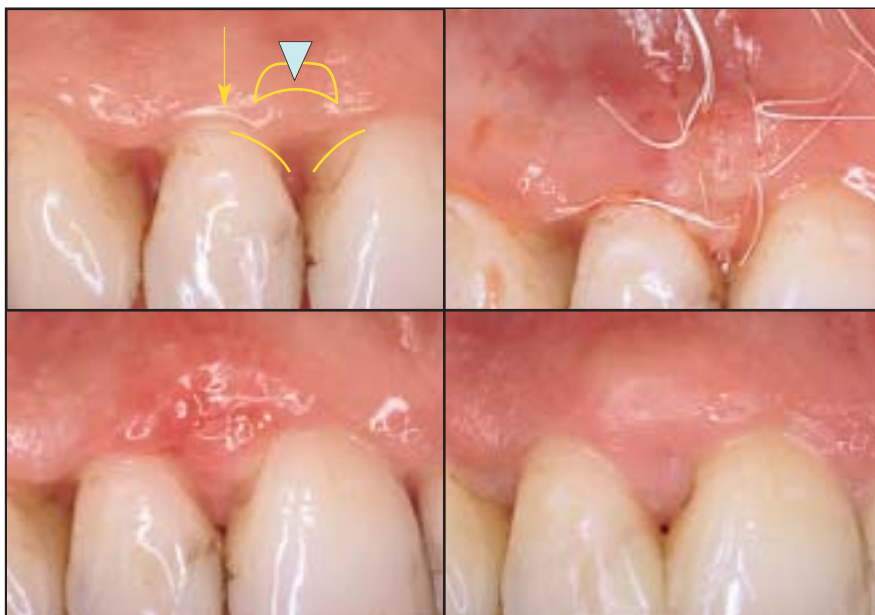

Fig 11 Top left: Technique to increase interproximal papilla: semilunar incision allows for positioning of a connective tissue graft beneath the coronally positioned interdental tissue. Top right: Interdental papilla at the removal of sutures after 2 weeks. Bottom left: Healing after 1 month. Bottom right: Healing after 3 months.

region. The buccal and palatal flaps are then sutured together with the connective tissue graft underneath.¹⁴ The second technique was performed in one case to achieve root coverage and papilla reconstruction in a Class IV recession. A subepithelial connective tissue graft harvested from the tuberosity area is positioned in an envelope flap elevated with an incision performed at the level of the mucogingival junction. The connective tissue and the coronal displacement of the flap allow the simultaneous treatment of the gingival recession and interproximal missing papilla.¹⁵ To increase the volume of the interdental tissue, a modification of the latter technique was proposed. It consists of the use of bone graft harvested from the tuberosity area and a palatal free connective tissue graft inserted in an envelope flap.¹⁶

In the case of implant therapy, the absence of interimplant papillae impairs esthetics. Some attempts have been proposed in the literature to recreate the scalloped and positive architecture of the soft tissue around implants.^{17,18} One novel technique consists of buccal dislodgment of a full-thickness flap raised from a site slightly more palatal with respect to the implants.¹⁹ To ensure and stabilize the most coronal position of the flap, the ramp mattress suture technique is performed. This new suturing approach provides a coronal pulling traction, whereas the palatal flap receives compression on its underlying layers. After 4 to 5 weeks, a vestibular scalloped gingivectomy is

performed in correspondence to the vestibular surface of the abutments to create a positive architecture of the gingival margin.

Although more and more sophisticated approaches showing good clinical results have been proposed to restore the lost interdental papilla, the predictability of various procedures has not been completely documented, and no data on the long-term stability are available in the literature.

References

1. Tarnow DP, Magner AW, Fletcher P. The effect of the distance from the contact point to the crest of bone on the presence or absence of the interproximal dental papilla. *J Periodontol* 1992;63:995–996.
2. Kokich VG. Esthetics: The orthodontic-periodontic restorative connection. *Semin Orthod* 1996;2:21–30.
3. Bresson G, Romerowski J. Pleading for a too often neglected discipline: Dental anatomy, various interesting aspects in current practice [in French]. *Rev Odontostomatol* 1978;7(1):47–56.
4. Nordland WP, Tarnow DP. A classification system for loss of papillary height. *J Periodontol* 1998;69:1124–1126.
5. Agudio G, Pini Prato GP, Nevins M, Cortellini P, Ono Y. Esthetic modifications in periodontal therapy. *Int J Periodontics Restorative Dent* 1989;9:288–299.
6. Han TJ, Takei HH. Progress in gingival papilla reconstruction. *Periodontol* 2000 1996;11:65–68.
7. Blatz MB, Hürzeler MB, Strub JR. Reconstruction of the lost interproximal papilla—Presentation of surgical and non-surgical approaches. *Int J Periodontics Restorative Dent* 1999;19:395–406.
8. Shapiro A. Regeneration of interdental papillae using periodic curettage. *Int J Periodontics Restorative Dent* 1985;5(5): 27–33.
9. Takei HH, Han TJ, Carranza FA Jr, Kenney EB, Lekovic V. Flap technique for periodontal bone implants. Papilla preservation technique. *J Periodontol* 1985;56: 204–210.
10. Cortellini P, Pini Prato G, Tonetti MS. The modified papilla preservation technique. A new surgical approach for interproximal regenerative procedures. *J Periodontol* 1995;66:261–266.
11. Cortellini P, Tonetti MS. Microsurgical approach to periodontal regeneration. Initial evaluation in a case cohort. *J Periodontol* 2001;72:559–569.
12. Cortellini P, Pini Prato G, Tonetti MS. The simplified papilla preservation flap. A novel surgical approach for the management of soft tissues in regenerative procedures. *Int J Periodontics Restorative Dent* 1999;19:589–599.
13. Beagle JR. Surgical reconstruction of the interdental papilla: Case report. *Int J Periodontics Restorative Dent* 1992;12: 144–151.
14. Azzi R, Etienne D, Carranza F. Surgical reconstruction of the interdental papilla. *Int J Periodontics Restorative Dent* 1998;18:467–473.
15. Azzi R, Etienne D, Sauvan J, Miller PD. Root coverage and papilla reconstruction in Class IV recession: A case report. *Int J Periodontics Restorative Dent* 1999;19:449–455.
16. Azzi R, Takei HH, Etienne D, Carranza F. Root coverage and papilla reconstruction using autogenous osseous and connective tissue grafts. *Int J Periodontics Restorative Dent* 2001;21:141–147.
17. Palacci P. Peri-implant soft tissue management: Papilla regeneration technique. In: Palacci P, Ericsson I, Engstrand P, Rangert P (eds). *Optimal Implant Positioning and Soft Tissue Management for the Brånemark System*. Chicago: Quintessence, 1995:59–70.
18. Jemt T. Regeneration of gingival papillae after single-implant treatment. *Int J Periodontics Restorative Dent* 1997;17: 327–333.
19. Tinti C, Parma Benfenati S. The ramp mattress suture: A new suturing technique combined with a surgical procedure to obtain papillae between implants in the buccal area. *Int J Periodontics Restorative Dent* 2002;22:63–69.