



UNIVERSITÀ  
DEGLI STUDI  
FIRENZE

FLORE

## Repository istituzionale dell'Università degli Studi di Firenze

### **Hepatitis C virus: a common triggering factor for both nodular vasculitis and Sjogren's syndrome?**

Questa è la Versione finale referata (Post print/Accepted manuscript) della seguente pubblicazione:

*Original Citation:*

Hepatitis C virus: a common triggering factor for both nodular vasculitis and Sjogren's syndrome? / C. Cardinali; G. Gerlini; M. Caproni; N. Pimpinelli; P. Fabbri. - In: BRITISH JOURNAL OF DERMATOLOGY. - ISSN 0007-0963. - STAMPA. - 142:(2000), pp. 187-188.

*Availability:*

This version is available at: 2158/25256 since:

*Terms of use:*

Open Access

La pubblicazione è resa disponibile sotto le norme e i termini della licenza di deposito, secondo quanto stabilito dalla Policy per l'accesso aperto dell'Università degli Studi di Firenze (<https://www.sba.unifi.it/upload/policy-oa-2016-1.pdf>)

*Publisher copyright claim:*

(Article begins on next page)

of an HIV infection should be considered.<sup>7</sup> However, to date the authors are unaware of any previous report on perianal tuberculosis in an HIV-infected individual.

The tuberculin skin test may be negative in patients with orificial tuberculosis. This phenomenon is called 'negative anergy' and is caused by a decrease in tuberculo-specific host defence at the time of a severe infection.<sup>8</sup> It is important not to depend solely on a negative result of the tuberculin skin test. Histopathological examination of an ulcer edge is often the key to the correct diagnosis.<sup>9</sup> Polymerase chain reaction (PCR) is promising as a future diagnostic technique and can probably lead to a quicker and more accurate diagnosis, but cultures should always be done to confirm PCR results and determine drug resistance.<sup>10</sup>

Departments of Dermatology and  
Venereology and \*Pulmonary Diseases, W.I.VAN DER MEIJDEN  
University Hospital E.C.GROENINX VAN ZOELLEN\*  
Rotterdam-Dijkzigt, F.B.DE WAARD-VAN DER SPEK  
Dr Molewaterplein 40,  
3015 GD, Rotterdam,  
the Netherlands

## References

- 1 Royal Netherlands Tuberculosis Association (KNCV). *Netherlands Tuberculosis Register, Index Tuberculosis 1996*. The Hague: KNCV 1997.
- 2 Yates VM, Ormerod LP. Cutaneous tuberculosis in Blackburn district (U.K.): a 15-year prospective series, 1981–95. *Br J Dermatol* 1997; **136**: 483–9.
- 3 Le Bourgeois PhC, Poynard T, Modai J *et al*. Ulceration péri-anales. Ne pas oublier la tuberculose. *Presse Med* 1984; **13**: 2507–9.
- 4 Betloch I, Banuls J, Sevilla A *et al*. Perianal tuberculosis. *Int J Dermatol* 1994; **33**: 270–1.
- 5 Chung CC, Choi CL, Kwok SPY *et al*. Anal and perianal tuberculosis: a report of three cases in 10 years. *JR Coll Surg Edinb* 1997; **42**: 189–90.
- 6 Schmid ML, McKendrick MW, Lobo A, Leach M. A perianal ulcer. *Lancet* 1999; **353**: 894.
- 7 Libraty DH, Byrd TE. Cutaneous miliary tuberculosis in the AIDS era: case report and review. *Clin Infect Dis* 1996; **23**: 706–10.
- 8 Sehgal VN, Wagh SA. Cutaneous tuberculosis, current concepts. *Int J Dermatol* 1990; **29**: 237–52.
- 9 Sarela AI, Supe AN. Tuberculous perianal ulcers. *JR Soc Med* 1996; **89**: 584.
- 10 Nachbar F, Classen V, Nachbar T *et al*. Orificial tuberculosis: detection by polymerase chain reaction. *Br J Dermatol* 1996; **135**: 106–9.

## Hepatitis C virus: a common triggering factor for both nodular vasculitis and Sjögren's syndrome?

SIR, Nodular vasculitis (NV) is a lobular panniculitis associated with vasculitis of the septal blood vessels. It is characterized by a chronic eruption of nodular, erythematous and painful lesions that occur predominantly on the posterior and lateral surfaces of the legs. These lesions can evolve into bluish-red plaques. They may ulcerate and, after healing,

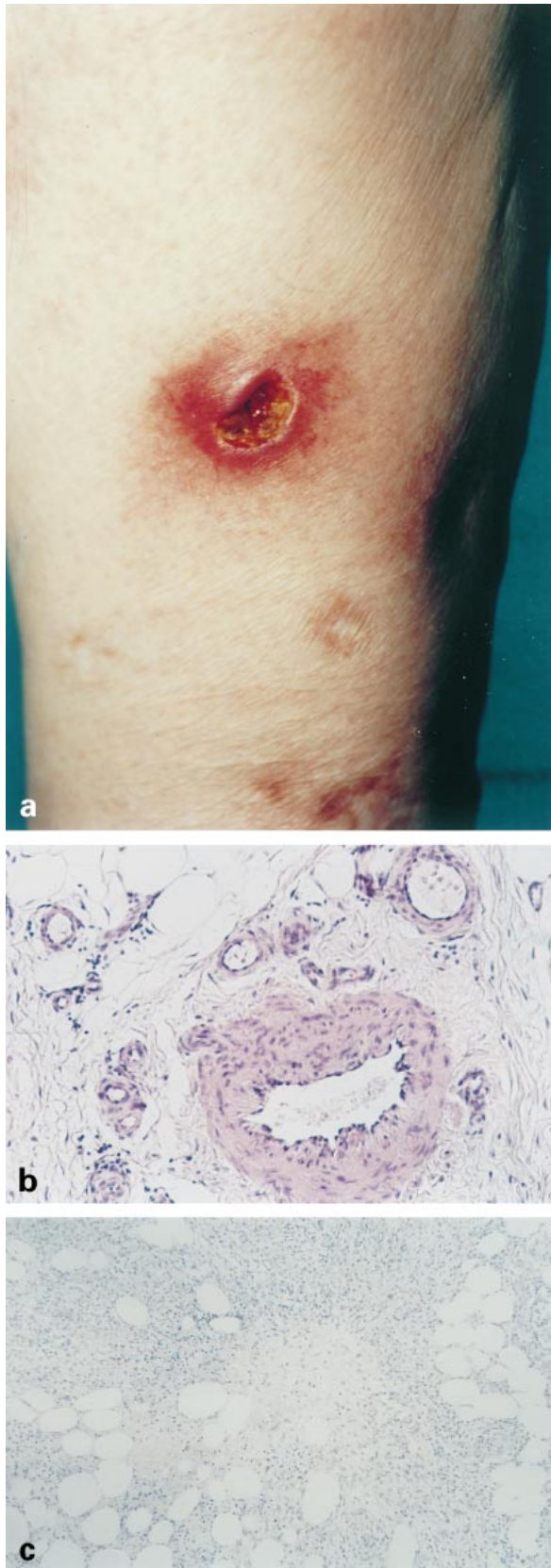
leave atrophic scars.<sup>1</sup> Infections are one of the most important causes of NV.

Sjögren's syndrome (SS) is characterized by dry eyes (xerophthalmia) and dry mouth (xerostomia),<sup>2</sup> resulting from a lymphocytic infiltrate of the lacrimal and salivary glands. Hepatitis C virus (HCV)-associated SS has been widely reported. HCV infection is also often associated with cutaneous vasculitis, mainly related to cryoglobulinaemia.<sup>3</sup> We report the case of a patient with HCV hepatitis who subsequently developed cutaneous NV and SS.

A 65-year-old Caucasian woman presented with a symmetrical eruption of erythematous-cyanotic, subcutaneous nodules of the lower legs and the abdomen. She reported a 10-year history of painful nodular lesions with a particular preference for the calf area. These lesions had a chronic recurrent course, occurring frequently during the winter. Shortly after the onset of the skin problems, she developed xerophthalmia, xerostomia, arthralgia, myalgia and recurrent swelling of the parotid glands. She had a history of chronic HCV infection diagnosed 14 years previously. Physical examination revealed several tender, erythematous-cyanotic, oedematous nodules, 0.5–2 cm in size distributed on the lower legs (Fig. 1a) and abdomen; some of these lesions were ulcerated. Hyperpigmented, atrophic scars could be observed also. A biopsy taken from a nodule of the left leg mainly showed septal panniculitis with vasculitis (arteritis) (Fig. 1b), and to a lesser extent lobular panniculitis, with fat cell necrosis and granulomatous inflammation (Fig. 1c).

Cultures for fungi and atypical mycobacteria were negative. Neither immunoglobulins nor complement components were found by direct immunofluorescence (DIF) on lesional skin. Polymerase chain reaction (PCR) assay on the skin specimen did not detect HCV RNA. Biopsy of minor salivary glands revealed lymphocytic sialadenitis (grade 3 according to Chisholm and Mason scoring system). Routine laboratory investigations were normal except for a slight increase in  $\gamma$ -glutamyl transpeptidase at 79 U/L (normal 5–40 U/L), aspartate transaminase at 43 U/L and alanine transferase at 61 U/L (normal 5–40 U/L). No cryoglobulins were detected on three different occasions. The following studies were either negative or within normal limits: circulating immune complexes (determined by ELISA), serum amylase and lipase,  $\alpha_1$ -antitrypsin, complement activity, angiotensin-converting enzyme. Anti-HCV antibodies and serum HCV RNA detection by PCR confirmed the previously diagnosed HCV infection. Serologic tests for hepatitis B virus, HIV and Epstein–Barr virus were negative. Antinuclear antibodies were repeatedly positive (1 : 20–1 : 160), while anti-ds-DNA was positive (63.6 iu/mL; negative < 35, borderline 35–55, positive > 55) on only one occasion. Anti-Ro/SSA and La/SSB antibodies were negative, as was the tuberculin skin test reaction. The chest X-ray was normal, and abdominal ultrasound showed hepatomegaly. Ocular involvement was confirmed by a positive Schirmer's test.

The liver biopsy showed a lymphohistiocytic infiltrate in portal tracts, focal hepatocellular necrosis and diffuse fibrosis. The diagnosis of SS was made according to the criteria



recently established by the European Community Study Group.<sup>4</sup> The diagnosis of nodular vasculitis was established on the basis of the clinical features and histological analysis. The patient did not respond to systemic corticosteroid treatment, while good results were obtained with dapsone (75 mg/daily), although discontinuation of the treatment was followed by relapse.

The relationship between HCV and SS is not yet fully clear, but a possible role for HCV in the pathogenesis of SS has been hypothesized.<sup>5,6</sup> Indeed, some authors state that HCV may be involved in the pathogenesis of a pseudo-SS, in which the clinical and pathological features resemble those of SS, but anti-SSA and anti-SSB antibodies are negative.<sup>5,6</sup>

The most likely pathogenic hypothesis for the association of HCV, NV and SS is the triggering of immune-mediated mechanisms by HCV. The local deposition of circulating immune complexes (antibodies against HCV antigens?) might be the initial pathogenic mechanism involved in NV.<sup>7</sup> Subsequently, a delayed-type hypersensitivity might be important in determining the chronic course of the disease.<sup>7</sup>

An interesting, additional point is the good response of both HCV hepatitis and cutaneous vasculitis to interferon- $\alpha$  treatment. In fact, interferon resulted in a clear-cut improvement of the cutaneous lesions in a case of HCV-related cryoglobulinaemia with manifestations of cutaneous vasculitis.<sup>3</sup> Durand and coworkers<sup>8</sup> provide strong additional evidence for the role of HCV as aetiological agent in cutaneous vasculitis: HCV RNA was detected in lesional skin by PCR, and again interferon was found to be effective in resolving skin lesions.

We propose that HCV might be the cause of both SS and NV in our patient, as the clinical manifestations became evident only after the patient had contracted the HCV infection. Moreover, no other known cause of NV was revealed in our investigations.

*Clinica Dermatologica II,  
Università degli Studi di Firenze,  
Via della Pergola 58,  
50121, Firenze, Italy  
E-mail: fabbri@cesit1.unifi.it*

C. CARDINALI  
G. GERLINI  
M. CAPRONI  
N. PIMPINELLI  
P. FABBRI

## References

- 1 Bondi EE, Lazarus GS. Disorders of subcutaneous tissue. In: *Dermatology in General Medicine* (Fitzpatrick TB, Eisen AZ, Wolff K, Freedberg IM, Austen KF, eds), 4th edn, Vol. 1. New York: McGraw-Hill, 1993: 1337–8.
- 2 Fox RI. Epidemiology, pathogenesis, animal models, and treatment of Sjögren's syndrome. *Curr Opin Rheumatol* 1994; **6**: 501–8.

**Figure 1.** (a) Clinical aspect: erythematous, subcutaneous nodule of the lower leg with central ulceration. (b) Skin biopsy showing infiltration of vessel walls by mononuclear cells associated with endothelial cell swelling (haematoxylin and eosin, original magnification  $\times 250$ ). (c) Skin biopsy showing granulomatous inflammatory infiltrate in the fat lobules and in the septa composed of lymphoid cells, histiocytes, epithelioid cells (haematoxylin and eosin, original magnification  $\times 200$ ).

- 3 Schirren CA, Zachoval R, Schirren CG *et al*. A role for chronic hepatitis C virus infection in a patient with cutaneous vasculitis, cryoglobulinemia, and chronic liver disease. Effective therapy with interferon-alpha. *Dig Dis Sci* 1995; **40**: 1221–5.
- 4 Vitali C, Bombardieri S, Moutsopoulos HM *et al*. Preliminary criteria for the classification of Sjögren's syndrome: results of a prospective concerted action supported by the European community. *Arthritis Rheum* 1993; **36**: 340–7.
- 5 Boscagli A, Hatron PY, Canva-Delcambre V *et al*. Sicca syndrome and hepatitis C virus infection: a Gougerot–Sjögren pseudo-syndrome? *Rev Med Interne* 1996; **17**: 375–80.
- 6 Mariette X. Sjögren's syndrome and virus. *Rev Med Interne* 1994; **15**: 601–6.
- 7 Petruzzellis V, Conte A, Florio T *et al*. La vasculite nodulare: osservazioni su 25 casi. *G Ital Dermatol Venereol* 1991; **126**: 357–62.
- 8 Durand JM, Kaplanski G, Richard MA *et al*. Cutaneous vasculitis in a patient infected with hepatitis C virus. Detection of hepatitis C virus RNA in the skin by polymerase chain reaction. (Letter.) *Br J Dermatol* 1993; **128**: 359–60.

### Radiotherapy and erythema nodosum

SIR, We were interested to read a recent article of correspondence published in the journal by Takagawa *et al*. about radiation induced erythema nodosum.<sup>1</sup> Despite few reports in the literature we believe that it is not an uncommon association and relatively commonly encountered. We report another patient who developed erythema nodosum after radiation therapy for a uterine leiomyosarcoma.

A 49-year-old woman was diagnosed as having a high-grade uterine leiomyosarcoma in 1998 after a hysterectomy was performed for irregular menstrual bleeding and rapidly enlarging fibroids. She was subsequently treated with external beam radiotherapy to the pelvis to a total dose of 45 Gy in 25 fractions over 5 weeks. Intracavity brachytherapy to a total dose of 8 Gy was also administered on two separate occasions. Ten days after starting radiotherapy (11 fractions) the patient noticed a firm painful erythematous lesion on the back of the right calf. Over the next few weeks while continuing radiotherapy similar lesions erupted over the left calf and right shin. She was referred to the dermatology department and a clinical diagnosis of erythema nodosum was made.

This was confirmed by a skin biopsy which showed a septal and lobular panniculitis. Ziehl–Neelsen stain for acid-fast bacilli was negative and there was no growth from skin sent for culture. Investigations including a full blood count, calcium, amylase, serum angiotensin-converting enzyme inhibitor,  $\alpha_1$ -antitrypsin level and antistreptolysin titre were either normal or negative. Liver function tests revealed an elevated  $\gamma$ -glutamyl transpeptidase of 51 U/L (normal: < 35). The erythrocyte sedimentation rate over 1 h was slightly raised at 27 mm/h (normal: < 20). The chest X-ray was unremarkable. Mantoux test with tuberculin 1 in 10,000 was within normal limits.

She was treated with oral erythromycin, topical clobetasol propionate and systemic non-steroidal anti-inflammatory drugs. No further radiotherapy has been administered and the lesions completely resolved within 8 weeks.

Erythema nodosum is a reactive dermatosis with an unknown pathogenesis. In some patients with erythema nodosum an underlying disease such as streptococcal infection, sarcoid or tuberculosis is identified; however, in approximately one-half of the cases no causative factor can be found.<sup>2</sup> It is possible that radiation treatment has not been considered as a causative factor or that the association is not well recognized and for either reason therefore under-reported.

Another reactive dermatosis, Sweet's syndrome, has also been associated with radiotherapy.<sup>3</sup> This and erythema nodosum can occur simultaneously and may share a common mechanism of pathogenesis.<sup>4</sup> Takagawa *et al*. speculate that in patients with radiation-induced erythema nodosum, breakdown products of cancer cells destroyed by radiation might activate circulating antibodies and complement to form immune complexes thereby triggering the reaction. Erythema nodosum did not recur after the further sessions of radiotherapy and they proposed that this was because there was not enough residual tumour left to release breakdown products. The tumour in our patient had been surgically removed prior to radiotherapy and the onset of the erythema nodosum. Whatever the mechanism it seems certain that radiotherapy can act to trigger several reactive dermatoses.

Department of Dermatology,  
The Royal Marsden Hospital,  
Fulham Road, London SW3 6JJ, U.K.

L.A. FEARFIELD  
C.B. BUNKER

### References

- 1 Takagawa S, Nakamura S, Yokozeki H, Nishioka K. Radiation-induced erythema nodosum. *Br J Dermatol* 1999; **140**: 372–3.
- 2 Cribier B, Caille A, Heid E, Grosshans E. Erythema nodosum and associated diseases. A study of 129 cases. *Int J Dermatol* 1998; **37**: 667–72.
- 3 van der Meij EH, Epstein JB, Hay J *et al*. Sweet's syndrome in a patient with oral cancer associated with radiotherapy. *Eur J Cancer B Oral Oncol* 1996; **32B**: 133–6.
- 4 Waltz KM, Long D, Marks JG Jr, Billingsley EM. Sweet's syndrome and erythema nodosum: the simultaneous occurrence of two reactive dermatoses. *Arch Dermatol* 1999; **135**: 62–6.

### Interferon alpha 2b for treatment of complex cutaneous haemangiomas of infancy: a reduced dosage schedule

SIR, the treatment of complex infantile haemangiomas (IHs) with subcutaneous interferon (IFN)  $\alpha$ 2b or 2a is usually performed with doses as high as 2–3 million U/m<sup>2</sup> per day for many months.<sup>1</sup> We have previously reported on the efficacy of lower doses.<sup>2</sup> The efficacy of even lower IFN doses is described here.

Eight patients, six females and two males with complex cutaneous haemangiomas were studied. At the onset of treatment, their ages ranged from 2 to 11 months. Five