LANGERHANS CELLS AND MYCOSIS FUNGOIDES-A CRITICAL OVERVIEW OF THEIR PATHOGENIC ROLE IN THE DISEASE

Clinical and Experimental Dermatology 1990; 15: 7–12.

Langerhans cells and mycosis fungoides—a critical overview of their pathogenic role in the disease

D.BANI, N.PIMPINELLI,* S.MORETTI* AND B.GIANNOTTI* *Department of Human Anatomy and Histology, Section of Histology, V. le G.Pieraccini, 6 and * II Dermatological Clinic, Via della Pergola, 56, University of Florence, Florence, Italy*

Accepted for publication 4 *August* 1989

Summary

Skin biopsies from seven patients with mycosis fungoides in various clinical stages (patches, plaques, nodules) were studied immunohistochemically and ultrastructurally, with the aim of investigating and quantifying the distribution of Langerhans cells and their relationships to mycosis cells. Our findings have revealed that in patches and plaques both Langerhans cells and mycosis cells were numerous in the epidermis. Notwithstanding this, in all the specimens examined, only one Langerhans cell forming close contact with a mycosis cell was detected. In the nodules, Langerhans cells and mycosis cells were sparse in the epidermis and no contacts were seen between them. Moreover, in all the patients studied, only a single Langerhans cell was found in the dermal infiltrate without any closely related mycosis cells. Conversely, numerous interdigitating cells have been found in the dermis of patches and plaques, often tightly adhering to mycosis cells. In the nodule, a few scattered interdigitating cells were seen, but often these had close contacts with neoplastic lymphoid cells. These findings indicate that close apposition between Langerhans cells and mycosis cells, which led previous authors to hypothesize a persistent stimulatory action of Langerhans cells on T lymphocytes, eventually leading to the malignant transformation of the latter, is unusual in mycosis fungoides. Therefore, if such a pathogenic role may be attributed to accessory cells in mycosis fungoides it is more probably exerted by dermal interdigitating cells and not by Langerhans cells, as previously proposed.

Mycosis fungoides (MF) is an epidermotropic T-cell lymphoma in which epidermal exocytosis of neoplastic cells, the so-called mycosis cells (MCs) which maintain the surface markers of mature T-helper lymphocytes over a long period, takes place in skin lesions. These cells often tend to gather into clusters, giving rise to Pautrier micro-abscesses.

Besides MCs, immunohistochemical studies[1–3] have revealed the presence of numerous CD1a-positive dendritic cells, considered to be Langerhans cells (LCs), in the epidermis, either scattered among keratinocytes or in the Pautrier micro-abscesses. Electron microscopy[4–9] has confirmed that both MCs—characterized by irregularly indented, cerebriform nuclei—and LCs—recognized by the presence of typical Birbeck granules in their cytoplasms frequently occur in the epidermis of MF skin lesions. LCs were at times found forming close epithelial-like contacts with MCs, similar to those which LCs commonly establish with T lymphocytes in allergic contact dermatitis.[10,11] Furthermore, LCs from skin lesions of MF have been reported to contain cytoplasmic bodies resembling C-type retrovirus particles.[5,9] Based on these findings, it has been suggested that LCs may play a role in inducing the malignant transformation of T lymphocytes and in supporting their proliferative activity through aberrant chronic stimulation mimicking the events occurring in allergic contact dermatitis [4,12] and perhaps induced by viral infection.[5,13] However, the above studies did not assess whether or not the close contacts between LCs and MCs, which should be regarded as the key mechanism in the pathogenic hypothesis proposed, are a sufficiently constant finding to support a major role for LCs in MF.

In this study we performed a quantitative evaluation of the distribution of LCs and MCs and of the occurrence of contacts between these two cell types in the epidermis of skin lesions of MF at its various clinical stages, with the aim of better clarifying the role of LCs in this disease.

Methods

Ten biopsies were taken under local anaesthesia from skin lesions of seven patients with MF at various clinical stages

Correspondence: Dr D. Bani, Dipartimento di Anatomia Umana ed Istologia, Sezione di Istologia "Enrico Allara", V. le G. Pieraccini, 6, I-50139 Firenze, Italy.

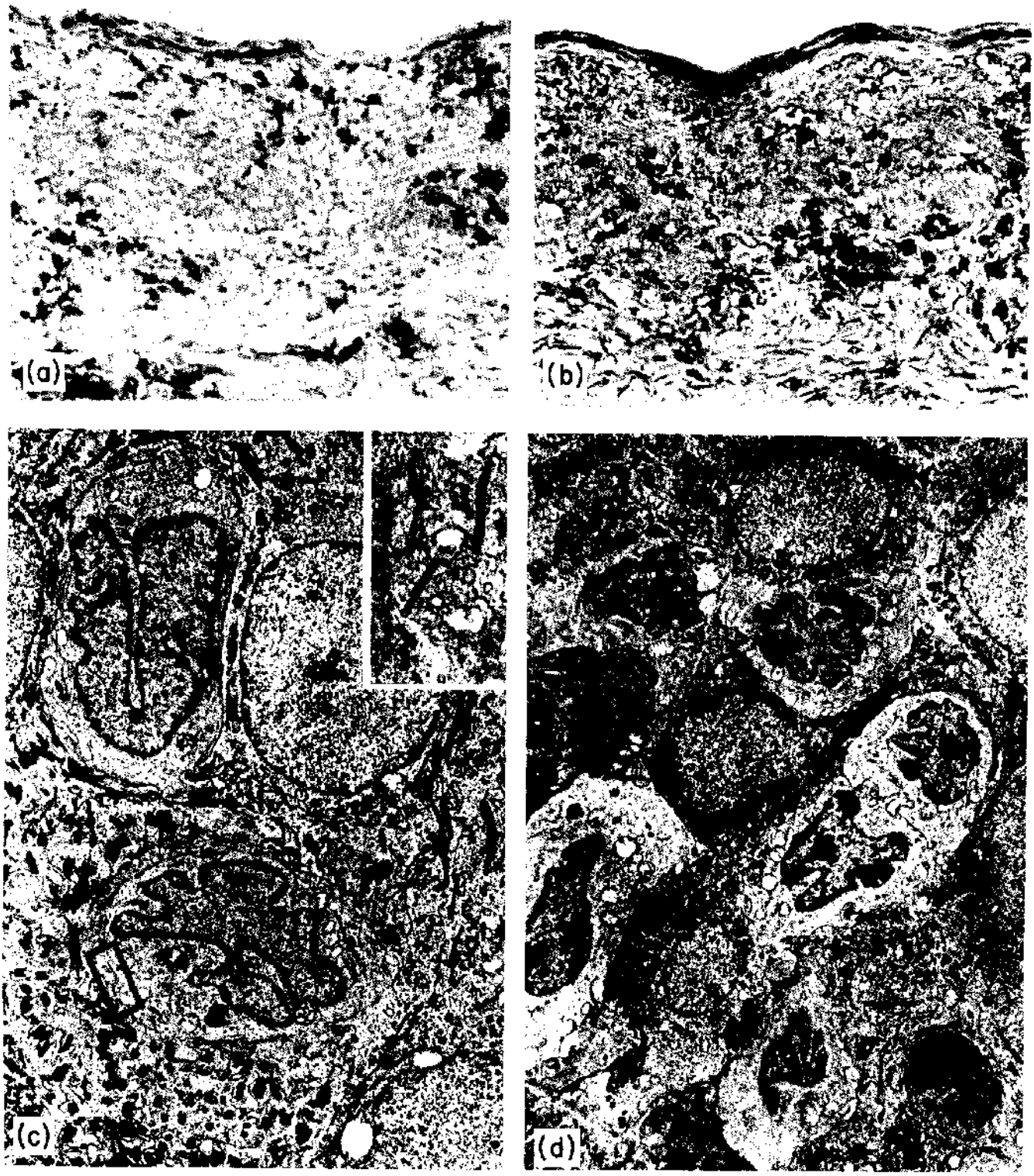

Figure 1. Patch stages of mycosis fungoides skin lesions: (a) numerous CD1a-positive dendritic cells are seen in the epidermis. Frozen section, immunoperoxidase method (magnification × 260); (b) numerous CD4-positive lymphoid cells infiltrating the epidermis are seen. Frozen section, immunoperoxidase method (magnification × 260); (c) two adjacent Langerhans cells are seen in the epidermis (EM × 5000); insert: detail of some Birbeck granules (magnification × 32000); (d) several mycosis cells can be seen infiltrating the epidermis (EM × 4450).

(four patches, four plaques, two nodules). Six of the seven patients had been treated with PUVA, topical steroids, or PUVA plus topical steroids, or antiblastic chemotherapy. Treatment was interrupted at least 2 months before biopsy in order to allow the LC population, which might have been damaged or reduced in number by the therapy, to be restored to pre-treatment levels.[14]

Immunohistochemistry

Two series of three consecutive 6-μm-thick sections were obtained per specimen with a cryostat. The first, second and third sections of each series were incubated with anti-CD2 (T11, Coulter Clone, UK), anti-CD4 (T4, Coulter Clone) and anti-CD1a (OKT6, Ortho, USA) monoclonal antibodies, respectively. The sections were subsequently incubated with sheep biotinylated anti-mouse serum (Amersham, UK) for 30 min at room temperature and then with streptavidin-biotin-peroxidase complex (Amersham) for 20 min at room temperature. Peroxidase activity was demonstrated by aminoethyl-carbazole and hydrogen peroxide. The sections were finally counter-stained with Mayer's haematoxylin. Normal human lymph nodes were used as positive controls. Sections incubated without the primary antibody or without any antibody were used as negative controls for the second polyclonal antibody and for the peroxidase enzymatic reaction, respectively. A quantitative analysis of the numbers of immunolabelled cells was performed by evaluating the number of positive cells over 100 cells per field with the nuclei in the plane of the section in six randomly chosen fields at $\times$ 400 magnification in each specimen. The values obtained by two different observers were then averaged, although the differences were negligible.

Electron microscopy

The tissue fragments were fixed in 4% glutaraldehyde in 0·1-mol/l cacodylate buffer (pH 7·4) for 3 h at room temperature and post-fixed in 1% OsO_4 in phosphate buffer (pH 7·4) for 2 h at 5°C. The specimens were dehydrated in an acetone series, passed through propylene-oxide and embedded in Epon 812. Semithin sections were cut from each biopsy specimen and examined by light microscopy in order to select epidermal tissue areas including either Pautrier micro-abscesses or numerous scattered non-keratinocyte cells. Consecutive ultrathin sections were obtained from these areas, stained with uranyl-acetate and alkaline bismuth-subnitrate, and examined with Siemens Elmiskop 102 electron microscope at 80 kV. An evaluation of the number of LCs and MCs in ultrathin sections was carried out following the quantitative method proposed by Kolde and Knop[15] with minor modifications. According to this method, consecutive ultrathin sections were collected before staining on formvar-coated 100-mesh grids, using the square openings of the grids as test areas. At least 10 test areas showing all epidermal layers and the upper dermis were evaluated per specimen. The test area was photographed at low magnification (about $\times$ 500) to determine the tissue reference area within the squares. LCs and MCs were then examined and counted directly on the microscope screen. This sampling procedure allows for approximately 60 LCs and MCs to be evaluated per biopsy.

Results

Immunohistochemistry

Quantitative analysis carried out on the immunostained sections of the skin lesions of MF revealed that CD1a-positive dendritic cells were quite numerous in the patches and the plaques in both the epidermis and the dermis (Fig. 1a), as well as CD2/CD4-positive lymphoid cells (Fig. 1b). In the nodules, both CD1a-positive dendritic cells and CD2/CD4-positive lymphoid cells were an occasional finding. Numerical data are listed in Table 1.

Table 1. Percentage of immunostained cells in MF skin lesions

	Patches				Plaques				Nodules	
Antibodies	1	2	3	4	5	6	7	8	9	10
Epidermis										
T11 (CD2)	8	6	9	4	9	10	7	6	1	3
T4 (CD4)	7	6	6	5	7	7	8	4	1	2
T6 (CD1a)	23	18	21	16	16	19	22	14	4	6
Dermis										
T11 CD2)	70	85	60	75	60	80	60	80	10	10
T4 (CD4)	70	70	50	60	60	65	50	60	<5	5
T6 (CD1a)	20	10	30	15	25	10	25	20	<5	<5

Electron microscopy

LCs and MCs were numerous in the epidermis of skin lesions from the six patients with patches and plaques (Fig. 1c,d) and were distributed through all the basal and spinous layers. Despite this, no LCs could be found in the Pautrier micro-abscesses, which only contained MCs and cell remnants, nor were close contacts detected between LCs and MCs in five of the six patients. In the remaining patient, only two LCs of the 25 encountered were seen near to MCs, but of these only one showed close apposition with a MC (Fig. 2a). In the lesions of the patient with nodules a few LCs and MCs were found dispersed singly among keratinocytes and they were never seen tightly apposed. Moreover, only in one case

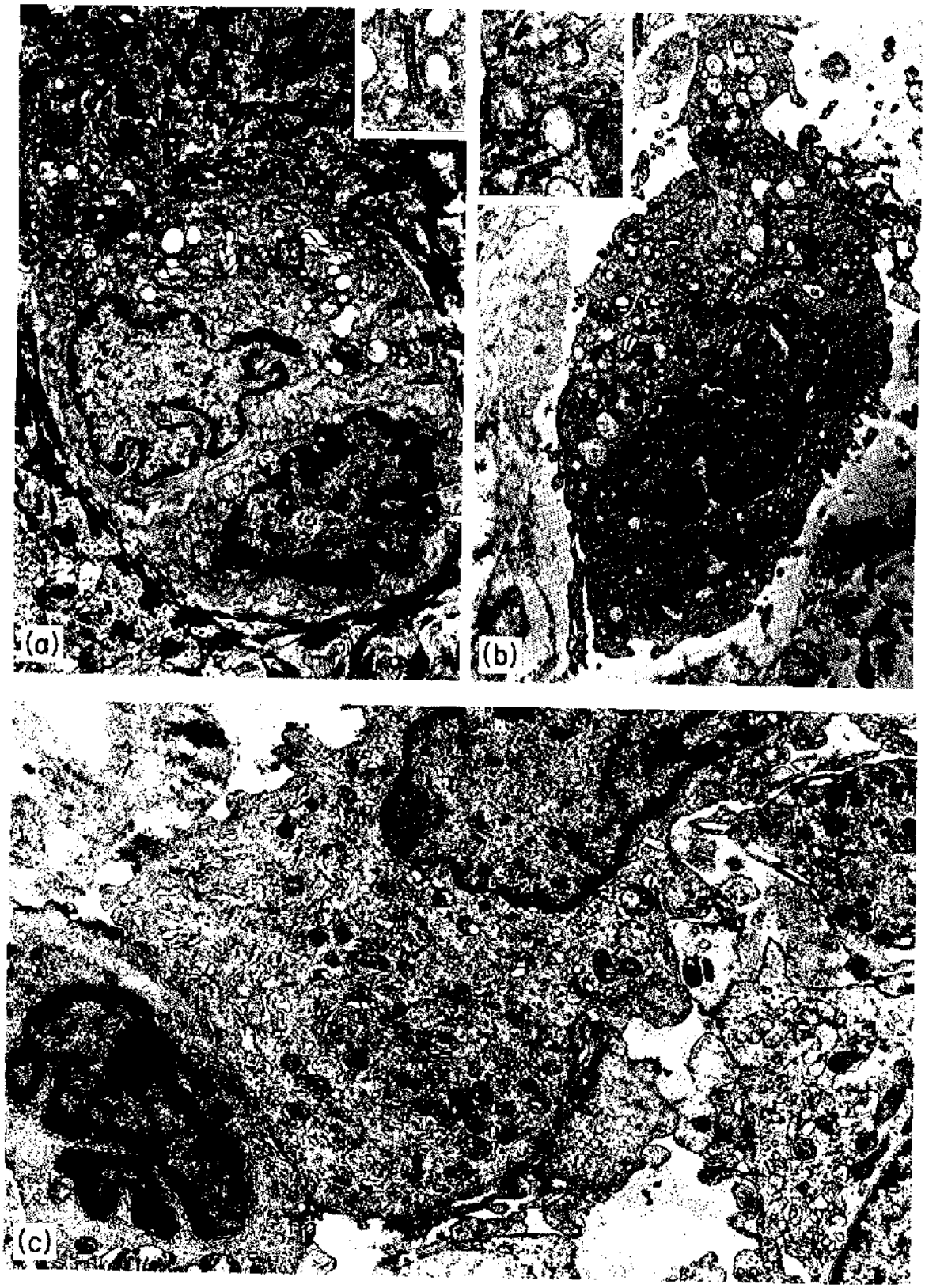

Figure 2. Patch stages of mycosis fungoides skin lesions: (a) a Langerhans cell (upper) is seen in close apposition to a lymphoid cell (lower) (EM × 10 000); insert: detail of a Birbeck granule (magnification × 60 000); (b) a Langerhans cell, containing several Birbeck granules, is seen in the dermis without mycosis cells nearby (EM × 10 000); insert: detail of some Birbeck granules (magnification × 40 000); (c) an interdigitating cell, showing well-developed Golgi apparatus, several cisternae of endoplasmic reticulum and mitochondria and a few primary lysomes can be seen in the dermis tightly adhering to a mycosis cell (lower left) (EM × 12 000).

(patch) was a single LC found in the dermal infiltrate and there were no MCs in its vicinity (Fig. 2b).

On the other hand, large numbers of cells with the cytological features of interdigitating cells (IDCs) were found in the dermal infiltrate in both patches and plaques. These cells showed an oval, indented nucleus with small chromatin clumps, a large cytoplasm protruding into several, branched processes and containing well-developed Golgi apparatus, numerous cisternae of endoplasmic reticulum and mitochondria and a few primary lysosomes. IDCs were often tightly adherent to MCs (Fig. 2c). Few and scattered IDCs were seen in the nodules; when found they were often in contact with neoplastic lymphoid cells. It should be stressed that Birbeck granules were never observed in these cells in the dermis.

Finally, despite a thorough search, no virus-like particles were found either in LCs and IDCs or in MCs in any of the cases examined.

Discussion

Present findings indicate that close relationships between LCs and MCs are occasional in MF. In fact, only once was tight apposition seen between these two cell types in the epidermis, although they were numerous in the patches and plaques as compared with normal epidermis. Here LCs are known to be located mainly in the upper spinous layers and represent no more than 4–8% of the epidermal cells, and lymphoid cells are virtually absent.[16] Moreover, in the MF skin lesions, no LCs were detected in the Pautrier micro-abscesses and the single LC which was found in the dermis had no contact with the numerous MCs nearby. Virus-like particles could not be found in any of the cases studied. Based on the above findings, it seems unlikely that LCs play a pathogenic role in MF such as that previously suggested, in which the close apposition between LCs and epidermotropic T cells has been proposed as a clue for the transmission of proliferative and even tranforming—stimuli from the former to the latter cells.[4,5,12,13] Indeed, it is at present widely accepted that LCs play a role in the afferent phase of the cell-mediated immune response by taking foreign antigens and carrying them via lymphatic vessels to the lymph nodes draining skin.[17–19] Another kind of accessory cell seems to be involved in the activation of lymphocytes through intimate contacts, namely IDCs, which are thought to develop from LCs after they migrate into the lymph node[20] and are known to be able to express CD1a antigen.[21–23] Hence, if a possible pathogenic role could be attributed to accessory cells in MF, this should most probably be assigned to IDCs, not LCs, the former being very numerous in the dermal infiltrate of MF[22,23] as well as in skin lesions from patients with Sezary's syndrome.[24] They are frequently apposed to lymphoid cells. In fact, although binding between accessory and lymphoid cells is probably a dynamic phenomenon, and morphological analysis cannot definitely demonstrate a functional interaction, it is noteworthy that such binding has constantly been found in the dermis between IDCs and MCs.

In this context, the large numbers of LCs in the epidermis of patches and plaques may be considered to be an epiphenomenon related to the intra-epidermal migration of precursors to accessory cells from the dermis where they congregate and differentiate into IDCs. Interleukin-1 has been found to be elevated in the epidermis of MF patients[25] and it is conceivable that, through the release by keratinocytes of chemotactic factors such as this, some precursors may be attracted into the epidermis where they develop into LCs, as we have previously observed.[26]

References

1. Mackie RM, Turbitt ML. The use of a double-label immunoperoxidase monoclonal antibody technique in the investigation of patients with mycosis fungoides. *British Journal of Dermatology* 1982; **106**: 379–384.
2. Ralfkiaer E, Lange-Wantzin G, Mason DY, Hou-Jensen K, Stein H, Thomsen K. Phenotypic characterization of lymphocyte subsets in mycosis fungoides. Comparison with large plaque parapsoriasis and benign chronic dermatoses. *American Journal of Clinical Pathology* 1985; **84**: 610–619.
3. Drijkoningen M, De Wolf-Peeters C, Snauwaert J, De Greef H, Desmet V. Immunohistochemical study of epidermal Langerhans cells and dermal dendritic cells in benign and malignant skin lesions characterized by a dermal lymphoid infiltrate consisting either of B-cells or T-cells. *Virchows Archiv. A, Pathological Anatomy and Histopathology* 1987; **411**: 337–343.
4. Rowden G, Lewis MG. Langerhans cells: involvement in the pathogenesis of mycosis fungoides. *British Journal of Dermatology* 1976; **95**: 665–672.
5. van der Loo EM, van Muijen GNP, van Vloten WA, Beens W, Scheffer E, Meijer CJLM. C-type virus-like particles specifically localized in Langerhans cells and related cells of skin and lymph nodes of patients with mycosis fungoides and Sezary's syndrome. *Virchows Archiv. B, Cell Pathology* 1979; **31**: 193–203.
6. Schmitt D, Thivolet J. Lymphocyte-epidermis interactions in malignant epidermotropic lymphomas: I-ultrastructural aspects. *Acta Dermato-Venereologica (Stockholm)* 1980; **60**: 1–11.
7. Holden CA, Morgan EW, MacDonald DM. A technique for immunoultrastructural identification of T6-positive Langerhans cells and indeterminate cells in mycosis fungoides. *Journal of Investigative Dermatology* 1982; **79**: 382–384.
8. Jimbow K, Chiba M, Horikoshi T. Electron microscopic identification of Langerhans cells in the dermal infiltrates of mycosis fungoides. *Journal of Investigative Dermatology* 1982; **78**: 102–107.
9. Fuellbrandt U, Meissner K, Loening T, Jaenner M. A second look at intraepithelial Langerhans cells in mycosis fungoides and related disorders. Ultrastructural study with special reference to Langerhans granules and virus-like particles. *Virchows Archiv. A, Pathological Anatomy and Histopathology* 1983; **402**: 47–60.
10. Silberberg I. Ultrastructural studies of Langerhans cells in contact sensitivity and primary irritant reactions to mercuric chloride. *Clinical Research* 1971; **19**: 715–721.
11. Stingl F, Katz SI, Shevack EM, Rosenthal AS, Green I.

Analogous function of macrophages and Langerhans cells in the initiation of the immune response. *Journal of Investigative Dermatology* 1978; **71**: 59–64.

12. Tan RSM, Butterworth CM, McLaughlin H, Malka S, Samman PD. Mycosis fungoides: a disease of antigen persistence. *British Journal of Dermatology* 1971; **91**: 607–616.
13. MacKie RM. Initial event in mycosis fungoides of the skin is viral infection of epidermal Langerhans cells. *Lancet* 1981; **ii**: 283–285.
14. Murphy GF, Messadi D, Fonferko E, Hancock WW. Phenotypic transformation of macrophages to Langerhans cells in the skin. *American Journal of Pathology* 1986; **123**: 401–406.
15. Kolde G, Knop J. Ultrastructural morphometry of epidermal Langerhans cells: introduction of a simple method for a comprehensive quantitative analysis of the cells. *Archives of Dermatological Reasearch* 1986; **278**: 291–301.
16. Smolle J, Ehall R, Kerl H. Inflammatory cell types in normal human epidermis. An immunohistochemical and morphometric study. *Acta Dermato-Venereologica (Stockholm)* 1985; **65**: 479–483.
17. Balfour BM, Drexhage HA, Kamperdijk EWA, Hoefsmith ECM. Antigen-presenting cells, including Langerhans cells, veiled cells and interdigitating cells. In: *Microenvironments in Haemopoietic and Lymphoid Differentiation*. London: Pitman Medical, 1981: 281–301.
18. Hoefsmith ECM, Duijvestijn AM, Kamperdijk EWA. Relation between Langerhans cells, veiled cells and interdigitating cells. *Immunobiology* 1982; **161**: 255–265.
19. Macatonia SE, Knight SC, Edwards AJ, Griffiths S, Fryer P. Localization of antigen on lymph node dendritic cells after exposure to the contact sensitizer fluorescein isothiocyanate. Functional and morphological studies. *Journal of Experimental Medicine* 1987; **166**: 1654–1667.
20. Veldman JE, Kaiserling E. Interdigitating cells. In: Carr I, Daems WT, eds. *The Reticuloendothelial System*, Vol. 1. New York: Plenum Publishing Corp., 1980: 381–416.
21. Ralfkiaer E, Stein H, Plesner T, Hou-Jensen K, Mason D. *In situ* immunological characterization of Langerhans cells with monoclonal antibodies: comparison with other dendritic cells in skin and lymph nodes. *Virchows Archiv. A, Pathological Anatomy and Histopathology* 1984; **403**: 401–412.
22. Bani D, Moretti S. Are Langerhans cells usual components of the dermal infiltrate of mycosis fungoides? *Archives of Dermatological Research* 1987; **279**: 561–563.
23. Bani D, Moretti S, Pimpinelli N, Giannotti B. Interdigitating cells in the dermal infiltrate of mycosis fungoides. An ultrastructural and immunohistochemical study. *Virchows Archiv. A, Pathological Anatomy and Histopathology* 1988; **412**: 451–458.
24. Romagnoli P, Moretti S, Fattorossi A, Giannotti B. Dendritic cells in the dermal infiltrate of Sezary syndrome. *Histopathology* 1986; **101**: 25–36.
25. Tron VA, Rosenthal D, Sauder DN. Epidermal interleukin-1 is increased in cutaneous T-cell lymphoma. *Journal of Investigative Dermatology* 1988; **90**: 378–381.
26. Bani D, Moretti S, Pimpinelli N, Giannotti B. Differentiation of monocytes into Langerhans cells in human epidermis. An ultrastrucural study. In: Thivolet J, Schmitt D, eds. *The Langerhans Cell*. Montrouge, London: John Libbey, 1988: 75–83.