



UNIVERSITÀ
DEGLI STUDI
FIRENZE

FLORE

Repository istituzionale dell'Università degli Studi
di Firenze

**SCLEROSING EPITHELIAL HAMARTOMA ASSOCIATED WITH A
MELANOCYTIC COMPOUND NEVUS**

Questa è la Versione finale referata (Post print/Accepted manuscript) della seguente pubblicazione:

Original Citation:

SCLEROSING EPITHELIAL HAMARTOMA ASSOCIATED WITH A MELANOCYTIC COMPOUND NEVUS / N. PIMPINELLI; C. URSO; U. REALI. - In: THE JOURNAL OF DERMATOLOGIC SURGERY AND ONCOLOGY. - ISSN 0148-0812. - STAMPA. - 13:(1987), pp. 1124-1126.

Availability:

This version is available at: 2158/25501 since:

Terms of use:

Open Access

La pubblicazione è resa disponibile sotto le norme e i termini della licenza di deposito, secondo quanto stabilito dalla Policy per l'accesso aperto dell'Università degli Studi di Firenze (<https://www.sba.unifi.it/upload/policy-oa-2016-1.pdf>)

Publisher copyright claim:

(Article begins on next page)

***Sclerosing Epithelial Hamartoma
Associated with a Melanocytic
Compound Nevus***

N. PIMPINELLI, M.D.
C. URSO, M.D.
U.M. REALI, M.D.

CASE REPORT

Sclerosing Epithelial Hamartoma Associated with a Melanocytic Compound Nevus

N. PIMPINELLI, M.D.
C. URSO, M.D.
U.M. REALI, M.D.

CASE REPORT

Abstract. A case of sclerosing epithelial hamartoma in a 19-year-old female is reported. The lesion, presenting the distinctive clinical and histologic features, was associated with a melanocytic compound nevus. This unusual and interesting event is discussed.

In cutaneous pathology, adnexal neoplasms represent a large group of lesions whose variety is the mirror of the complex skin architecture. In 1977, a distinctive clinical and pathologic entity was simultaneously reported as sclerosing epithelial hamartoma¹ and desmoplastic trichoepithelioma.² Clinically, it features a solitary, small, firm nodule or plaque, white or yellowish in color, often with a depressed center and a slightly raised, threadlike periphery, most commonly found on the face.

The main histologic findings are narrow strands of epithelial basaloid cells and keratinous cysts randomly intermingled in a fibrous hypocellular stroma. This peculiar lesion had been previously reported under other titles, most often as solitary trichoepithelioma.³⁻⁹

N. Pimpinelli, M.D., Resident, II Department of Dermatology; C. Urso, M.D., Resident, Department of Pathology; and U. M. Reali, M.D., Associate Professor of Plastic Surgery, and Head, Plastic Surgery Unit, are from The University of Florence, Florence, Italy.

Address reprint requests to U. M. Reali, M.D., Chirurgia Plastica Dermatologica, Via della Pergola 58, 50121 Firenze, Italy.

CASE REPORT

A 19-year-old girl came to us in November 1985 presenting a pigmented nodule on the left cheek. The lesion had a diameter of 9 mm, was firm, and showed a sicklelike slight depression with a thin border of milia on the medial side (Fig. 1). The lesion was entirely excised.

Histologic examination of the lesion showed a focal epidermal hyperplasia with acanthosis and hyperkeratosis. Small nests of melanocytes were observed at the dermo-epidermal junction (Fig. 2). Papillar and reticular dermis contained a considerable number of nevus cells, alone or grouped in



FIGURE 1. The pigmented nodule on the left cheek shows a slight, sickle-like depression with a thin border of milia on its medial side.



FIGURE 2. Small nests of melanocytes at the dermo-epidermal junction. In the dermis (lower left side), some strands of basaloid cells are recognizable.

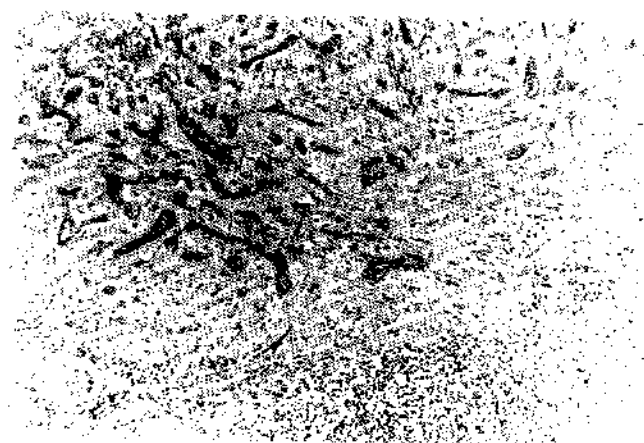


FIGURE 3. In the superficial dermis, narrow strands of epithelial basaloid cells are scattered in a fibrous, hypocellular stroma. A nest of nevus cells appears in the underlying reticular dermis.

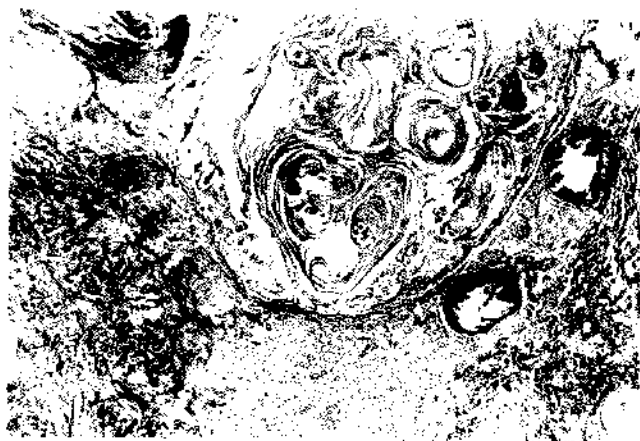


FIGURE 4. Keratinous cystic structures in the dermis.

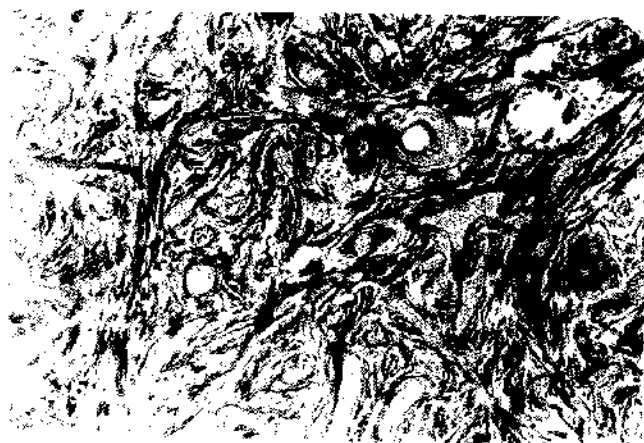

FIGURE 5. Strands of basaloid cells are intermingled with keratinous cysts in a fibrous stroma, with condensed collagen.

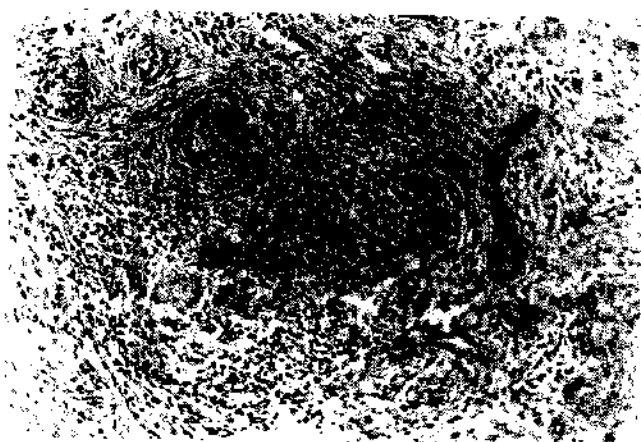


FIGURE 6. Nevus cells and sclerosing epithelial hamartoma are closely associated.

small nests (Fig. 3). Various sized, calcific keratinous cysts were often observed in the adjoining dermis. The cystic wall was sometimes present in the form of keratinizing squamous epithelium (Fig. 4). Foreign-body giant cells were focally observed where the keratinous material contacted the dermal connective tissue. Narrow strands of epithelial cells, linear or occasionally branched, were intermingled with the keratinous cysts (Fig. 5). These strands were composed of small cuboidal basaloid cells, with a round or oval, darkly staining nuclei, without cytologic atypias. Keratinous cysts and epithelial strands were scattered in a fibrous, hypocellular stroma with a condensed collagen. In some zones, nevus cells and sclerosing epithelial hamartoma were closely associated (Fig. 6).

DISCUSSION

This case shows the peculiar features of sclerosing epithelial hamartoma associated with a melanocytic compound nevus. The presence of a firm nodule with a thin border of milia and the histologic finding of keratinous cysts and epithelial basaloid strands intermingled in a fibrous hypocellular stroma are distinctive. The occasional finding of a pericyclic giant-cell reaction represents a further, secondary element for the diagnosis.^{1,2} The clinical differential diagnosis with sebaceous hyperplasia and granuloma annulare (in its milder or initial expressions) is generally allowed by the less firm consistency of these two lesions.^{1,2} The major diagnostic problem is the histologic differentiation of sclerosing epithelial hamartoma from other benign cutaneous hamartomas (solitary trichoepithelioma, syringoma), and from morphea-like basal cell carcinoma.^{1,2,10-12}

In morphea-like basal cell carcinoma, keratinous cysts are constantly absent, whereas solid islands of epithelial basaloid cells with peripheral palisading are observed. Elongated strands of tumor cells often extend deeply into the dermis, and the tumor is not usually symmetric in its overall architecture. In solitary trichoepithelioma, narrow strands of epithelial basaloid cells are usually absent, the stroma is looser and more cellular in comparison to sclerosing epithelial hamartoma, and there is often evidence of germ hair induction. Syringoma does not usually show keratinous cysts and often exhibits several small ducts lined with flat, sometimes vacuolated cells. Less frequently, sclerosing epithelial hamartoma must be distinguished from cutaneous metastases from breast carcinoma.^{1,2,10,11} These metastases may sometimes produce strands of basophilic cells that usually comprise a single line of cells, often in an "Indian file" pattern. A desmoplastic reaction is possible.

Cytologic atypias, the absence of keratinizing cysts, the possible presence of large masses of tumor cells, and the frequent involvement of the subcutis generally allow the diagnosis of cutaneous metastases from breast carcinoma. The histogenesis of sclerosing epithelial hamartoma has not been

clarified until now, and some recent ultrastructural studies^{13,14} did not conclusively indicate an origin from hair follicles.

Sclerosing epithelial hamartoma is quite an unusual lesion and its association with a melanocytic nevus represents a very rare observation. Presently, it is not possible to show a relation between these two lesions.¹⁵ The association is therefore interpretable as an unusual event in which a rare lesion has developed along with a common one.

REFERENCES

1. MacDonald DM, Wilson Jones E, Marks R. Sclerosing epithelial hamartoma. *Clin Exp Dermatol* 2:153-160, 1977.
2. Brownstein MH, Shapiro H. Desmoplastic trichoepithelioma. *Cancer* 40:2979-2986, 1977.
3. Walters M. Epithelioma adenoides cysticum. *Arch Dermatol Syphil* 56:88-100, 1901.
4. Schopper KJ. Epithelioma adenoides cysticum (Brooke). *Arch Dermatol Syphil* 98:199-214, 1909.
5. Zeligman I. Solitary trichoepithelioma. *Arch Dermatol* 82:35-40, 1960.
6. Gray HR, Helwig EB. Epithelioma adenoides cysticum and solitary trichoepithelioma. *Arch Dermatol* 87:102-114, 1963.
7. Philipps A. Hair follicle hamartoma. *Trans St John's Hospital Dermatol Soc* 56:207, 1970.
8. Nasemann T, Schropf F, Wollenweber J, Schmarsow R. Atypisches, isoliertes trichoepitheliom am kinn. *Hautarzt*, 24:105-110, 1973.
9. Headington JT. Tumors of the hair follicle. *Am J Pathol*, 85:479-515, 1976.
10. Bernstein G, Roth CJ. Sclerosing Epithelial Hamartoma. *J Dermatol Surg Oncol* 4:87-90, 1978.
11. Rahbari H, Mehregan AH. Benign follicular neoplasias. *J Dermatol Surg Oncol* 5:295-298, 1979.
12. Takei Y, Fukushiro S, Arkerman AB. Criteria for histologic differentiation of desmoplastic trichoepithelioma (sclerosing epithelial hamartoma) from morphea-like basal cell carcinoma. *Am J Dermatopathol* 7:207-221, 1985.
13. Bondi R, Santucci M, Reali UM, Donati E, Giannotti B. An ultrastructural study of a sclerosing epithelial hamartoma. *Am J Dermatopathol* 7:223-229, 1986.
14. Dervan PA, O'Hegarty M, O'Loughlin S, Corrigan T. Solitary familial desmoplastic trichoepithelioma. A study by conventional and electron microscopy. *Am J Dermatopathol* 7:277-282, 1985.
15. Rahbari H, Mehregan AH. Trichoepithelioma and pigmented nevus: A combined malformation. *J Cutan Pathol* 2:225-229, 1975.