UNIVERSITÀ DEGLI STUDI FIRENZE

FLORE
Repository istituzionale dell'Università degli Studi di Firenze

CYTOTOXIC/NATURAL KILLER CELL CUTANEOUS LYMPHOMAS: REPORT OF THE E.O.R.T.C. CUTANEOUS LYMPHOMA TASK FORCE WORKSHOP.

Questa è la Versione finale referata (Post print/Accepted manuscript) della seguente pubblicazione:

Original Citation:

CYTOTOXIC/NATURAL KILLER CELL CUTANEOUS LYMPHOMAS: REPORT OF THE E.O.R.T.C. CUTANEOUS LYMPHOMA TASK FORCE WORKSHOP / M. SANTUCCI; N. PIMPINELLI; D. MASSI; M.E. KADIN; C.J.L.M. MEIJER; H.K. MULLER-HERMELINK; M. PAULLI; J. WECHSLER; R. WILLEMZE; H. AUDRING; M.G. BERNENGO; L. CERRONI.. - In: CANCER. - ISSN 0008-543X. - STAMPA. - 97:(2003), pp. 610-627.

Availability:

This version is available at: 2158/216793 since:

Terms of use:

Open Access

La pubblicazione è resa disponibile sotto le norme e i termini della licenza di deposito, secondo quanto stabilito dalla Policy per l'accesso aperto dell'Università degli Studi di Firenze (https://www.sba.unifi.it/upload/policy-oa-2016-1.pdf)

Publisher copyright claim:

(Article begins on next page)

12 October 2024

Cytotoxic/Natural Killer Cell Cutaneous Lymphomas

Report of the EORTC Cutaneous Lymphoma Task Force Workshop

Marco Santucci, M.D.[1]
Nicola Pimpinelli, M.D., Ph.D.[2]
Daniela Massi, M.D., Ph.D.[1]
Marshall E. Kadin, M.D.[3]
Chris J. L. M. Meijer, M.D.[4]
Hans Konrad Müller-Hermelink, M.D.[5]
Marco Paulli, M.D.[6]
Janine Wechsler, M.D.[7]
Rein Willemze, M.D.[8]
Heike Audring, M.D.[9]
Maria Grazia Bernengo, M.D.[10]
Lorenzo Cerroni, M.D.[11]
Sergio Chimenti, M.D.[12]
Andreas Chott, M.D.[13]
José L. Díaz-Pérez, M.D.[14]
Edgard Dippel, M.D.[15]
Lyn M. Duncan, M.D.[16]
Alfred C. Feller, M.D.[17]
Marie-Louise Geerts, M.D.[18]
Christian Hallermann, M.D.[19]
Werner Kempf, M.D.[20]
Robin Russell-Jones, M.D.[21]
Christian Sander, M.D.[22]
Emilio Berti, M.D.[23]

BACKGROUND. Cutaneous lymphomas expressing a cytotoxic or natural killer (NK) cell phenotype represent a group of lymphoproliferative disorders for which there is currently much confusion and little consensus regarding the best nomenclature and classification.

METHODS. This study analyzes 48 cases of primary cutaneous lymphoma expressing cytotoxic proteins and/or the NK cell marker, CD56. These cases were collected for a workshop of the European Organization for Research and Treatment of Cancer Cutaneous Lymphoma Task Force, to better clarify the clinical, morphologic, and phenotypic features of these uncommon tumors.

RESULTS. Several categories with different clinical and pathologic features were delineated: 1) aggressive, CD8+, epidermotropic, cytotoxic T-cell lymphoma; 2) mycosis fungoides, cytotoxic immunophenotype variant; 3) subcutaneous panniculitis-like T-cell lymphoma; 4) NK/T-cell lymphoma, nasal type; 5) CD4+, NK cell lymphoma; 6) blastoid NK cell lymphoma; (7) intravascular NK-like lymphoma; and 8) cytotoxic, peripheral T-cell lymphoma.

CONCLUSIONS. Our data show that primary cutaneous cytotoxic/NK cell lymphomas include distinct groups of diseases, clinically, histologically, and biologically. Because the finding of a cytotoxic phenotype often has prognostic significance, the routine use of cytotoxic markers in the diagnosis and classification of cutaneous lymphomas should be expanded. ***Cancer* 2003;97:610–27.**

© 2003 American Cancer Society.

DOI 10.1002/cncr.11107

KEYWORDS: cytotoxic/NK cell lymphomas, skin, classification, CD56, TIA-1, prognosis, therapy.

[1] Department of Human Pathology and Oncology, University of Florence Medical School, Florence, Italy.

[2] Department of Dermatological Sciences, University of Florence Medical School, Florence, Italy.

[3] Section of Hematopathology, Department of Pathology, Beth Israel Deaconess Medical Center, Harvard Medical School, Boston, Massachusetts.

[4] Department of Pathology, Free University Hospital, Amsterdam, The Netherlands.

[5] Institute of Pathology, University of Würzburg, Würzburg, Germany.

[6] Department of Pathology, IRCCS San Matteo Hospital, Pavia, Italy.

[7] Department of Pathology, Henry Mondor Hospital, Paris, France.

[8] Department of Dermatology, University of Leiden, Leiden, The Netherlands.

[9] Department of Dermatology, Charité Humboldt University, Berlin, Germany.

[10] Department of Dermatology, University of Turin, Turin, Italy.

[11] Department of Dermatology, University of Graz, Graz, Austria.

[12] Department of Dermatology, University of Rome "Tor Vergata," Rome, Italy.

[13] Institute for Clinical Pathology, University of Vienna, Vienna, Austria.

[14] Department of Dermatology, Cruces Hospital, University of Bilbao, Bilbao, Spain.

[15] Department of Dermatology, "Benjamin Franklin" University Hospital, Berlin, Germany.

[16] Dermatopathology Unit, Massachusetts General Hospital, Harvard Medical School, Boston, Massachusetts.

[17] Institute of Pathology, Medical University of Lübeck, Lübeck, Germany.

[18] Department of Dermatology, University Hospital of Gent, Gent Belgium.

[19] Department of Dermatology, "Georg August" University of Göttingen, Göttingen, Germany.

[20] Department of Dermatology, University Hospital of Zurich, Zurich, Switzerland.

[21] Skin Tumour Unit, St. John's Institute of Dermatology, St. Thomas' Hospital, London, United Kingdom.

[22] Department of Dermatology, "Ludwig Maximilians" University of Munich, Munich, Germany.

[23] Institute of Dermatological Sciences, University of Milan, Milan, Italy.

Address for reprints: Marco Santucci, Dipartimento di Patologia Umana ed Oncologia, Universitá degli Studi di Firenze, Viale G.B. Morgagni, 85 50134 Firenze, Italy; Fax: 011-39-055-4379868; E-mail: Marco.Santucci@UNIFI.IT

Received July 30, 2002; revision received August 14, 2002; accepted August 27, 2002.

© 2003 American Cancer Society

Several subtypes of cutaneous lymphomas (although reported in the current literature and recently included in the World Health Organization [WHO] classification[1]) are not yet mentioned, or are included as provisional entities, in the Cutaneous Lymphoma Study Group of the European Organization for Research and Treatment of Cancer (EORTC) classification.[2] This is the result of the absence of a distinctive clinicopathologic presentation. Among the categories of this "gray" area, cutaneous lymphomas expressing a cytotoxic or natural killer (NK) cell phenotype represent a group of lymphoproliferative disorders for which there is currently much confusion and little consensus regarding the best nomenclature and classification. In particular, the rarity of tumors expressing the NK cell phenotype, especially in Western countries, represents a major limitation to a complete understanding. The recognition of lymphoid neoplasms expressing a cytotoxic or an NK-like phenotype may have relevant clinical and therapeutic implications because it has been reported that many of them follow an aggressive clinical course.[3–6]

The aim of this report is to describe the spectrum of primary cutaneous lymphomas expressing cytotoxic proteins and/or the NK cell marker, CD56, and to better clarify their clinical, morphologic, and phenotypic features.

MATERIALS AND METHODS

A workshop of the EORTC Cutaneous Lymphoma Task Force was held on July 3–5, 1998, at the Study Center "I Cappuccini," S. Miniato (Pisa, Italy). Cases were solicited on the following topics: 1) lymphomas in which tumor cells expressed at least one of the following molecules, namely, CD8, TIA-1, or CD56; 2) lymphoma showing features of subcutaneous or angiocentric lymphoma; and 3) lymphoma expressing the γ/δ phenotype. Sixty examples of primary cutaneous lymphoma exhibiting one the aforementioned features were provided.

During the workshop, there was a plenary discussion on the definition and differential diagnosis of cytotoxic and nonnasal NK/T-cell primary cutaneous lymphomas, but some gray areas still remained. To solve residual problems, a committee composed of 10 experienced dermatopathologists or hematopathologists (EB, MEK, DM, CJLMM, HKM-H, MP, NP, MS, JW, RW) was appointed. They met on January 16–18, 1999, at the Department of Human Pathology and Oncology, University of Florence Medical School, Florence, (Italy). This report summarizes the results of both the plenary and committee discussions. Forty-eight cases of appropriate immunophenotype were identified and included in the present study. Four of these cases have been included in previous studies on various lymphoma types.[7–10]

Clinical records and follow-up data through December 1999 were obtained from patients' charts. The principal parameters evaluated included age and gender, extent of disease, spontaneous regression, symptoms at presentation, bone marrow involvement, cutaneous recurrences, extracutaneous progression of disease, treatment, and follow-up duration (Table 1).

The TIA-1 and CD56 status was determined immunohistochemically on paraffin sections using the antibodies TIA-1 (Coulter, Miami, FL) and 123C3 (LabVision, Fremont, CA), respectively. In previous studies, other authors have shown that 123C3 reliably detects CD56 expression in lymphomas on paraffin-embedded tissues.[5] Additional immunohistochemical data were provided by the source institutions. Epstein–Barr virus (EBV) infection was demonstrated using nonisotopic in situ hybridization for EBV-encoded small RNAs (EBERs) on paraffin-embedded material, as previously described,[11] as well as by immunohistochemistry with antibodies against LMP-1 or by polymerase chain reaction (PCR). The DNA used for gene rearrangement studies was extracted from frozen or paraffin-embedded tumor tissue. T-cell receptor (TCR) gene rearrangement was evaluated by a PCR assay coupled with nondenaturing polyacrylamide gel electrophoresis according to a method previously described.[12] Amplification of the TCR-γ chain locus V-J junctional region was performed by using oligonucleotide primers specific for J1/2 paired with V2a, V9, and V10. In some cases, DNA was digested with restriction endonuclease *Bam*HI, *Eco*RI, or *Hind*III, subjected to electrophoresis on a 0.8% agarose gel, and transferred to a nitrocellulose filter for Southern analysis using hybridization with ^{32}P-labeled DNA probes, according to standard protocols.[13,14] Rearrangements of the TCR and immunoglobulin genes were evaluated using probes that include a 1.0-kb germline Pst-EcoRI fragment containing the first region (Jδ1), the constant region of TCR-β gene (Cβ), the TCR-γ gene, and JH (heavy-chain joining region).[15]

RESULTS

Several groups with different clinical (Table 1) and pathologic features were delineated among these 48 cases.

Cases 1–4: Aggressive, CD8+, Epidermotropic, Cytotoxic T-cell Lymphoma WHO: Not Recognized

Clinical features

This group included four male patients, 33–82 years of age (mean age, 62 years; median age, 76.5 years). Three of the four patients presented with widespread,

TABLE 1
Clinical Data and Follow-Up Information

Case no.	Gender/ age	Type of lesion	Sites of disease at presentation	Initial treatment	Subsequent treatment	Progression	Outcome (mos)
1	M/33	Plaques, nodules	Widespread	PUVA-PR	IFN-NR, TSEBI-NR, CT(CHOP)-NR	Skin, oral mucosa, and systemic involvement (sepsis)	DOD, 34
2	M/82	Nodules	Widespread	CT (COP) and RT-CR	CT (unspecified)	Skin and systemic involvement	DOD, 17
3	M/59	Plaques	Widespread	Topical nitrogen mustard-CR	CT (CHOP), RT, topical nitrogen mustard	Skin and systemic involvement	DOD, 28
4	M/74	Nodules	Lower limb	IFN and retinoids-PR	CT (CHOP)-PR	Skin and systemic involvement	DOD, 10
5	M/16	Patches, plaques	Widespread	PUVA-CR	N.A.	Skin	AWD, 24
6	M/30	Patches	Lower limb	PUVA-PR	Topical steroids-NR CT (miltefusine)-PR	Skin	AWD, 36
7	F/77	Plaques	Widespread	PUVA-PR	RT (TSEBI)-CR	Skin	AWD, 32
8	F/30	Patches	Trunk	PUVA-CR	Nil	Nil	NED, 30
9	F/59	Patches, plaques	Widespread	PUVA-CR	PUVA-PR	Skin	AWD, 144
10	F/54	Subcutaneous nodules	Limbs	Systemic steroids-CR	CT(cyclophosphamide)-PR	Skin	AWD, 96
11	M/14	Subcutaneous nodules	Limbs, buttocks	CT (ACVBP)-CR	Nil	Nil	NED, 15
12	F/55	Subcutaneous nodules	Limbs	Nil (spontaneous remission)	Nil (spontaneous remission)	Skin	AWD, 60
13	M/36	Subcutaneous nodules	Limbs	Topical steroids-CR	CT (CHOP, CDA, ara-C, others)-PR, RT (TSEBI)-PR	Skin and systemic involvement (hemophagocytic syndrome)	AWD, 24
14	M/53	Subcutaneous nodules	Limbs	Steroids and hydroxychlorokine-NR	CT (mitoxantrone, etoposide, vincristine, cyclophosphamide)-NR	Skin and systemic involvement (pancytopenia, sepsis)	DOD, 9
15	F/56	Subcutaneous nodules	Head, trunk, upper limb	Steroids-NR	CT (cyclophosphamide, CEOP)-NR	Skin and systemic involvement (pancytopenia, sepsis)	DOD, 24
16	M/10	Subcutaneous nodules	Trunk, upper limb	Steroids-NR	CT (cyclophosphamide, CEOP)-NR	Skin and systemic involvement (pancytopenia, sepsis)	DOD, 5
17	M/76	Subcutaneous nodules	Limbs[a]	N.A.	N.A.	Skin	AWD, 24
18	F/44	Subcutaneous nodules	Lower limb	CT (CHOP)-NR	CT (VIM2, ara-C)-NR	Skin and systemic involvement (liver and lung)	DOD, 17
19	F/8	Subcutaneous nodules	Trunk	Cyclosporine-PR	CT (unspecified)-NR	Skin and systemic involvement	DOD, 23
20	F/73	Subcutaneous nodules	Lower limb, buttocks	CT (CHOP)-PR	RT-PR, CT (methotrexate)-PR	Skin and systemic involvement (liver)	DOD, 12
21	F/33	Subcutaneous nodules	Limbs, buttocks	Steroids and retinoids-PR	N.A.	Skin and systemic symptoms (malaise, fatigue, and fever)	AWD, 12
22	M/53	Nodule	Upper limb[a]	N.A.	N.A.	N.A.	N.A.
23	F/27	Nodules	Head, trunk	Nil (spontaneous remission)	N.A.	N.A.	N.A.
24	F/43	Nodules	Upper limb	CT (CHOP)-CR	CT (unspecified)-PR	Skin,[b]	AWD, 10
25	M/71	Nodules	Trunk, limbs	CT (CHOP)-CR	CT (methotrexate)-CR	CNS	DOC (stroke), 3
26	M/60	Nodules	Head	CT (VICOP-B)-NR	CT (unspecified)-NR	Skin and systemic involvement (bone marrow)	DOD, 8
27	M/60	Papules, plaques	Widespread	CT (fludarabine)-CR	Nil	Nil	NED, 16
28	M/57	Plaques, nodules	Widespread	CT (unspecified)-PR	CT (unspecified)-PR	Skin	N.A.
29	F/47	Plaques	Head, lower limb	RT and CT (CHOP)-CR	IFN and CT (vincristine, chlorambucil)-PR	Skin and systemic involvement (lymph nodes, CNS)	DOD, 31
30	M/41	Plaques	Lower limb[a]	RT-CR	Nil	Nil	NED, 44
31	M/38	Plaques, nodules	Widespread	Nil	CT (PROMACE-CYTABOM) and allogeneic BMT-CR	Skin and systemic involvement (bone marrow and blood)	DOD, 22
32	M/83	Plaques, nodules	Trunk	CT (mini-CEOP)-CR	CT (unspecified)-NR	Skin and systemic involvement (bone marrow and blood)[b, c]	DOD, 10
33	M/80	Plaques, nodules	Head, trunk	CT (COP)-NR	CT (unspecified)-PR	Skin and systemic involvement (bone marrow)	DOD, 20
34	M/51	Nodules	Head, trunk	N.A.	N.A.	N.A.	N.A.
35	M/55	Plaques, nodules	Head, trunk	CT (MACOP-B)-CR	IFN, CT (chlorambucil), and steroids-NR, autologous BMT-CR	Skin and systemic involvement	N.A.
36	M/61	Plaques, nodules	Trunk, limbs	CT (CEOP)-CR	RT and CT (MACOP-B)-CR	Skin and systemic involvement (bone marrow, blood, and lymph nodes)	DOD, 37
37	M/58	Plaques, nodules	Widespread	CT (CHOP)-PR	CT (unspecified)-NR	Skin and systemic involvement (testis and bone marrow)	DOD, 16
38	M/54	Plaques	Trunk, lower limb	Antibiotic[d]	CT (CHOP)-CR	Skin and systemic involvement (CNS)	DOD, 17
39	F/72	Nodule	Head	RT-CR	Nil	Nil	NED, 36
40	M/43	Nodule	Upper limb	N.A.	N.A.	N.A.	N.A.
41	M/63	Nodules	Limbs, trunk	Nil (spontaneous remission)	Nil	Skin	NED, 12
42	F/60	Nodules	Limbs, trunk	Steroids and clofazimine-PR	N.A.	Skin	AWD, 60
43	F/63	Plaques	Lower limb	RT and CT (cyclophosphamide)-CR	Nil	Nil	NED, 36
44	M/60	Nodules	Limbs[e]	RT-NR,	CT (CDA, CHOP)-PR	Skin and systemic involvement (lymph nodes)	DOD, 18
45	F/38	Plaques, nodules	Trunk, limbs[f]	CT (unspecified)-CR		Nil	N.A.
46	F/76	Plaques	Limbs	Nil (spontaneous remission)	RT-PR	Skin and systemic involvement (lymph nodes, soft tissues, CNS)	DOD, 11
47	M/77	Nodule	Head	Surgery and RT-CR	N.A.	Skin and systemic involvement (pharyngeal mass)	DOD, 11
48	M/39	Nodule	Lower limb	RT-CR	RT + CT (CHOP)-PR	Skin and systemic involvement (soft tissues and bone marrow)	DOD, 12

AWD: Alive with disease; BMT: bone marrow transplantation; CNS: central nervous system; CR: complete remission; CT: chemotherapy; DOD: dead of disease; NR: no response; PR: partial remission; RT: radiotherapy; N.A.: information not available; NED: no evidence of disease; IFNα: -2 recombinant interferon; TSEBI: total skin electron beam irradiation; ara-C: cytosine arabinoside; PUVA: psoralen ultraviolet light; CHOP: cyclophosphamide, doxorubicin, vincristine, and prednisone.

[a] Myelodysplastic syndrome.

[b] Polypoidal thickening of the nasal/paranasal mucosa demonstrated at computed tomographic scan; biopsy not performed.

[c] Gastric carcinoma.

[d] Treatment for concomitant Borrelia Burgdorferi infection.

[e] Hairy cell leukemia.

[f] Lymphomatoid granulomatosis Epstein–Barr virus infection.

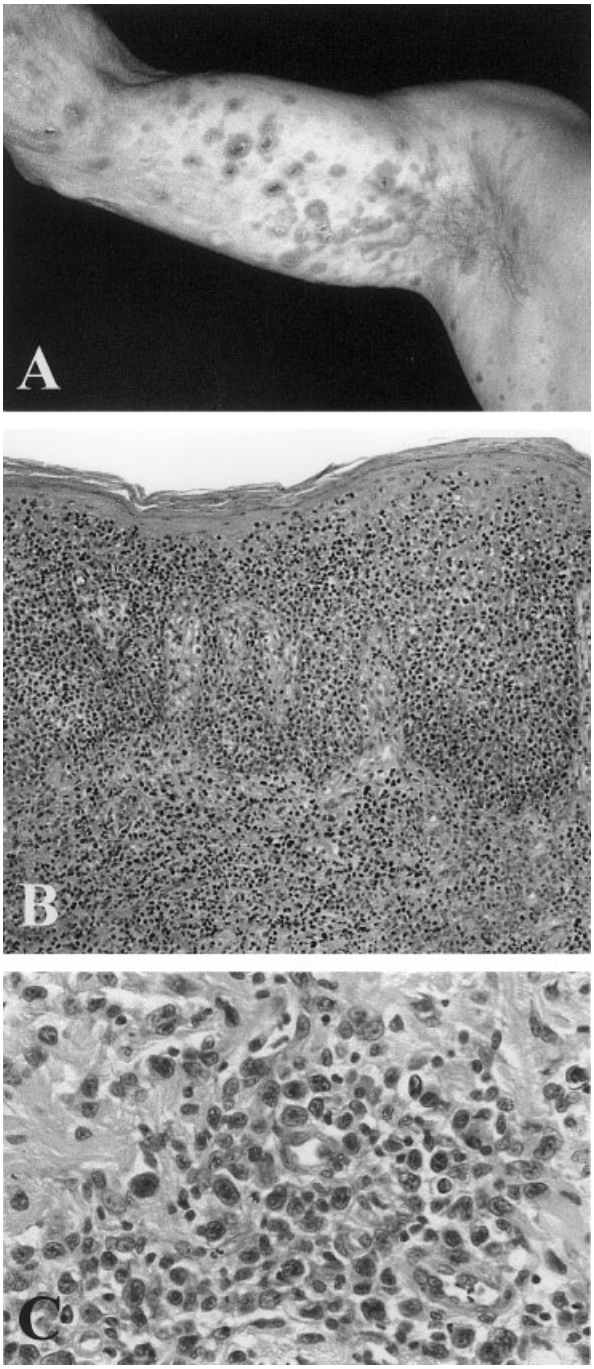

FIGURE 1. Aggressive, CD8+, epidermotropic, cytotoxic T-cell lymphoma. (A) Typical clinical presentation with plaques and nodules, often with hemorrhage and central ulceration. (B) Tumor cells show striking epidermotropism within a markedly hyperplastic epidermis. (C) Neoplastic cells are medium to large in size, with pleomorphic or sometimes roundish nuclei.

disseminated plaques and/or nodules that had developed within a few weeks, often with hemorrhage and central ulceration (Fig. 1A). One patient presented with nodular lesions on the right leg. The initial treatment was skin oriented in two patients (treated with psoralen ultraviolet light [PUVA] and topical chemotherapy). The other two patients were treated with multiagent chemotherapy (cyclophosphamide, doxorubicin, vincristine, and prednisone [CHOP]), radiotherapy (total skin electron beam irradiation [TSEBI], and with α-2 recombinant interferon and etretinate. Despite the initial response to treatment, the disease course was very aggressive, with rapid extracutaneous spread and death (sepsis). All patients died of disease within 3 years from diagnosis (survival, 10–34 months; mean, 22.2 months; median, 22.5 months).

Histologic features

The cutaneous specimens showed no consistent epidermal modifications, the epidermis being atrophic in two cases (one of which displayed central ulceration) and acanthotic in the other two. Single necrotic keratinocytes were detected at the dermal-epidermal junction. In one case, the confluence of basilar necrotic keratinocytes gave rise to a dermal-epidermal cleft, reminiscent of pityriasis lichenoides et varioliformis acuta. Moderate to marked spongiosis was always observed, with blistering in two cases. Tumor cells showed striking epidermotropism, both of single cells and tiny collections (Fig. 1B). Colonization of the basal cell layer by neoplastic cells in a linear configuration and involvement of the entire epidermis in a pagetoid fashion were observed. They were particularly evident at the periphery of the lesions, whereas Pautrier microabscesses were not seen. In three cases, the neoplastic infiltrate presented a lichenoid pattern, obscuring the dermal-epidermal junction, at the papillary and superficial reticular dermis, whereas a patchy/nodular perivascular infiltrate was found in the mid-lower reticular dermis. Conversely, in one case, the neoplastic infiltrate was almost confined to the epidermis, in a pagetoid pattern. Subcutaneous involvement was documented in two cases. Neoplastic cells were medium to large, with an irregular (pleomorphic) or round (blastic) nucleus (Fig. 1C). Adnexal involvement by tumor cells (both of pilosebaceous units and eccrine ducts) was seen in three of four cases. Angiocentricity and angioinvasion were observed in two cases.

Immunophenotype

In all four cases, the tumor cell phenotype was CD3+, CD4−, CD8+, CD45RA+, CD45RO−, TIA-1+, bcl-2+, MIB-1+ (> 90% of tumor cells). CD56 expression was observed in three of the four cases. Granzyme B was expressed in two cases, and epithelial membrane antigen (EMA) in one case. Among the three cases in which frozen tissue was available for analysis, one case was CD2−/CD5−/CD7−, one case was CD2+/

CD5−/CD7+, and the third case was CD2−/CD5+/CD7+. Rearrangement of the TCR-γ gene was demonstrated in the three cases investigated.

Cases 5–9: Mycosis Fungoides, Cytotoxic Immunophenotype Variant (WHO: Mycosis Fungoides)

Clinical features

This group included five patients (three women and two men), 16–77 years of age (mean age, 42.4 years; median age, 44.5 years). These patients were characterized by the typical clinical presentation and course of mycosis fungoides. All patients presented with erythematous and scaly, sometimes poikilodermatous, patches, and/or plaques. The initial treatment consisted of PUVA in all cases. The disease showed an overall indolent, slowly progressing course, with recurrences controlled by generally nonaggressive treatments (four of five patients are alive with disease and one has no evidence of disease, with a follow-up of 24–144 months; mean, 53.2 months; median, 32 months).

Histologic features

The skin specimens were characterized by a moderately dense lympho(histio)cytic infiltrate around blood vessels of the superficial and deep dermis. The infiltrating cells filled a widened papillary dermis and were arranged in a band-like configuration. Medium to large cerebriform cells were found within the epidermis, singly or in tiny collections. The epidermis was usually acanthotic, with focal orthokeratotic or parakeratotic scales. Spongiotic microvesiculation was evident in one case in which the histology was reminiscent of aggressive, CD8+, epidermotropic, cytotoxic T-cell lymphomas. In one case, epidermotropic changes were scant. Papillary dermal fibrosis was often found between the dermal band-like infiltrate and the overlying epidermis. Cerebriform and pleomorphic lymphocytes were constantly present in large numbers in the dermal infiltrate intermingled with inflammatory cells, especially plasma cells and eosinophils. Extravasation of erythrocytes was sometimes seen.

Immunophenotype

In all cases, the neoplastic cells expressed the CD2+, CD3+, CD4−, CD5+, TIA-1+ phenotype. CD8 positivity was detected in three cases, and two cases expressed the CD56 antigen. One case was CD45RO+/CD45RA− and two cases were CD45RO−/CD45RA+. In the case showing prominent spongiotic microvesiculation and a histologic profile reminiscent of aggressive, CD8+, epidermotropic, cytotoxic T-cell lymphomas, all epidermotropic tumor cells were positive for the CD30 antigen, whereas there was total negativity of dermal tumor cells for CD30 expression.

Cases 10–21: Subcutaneous Panniculitis-like T-cell Lymphoma (WHO: Subcutaneous Panniculitis-like T-cell Lymphoma)

Clinical features

This group included 12 patients (7 women and 5 men), 8–76 years of age (mean age, 42.6 years; median age, 53 years). All patients showed a typical clinical presentation mimicking panniculitis: indurated, painful, subcutaneous plaques and/or nodules mostly located on the lower limbs, frequently with ulceration (Fig. 2A) and fever. Most patients were treated initially with antiinflammatory/immunosuppressive regimens (steroids with or without low-dose cyclophosphamide or hydroxychlorokine or retinoids). Three patients were treated with multiagent chemotherapy (CHOP [cyclophosphamide, doxorubicin, vincristine, prednisone], ACVBP [doxorubicin, cyclophosphamide, vindesine, bleomycin, prednisone]) and one patient was not treated due to spontaneous remission of skin lesions. The clinical behavior was rapidly progressive in six cases, with cutaneous dissemination, extracutaneous spread, sepsis, and death despite aggressive chemotherapy (CHOP, CEOP [cyclophosphamide, epirubicine, vincristine, prednisone], VIM2, cytosine arabinoside). Two additional patients, although still alive with disease, experienced systemic symptoms including hemophagocytic syndrome. Conversely, the clinical course was indolent in four patients, three of whom are alive with local disease. These patients experienced cutaneous recurrences, sometimes undergoing spontaneous remission, with long-standing remissions even after mild treatments. The last patient is alive with no evidence of disease after 15 months of follow-up.

Histologic features

All cases were characterized by a predominantly subcutaneous atypical lymphoid infiltrate. Involvement of the subcutis, without any dermal extension, was observed in two cases. A slight (five cases) to moderate (five cases) involvement of the reticular dermis, mainly perivascular in location, was observed in 10 cases. The involvement of the papillary dermis, with epidermotropic phenomena, was observed as a major feature in one case and was less prominent in three additional cases. The pathognomonic histopathologic feature of this group of lymphomas was infiltration of fat lobules by neoplastic cells in a lace-like fashion resembling a lobular panniculitis in eight cases (Fig. 2B) and a mixed panniculitis (lobular plus septal) in four cases. Subcutaneous septa were rarely thickened.

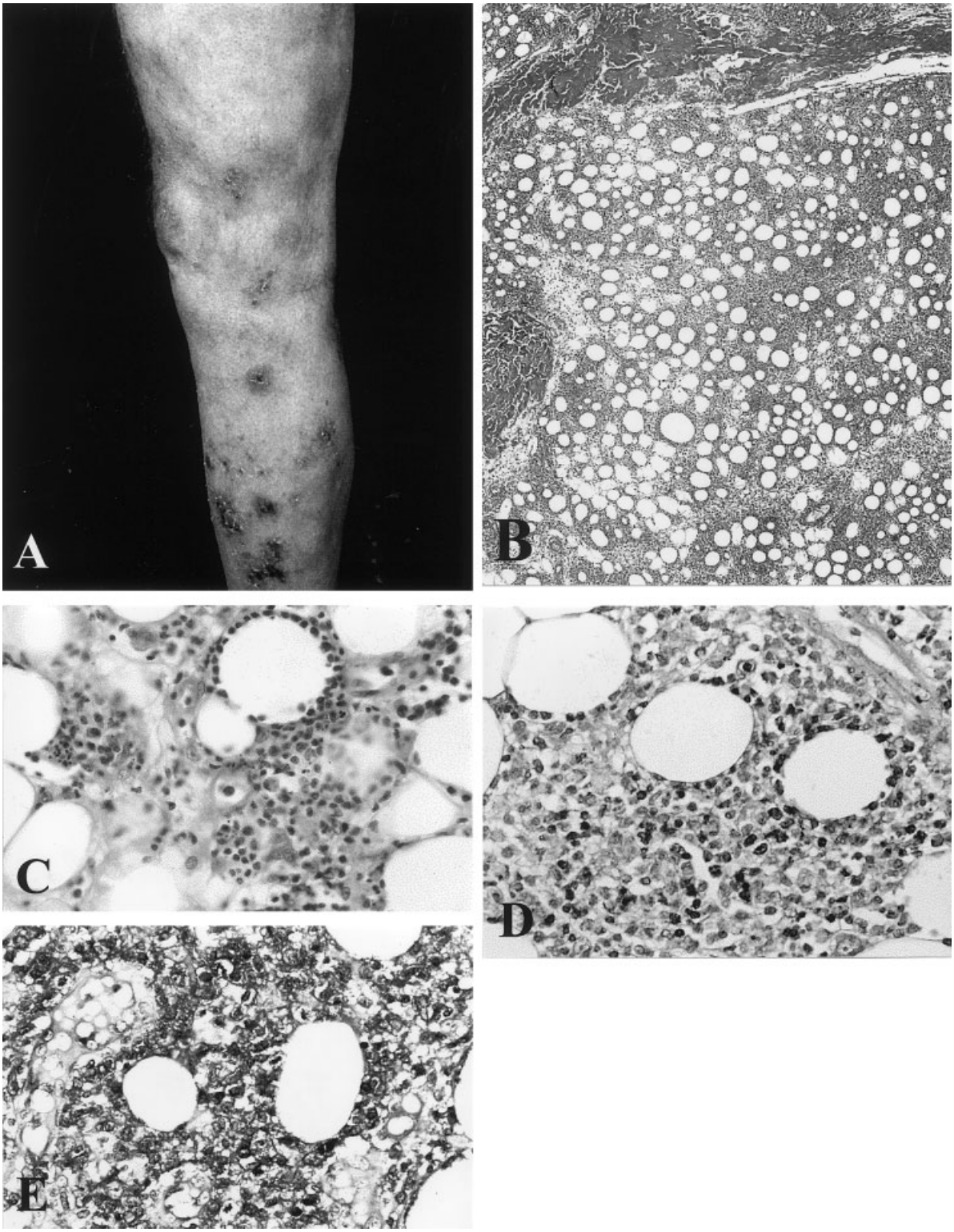

FIGURE 2. Subcutaneous panniculitis-like T-cell lymphoma. (A) Characteristic clinical presentation mimicking panniculitis with plaques and nodules located on the lower limbs, frequently with ulceration. (B) The neoplastic infiltrate predominantly involves subcutaneous fat in a lace-like fashion resembling a lobular panniculitis. (C) Rimming of individual adipocytes by neoplastic cells and karyorrhectic phenomena are common features. (D) TIA-1 positivity is observed in neoplastic cells. (E) Tumor cells show a positive immunoreaction for CD8.

The rimming of individual adipocytes by neoplastic cells was a common feature (Fig. 2C). The neoplastic infiltrate was composed of pleomorphic lymphocytes of variable size, with an irregular, hyperchromatic nucleus. A predominance of small to medium cells was observed in all cases and large transformed lymphoid cells were seen in six cases. A characteristic feature was the presence of karyorrhectic phenomena, which were seen in every case and were prominent in 10 cases. Fat necrosis was frequent with foamy or finely vacuolated histiocytes. Small cysts lined by amorphous eosinophilic material were documented in five cases. Multinucleated giant cells were seen in five cases. Scattered plasma cells were rarely seen. Neutrophils and eosinophils were absent, except for two cases in which neutrophilic microabscesses were found within necrotic foci. A slight to moderate angiocentricity occurred in eight cases and angioinvasion of small blood vessels was present in five cases.

Immunophenotype

In all cases, the tumor cell phenotype was CD2+, CD3+, CD45RO+, CD43+, and TIA-1+ (Fig. 2D). Seven cases expressed the T-suppressor cell antigen, CD8 (Fig. 2E), and possible coexpression of CD4 was seen in two of these cases. Two additional cases were CD4+/CD8−, whereas the neoplastic cells did not express either CD4 or CD8 in three cases. CD56 was positive in 7 of 12 cases. Among the five cases with frozen tissue available for immunohistochemistry, three were positive for CD5 antigen and all cases were negative for CD7. Perforin and Granzyme B (GrB) cytoplasmic staining was observed in all four tested cases. Weak focal staining for CD30 was noted in two of seven cases. All nine cases tested expressed TCR antigens. Two cases proved to be α/β (βF1+) T-cell lymphomas and the other seven were derived from γ/δ T cells (TCRδ1+). All γ/δ+ cases were CD56+, whereas none of the two α/β lymphomas expressed CD56+. A significant difference in the tumor cell phenotype was observed according to the exclusive subcutaneous or subcutaneous and dermal involvement by neoplastic cells. Among cases with dermal extension tested for TCRs, seven were TCRδ1+ and one was βF1+. Clonal TCR gene rearrangements were documented in the six cases investigated. Clonal rearrangement of TCR-γ was shown in five lymphomas, including 1 α/β and 4 γ/δ lymphomas. Clonal rearrangements of the TCR-δgene were confirmed by PCR analysis in 1 γ/δ lymphoma showing a clonal $V\delta_2$ rearrangement. None of the three cases tested for EBER or LMP-1 was positive for EBV.

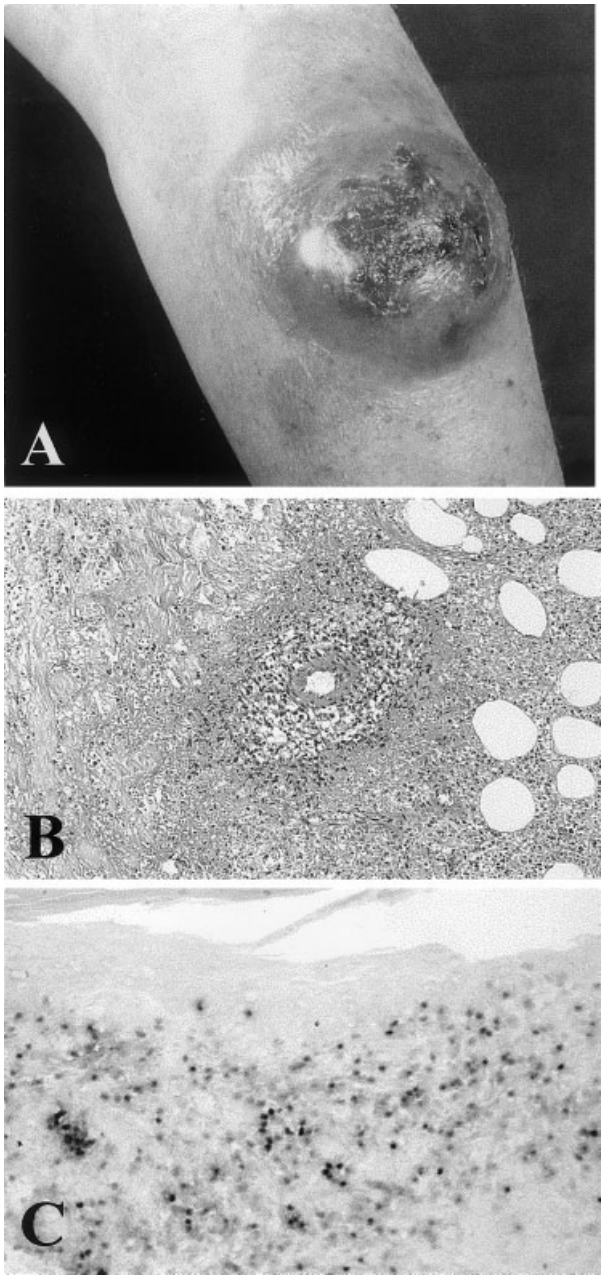

FIGURE 3. Natural killer T-cell lymphoma, nasal type. (A) Clinical presentation with a single nodular lesion with hemorrhage and central ulceration on a finger. (B) Prominent zonal tumor cell necrosis, with angiocentric and angiodestructive phenomena of small to medium-sized vessels, is frequently observed. (C) Epstein–Barr virus (EBV)-encoded RNA in situ hybridization shows that neoplastic cells are EBV positive.

Cases 22–24: NK/T-Cell lymphoma, Nasal Type (WHO: Extranodal NK/T-cell Lymphoma, Nasal Type)

Clinical features

This group included two females (age 27 and 43 years, respectively) and one male aged 53 years. The male patient, affected by a myelodysplastic syndrome, pre-

sented with a single nodular lesion on the left ring finger (Fig. 3A). Another patient developed multiple cutaneous nodules that underwent spontaneous remission. Staging was negative. These two patients were lost to follow-up. The third patient presented with multiple, rapidly growing cutaneous nodules on the left arm and other lesions appeared on the legs 6 months later, some of which underwent spontaneous remission. Approximately 6 months after diagnosis, a computed tomographic (CT) scan documented a polypoidal thickening of the nasal and paranasal (frontal sinus) mucosa. Bone CT scan and bone marrow biopsy were negative. Following aggressive multiagent chemotherapy courses, the lesions underwent almost complete remission, but the disease recurred. The patient died with disseminated disease 18 months from diagnosis.

Histologic features

In two cases, the lymphomatous infiltrate was diffuse, involving the entire dermis and the subcutis. In the last case, tumor cells were localized mainly to the deep reticular dermis and subcutis. The neoplastic infiltrate was composed of small to medium-sized pleomorphic lymphocytes with irregular nuclei, inconspicuous nucleoli, and scant cytoplasm. Neither polymorphonuclear leukocytes nor plasma cells were seen, whereas small numbers of reactive lymphocytes, intermingled with tumor cells, were observed in all cases. In one case, reactive lymphocytes were seen in the epidermis and skin appendages. Apoptosis was prominent in two cases. Zonal tumor cell necrosis, focal or confluent, with angiocentric and angiodestructive phenomena of small to medium-sized vessels was a prominent feature in all specimens (Fig. 3B). The vessels of the deep reticular dermis were massively infiltrated by atypical lymphoid cells and surrounded by extensive areas of coagulative necrosis, with only cuffs of surviving lymphoma cells around the blood vessels. The involved vessels showed endothelial swelling and onion skin thickening of the wall, with fibrin deposition and nuclear debris. Extensive epidermal ulceration was observed in one case.

Immunophenotype

All cases were CD3−, CD3ε+, CD56+, CD57−, CD4−, CD45RO+, CD45RA−, and TIA-1+. Two of three cases were CD8−. In one case in which frozen tissue was available, tumor cells were CD2+/CD94+/NKp46+/CD5−/CD7−. CD30 expression was found in a minority of tumor cells (<30%) in two of three cases. In all cases, B-lineage markers (CD20, CD79a) were negative. None of the cases showed clonal TCR rearrangement by PCR for TCR-γ. In the two cases tested, neoplastic cells were EBER+ (in situ hybridization and PCR; Fig. 3C) and LMP−1+.

Cases 25–36: CD4+, NK Cell Lymphoma (WHO: Blastic NK Cell Lymphoma)

Clinical features

This group comprised 12 patients (11 males and only 1 female), 38–83 years of age (mean age, 58.7 years; median age, 58.5 years). All patients presented with rapidly extending, multiple plaques and/or nodules in noncontiguous skin sites (Fig. 4A). Nine patients received multiagent chemotherapy as the initial treatment (mostly CHOP-like regimens) and one patient received chemotherapy and radiotherapy (TSEBI). In one case, characterized by a localized lesion of the lower limb, radiotherapy alone was given. In one case, no treatment was given initially. There were no data concerning treatment in one case. Complete remission was achieved after the initial treatment in 6 of 10 treated patients. For seven patients, the course was characterized by skin disease recurrence and systemic involvement (bone marrow, blood, lymph nodes, central nervous system [CNS], and nasopharynx, variably involved) despite aggressive multiagent chemotherapy and autologous bone marrow transplantation in two patients. Two patients achieved stable complete remission and currently have no evidence of disease. Clinical information concerning the current status is not available for three cases.

Histologic features

The lymphomatous infiltrate was diffuse, involving the entire thickness of the dermis in five cases (Fig. 4B), with subcutaneous extension in two cases. In seven other cases, tumor cells were arranged in a patchy-nodular profile at the dermal level, with subcutaneous involvement in six cases. In nine cases, single cells or rows of neoplastic cells infiltrated the dermal collagen bundles in an "Indian file" or reticular pattern (Fig. 4C). In most cases (8 of 12), a clear-cut grenz zone, with edema of the papillary dermis (three cases), was observed. Focal epidermotropic phenomena were observed in three cases. Cytologically, a variable mixture of small-medium to large pleomorphic lymphocytes was noted in nine cases (Fig. 4D). In the other three cases, the neoplastic infiltrate was monomorphous, composed of medium to large blastic lymphocytes. Neither polymorphonuclear leukocytes nor plasma cells were seen, whereas small numbers of reactive lymphocytes, intermingled with tumor cells, were observed. Apoptotic phenomena were not prominent. Angiocentric and angiodestructive features of small to medium-sized vessels were often observed, but were

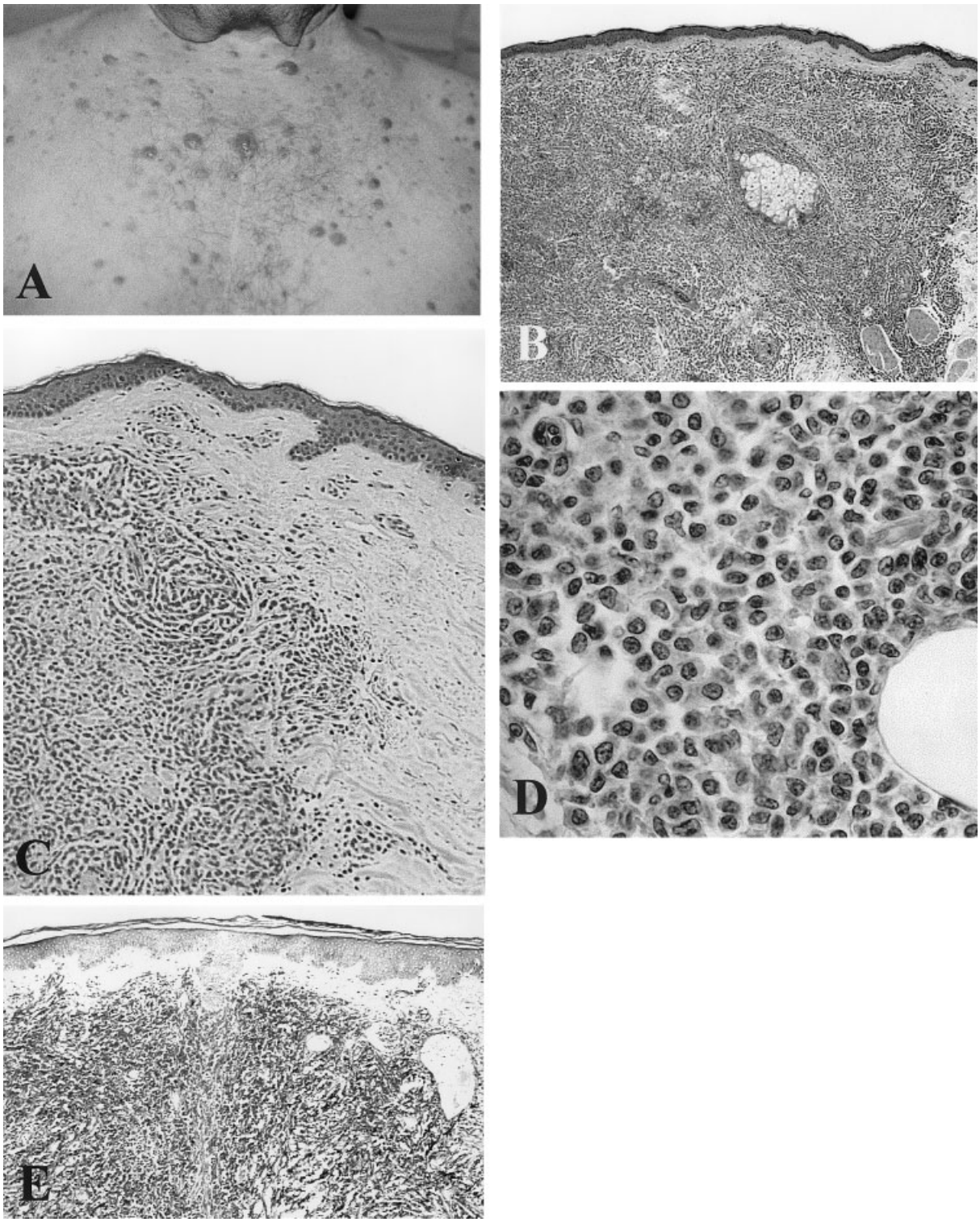

FIGURE 4. CD4+, natural killer cell lymphoma. (A) Clinical presentation with multiple cutaneous erythematous nodules. (B) Diffuse lymphomatous infiltrate involving the entire dermis. (C) Single cells or rows of neoplastic cells infiltrate the dermal collagen bundles in an Indian file or reticular pattern. (D) The neoplastic infiltrate is composed of medium to large lymphocytes. (E) Tumor cells are diffusely positive for CD56.

not prominent. There were no obvious areas of intratumoral necrosis.

Immunophenotype

All cases were CD4+, CD56+ (Fig. 4E), bcl-2+, CD43+, CD3−, CD8−, βF1−, TCRδ1−, CD30−. All but one case were CD45RA+/CD45RO−. CD3ε (polyclonal anti-CD3) was expressed in four of seven tested cases. On frozen sections, all eight cases were CD123/IL3Rα+, CD94−, NKp46−. Eight of 12 cases were CD2−/CD5−/CD7−, 3 cases were CD2−/CD5−/CD7+, whereas the last case was CD2+/CD5−/CD7+. The CD57 antigen was found in two of the six tested cases. In eight of the nine cases tested, a high proliferative activity of tumor cells (MIB-1 >50%) was found. TIA-1 was negative in all but two cases. Among the 10 cases in which CD68 expression was evaluated, 7 cases gave a positive reaction in a high percentage of tumor cells. CD34 was negative in the eight tested cases. B-cell–associated antigens (CD20, CD21, CD22, CD79a) were negative in all cases. None of the 10 cases tested for EBER and LMP-1 was positive for EBV. None of the nine cases tested showed TCR gene rearrangements.

Case 37: Blastoid NK Cell Lymphoma (WHO: Blastic NK Cell Lymphoma)

Clinical features

This patient was a 58-year-old man who presented with multiple plaques and nodules disseminated on the skin. At presentation, systemic symptoms were absent and the patient's staging workup was negative. Following aggressive chemotherapy courses (CHOP), the patient experienced partial remission. Shortly thereafter, the disease pursued a fulminant course with bone marrow and testicular involvement. The patient died 16 months after diagnosis.

Histologic features

The tumor cells were located mainly in the middle and deep dermis, sparing the subepidermal region, and infiltrated the collagen bundles in an interstitial pattern of growth. The infiltrate was monomorphous and composed of medium to large-sized cells with round nuclei and fine diffuse chromatin.

Immunophenotype

The neoplastic cells were CD3−, CD4−, CD8−, CD45RO−, CD45RA+, CD56+, TIA-1−, GrB−, βF1−, TCRδ1−, EBER−, and LMP-1−. A focal positivity for CD68 was also demonstrated. B-cell markers (CD20, CD79a) were negative.

Case 38: Intravascular NK-like Lymphoma (WHO: Not Recognized)

Clinical features

The patient, a 54-year-old man, presented with erythematous plaques on the trunk (Fig. 5A) and thighs, leukopenia (with CD4 T-cell depletion), and weight loss. Borrelia burgdorferi was detected serologically and in the skin by enzyme-linked immunosorbent assay and PCR, respectively. Complete remission of skin lesions, with simultaneous conversion to negative PCR for Borrelia, was achieved after five CHOP courses. However, shortly after the resolution of the cutaneous lesions, clinical and CT scan signs of CNS involvement appeared and the patient died of disease 17 months after diagnosis.

Histologic features

The skin specimen was characterized by a vascular-occlusive process involving venules, capillaries, and arterioles at the dermal and subcutaneous levels. Affected vessels were dilated by an accumulation of noncohesive, large atypical blast-like cells (Fig. 5B), often mixed with abundant fibrin. Vascular occlusion, without significant recanalization, was often observed. The epidermis demonstrated no significant changes.

Immunophenotype

The tumor cell phenotype was CD3ε+, CD56+ (Fig. 5C), TIA-1+, GrB+, CD30+, MIB-1+ (100% of tumor cells), EBER+ (Fig. 5D), LMP1−, CD4−, CD8−, CD20−, CD79a−, CD57−, CD68−, and bcl-2−.

Cases 39–48: Cytotoxic, Peripheral T-cell Lymphoma (WHO: Peripheral T-cell Lymphoma, Unspecified)

Clinical features

This group included 10 patients (5 women, 5 men) 38–77 years of age (mean age, 59.1 years; median age, 61.5 years). Patients presented with isolated/localized or disseminated nodules and/or plaques. The treatment was variable, mostly depending on the distribution of skin lesions (surgery and/or radiotherapy in patients with isolated/localized lesions, single or multiagent chemotherapy in patients with disseminated lesions). In this group, two clinical subsets were delineated. One subset was characterized by extracutaneous spread (lymph nodes, pharynx, soft tissues, CNS, bone marrow) and death despite treatment with multiagent chemotherapy (CHOP or CHOP-like). In the second group, the patients showed a chronic course, with spontaneous remission of disease in one case. Neither the variable distribution of skin lesions at presentation (isolated/localized vs. disseminated)

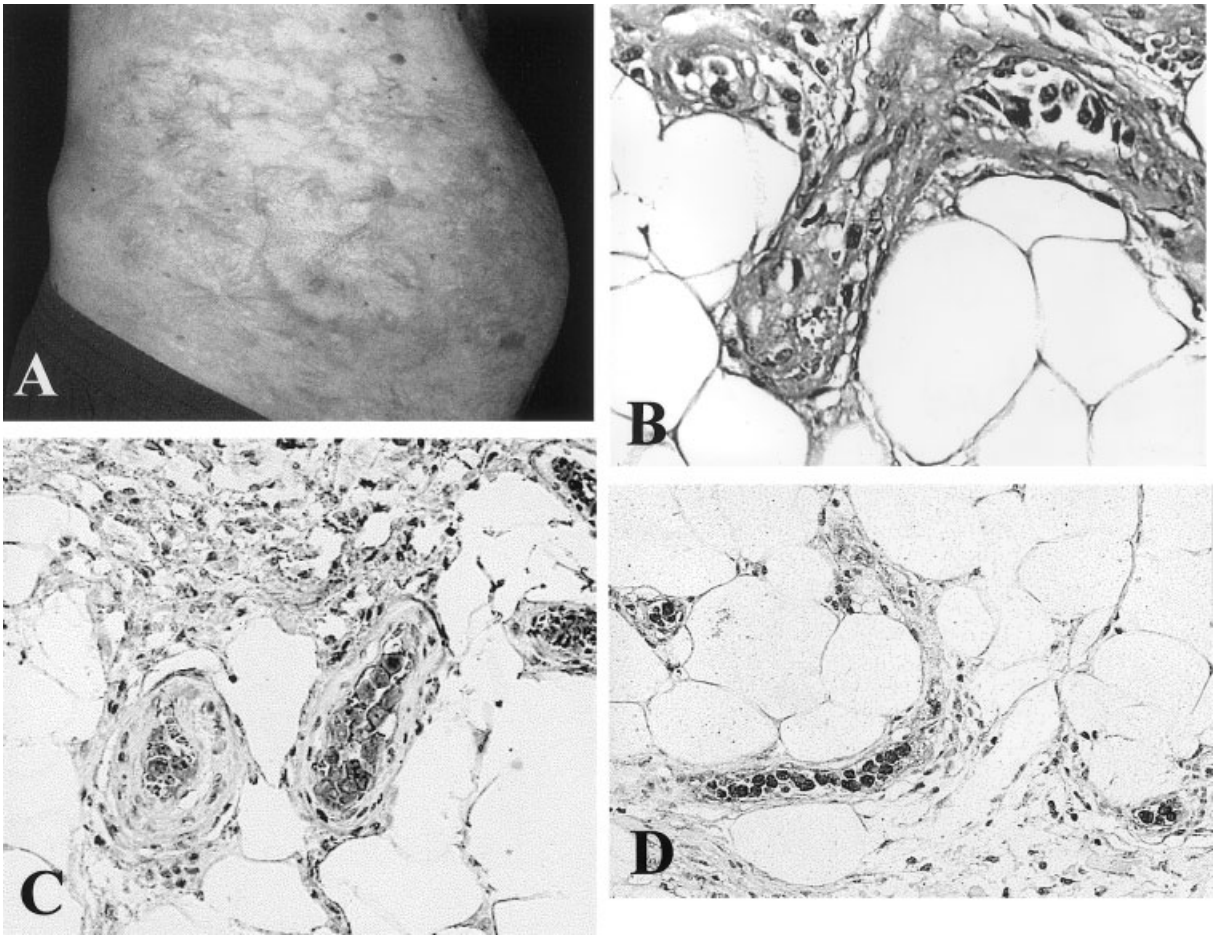

FIGURE 5. Intravascular natural killer-like lymphoma. (A) The patient presented with erythematous plaques on the trunk. (B) Affected vessels are dilated by an accumulation of noncohesive, large atypical blast-like cells. (C) Tumor cells are positive for CD56. (D) Epstein–Barr virus (EBV)-encoded RNA *in situ* hybridization shows that neoplastic cells are EBV positive.

nor the aggressiveness of the initial treatment correlated with the clinical course.

Histologic features

This group was characterized by a proliferation of pleomorphic lymphocytes of variable size (small to medium cells in three cases, medium to large cells in six cases, and large, blast-like cells in one case). The pattern of infiltration was heterogenous, ranging from patchy perivascular (three cases) to diffuse dermal involvement (two cases), to diffuse in the dermis with extensive subcutaneous involvement (three cases), to mainly subcutaneous with slight dermal involvement (two cases).

Immunophenotype

All cases expressed CD3, all but two cases were TIA-1+, and 5 of 10 were CD56+ (including the 2 TIA-1− cases). Three cases were CD4+, three cases CD8+ and the five CD4−, CD8− cases stained with βF1 (two cases) or with TCR-δ1 (two cases). The CD45RO antigen was diffusely expressed in one-half of the cases. Among the six cases in which frozen material was available, three cases expressed either CD2, CD5, or CD7. Two cases showed a diffuse positivity (> 70% of tumor cells) for the CD30 antigen. One of these two patients experienced spontaneous remission and is alive with no evidence of disease 1 year from diagnosis. All but one case was negative for B-cell–associated markers. The remaining case was immunoreactive for CD79a, even though it lacked immunoreactivity for CD20, was positive for βF1, and lacked clonal rearrangement for Ig heavy chains by PCR. None of the five cases tested for EBER and/or LMP-1 was positive for EBV.

DISCUSSION

The spectrum of cutaneous cytotoxic lymphomas was heterogenous with regard to clinical presentation, morphologic and immunophenotypic features, asso-

TABLE 2
Summary of the Major Types of Cutaneous Lymphomas Expressing the Cytotoxic-Associated Marker TIA-1 and/or the Natural Killer Cell Marker CD56[a]

Characteristics	Aggressive, CD8+, epidermotropic, cytotoxic T-cell lymphoma	Mycosis fungoides, cytotoxic immunophenotype variant	Subcutaneous pannicilitis-like T-cell lymphoma	NK/T-cell lymphoma, nasal type	CD4+, NK cell lymphoma	Blastoid NK-cell lymphoma	Intravascular NK-like lymphoma
Age	Middle-aged or elderly adults	Middle-aged or elderly adults	Middle-aged adults, children	Adults	Adults	Adults	Adult
Gender	M > F	M = F	F ≥ M	M > F	M > F	M	M
Clinical presentation	Patches, plaques, and nodules, often with hemorrhage and ulceration	As typical mycosis fungoides	Mimicking panniculitis: indurated, painful subcutaneous plaques or nodules, mostly located on the lower limbs, common ulceration of lesions and fever	Multiple cutaneous nodules commonly followed by systemic dissemination (upper aerodigestive tract, soft tissues, testis, and gastrointestinal tract); sometimes involvement of multiple extranodal sites at presentation	Multiple cutaneous papules, plaques, and nodules in noncontiguous skin sites	Disseminated plaques and nodules on the skin; sometimes systemic disease at presentation	Disseminated, cutaneous erythematous plaques
Histologic features	Lichenoid infiltrate composed of medium/large pleomorphic T cells, with linear and pagetoid epidermotropism, spongiosis, and blistering, variable numbers of necrotic keratinocytes at the dermal-epidermal junction.	As typical mycosis fungoides	Variably sized pleomorphic lymphocytes infiltrating subcutis in a lace-like fashion, with rimming of adipocytes by neoplastic cells; karyorrhexis and fat necrosis common; granulomatous reaction and erythrophagocytosis seldom observed; frequent dermal involvement in TCRδ1+ cases.	Proliferation of variably sized pleomorphic cells, with prominent angiocentricity, angiodestructive growth, and extensive necrosis.	Variably sized pleomorphic lymphocytes or, more rarely, monomorphic medium-large blasts in an "Indian file" or reticular pattern; angiocentric and/or angiodestructive features frequently observed, never prominent.	Monomorphous infiltrate composed of medium-large–sized cells infiltrating collagen bundles in an interstitial pattern	Intravascular accumulation of large atypical blast-like cells mixed with abundant fibrin
Most common immunophenotype	CD3+, CD4−, CD8+, CD45RA+, CD45RO−, TIA-1+, bcl-2+, MIB-1+(> 90%), CD56+/−, CD2−/+, CD5−/+, CD7+/−	CD3+, CD4−, CD8+/−, CD45RA+/−, CD45RO−/+, TIA-1+, CD56−/+, CD2+, CD5+	CD2+, CD3+, CD3ε+, CD45RO+, CD43+, TIA-1/perforin/GrB+, CD8+/−, CD4−/+, CD56+/−, CD5+/−, CD7−. γ/δ(TCRδ1+) > α/β(βF1+) (Europe), α/β(βF1+)>γ/δ(TCRδ 1+) (USA)	CD2+, CD3−, CD3ε+, CD4−, CD8−/+, CD45RO+, CD45RA−, TIA-1+, CD56+, CD57−, CD16−	CD4+, CD56+, bcl-2+, CD43+, CD3−, CD3ε+, CD8−, CD45RA+, CD45RO−, CD5−, CD2−/+, CD7−/+, βF1−, TCRδ1−, CD30−, CD57−/+, MIB-1+ (> 50%) TIA-1−/+, CD68+/−, CD34−	CD2−/+, CD3−, CD3ε+, CD4−, CD8−, CD45RO−, CD45RA+, CD56+, TIA-1−, GrB−, βF1−, TCRδ1−, TdT+/−	CD3ε+, CD56+, TIA-1+, GrB+, CD30+, MIB-1+ (100%), CD4−, CD8−, CD57−, CD68−, bcl-2−
TCR genes	Rearranged (TCRγ)	Rearranged	Rearranged	Germline	Germline	Germline	N.T.
Association with EBV	Absent	Absent	Absent	Present (> 90%)	Absent	Absent	?
Clinical behavior	Rapidly progressive dissemination (oral cavity, testis, lung, CNS, soft tissues; sparing of lymph nodes) and fatal outcome (mean survival time 32 mos)	As typical mycosis fungoides	Frequent dissemination of skin lesions and systemic spread to bone marrow, lung, liver, commonly accompanied by sepsis and hemophagocytic syndrome; more rarely, indolent course with spontaneous remission	Aggressive, with early dissemination; common recurrences despite initial response to chemotherapy	Aggressive, with rapid dissemination to bone marrow (leukemia +/−) and fatal outcome	Aggressive, with systemic involvement and death	CNS involvement and death
Treatment guidelines	Chemotherapy (purine analoges) with/without radiotherapy; allogeneic minitransplant (second line)	As typical MF (PUVA, topical chemotherapy)	Chemotherapy (CHOP-like or third-generation regimens, possibly followed by allogeneic BMT) with/without radiotherapy	Chemotherapy (CHOP-like or third-generation regimens), possibly followed by autologous or allogeneic BMT with/without radiotherapy; radiotherapy on isolated lesions.			

NK: natural killer cell; N.T.: not tested; BMT: bone marrow transplantation; TCR: T-cell receptor; CNS: central nervous system; EBV: Epstein-Barr virus infection.
[a] Based on data from the current series and from cases reported in the literature.

ciation with EBV, and clinical course. Taking into account these features, several categories were identified. Their salient features are summarized in Table 2, based on information from the current study and the literature.

Information on aggressive, CD8+, epidermotropic, cytotoxic T-cell lymphomas is very limited. Only sporadic cases of mycosis fungoides, pagetoid reticulosis, or other types of T-cell lymphomas expressing a CD8+, cytotoxic phenotype have been de-

scribed.[16–33] Even the EORTC classification in its current form does not include CD8+ cytotoxic T-cell lymphomas neither in a well defined nor provisional category.[2] However, Berti et al.[8] drew attention to these tumors and suggested that CD8+ cytotoxic T-cell lymphomas represent a distinctive type of cutaneous T-cell lymphoma with an aggressive clinical behavior.[8] The results of our study confirmed those of Berti et al.[8] concerning the distinctive clinical presentation and course, histology, and immunophenotypic features of neoplastic cells of this peculiar type of cutaneous T-cell lymphoma. In addition, we demonstrated that these cutaneous T-cell lymphomas also express the CD56 antigen, a finding not previously reported. The T-cell origin and the clonality of this neoplasm were confirmed by the rearrangement of the TCR-γ gene in the three cases investigated. The course of the disease is characterized by rapidly progressive dissemination and death, despite the use of aggressive multiagent chemotherapy regimens. It is noteworthy that the systemic spread did not involve the lymph nodes, but involved the oral cavity (one case), the soft tissues of the centrofacial region (one case), and unusual sites (lung, testis, or CNS) accompanied by sepsis in one case. This may be attributed to the CD56+ phenotype, which is associated with homing to extranodal sites.

Aggressive therapeutic modalities were ineffective in the management of these patients. Therefore, new strategies are needed. In this respect, two main points should be taken into account. First, the course of the disease is frequently associated with severe immunodeficiency. Therefore, neither TSEBI nor aggressive polychemotherapy regimens are likely to achieve long-standing clinical responses. When possible, an allogeneic minitransplant instead of autologous bone marrow transplantation may be suggested. Alternatively, the use of purine analogs devoid of high immunosuppressive capacity (like gemcitabine, which was used in aggressive cutaneous T-cell lymphoma cases[34]) may be proposed, possibly associated with local radiotherapy. Second, as suggested by Berti et al.,[8] the putative Th1-like cytokine profile of these aggressive CD8+ cutaneous T-cell lymphoma should discourage treatments that increase Th1 responses (e.g., retinoids or interferon alpha). Extreme caution should be used for such regimens.

Concerning mycosis fungoides, the cytotoxic immunophenotype variant, these cases were characterized by the typical clinical evolution, histology, and course of mycosis fungoides. If there are immunophenotypic similarities with CD8+ aggressive lymphomas, cytotoxic mycosis fungoides has to be regarded as a phenotypic, and not a clinicopathologic, variant of mycosis fungoides and should be treated nonaggressively according to well established guidelines (PUVA, topical chemotherapy).

Subcutaneous panniculitis-like T-cell lymphoma (SPTCL), currently included as a provisional entity in both the REAL classification[35] and the EORTC classification[2] for primary cutaneous lymphomas, has been incorporated as an entity in the WHO classification.[2] The 12 cases in the current series exhibited the typical features as described in the more than 60 cases reported to date.[36–59] In our series, two phenotypic subsets can be delineated: TCR-γ/δ+/CD56+ and α/β+/CD56−. In agreement with previous observations,[58] these phenotypic subsets correlated with the presence or absence of dermal invasion. All but one case with dermal extension were γ/δ+/CD56+. Although a limited number of SPTCLs have been investigated for TCR expression, earlier studies from Europe and Eastern countries documented a prevalent γ/δ TCR expression similar to that found in the current, study.[40,46,55,60–62] American studies have emphasized that the majority of SPTCL cases expressed α/β TCRs.[57,58] We do not know the reasons for the discrepancy between the American and European/Eastern studies. In agreement with previous observations,[39,49] most cases have an aggressive clinical behavior. In a few cases, the course of the disease is indolent, with spontaneous remission of skin lesions and long periods of stable disease without associated systemic symptoms. Neither the age of the patients nor the aggressiveness of the initial treatment was related to the course of the disease. In agreement with previous observations,[57] a correlation was found between the expression of TCR-γ/δ+/CD56+ phenotype by tumor cells and an aggressive course. Therefore, the presence of this peculiar immunophenotypic profile may be indicative of a dismal clinical course and may require aggressive therapeutic modalities (CHOP-like or third generation regimens, possibly followed by allogeneic bone marrow transplantation). Conversely, the finding of a TCR-α/β+/CD56− phenotype may be indicative of an indolent course and favor less aggressive treatments. However, further studies are needed to confirm whether the origin (α/β or γ/δ) and CD56 expression have a prognostic significance.

Increasing attention has been given to the clinicopathologic spectrum of the CD56+ lymphomas, possibly due to the availability of a paraffin section-reactive CD56 antibody, which has greatly facilitated the recognition and further characterization of these rare tumors.[4–5,63–69] CD56+ lymphomas show a polymorphous clinical presentation, a wide morphologic spectrum, and a variable immunophenotypic profile. For this reason, there is much confusion and little

consensus regarding the best nomenclature for these tumors. A review of the literature on this topic shows that similar cases have been designated with different terms, such as "aggressive natural killer cell leukemia/lymphoma",[70,71] "large granular lymphocytic lymphoma",[72,73] "angiocentric T-cell lymphoma",[74] "CD56+ T-"cell lymphoma,"[75,76] "natural killer cell lymphoma" and "CD56 angiocentric lymphoma".[78] A comprehensive study provided a more complete picture of these rare neoplasms and better clarified the clinicopathologic spectrum of these uncommon tumors.[5] In the current study, we focused on NK and NK-like lymphomas with primary presentation of disease in the skin. It should be noted that many of our cases had histologic/immunophenotypic patterns that were difficult to assign unambiguously to one or another of the existing categories. In addition, this preliminary review gave us reason to doubt that histopathologic features by themselves were invariably specific. That is, we frequently found it impossible to unequivocally classify single cases on morphologic grounds alone.

The three cases of NK/T-cell lymphoma, nasal type, showed the characteristic morphology (dermal proliferation of small to medium pleomorphic cells, with prominent angiocentricity and angiodestructive growth as well as extensive necrosis), immunophenotype (CD3−, CD3ε+, CD56+, CD45RO+, TIA-1+, TCRs−), and association with EBV, as previously described.[4,5,79] In addition, in the only patient with available follow-up information, the development of skin lesions was rapidly followed by involvement of the frontal paranasal sinuses and nasal cavity, in agreement with the highly aggressive clinical behavior reported in previous studies.[4,5] An extensive immunohistochemical study on frozen section also showed an NK CD2+/CD94+/NKp46+ phenotype.

Clinically, in the group of CD4+ NK cell lymphomas, a striking male preponderance was observed, in agreement with previous observations.[5,67] Histopathologically, these cases showed a dermal infiltrate of variably sized pleomorphic cells or monomorphic, medium to large blasts. The neoplastic cells showed an Indian file or reticular pattern of infiltration. The angiocentric/angiodestructive features, although often observed, were never prominent as in the nasal type NK/T-cell lymphoma. The immunophenotype was CD3ε+/−, CD4+, CD43+, CD45RA+/−, CD56+, CD68+/−, CD123/IL3Rα+, CD3−, CD57−, TCRs−, TIA-1−, EBER− and LMP-1−, resembling the immunophenotypic profile described by Petrella et al.[6] as "CD4+, CD56+ cutaneous lymphomas." Possible examples were published by others.[7,80,81] Therefore, we preferred to retain this terminology instead of using the one proposed by the WHO classification (blastic NK-cell lymphoma).

The expression of CD4, CD56, CD68, and CD123 and the negativity of NKp46 and CD94 (in seven cases tested), the striking male preponderance, and the subsequent rapid spread to bone marrow, with or without leukemic evolution, raise doubts concerning the origin/differentiation of tumor cells and the relationship of this entity with other NK/T-cell lymphomas and leukemias.[4,5,70,82–85] The CD4+/CD68+/CD123+ phenotype was mainly expressed by immature monocytic and dendritic cell precursors. The cases belonging to this group, although primary cutaneous at presentation according to the EORTC definition[2] and characterized by initial response to the treatment with aggressive polychemotherapy, experienced rapid spread to the bone marrow, with or without leukemia, and death notwithstanding aggressive second-line treatments including bone marrow transplantation. We recommend aggressive polychemotherapy possibly followed by autologous or heterologous bone marrow transplantation in patients presenting with disseminated cutaneous diseases and local radiotherapy and close follow-up in patients who present with single, isolated skin lesions.

The patient with blastoid NK cell lymphoma presented with the clinical symptoms (extranodal disease at diagnosis, histopathologic features (monomorphous proliferation of medium to large cells in a retiform pattern reminiscent of leukemia), immunophenotypic profile (CD3−, CD4−, CD8−, CD56+, βF1−, TCRδ1−), the lack of association with EBV, and the aggressive clinical course recently described by Chan et al.[5] as typical of this entity. For this reason, and because of the lack of CD4 expression, we believe that this case is phenotypically different from CD4+NK-like lymphoma. Therefore, we retained the original terminology instead of using the one proposed by the WHO classification, which lumps the two categories under the heading "blastic NK cell lymphoma." However, because few cases of blastoid NK cell lymphoma have been reported, the proper nosology of these rare cases and their relationship with other types of NK/T-cell lymphomas/leukemias remain to be determined. In particular, it cannot be excluded that both blastoid NK cell lymphoma and CD4+/CD56+ primary cutaneous lymphoma partly overlap with or may be identical to the entity called blastic NK cell lymphoma according to the WHO classification.[1]

The only case of intravascular, NK-like lymphoma had such a distinctive morphoimmunophenotypic profile that it deserves a separate category. We preferred to use NK-like instead of NK cell because we were not able to investigate the TCR gene status. On

histopathologic examination, our case exhibited the typical intravascular accumulation of large atypical cells, which dilated and occluded the vascular lumina and were associated with fibrinous thrombi.[86] To the best of our knowledge, this is the first case reported of an intravascular NK-like lymphoma. In fact, most of the previously described cases showed a B-cell phenotype and a concurrent predilection for lung and skin,[87,88] whereas fewer reported cases of T-cell–derived cases showed a clear-cut predilection for the skin.[88–100] The current case characterized by complete remission after initial aggressive polychemotherapy (CHOP), metastasis to the CNS, and death 17 months after diagnosis, has to be considered exceptional as that putatively histiocytic variant reported.[101]

The group of cytotoxic, peripheral T-cell lymphomas by Snowden et al. represented a hodgepodge of cases that did not have unifying features and were lumped together because they did not conform to any of the other categories. These cases were composed of pleomorphic lymphocytes of variable size or blast-like cells with the features of pleomorphic small to medium-sized cutaneous T-cell lymphoma or large cell cutaneous T-cell lymphoma, CD30−, or large cell cutaneous T-cell lymphoma CD30+/lymphomatoid papulosis according to the EORTC classification. Although the small number of cases does not us allow to draw definite conclusions, it seems that the cytotoxic phenotype does not significantly affect the clinical evolution and prognosis of the single entities, similarly to cytotoxic mycosis fungoides.

In conclusion, primary cutaneous lymphomas expressing the cytotoxic granule-associated protein (TIA-1) and/or the NK cell marker (CD56) include distinct groups of diseases, both clinically and biologically. Our objective was to clarify the clinical, morphologic, and phenotypic features of these distinct categories, which are often characterized by a highly aggressive behavior. Because the finding of a cytotoxic phenotype often has prognostic significance, the routine use of cytotoxic markers in the diagnosis and classification of cutaneous lymphomas should be expanded.

REFERENCES

1. Jaffe ES, Harris NL, Stein H, Vardiman JW. Tumours of haematopoietic and lymphoid tissues. World Health Organization classification of tumours. Lyon: IARC Press, 2001.
2. Willemze R, Kerl H, Sterry W, et al. EORTC classification for primary cutaneous lymphomas: a proposal from the cutaneous lymphoma study group of the European Organization for Research and Treatment of Cancer. *Blood.* 1997;90: 354–374.
3. Felgar RE, Macon WR, Kinney MC, Roberts S, Pasha T, Salhany KE. TIA-1 expression in lymphoid neoplasms: identification of subsets with cytotoxic T lymphocyte or natural killer differentiation. *Am J Pathol.* 1997;150:1893–1900.
4. Jaffe ES, Chan JKC, Su IJ, et al. Report of the workshop on nasal and related extranodal angiocentric T/natural killer cell lymphomas. *Am J Surg Pathol.* 1996;20:103–111.
5. Chan JKC, Sin VC, Wong KF, et al. Nonnasal lymphoma expressing the natural killer cell marker CD56: a clinicopathologic study of 49 cases of an uncommon aggressive neoplasm. *Blood.* 1997;89:4501–4513.
6. Petrella T, Dalac S, Maynadiè M, et al. CD4+ CD56+ cutaneous neoplasms: a distinct hematological entity? *Am J Surg Pathol.* 1999;23:137–146.
7. Dummer R, Potoczna N, Häffner AC, Zimmermann DR, Gilardi S, Burg G. A primary cutaneous non-T, non-B CD4+, CD56+ lymphoma. *Arch Dermatol.* 1996;132:550–553.
8. Berti E, Tomasini D, Vermeer M, Meijer CJLM, Alessi E, Willemze R. Primary cutaneous CD8-positive epidermotropic cytotoxic T-cell lymphomas: a distinct clinicopathologic entity with an aggressive clinical behavior. *Am J Pathol.* 1999;155:483–492.
9. Blakolmer K, Vesely M, Kummer JA, Jurecka W, Mannhalter C, Chott A. Immunoreactivity of B-cell markers (CD79a, L26) in rare cases of extranodal cytotoxic peripheral T-(NK/T-) cell lymphomas. *Mod Pathol.* 2000;13:766–772.
10. Kamarashev J, Burg G, Mingari MC, Kempf W, Hofbauer G, Dummer R. Differential expression of cytotoxic molecules and killer cell inhibitory receptors in CD8+ and CD56+ cutaneous lymphomas. *Am J Pathol.* 2001;158:1593–1598.
11. Montone KT, Brigati DJ. In situ molecular pathology: instrumentation, oligonucleotides, and viral nucleic acid detection. *J Histotechnol.* 1994;17:195.
12. Bottaro M, Berti E, Biondi A, Migone N, Crosti L. Heteroduplex analysis of T-cell receptor γ gene rearrangements for diagnosis and monitoring of cutaneous T-cell lymphomas. *Blood.* 1994;83:3271–3278.
13. Arnold A, Cossman J, Bakhshi A, Jaffe ES, Waldmann TA, Korsmeyer SJ. Immunoglobulin-gene rearrangements as unique clonal markers in human lymphoid neoplasms. *N Engl J Med.* 1983;309:1593–1599.
14. Minden MD, Toyonaga B, Ha K, et al. Somatic rearrangement of T-cell antigen receptor gene in human T-cell malignancies. *Proc Natl Acad Sci USA.* 1985;82:1224–1227.
15. Kimura N, Toyonaga B, Yoshikai Y, Du RP, Mak T. Sequences and repertoire of the human T cell receptor α and β chain variable region genes in thymocytes. *Eur J Immunol.* 1987;17:375–383.
16. Jensen JR, Thestrup-Pedersen K. Subpopulations of T-lymphocytes in a patient with fulminant mycosis fungoides. *Acta Derm Venereol (Stockh).* 1980;60:159–161.
17. Haynes BF, Hensley LL, Jegasothy BV. Phenotypic characterization of skin-infiltrating T cells in cutaneous T-cell lymphoma: comparison with benign cutaneous T-cell infiltrates. *Blood.* 1982;60:463–473.
18. Caputo R, Monti M, Berti E, Cavicchini S. A verrucoid epidermotropic OKT8 positive lymphoma. *Am J Dermatopathol.* 1983;5:159–161.
19. Buechner SA, Winkelmann RK, Banks PM. T cells and T cell subsets in mycosis fungoides and parapsoriasis. A study of 18 cases with anti-human T cell monoclonal antibodies and histochemical techniques. *Arch Dermatol.* 1984;120: 897–905.

20. Bennet SR, Greer JP, Stein RS, Glick AD, Cousar JB, Collins RD. Death due to splenic rupture in suppressor cell mycosis fungoides: a case report. *Am J Clin Pathol.* 1984;82:104–109.
21. Mackie RM, Turbitt ML. A case of pagetoid reticulosis bearing the cytotoxic suppressor surface marker on the lymphoid infiltrate: further evidence that pagetoid reticulosis is not a variant of mycosis fungoides. *Br J Dermatol.* 1984;110:89–94.
22. Gonzalez M, Martin-Pascual MM, Miguel JS, Caballero MD, Lopez Borrasca A. Phenotypic characterization of skin infiltrating cells in pagetoid reticulosis by monoclonal antibodies. *Acta Derm Venereol (Stockh).* 1984;64:421–424.
23. Nasu K, Said J, Vonderheid E, Olerud J, Sako D, Kadin M. Immunopathology of cutaneous T-cell lymphomas. *Am J Pathol.* 1985;119:436–447.
24. Ralfkiaer E, Lange-Wantzin G, Mason DY, Hou Jensen K, Stein H, Thomsen K. Phenotypic characterization of lymphocyte subsets in mycosis fungoides. Comparison with large plaque parapsoriasis and benign chronic dermatoses. *Am J Clin Pathol.* 1985;84:610–619.
25. Quanterman MJ, Lesher JL, Davis LS, Pantazis CG, Mullins S. Rapidly progressive CD8-positive cutaneous T-cell lymphoma with tongue involvement. *Am J Dermatopathol.* 1995;17:287–291.
26. Jimbow K, Maeda K, Ito Y, Ishida O, Takami T. Heterogeneity of cutaneous T-cell lymphoma. Phenotypic and ultrastructural characterization of four unusual cases. *Cancer.* 1985;56:2458–2469.
27. Ohkolhchi K, Aiba S, Tagami H. OKT8-reactive cell mycosis fungoides. *Arch Dermatol.* 1986;122:20–22.
28. Fujiwara Y, Abe Y, Kuyama M, et al. CD8+ cutaneous T-cell lymphoma with pagetoid epidermotropism, and angiocentric, and angiodestructive infiltration. *Arch Dermatol.* 1990; 126:801–804.
29. Urrutia S, Piris MA, Orradre JL, Martinez B, Cruz MA, Garcia-Almagro D. Cytotoxic/suppressor (CD8+, CD4−) cutaneous T-cell lymphoma with aggressive course. *Am J Dermatopathol.* 1990;12:603–606.
30. Agnarsson BA, Vonderheid EC, Kadin ME. Cutaneous T cell lymphoma with suppressor/cytotoxic (CD8) phenotype: identification of rapidly progressive and chronic subtypes. *J Am Acad Dermatol.* 1990;22:569–577.
31. Smoller BR, Stewart M, Warnke R. A case of Woringer-Kolopp disease (localized pagetoid reticulosis) or unilesional mycosis fungoides? *Arch Dermatol.* 1992;128:526–529.
32. Marti RM, Estrach T, Palou J, et al. Specific cutaneous lesions in a CD8+ peripheral T-cell lymphoma. *Int J Dermatol.* 1992;31:624–628.
33. Kikuchi A, Sakuraoka K, Kurihara S, Akiyama M, Shimizu H, Nishikawa T. CD8+ cutaneous anaplastić large-cell lymphoma: report of two cases with immunophenotyping, T-cell-receptor gene rearrangement and electron microscopic studies. *Br J Dermatol.* 1992;126:404–408.
34. Zinzani PL, Magagnoli M, Bendandi M, et al. Therapy with gemcitabine in pretreated peripheral T-cell lymphoma patients. *Ann Oncol.* 1998;9:1351–1353.
35. Harris NL, Jaffe ES, Stein H, et al. A revised European-American classification of lymphoid neoplasms: a proposal from the International Lymphoma Study Group. *Blood.* 1994;84:1361–1392.
36. Wick MR, Sanchez NP, Crotty CP, Winkelmann RK. Cutaneous malignant histiocytosis: a clinical and histologic study of eight cases, with an immunohistochemical analysis. *J Am Acad Dermatol.* 1983;8:50–62.
37. Ashworth J, Coady AT, Guy R, Breathnach SM. Brawny cutaneous induration and granulomatous panniculitis in large cell non-Hodgkin's (T suppressor/cytotoxic cell) lymphoma. *Br J Dermatol.* 1989;120:563–569.
38. Tanaka K, Hagari Y, Sano Y, Shimano S, Namba K. A case of T-cell lymphoma associated with panniculitis, progressive pancytopenia and hyperbilirubunemia. *Br J Dermatol.* 1990;123:649–652.
39. Gonzalez CL, Medeiros J, Braziel RM, Jaffe ES. T-cell lymphoma involving subcutaneous tissue. A clinicopathologic entity commonly associated with hemophagocytic syndrome. *Am J Surg Pathol.* 1991;15:17–27.
40. Burg G, Dummer R, Wilhelm M, et al. A subcutaneous delta-positive T-cell lymphoma that produces interferon gamma. *N Engl J Med.* 1991;325:1078–1081.
41. Smith KJ, Skelton HG, Giblin WL, James WD. Cutaneous lesions of hemophagocytic syndrome in a patient with T-cell lymphoma and active Epstein-Barr virus infection. *J Am Acad Dermatol.* 1991;25:919–924.
42. Grange F, Avril MF, Duvillard P, et al. Lymphome à grandes cellules anaplasiques Ki1+ en tissu sous-cutané, avec aspect clinique de panniculite. *Ann Dermatol Venereol.* 1992; 119:890–892.
43. Hytiroglou P, Phelps RG, Wattenberg DJ, Strauchen JA. Histiocytic cytophagic panniculitis: molecular evidence for a clonal T-cell disorder. *J Am Acad Dermatol.* 1992;27:333–336.
44. Prescott RJ, Banerjee SS, Cross PA. Subcutaneous T-cell lymphoma with florid granulomatous panniculitis. *Histopathology.* 1992;20:535–537.
45. Kaplan MA, Jacobson JO, Ferry JA, Harris NL. T-cell lymphoma of the vulva in a renal allograft recipient with associated hemophagocytosis. *Am J Surg Pathol.* 1993;17: 842–849.
46. Avinoach I, Halevy S, Argov S, Sacks M. λ/δ T-cell lymphoma involving the subcutaneous tissue and associated with a hemophagocytic syndrome. *Am J Dermatopathol.* 1994;16:426–433.
47. Chan YF, Lee KC, Llewellyn H. Subcutaneous T-cell lymphoma presenting as panniculitis in children: report of two cases. *Pediatr Pathol.* 1994;14:595–608.
48. Mehregan DA, Su D, Kurtin PJ. Subcutaneous T-cell lymphoma: a clinical, histopathologic and immunohistochemical study of six cases. *J Cutan Pathol.* 1994;21:110–117.
49. Perniciaro C, Winkelmann RK, Ehrhardt D. Fatal systemic cytophagic histiocytic panniculitis: a histopathologic and immunohistochemical study of multiple organ sites. *J Am Acad Dermatol.* 1994;31:901–905.
50. Harada H, Iwatsuki K, Kaneko F. Detection of Epstein-Barr virus genes in malignant lymphoma with clinical and histologic features of cytophagic histiocytic panniculitis. *J Am Acad Dermatol.* 1994;31:379–383.
51. Cho KH, Oh JK, Kim CW, Heo DS, Kim ST. Peripheral T-cell lymphoma involving subcutaneous tissue. *Br J Dermatol.* 1995;132:290–295.
52. Wang CY, Su WP, Kurtin PJ. Subcutaneous panniculitis T-cell lymphoma. *Int J Dermatol.* 1996;35:1–8.
53. Romero LS, Goltz RW, Nagi C, Shin SS, Ho A. Subcutaneous T-cell lymphoma with associated hemophagocytic syndrome and terminal leukemic transformation. *J Am Acad Dermatol.* 1996;34:904–910.

54. Sajben FP, Schmidt C. Subcutaneous T-cell lymphoma: a case report and additional observations. *Cutis.* 1996;58: 297–302.
55. von den Driesch P, Staib G, Simon M, Sterry W. Subcutaneous T-cell lymphoma. *J Am Acad Dermatol.* 1997;36:285–289.
56. Dargent JL, Roufosse C, Delville JP, et al. Subcutaneous panniculitis-like T-cell lymphoma: further evidence for a distinct neoplasm originating from large granular lymphocytes of T/NK phenotype. *J Cutan Pathol.* 1998;25:394–400.
57. Salhany KE, Macon WR, Choi JK, et al. Subcutaneous panniculitis-like T-cell lymphoma. Clinicopathologic, immunophenotypic, and genotypic analysis of alpha/beta and gamma/delta subtypes. *Am J Surg Pathol.* 1998;22:881–893.
58. Kumar S, Krenacs L, Medeiros J, et al. Subcutaneous panniculitic T-cell lymphoma is a tumor of cytotoxic T lymphocytes. *Hum Pathol.* 1998;29:397–403.
59. Craig AJ, Cualing H, Thomas G, Lamerson C, Smith R. Cytophagic histiocytic panniculitis—a syndrome associated with benign and malignant panniculitis: case comparison and review of the literature. *J Am Acad Dermatol.* 1998;39:721–736.
60. Ralfkiaer E, Wollf-Sneedorff A, Thomsen K, Geisler C, Vejlsgaard GL. T-cell receptor λ/δ -positive peripheral T-cell lymphomas presenting in the skin: a clinical, histological and immunophenotypic study. *Exp Dermatol.* 1992;1:31–36.
61. Fujita M, Miyachi Y, Furukawa F, et al. A case of cutaneous T-cell lymphoma expressing λ/δ T-cell receptors. *J Am Acad Dermatol.* 1993;28:355–360.
62. Munn SE, McGregor JM, Jones A, et al. Clinical and pathological heterogeneity in cutaneous gamma-delta T-cell lymphoma: a report of three cases and a review of the literature. *Br J Dermatol.* 1996;135:976–981.
63. Tsang WYW, Chan JKC, Pau MY. Utility of a paraffin section-reactive CD56 antibody (123C3) for characterization and diagnosis of lymphomas. *Am J Surg Pathol.* 1996;20: 202–210.
64. Jaffe ES. Classification of natural killer (NK) cell and NK-like T-cell malignancies. *Blood.* 1996;87:1207–1210.
65. Jaffe ES, Krenacs L, Raffeld M. Classification of T-cell and NK-cell neoplasms based on the REAL classification. *Ann Oncol.* 1997;8(Suppl 2):S17.
66. Chan JKC, Tsang WYW, Lau WH, et al. Aggressive T/natural killer lymphoma presenting as testicular tumor. *Cancer.* 1996;77:1198–1205.
67. Ansai SI, Maeda K, Yamakawa M, et al. CD56-positive (nasal-type T/NK cell) lymphoma arising on the skin. Report of two cases and review of the literature. *J Cutan Pathol.* 1997;24:468–476.
68. Kwong YL, Chan ACL, Liang R, et al. CD56+ NK lymphomas: clinicopathologic features and prognosis. *Br J Haematol.* 1997;97:821–829.
69. Natkunam Y, Smoller BR, Zehnder JL, Dorfman RF, Warnke RA. Aggressive cutaneous NK and NK-like T-cell lymphomas. *Am J Surg Pathol.* 1999;23:571–581.
70. Imamura N, Kusunikoi Y, Kawa-Ha K, et al. Aggressive natural killer cell leukemia/lymphoma: report of four cases and review of the literature. Possible existence of a new clinical entity originated from the third lineage of lymphoid cells. *Br J Haematol.* 1990;75:49–59.
71. Sun T, Brody J, Susin M, et al. Aggressive natural killer cell lymphoma/leukemia: a recently recognized clinico-pathologic entity. *Am J Surg Pathol.* 1993;17:1289–1299.
72. Berceanu S, Roman S, Butoianu E, et al. A particular case of large granular lymphocytes lymphoma. *Haematologica.* 1989;22:43–53.
73. Sun T, Schulman P, Kolitz J, et al. A study of lymphoma of large granular lymphocytes with modern modalities: report of two cases and review of the literature. *Am J Hematol.* 1992;40:135–142.
74. Chan JKC, Ng CS, Ngan KC, Hui PK, Lo STH, Lau WH. Angiocentric T-cell lymphoma of the skin: an aggressive lymphoma distinct from mycosis fungoides. *Am J Surg Pathol.* 1988;12:861–876.
75. Hayashi K, Nakamura S, Koshikawa T, et al. A case of neural cell adhesion molecule-positive peripheral T-cell lymphoma associated with human T-cell lymphotrophic virus type 1 showing an unusual involvement of the gastrointestinal tract during the course of the disease. *Hum Pathol.* 1994;25:1251–1253.
76. Tsang WYW, Chan JKC, Yip TTC, et al. In situ localization of Epstein-Barr virus encoded RNA in non-nasal/nasopharyngeal CD56-positive and CD56-negative T-cell lymphoma. *Hum Pathol.* 1994;25:758–765.
77. Takayama A, Ochiai T, Yoshizawa K, Fujisawa S, Morishima T. Cutaneous natural killer cell lymphoma. *Skin Cancer.* 1996;7:376.
78. Nakamura S, Suchi T, Koshikawa T, et al. Clinicopathologic study of CD56 (NCAM)-positive angiocentric lymphoma occurring in sites other than the upper and lower respiratory tract. *Am J Surg Pathol.* 1995;19:284–296.
79. Wong KF, Chan JKC, Ng CS, Lee KC, Tsang WYW, Cheung MMC. CD56 (NKH1)-positive hematolymphoid malignancies: an aggressive neoplasm featuring frequent cutaneous-mucosal involvement, cytoplasmic azurophilic granules and angiocentricity. *Hum Pathol.* 1992;23:798–804.
80. Adachi M, Maeda K, Takekawa M, et al. High expression of CD56 (N-CAM) in a patient with cutaneous CD4-positive lymphoma. *Am J Hematol.* 1994;47:278–282.
81. Wasik MA, Sackstein R, Novick D, et al. Cutaneous CD56+ large T-cell lymphoma associated with high serum concentration of IL-2. *Hum Pathol.* 1996;27:738–744.
82. Imamura N, Kusunoki Y, Kajihara H, Okada K, Kuramoto A. Aggressive natural killer cell leukemia/lymphoma with N901-positive surface phenotype: evidence for the existence of a third lineage of lymphoid cells. *Acta Haematol.* 1988;80:121–128.
83. Gattei V, Carbone A, Marotta G, et al. Expression of the natural killer antigens in malignant histiocytosis and a subset of acute myelomonocytic leukemias. *Bone Marrow Transplant.* 1989;4:22.
84. Gattei V, Carbone A, Zagonel V, Pinto A. Expression of natural killer antigens in a subset of non-T, non-B lymphoma/leukemia with histiocytic features. *Br J Haematol.* 1990; 76:444–448.
85. DiGiuseppe JA, Louie DC, Williams JE, et al. Blastic natural killer cell leukemia/lymphoma: a clinicopathologic study. *Am J Surg Pathol.* 1997;21:1223–1230.
86. Wick MR, Mills SE, Scheithauer BW, Cooper PH, Davitz MA, Parkinson K. Reassessment of malignant endotheliomatosis. Evidence in favour of its reclassification as "intravascular lymphoma." *Am J Surg Pathol.* 1986;10:112–123.
87. Carroll TJ Jr., Schelper RL, Goeken JA, Kemp JD. Neoplastic angioendotheliomatosis: immunopathologic and morphologic evidence for intravascular malignant lymphomatosis. *Am J Clin Pathol.* 1986;85:169–175.

88. Stroup RM, Sheibani K, Moncada A, Purdy LJ, Battifora H. Angiotropic (intravascular) large cell lymphoma: a clinicopathologic study of seven cases with unique clinical presentations. *Cancer*. 1990;66:1781–1788.
89. Sheibani K, Battifora H, Winberg CD, et al. Further evidence that "malignant angioendotheliomatosis" is an angiotropic large-cell lymphoma. *N Engl J Med*. 1986;314:943–948.
90. Maruyama N, Ishida Y, Sato H, Koike T, Nagao K. Expression of lymphocyte-associated antigens on neoplastic angioendotheliosis. *Appl Pathol*. 1986;5:246.
91. Sepp N, Schuler G, Romani N, et al. "Intravascular lymphomatosis" (angioendotheliomatosis): evidence for a T-cell origin in two cases. *Hum Pathol*. 1990;21:1051–1058.
92. Tateyama H, Eimoto T, Tada T, Kamiya M, Fujiyoshi Y, Kajiura S. Congenital angiotropic lymphoma (intravascular lymphomatosis) of the T-cell type. *Cancer*. 1991;67:2131–2136.
93. Clark WC, Dohan FC, Moss T, Schweitzer JB. Immunocytochemical evidence of lymphocytic derivation of neoplastic cells in malignant endotheliomatosis. *J Neurosurg*. 1991; 74:757–762.
94. Shimokawa I, Higami Y, Sakai H, Moriuchi Y, Murase K, Ikeda T. Intravascular malignant lymphomatosis: a case of T-cell lymphoma probably associated with human T-cell lymphotropic virus. *Hum Pathol*. 1991; 22:200–202.
95. Sangueza O, Hyder DM, Sangueza P. Intravascular lymphomatosis: report of an unusual case with T-cell phenotype occurring in an adolescent male. *J Cutan Pathol*. 1992;19: 226–231.
96. Lopez-Gil F, Roura M, Umbert I, Umbert P. Malignant proliferative angioendotheliomatosis or angiotropic lymphoma associated with a soft-tissue lymphoma. *J Am Acad Dermatol*. 1992;26:101–104.
97. Glass J, Hochberg FH, Miller DC. Intravascular lymphomatosis: a systemic disease with neurologic manifestations. *Cancer*. 1993;71:3156–3164.
98. DiGiuseppe JA, Nelson WG, Seifter EJ, Boitnott JK, Mann RB. Intravascular lymphomatosis: a clinicopathologic study of 10 cases and assessment of response to chemotherapy. *J Clin Oncol*. 1994;12:2573–2579.
99. Ghorbani RP, Shokouh-Amiri H, Gaber LW. Intragraft angiotropic large-cell lymphoma of T-cell type in a long-term renal allograft recipient. *Mod Pathol*. 1996;9:671–676.
100. Au WY, Shek WH, Nicholls J, Tse KM, Todd D, Kwong YL. T-cell intravascular lymphomatosis (angiotropic large cell lymphoma): association with Epstein-Barr viral infection. *Histopathology*. 1997;31:563–567.
101. Snowden JA, Angel CA, Winfield DA, Pringle JH, West KP. Angiotropic lymphoma: report of a case with histiocytic features. *J Clin Pathol*. 1997;50:67–70.