



UNIVERSITÀ  
DEGLI STUDI  
FIRENZE

## FLORE

# Repository istituzionale dell'Università degli Studi di Firenze

### **A diagnosis of Fabry gastrointestinal disease by chance: a case report.**

Questa è la Versione finale referata (Post print/Accepted manuscript) della seguente pubblicazione:

*Original Citation:*

A diagnosis of Fabry gastrointestinal disease by chance: a case report / FERIOZZI S; SANZ TORRE E; RANALLI T V; CARDELLO P; A. MORRONE; ANCARANI E. - In: EUROPEAN JOURNAL OF GASTROENTEROLOGY & HEPATOLOGY. - ISSN 0954-691X. - STAMPA. - 19(2)::(2007), pp. 163-165.  
[10.1097/MEG.0b013e32800fef46]

*Availability:*

This version is available at: 2158/216178 since:

*Publisher:*

Lippincott, Williams & Wilkins:530 Walnut Street:Philadelphia, PA 19106:(800)638-3030, (301)223-2300,

*Published version:*

DOI: 10.1097/MEG.0b013e32800fef46

*Terms of use:*

Open Access

La pubblicazione è resa disponibile sotto le norme e i termini della licenza di deposito, secondo quanto stabilito dalla Policy per l'accesso aperto dell'Università degli Studi di Firenze (<https://www.sba.unifi.it/upload/policy-oa-2016-1.pdf>)

*Publisher copyright claim:*

(Article begins on next page)

# A diagnosis of Fabry gastrointestinal disease by chance: a case report

Sandro Feriozzi<sup>a</sup>, Elena Sanz Torre<sup>b</sup>, Teresa Valentina Ranalli<sup>c</sup>, Paolo Cardello<sup>d</sup>, Amelia Morrone<sup>e</sup> and Enzo Ancarani<sup>a</sup>

**Fabry disease is an X-linked lysosomal storage disease caused by a deficiency of  $\alpha$ -galactosidase A. This determines an accumulation of globotriaosylceramide within lysosomes. The clinical picture is highly variable and depends on cellular storage deposition. Renal, cardiac and nervous system are the most frequent organs involved. Gastrointestinal involvement is also present, associated with other clinical signs of Fabry disease and sometimes can be a prominent clinical manifestation. We describe a Fabry disease case in which gastrointestinal involvement was the first and the only clinical sign of Fabry disease and a diagnosis of Fabry disease was made by chance during a family screening. Enzyme replacement therapy was started and after 3 months, there was a complete disappearance of**

**signs. *Eur J Gastroenterol Hepatol* 19:163–165 © 2007 Lippincott Williams & Wilkins.**

European Journal of Gastroenterology & Hepatology 2007, 19:163–165

**Keywords:**  $\alpha$ -galactosidase A, agalsidase- $\alpha$ , enzyme replacement therapy, Fabry disease, gastrointestinal involvement

Departments of <sup>a</sup>Nephrology and Dialysis, <sup>b</sup>Gastroenterology, <sup>c</sup>Pathology, <sup>d</sup>Radiology, Belcolle Hospital, Viterbo and <sup>e</sup>Department of Pediatrics, Metabolic Unit, Florence, Italy

Correspondence to Sandro Feriozzi, MD, Nephrology and Dialysis, Ospedale Belcolle, Via sammartinese, snc, 01100 Viterbo, Italy  
Tel: +39 0761 403488; fax: +39 0761 338602;  
e-mail: nefrvit3@asl.vt.it, sandro.feriozzi@tiscali.it

Received 20 July 2006 Accepted 19 August 2006

## Introduction

Fabry disease (FD) is a lysosomal storage disorder caused by a mutation affecting the  $\alpha$ -galactosidase A (*GLA*) gene, mapped at locus Xq22 of the long arm of the X chromosome, that encodes the  $\alpha$ -galactosidase A (GAL A) enzyme. This change determines a total or partial deficiency of GAL A enzyme that results in a pathologic metabolism of glycosphingolipids and a progressive accumulation of globotriaosylceramide (Gb3) within lysosomes. The clinical picture is due to the involvement of cells of different organs by the Gb3 accumulation. Renal involvement (proteinuria and progressive renal failure), cardiac disease (hypertrophic cardiomyopathy) and neurological involvement (stroke in young people) are the most frequent and common features. As the intracellular accumulation of Gb3 can be found in any tissue, the clinical involvement will be extremely variable and a number of other signs and symptoms will be present (fever, pain on lower limbs, heat intolerance) [1]. Gastrointestinal involvement has been also described with bouts of pain, diarrhoea and constipation [2,3].

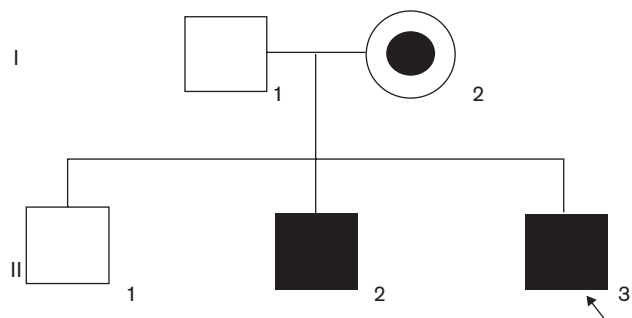
We describe a case of a young man with bouts of abdominal pain and constipation, in whom Crohn's disease was suspected. The only significant clinical manifestation of FD was, actually, gastrointestinal symptoms. The diagnosis was made by chance (during a family biochemical and molecular analysis) and the enzyme replacement therapy (ERT) was associated with a complete recovery.

## Case report

In June 2004, a diagnosis of FD was made in a 26-year-old man (II: 2, Fig. 1). He had started regular haemodialytic treatment some weeks before because of a severe renal involvement with kidney failure (stage 5 K/DOQI CKD). No other clinical signs and or symptoms of FD were present except heat intolerance. In order to exclude a FD in our Unit, a screening of GAL A enzyme, on blood spot, was performed in all patients in haemodialytic treatment with unknown diagnosis. During such a screening,  $\alpha$ -GAL A plasma level was almost absent in this patient and this result was confirmed also on leukocytes (2.2 nmol/mg/h; n.v. > 46). On the basis of this, the entire *GLA* gene encoding region and the exon/intron boundaries were sequenced and a new c1079G > A nucleotide transition that leads to a new G360D amino acid change was identified.

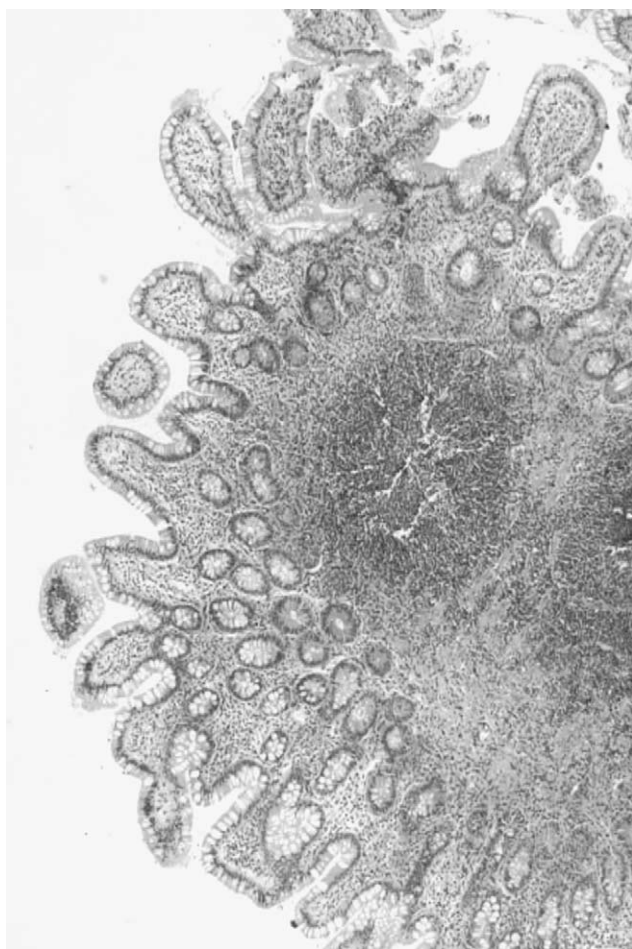
Afterwards (September 2004), his family (mother and two brothers, Fig. 1) was investigated for a  $\alpha$ -GAL deficiency. For his older brother (II:1), the anamnesis was negative, whereas his younger brother (II:3) reported a long history of gastrointestinal symptoms with recurrent bouts of abdominal pain associated with both constipation and diarrhoea. A few months before our diagnosis (April 2004), he was admitted to a University Hospital because of an episode of fever associated with pain in the lower limbs. The routinely performed laboratory analyses were in the normal range: serum creatinine 79.5  $\mu$ mol/l, blood urea nitrogen 10.3 mmol/l, uric acid 362.8  $\mu$ mol/l, glucose 3.6 mmol/l, cholesterol 3.57 mmol/l, triglycerides 0.994 mmol/l, red

Fig. 1



Pedigree of the family in study.

Fig. 2

Normal ileum. An aggregated lymphatic nodule presenting in mucosa and submucosa (haematoxylin-eosin stain, magnification  $\times 100$ ).

blood cells  $4780.000 \times 10^{12}/l$ , Hb 13.9 g/l, white blood cells  $8.240 \times 10^9/l^3$ , platelets  $304 \times 10^9/l$ . A mild increase of: erythrocyte sedimentation rate (ESR) 52 mm/h, C-reactive

protein (CPR) 5 mg/dl (n.v.  $< 1$  mg/l),  $\beta$ -2 serum microglobulin 2.7 mg/l (n.v.  $< 2.7$  mg/l) was seen. Chest radiograph, ECG, renal and liver ultrasound and auto-antibodies and infectious tests were negative. An echocardiography was normal. Rheumatology and haematology consultancies were inconclusive.

To investigate gastrointestinal symptoms, a colonoscopy was carried out which displayed a flat adenoma and some small areas of hyperaemia. Notwithstanding a nonspecific histological examination, Crohn's disease was suspected.

Meanwhile, the genetic investigation (September 2004) carried out in this family led to the identification of the c1079G  $>$  A (G360D) genetic lesion in his mother (I:2) at heterozygous level, and at hemizygous level in the brother (II:3) with gastrointestinal symptoms, whereas the analysis in the other brother (II:1) was negative. Alpha-GAL A enzyme activity in leukocytes was 0.9 nmol/mg/h in the patient with only gastrointestinal symptoms (II:3); 40% of normal control in his mother. On the basis of that, a diagnosis of FD was made in this family (Fig. 1).

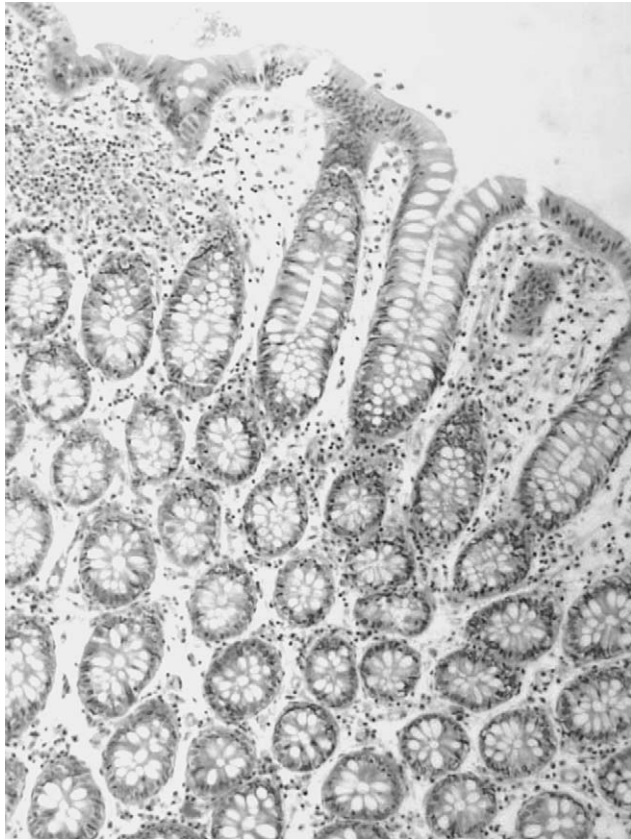
In January–March 2005, the patient (II:3) with gastrointestinal symptoms, was admitted at our hospital and carefully investigated for FD. No other clinical symptoms and or signs were found (kidney, heart, etc.), in particular, inflammation indexes (ESR, CPR,  $\beta$ 2) were within the normal range. A gastrointestinal screening, a radiograph enteroclysis of the colon and an endoscopy were all negative (Figs 2 and 3). He complained only of a mild heat intolerance. Then, ERT was started (agalsidase- $\alpha$  0.2 mg/kg/15 days) and after 3 months he referred a significant improvement of his bowel functions: the bouts of diarrhoea and constipation had disappeared.

## Discussion

This case showed the importance of including a suspect of a FD in the differential diagnosis of gastrointestinal disorders. Indeed, nonspecific gastrointestinal symptoms can be present in FD patients and include abdominal pain, diarrhoea, constipation, bloating, vomiting and poor weight gain. In a review, based on data collected from all Europe (Fabry Outcome Survey, FOS) and regarding a collection of 366 FD patients, gastrointestinal symptoms were present in 57% of males and 47% of females with FD: the most frequent symptoms were abdominal pain and diarrhoea [4]. Histological studies have demonstrated that gastrointestinal involvement in FD is very likely due to Gb3 accumulation in vegetative neurons of Meissner's plexus, in endothelial cells of vessels and in smooth muscle cells, compromising mesenteric circulation [3,5].

On the other hand, sometimes FD is concomitant with other gastrointestinal diseases. Tumer *et al.* [6] described

Fig. 3



Large bowel: a normal structure is evident (haematoxylin–eosin stain, magnification  $\times 200$ ).

the presence of FD in an 11-year-old girl affected by coeliac disease. Diagnosis of FD was made with a renal biopsy carried out because of proteinuria. In addition, the coexistence of FD and Crohn's disease has been recently described [7] in a 30-year-old woman. In this case, a hereditary nephropathy was suspected because her mother died in end-stage renal failure and her brother also was affected by a chronic renal failure. Laboratory and genetic investigation displayed GAL A enzyme deficiency in this family.

In our case, the diagnosis was made by chance during a biochemical and molecular analysis family screening for FD. Crohn's disease was suspected in our patient because gastrointestinal symptoms were associated with a mild increase of inflammation (CPR, ESR). Small bowel radiograph and histological study of intestinal mucosa, however, did not display any lesions consistent with Crohn's disease like stenosis of abdominal lumen or granulomas and changes in the architecture of glands. Regarding FD, two clues, although nonspecific for FD, were present in the clinical history: the episode of unknown fever associated with pain in lower limbs and the existence of a brother with renal failure.

The start of ERT was followed, after 3 months, by a complete recovery and all gastrointestinal symptoms disappeared. A significant improvement of gastrointestinal diseases with ERT is shared in some experiences. Dehout *et al.* [8] describes a reduction of severity and frequency of abdominal pain after 6 months of ERT in a group of FD patients. Banikazemi *et al.* [9] reported marked improvements of gastrointestinal symptoms after 6–7 months of ERT and the patients were able to interrupt their gastrointestinal medications. It can be interesting to point out that, in our case, clinical improvement was observed after only 3 months of ERT. That might be due to a milder cellular accumulation of Gb3 or a particular sensitivity of our patient to ERT. On the other hand, a very rapid improvement of gastrointestinal symptoms, following the first few infusions of ERT, has been already described by Hoffmann *et al.* [10] in a patient with a typical long story of FD. Actually, the reasons for which some patients have these prompt responses to ERT remain still unclear [10].

This case demonstrates how diagnosis of FD can be an easily missed diagnosis because a very wide range of symptoms may be present. Moreover, often clinical features are nonspecific, like bouts of intestinal problems and the diagnosis of FD is possible only taking it into account in a differential diagnosis. Moreover, our report confirms that ERT is able to correct the clinical picture of gastrointestinal disorder completely. We also would like to stress the interfamilial clinical heterogeneity in this family.

## References

- Desnick RJ, Ioannou YA, Eng CM.  $\alpha$ -Galactosidase A deficiency: Fabry disease. In: Scriver CR, Beaudet AL, Sly WS, Valle D, editors. *The metabolic and molecular bases of inherited disease*. 2nd ed. Vol. 3. New York: McGraw-Hill; 2001. pp. 3733–3774.
- Sheth K, Werlin S, Freeman N, Hodach A. Gastrointestinal structure and function in Fabry disease. *Am J Gastroenterol* 1981; **76**:246–251.
- Rowe J, Gilliam J, Warthin T. Intestinal manifestation of Fabry disease. *Ann Int Med* 1974; **81**:628–631.
- Mehta A, Ricci R, Widmer U, Dehout F, Garcia de Lorenzo A, Kampmann C, *et al.* Fabry disease defined: baseline clinical manifestation of 366 patients in the Fabry outcome survey. *Eur J Clin Invest* 2004; **34**:236–242.
- O'Brien B, Shnitka T, McDougall R, Walker K, Costopoulos L, Lentle B, *et al.* Pathophysiologic and ultrastructural basis for intestinal symptoms in Fabry's disease. *Gastroenterology* 1982; **82**:957–962.
- Tumer L, Ezgu F, Hasanoglu A, Dalgic B, Bakaloglu S, Memis L, Dursun A. The co-existence of Fabry and celiac diseases: a case report. *Pediatr Nephrol* 2004; **19**:679–681.
- Altarescu G, Elstein D. Coexistence of Fabry disease and Crohn's disease: a case report. *Inflamm Bowel Dis* 2005; **11**:87–88.
- Dehout F, Roland D, Treille de Grasseigne S, Guillaume B, Van Maldergem L. Relief of gastrointestinal symptoms under enzyme replacement therapy in patients with Fabry disease. *J Inherited Metab Dis* 2004; **27**: 499–505.
- Banikazemi M, Ullman T, Desnick R. Gastrointestinal manifestations of Fabry disease: clinical response to enzyme replacement therapy. *Mol Genet Metab* 2005; **85**:255–259.
- Hoffmann B, Reinhardt D, Koletzko B. Effect of enzyme-replacement therapy on gastrointestinal symptoms in Fabry disease. *Eur J Gastroenterol Hepatol* 2004; **16**:1067–1069.