



UNIVERSITÀ
DEGLI STUDI
FIRENZE

FLORE

Repository istituzionale dell'Università degli Studi di Firenze

Comparison of baseline and low-dose dobutamine technetium-99m sestamibi scintigraphy with low-dose dobutamine echocardiography

Questa è la Versione finale referata (Post print/Accepted manuscript) della seguente pubblicazione:

Original Citation:

Comparison of baseline and low-dose dobutamine technetium-99m sestamibi scintigraphy with low-dose dobutamine echocardiography for predicting functional recovery after revascularization / LEONCINI M; MARCUCCI G; R. SCIAGRA'; MONDANELLI D; TRAINI AM; MAGNI M; FRASCARELLI F; MENNUTI A; DABIZZI RP.. - In: THE AMERICAN JOURNAL OF CARDIOLOGY. - ISSN 0002-9149. - STAMPA. - 86(2000), pp. 153-157.

Availability:

This version is available at: 2158/222309 since:

Publisher:

EXCERPTA MEDICA INC, 650 AVENUE OF THE AMERICAS, NEW YORK, USA, NY, 10011 editore precedente:

Terms of use:

Open Access

La pubblicazione è resa disponibile sotto le norme e i termini della licenza di deposito, secondo quanto stabilito dalla Policy per l'accesso aperto dell'Università degli Studi di Firenze (<https://www.sba.unifi.it/upload/policy-oa-2016-1.pdf>)

Publisher copyright claim:

(Article begins on next page)

Comparison of Baseline and Low-Dose Dobutamine Technetium-99m Sestamibi Scintigraphy With Low-Dose Dobutamine Echocardiography for Predicting Functional Recovery After Revascularization

Mario Leoncini, MD, Gabriella Marcucci, MD, Roberto Sciagrà, MD, Dante Mondanelli, MD, Anna Maria Traini, MD, Massimo Magni, MD, Fabio Frascarelli, MD, Alberto Mennuti, MD, and Roberto P. Dabizzi, MD

Injection of sestamibi during low-dose dobutamine (LDD) infusion might improve tracer ability to detect viable myocardium. This study investigated the potential value of LDD technetium-99m sestamibi (sestamibi) single-photon emission computed tomography (SPECT) in predicting functional recovery after revascularization by comparing its results with those of sestamibi SPECT at rest and of LDD echocardiography. Before revascularization, 23 patients with chronic coronary artery disease and regional left ventricular dysfunction underwent sestamibi SPECT at rest and, on a separate day, LDD echocardiography and sestamibi SPECT with tracer injection during LDD infusion. Echocardiography at rest was repeated after revascularization. Semiquantitative sestamibi uptake results (grading from 0 = normal to 4 = absent) and wall motion (grading from 1 = normal to 4 = dyskinesia) were evaluated with a 16-segment

model. The ventricular wall was divided into 3 vascular territories. At follow-up, 20 of 32 asynergic vascular territories showed functional recovery, whereas 12 showed no changes. For prediction of functional recovery, LDD SPECT achieved better accuracy than SPECT at rest (87% vs 65%, $p < 0.05$); positive and negative predictive values of LDD SPECT were 90% and 83%, respectively, which was not significantly different from the related LDD echocardiographic values (84% and 69%). Thus, LDD sestamibi SPECT appears to be a promising method for detecting myocardial viability, which provides better accuracy than sestamibi SPECT at rest, and achieves predictive values comparable to those of LDD echocardiography. ©2000 by Excerpta Medica, Inc.

(Am J Cardiol 2000;86:153-157)

The reliability of technetium-99m sestamibi (sestamibi) scintigraphy for the evaluation of myocardial viability is controversial. Uptake correlates with the extent of viable myocardium,^{1,2} but sestamibi scintigraphy at rest seems to underestimate myocardial viability compared with thallium-201 scintigraphy or positron emission tomography,^{3,4} and shows just a fair agreement with low-dose dobutamine (LDD) echocardiography.⁵⁻⁷ However, delayed imaging,⁸ quantitative analysis of single-photon emission computed tomography (SPECT),⁹ or tracer injection under nitrate administration^{10,11} improve sestamibi recognition of viable myocardium. Because injection during LDD infusion increases sestamibi uptake in recent infarction,¹² this approach has been suggested to improve viability detection.¹³ The aim of the present study was (1) to investigate the ability of baseline and LDD

sestamibi SPECT to predict recovery of regional ventricular function after revascularization in patients with chronic coronary artery disease and left ventricular dysfunction, and (2) to compare sestamibi SPECT results with those of LDD echocardiography.

METHODS

Patient population: We prospectively enrolled 31 consecutive patients with coronary artery disease scheduled for revascularization based on the independent judgment of the referring physician. Sestamibi SPECT and LDD echocardiographic results were not a prerequisite for revascularization. Other inclusion criteria were left ventricular dysfunction with >3 contiguous asynergic segments, and $\geq 75\%$ stenosis of the related vessel. Of the potentially eligible patients, 3 were excluded because of a poor acoustic window. We also excluded patients with recent myocardial infarction or unstable angina, ventricular arrhythmias, and conduction disturbances. After enrollment, we excluded 8 patients because of revascularization refusal or failure, ventricular aneurismectomy, or early vessel reocclusion. Thus, the study group included 23

From the Division of Cardiology and Nuclear Medicine Unit, Misericordia e Dolce Hospital, Prato; Nuclear Medicine Unit, Department of Clinical Physiopathology, University of Florence, Florence, Italy. Manuscript received November 2, 1999; revised manuscript received and accepted February 8, 2000.

Address for reprints: Mario Leoncini, MD, Via del Cittadino 24, 59100, Prato, Italy. E-mail: r.sciagra@dfc.unifi.it.

TABLE 1 Comparison of Sensitivity, Specificity, Predictive Values, and Accuracy of Low-Dose Dobutamine (LDD) Echocardiography, Baseline Resting, and LDD Sestamibi SPECT for Predicting Functional Recovery

	Sensitivity	Specificity	PPV	NPV	Accuracy
LDD echocardiography	16/20 (80%)	9/12 (75%)	16/19 (84%)	9/13 (69%)	25/32 (78%)
SPECT at rest	13/20 (65%)	8/12 (67%)	13/17 (76%)	8/15 (53%)	21/32 (65%)
LDD SPECT	18/20 (90%)*	10/12 (83%)	18/20 (90%)	10/12 (83%)	28/32 (87%) [†]

*p = 0.06; [†]p < 0.05 versus SPECT at rest. Data are presented as number (%) of asynergic coronary artery territories.
NPV = negative predictive value; PPV = positive predictive value.

		Resting SPECT					Resting SPECT		
		+	-		+	-			
LDD echo	+	9	7	16	3	0	3		
	-	4	0	4	1	8	9		
		13	7	20	4	8	12		

FIGURE 1. Agreement between baseline SPECT at rest and LDD echocardiography in territories with (left panel) and without (right panel) functional recovery.

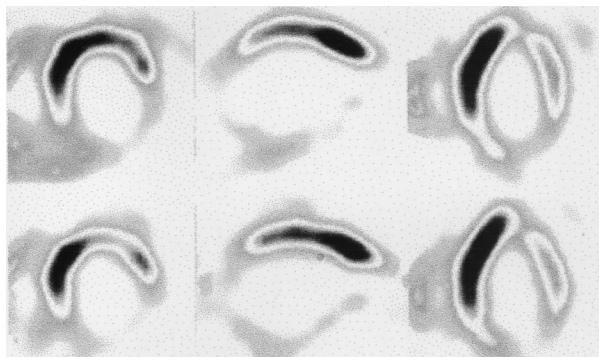


FIGURE 2. Baseline resting (lower row) and LDD (upper row) SPECT slices (from left to right: midventricular short axis, vertical long axis, and horizontal long axis) of a patient with 3-vessel coronary artery disease. A baseline severe inferior defect was not modified in the LDD images; no improvement in regional wall motion was registered after coronary artery bypass grafting.

patients (all men; mean age 59 ± 12 years; mean left ventricular ejection fraction $36 \pm 6\%$).

Study protocol: Before revascularization, patients underwent baseline sestamibi SPECT at rest, LDD echocardiography, and LDD sestamibi SPECT. Baseline resting and LDD studies were performed in the fasting state and in random order on 2 different days with a 24-hour interval. Beta-adrenergic blocking agents were withdrawn 48 hours before the test. Other medications were not administered on the day of the test. After baseline echocardiography, during continuous electrocardiographic, blood pressure, and echocardiographic monitoring, LDD infusion ($5 \mu\text{g}/\text{kg}$ body weight/min) was begun and continued for 5

minutes, and then increased to $10 \mu\text{g}/\text{kg}/\text{min}$ for another 5 minutes. Sestamibi (740 Mbq) was injected at minute 5 of the $10 \mu\text{g}/\text{kg}$ dose, which was maintained for another 60 seconds.¹⁴ After revascularization (≥ 3 months for bypass grafting, 1 month for coronary angioplasty), echocardiography was repeated. All patients gave written informed consent to participate in the protocol.

Echocardiography: Echocardiograms were performed before, during LDD, and at follow-up using all views obtainable from the parasternal and apical approach. Commercial

equipment (Hewlett Packard 1000, 2.5- and 3.5-MHz transducers; Palo Alto, California) was used and images were recorded on videotape for off-line evaluation. The left ventricular wall was divided into 16 segments and 3 vascular territories were considered.¹⁵ Segmental wall motion was scored as: 1 = normal, 2 = hypokinesia, 3 = akinesia, and 4 = dyskinesia.¹⁶ In evaluating wall motion abnormalities, attention was also paid to systolic thickening in the central portion of the segment. Echocardiographic baseline, LDD, and follow-up studies were analyzed in random order by 2 experienced observers who were blinded to the data. Discrepancies were resolved by consensus. An asynergic coronary territory was considered to have contractile reserve in LDD echocardiography or functional recovery in the follow-up control when, compared with the baseline study, it showed a wall motion improvement of ≥ 1 grade in ≥ 2 pertinent contiguous asynergic segments.^{17,18}

Sestamibi SPECT: Images were collected 1 hour after tracer injection using a single-head gamma camera (Siemens Orbiter Digitrac 7500, Chicago, Illinois), equipped with ultra-high resolution collimator, using a 15% window centered on the 140-keV photopeak of technetium-99m. SPECT acquisition was performed in step-and-shoot mode, 180° rotation arc, 32 projections of 40 seconds each, and 64×64 matrixes. Images were reconstructed using filtered back-projection without attenuation or scatter correction. The transaxial slices were realigned along the vertical and horizontal long axes and the short axis of the heart. The left ventricle was divided, considering the short-axis slices at 2 different levels (basal and mid-ventricular, 6 segments each) and the apical portion of the

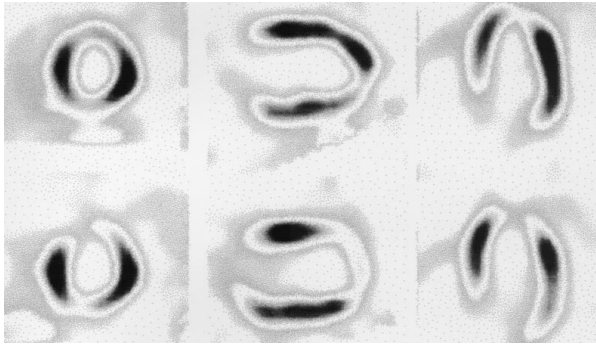


FIGURE 3. Baseline resting and LDD SPECT of a patient with 1-vessel coronary artery disease. Same image disposition as in Figure 2. The baseline anterior defect appears clearly reduced in the LDD images. After coronary angioplasty of the left anterior descending artery, significant functional recovery was observed.

tories probably included viable hibernating myocardium in the presence of normal, mildly or moderately reduced sestamibi uptake (score ≤ 2) in ≥ 2 pertinent contiguous segments.^{20,21}

Statistical analysis: Results are expressed as mean value \pm SD. Positive and negative predictive values, sensitivity, specificity, and accuracy were calculated according to standard definitions. The comparison of variables within groups was made with the Student's *t* test for paired data. The comparison of proportions was made using the Fisher's exact test. A *p* value of <0.05 was considered significant.

RESULTS

Baseline and follow-up echocardiography: In the 23 patients, a total of 32 vascular territories supplied by critically stenotic coronary vessels were successfully revascularized. These territories included 44 normal and 166 asynergic segments. After revascularization, 73 abnormal segments improved function. In terms of coronary artery regions, 20 of 32 asynergic territories showed functional recovery at follow-up, whereas 12 showed no changes.

Prediction of functional recovery: LDD ECHOCARDIOGRAPHY: No complications occurred during infusion and all patients completed the LDD protocol. Heart rate increased from 68 ± 9 beats/min at rest to 88 ± 2 beats/min at peak infusion ($p < 0.005$), and systolic blood pressure increased from 128 ± 17 mm Hg at rest to 144 ± 28 mm Hg at peak infusion ($p < 0.0002$). The presence of contractile reserve in LDD echocardiography correctly identified 16 of 20 territories with functional recovery (sensitivity 80%); its absence was registered in 9 of 12 territories with unchanged dysfunction after revascularization (specificity 75%). The related positive predictive value was 84% and the negative predictive value was 69%, with an overall accuracy for prediction of functional recovery of 78% (Table I).

BASELINE SESTAMIBI SPECT AT REST: SPECT at rest showed normal or mild to moderate uptake in 13 regions with functional recovery and in 4 territories with unchanged dysfunction (sensitivity 65%; specificity 67%), with 76% positive and 53% negative predictive values for the presence of functional improvement after revascularization (Table I). Thus, baseline resting sestamibi SPECT results were worse than those obtained using LDD echocardiography. Agreement between LDD echocardiography and SPECT at rest was 63% (Figure 1).

		LDD - SPECT							
		+	-						
Resting SPECT	+	12	1	13	Resting SPECT	+	2	2	4
	-	6	1	7		-	0	8	8
		18	2	20			2	10	12

FIGURE 4. Agreement between baseline SPECT at rest and LDD SPECT in territories with (left panel) and without (right panel) functional recovery.

		LDD - SPECT							
		+	-						
LDD echo	+	14	2	16	LDD echo	+	2	1	3
	-	4	0	4		-	0	9	9
		18	2	20			2	10	12

FIGURE 5. Agreement between LDD SPECT and LDD echocardiography in territories with (left panel) and without (right panel) functional recovery.

mid-ventricular vertical and horizontal long-axis slices (2 segments each), for a total of 16 segments. The same segment model and the same segment attribution to the pertinent coronary territory used for echocardiography were applied to the SPECT images.¹⁵ Segment tracer uptake was graded by 2 experienced observers who were blinded to the data, using a 5-point scoring scheme: 0 = normal, 1 = mildly reduced, 2 = moderately reduced, 3 = severely reduced, and 4 = absent uptake.¹⁹ Discrepancies were resolved by consensus. Dysfunctional coronary terri-

LDD SESTAMIBI SPECT: Figures 2 and 3 show 2 examples of resting and LDD perfusion images in our patient population. After LDD infusion, 47 asynergic segments with baseline score of ≥ 1 exhibited improvement in sestamibi uptake; of these segments, 29 had severely reduced or absent tracer uptake in baseline sestamibi SPECT at rest. Therefore, the presence of normal or mild to moderate sestamibi uptake in LDD SPECT correctly identified 18 of 20 territories with functional recovery (sensitivity 90%) and its absence in 10 of 12 territories with unchanged dysfunction (specificity 83%). The related positive predictive value was 90% and the negative predictive value 83%, with an overall accuracy for prediction of functional recovery of 87%, which was significantly higher ($p < 0.05$) than that achieved by SPECT at rest (Table 1). Agreement between resting and LDD SPECT was 72% (Figure 4). No significant differences between LDD SPECT and LDD echocardiography were found in sensitivity, specificity, predictive values, and accuracy. Agreement between LDD echocardiography and LDD SPECT was 78% (Figure 5). Both LDD echocardiography and LDD SPECT were positive in 16 regions; of these, 14 improved function after revascularization (88%). Similarly, both techniques were negative in 9 regions, and none of these had improved function. Four territories showed viability in LDD SPECT but no contractile reserve in LDD echocardiography, and all of these improved at follow-up. In contrast, 2 of 3 territories with severely reduced sestamibi uptake in LDD SPECT but preserved contractile reserve in LDD echocardiography improved function at follow-up (Figure 5).

DISCUSSION

LDD echocardiography and myocardial viability: Viable myocardium may functionally improve in response to inotropic stimulation, and contractile reserve elicited by LDD is a predictor of functional recovery in patients with chronic coronary artery disease. In our study, positive and negative predictive values of LDD echocardiography were 84% and 69%, respectively, confirming the accuracy of this method in predicting functional recovery after revascularization reported by previous studies.²²

Sestamibi SPECT and myocardial viability: Myocardial uptake and retention of sestamibi is dependent on cellular membrane integrity and mitochondrial function,^{23,24} and hence, reflect cellular viability. The value of sestamibi imaging for the detection of viable myocardium, however, remains controversial. In our study, the predictive values for reversible dysfunction derived from baseline sestamibi SPECT were lower than that observed using LDD echocardiography, which agrees with the results of previous studies comparing sestamibi with thallium-201 or positron emission tomography.^{3,4} Other studies, however, demonstrate that delayed imaging,⁸ quantitative SPECT,⁹ and nitrate-enhanced imaging^{10,11} improve the value of sestamibi scintigraphy for detecting myocardial viability.

LDD sestamibi SPECT and myocardial viability: Recently, Barilla et al¹² demonstrated that sestamibi injection during LDD infusion increases uptake in areas with recent infarction, and Roelants et al¹³ suggested that this might improve the detection of viable myocardium. Correlated with these observations, we observed increased sestamibi uptake in LDD SPECT in approximately 1/3 of segments with baseline defects, and most of these segments were found in territories with functional recovery. Our results demonstrate that sestamibi injection during LDD improves tracer accuracy in the detection of myocardial viability. Compared with baseline SPECT, LDD sestamibi imaging achieves higher sensitivity and specificity with a significant increase in accuracy for the prediction of reversible dysfunction. Furthermore, LDD SPECT predicts recovery of contractile function after revascularization with accuracy comparable to that of LDD echocardiography. Interestingly, in previous comparisons between thallium-201 scintigraphy and LDD echocardiography, the sensitivity for the detection of viable hibernating myocardium of perfusion imaging appeared slightly higher than that of echocardiography, but specificity was found to be significantly lower.²⁵

Study limitations: The first limitation is the small number of patients. This prevents comparison of the different methods for the prediction of improvement in global ventricular function, which is more important from a clinical viewpoint than regional wall motion. Follow-up was performed early after revascularization, whereas recent studies show that ventricular function can still improve several months later.²⁶ Silent restenosis or graft occlusion could not be completely ruled out, because angiography was not performed at follow-up. However, both problems should not affect the direct comparison of the methods. Ischemia during LDD could reduce sestamibi uptake in viable segments, and indeed in our series we observed uptake decrease in LDD images in 1 territory with functional recovery. This is a potential limitation of LDD SPECT and also precludes the use of a high-dose dobutamine protocol, which conversely improves the reliability of echocardiography.²⁷ Data were analyzed on a coronary territory instead of a segment basis; this has been done in other studies,^{10,16,17} and is reasonable in terms of decision making because revascularization usually involves an entire territory. Moreover, this approach reduces the risk of misalignment between echocardiography and SPECT. A final major limitation is the lack of quantification of sestamibi uptake, although visual scoring has been adopted for other clinical studies designed to assess viability with perfusion imaging.^{5,20} It is not conceivable that quantitative analysis would have affected baseline accuracy differently from LDD SPECT accuracy. Reasonably, the performance of SPECT compared with echocardiography should be expected to improve using quantitative imaging.

1. Dakik HA, Howell JF, Lawrie GM, Espada R, Weilbaecher DG, He Z-K, Mahmarian JJ, Verani MS. Assessment of myocardial viability with 99m-Tc-sestamibi tomography before coronary bypass graft surgery. Correlation with histopathology and postoperative improvement in cardiac function. *Circulation* 1997;96:2892-2898.
2. Maes A, Borgers M, Flameng W, Nuyts JL, Van de Werf F, Ausma JJ, Sergeant P, Montelms LA. Assessment of myocardial viability in chronic coronary artery disease using technetium-99m sestamibi SPECT. Correlation with histologic and positron emission tomographic studies and functional follow-up. *J Am Coll Cardiol* 1997;29:62-68.
3. Cuocolo A, Pace L, Ricciardelli B, Chiarello M, Trimarco B, Salvatore M. Identification of viable myocardium in patients with chronic coronary artery disease: comparison of thallium-201 scintigraphy with reinjection and technetium-99m-methoxyisobutyl isonitrile. *J Nucl Med* 1992;33:505-511.
4. Soufer R, Dey HM, Ng CK, Zaret BL. Comparison of sestamibi single photon emission computed tomography with positron emission tomography for estimating left ventricular myocardial viability. *Am J Cardiol* 1995;75:1214-1219.
5. Senior R, Raval U, Lahiri A. Technetium 99m-labeled sestamibi imaging reliably identifies retained contractile reserve in dyssynergic myocardial segments. *J Nucl Cardiol* 1995;2:296-302.
6. Claeys MJ, Rademakers FE, Vrints CJ, Krug B, Bosmans JM, Conraads V, Bossaert LL, Snoeck JP, Blockx PP. Comparative study of rest technetium-99m sestamibi SPET and low-dose dobutamine stress echocardiography for the early assessment of myocardial viability after acute myocardial infarction: importance of the severity of the infarct-related stenosis. *Eur J Nucl Med* 1996;23:748-755.
7. Hamby AS, Vaerenberg MM, Dobbeleir AA, Van den Heuvel PA, Franken PR. Abnormal BMIPP uptake in chronically dysfunctional myocardial segments: correlation with contractile response to low-dose dobutamine. *J Nucl Med* 1998;39:1845-1850.
8. Dilsizian V, Arrighi JA, Diodati JG, Quyyumi AA, Alavi K, Bacharach SL, Marin-Neto JA, Katsiyannis PT, Bonow RO. Myocardial viability in patients with chronic coronary artery disease. Comparison of 99mTc-sestamibi with thallium reinjection and 18F-fluorodeoxyglucose. *Circulation* 1994;89:578-587.
9. Udelson JE, Coleman PS, Metherall J, Pandian NG, Gomez AR, Griffith JL, Shea NL, Oates E, Konstam MA. Predicting recovery of severe regional ventricular dysfunction. Comparison of resting scintigraphy with 201-Tl and 99m Tc-sestamibi. *Circulation* 1994;89:2552-2561.
10. Bisi G, Sciarra R, Santoro GM, Fazzini PF. Rest technetium-99m sestamibi tomography in combination with short-term administration of nitrates: feasibility and reliability for prediction of postrevascularization outcome of asynergic territories. *J Am Coll Cardiol* 1994;24:1282-1289.
11. Sciarra R, Bisi G, Santoro GM, Zeraushek F, Sestini S, Pedenovi P, Pappagallo R, Fazzini PF. Comparison of baseline-nitrate technetium-99m sestamibi with rest-redistribution thallium-201 tomography in detecting viable hibernating myocardium and predicting postrevascularization recovery. *J Am Coll Cardiol* 1997;30:384-391.
12. Barillà F, De Vincentis G, Mangieri E, Ciavolella M, Panitteri G, Scopinaro F, Critelli G, Campa P. Recovery of contractility of viable myocardium during inotropic stimulation is not dependent on an increase of myocardial blood flow in the absence of collateral filling. *J Am Coll Cardiol* 1999;33:697-704.
13. Roelants V, Pasquet A, Robert A, D'Hondt AM, Vanoverschelde JL, Melin J. Comparison of rest and low-dose dobutamine sestamibi perfusion SPECT for delineation of reversible left ventricular ischemic dysfunction (abstr). *Circulation* 1996;94:I-239.
14. Mairesse GH, Marwick TH, Vanoverschelde JL, Baudhuin T, Wijns W, Melin JA, Detry JR. How accurate is dobutamine stress electrocardiography for detection of coronary artery disease? Comparison with two-dimensional echocardiography and technetium-99m methoxyisobutyl isonitrile (Mibi) perfusion scintigraphy. *J Am Coll Cardiol* 1994;24:920-927.
15. Segar D, Brown SE, Sawada SG, Ryan T, Feigenbaum H. Dobutamine stress echocardiography: correlation with coronary lesion severity as determined by quantitative angiography. *J Am Coll Cardiol* 1992;19:1197-2202.
16. Smart SC, Sawada S, Ryan T, Segar D, Atherton L, Berkovitz K, Bourdillon PDV, Feigenbaum H. Low-dose dobutamine echocardiography detects reversible dysfunction after thrombolytic therapy of acute myocardial infarction. *Circulation* 1993;88:405-415.
17. Bolognese L, Antoniucci D, Rovai D, Buonamici PG, Cerisano G, Santoro GM, Marini C, L'Abbate A, Fazzini PF. Myocardial contrast echocardiography versus dobutamine echocardiography for predicting functional recovery after myocardial infarction treated with primary coronary angioplasty. *J Am Coll Cardiol* 1996;28:1677-1683.
18. Meluzin J, Cerny J, Frelich M, Stetka F, Spinarova L, Popelova J, Stipal R. Prognostic value of the amount of dysfunctional but viable myocardium in revascularized patients with coronary artery disease and left ventricular dysfunction. *J Am Coll Cardiol* 1998;32:912-920.
19. Hachamovitch R, Berman DS, Kiat H, Cohen I, Cabico JA, Friedman J, Diamond GA. Exercise myocardial perfusion SPECT in patients without known coronary artery disease. Incremental prognostic value and use in risk stratification. *Circulation* 1996;93:905-914.
20. Panza JA, Dilsizian V, Laurienzo JM, Curiel RV, Katsiyannis PT. Relation between thallium uptake and contractile response to dobutamine. Implications regarding myocardial viability in patients with chronic coronary artery disease and left ventricular dysfunction. *Circulation* 1995;91:990-998.
21. Baumgartner H, Porenta G, Lau Y-K, Wutte M, Klaat U, Mehrabi M, Siegel RJ, Czernin J, Lauffer G, Fishbein MC, Maurer G. Assessment of myocardial viability by dobutamine echocardiography, positron emission tomography and thallium-201 SPECT. Correlation with histopathology in explanted hearts. *J Am Coll Cardiol* 1998;32:1701-1708.
22. Bax JJ, Wijns W, Cornel JH, Visser FC, Boersma E, Fioretti PM. Accuracy of currently available techniques for prediction of functional recovery after revascularization in patients with left ventricular dysfunction due to chronic coronary artery disease: comparison of pooled data. *J Am Coll Cardiol* 1997;30:1451-1460.
23. Piwnica-Worms D, Kronauge J, Chiu M. Uptake and retention of hexakis (2-methoxyisobutyl isonitrile) technetium in cultured chick myocardial cells. Mitochondrial and plasma membrane potential dependence. *Circulation* 1990;82:1826-1838.
24. Freeman I, Grunwald AM, Hoory S, Bodenheimer MM. Effect of coronary occlusion and myocardial viability on myocardial activity of technetium-99m-sestamibi. *J Nucl Med* 1991;32:292-298.
25. Cornel JH, Bax JJ, Elhendy A, Maat AP, Kimman GP, Geleijnse ML, Rambaldi R, Boersma E, Fioretti PM. Biphasic response to dobutamine predicts improvement of global left ventricular function after surgical revascularization in patients with stable coronary artery disease. Implications of time course of recovery on diagnostic accuracy. *J Am Coll Cardiol* 1998;31:1002-1010.
26. Afridi I, Grayburn PA, Panza JA, Oh JK, Zoghbi WA, Marwick TH. Myocardial viability during dobutamine echocardiography predicts survival in patients with coronary artery disease and severe left ventricular systolic dysfunction. *J Am Coll Cardiol* 1998;32:921-926.
27. Afridi I, Kleiman NS, Raizner AE, Zoghbi WA. Dobutamine echocardiography in myocardial hibernation. Optimal dose and accuracy in predicting recovery of ventricular function after coronary angioplasty. *Circulation* 1995;91:663-670.