



UNIVERSITÀ
DEGLI STUDI
FIRENZE

FLORE

Repository istituzionale dell'Università degli Studi di Firenze

Prediction of functional recovery in patients with chronic coronary artery disease and left ventricular dysfunction combining the

Questa è la Versione finale referata (Post print/Accepted manuscript) della seguente pubblicazione:

Original Citation:

Prediction of functional recovery in patients with chronic coronary artery disease and left ventricular dysfunction combining the evaluation of myocardial perfusion and contractile reserve using nitrate-enhanced technetium-99m Sestamibi gated single-photon emission computed tomography and dobutamine stress / LEONCINI M; MARCUCCI G; R. SCIAGRA'; FRASCARELLI F; SIMONETTI I; BINI L; MAIOLI M; MENNUTI A; DABIZZI RP.. - In: THE AMERICAN JOURNAL OF CARDIOLOGY. - ISSN 0002-9149. - STAMPA.

Availability:

This version is available at: 2158/222312 since:

Publisher:

EXCERPTA MEDICA INC, 650 AVENUE OF THE AMERICAS, NEW YORK, USA, NY, 10011 editore precedente:

Terms of use:

Open Access

La pubblicazione è resa disponibile sotto le norme e i termini della licenza di deposito, secondo quanto stabilito dalla Policy per l'accesso aperto dell'Università degli Studi di Firenze (<https://www.sba.unifi.it/upload/policy-oa-2016-1.pdf>)

Publisher copyright claim:

(Article begins on next page)

Prediction of Functional Recovery in Patients With Chronic Coronary Artery Disease and Left Ventricular Dysfunction Combining the Evaluation of Myocardial Perfusion and of Contractile Reserve Using Nitrate-Enhanced Technetium-99m Sestamibi Gated Single-Photon Emission Computed Tomography and Dobutamine Stress

Mario Leoncini, MD, Gabriella Marcucci, MD, Roberto Sciagrà, MD, Fabio Frascarelli, MD, Ignazio Simonetti, MD, Luciano Bini, MD, Mauro Maioli, MD, Alberto Mennuti, MD, and Roberto P. Dabizzi, MD

This study aimed to assess whether contractile reserve evaluation using dobutamine gated single-photon emission computed tomography (SPECT) improves the capability of quantitative perfusion analysis to predict functional recovery of viable hibernating myocardium. Resting and dobutamine nitrate-enhanced technetium-99m sestamibi (sestamibi) gated SPECT studies were performed in patients with coronary artery disease who had left ventricular dysfunction. Tracer activity was quantified, and wall motion and thickening visually scored. Reversible dysfunction was identified with gated SPECT repeated after coronary revascularization. Using the best activity threshold, perfusion quantification achieved 85% sensitivity and 55% specificity. Contractile reserve detection was significantly less sensitive (64%, $p < 0.0005$), but more specific (88%, $p < 0.00001$) than perfusion quantification. However, in the subgroup of hypokinetic segments, the sensitivity of contractile reserve assessment was just slightly lower than perfusion

quantification (72% vs 91%, $p = \text{NS}$), whereas specificity was significantly higher (94% vs 23%, $p < 0.00001$). Conversely, in the adyskinetic segments, perfusion quantification was significantly more sensitive than contractile reserve (82% vs 59%, $p < 0.005$), but similarly specific (76% vs 85%, $p = \text{NS}$). Therefore, the identification of reversible dysfunction based on perfusion quantification in adyskinetic segments and on contractile reserve detection in hypokinetic segments was significantly more specific (83% vs 55%, $p < 0.00001$) than standard quantitative perfusion SPECT, without major loss in sensitivity (78% vs 85%, $p = \text{NS}$). In conclusion, contractile reserve evaluation using dobutamine gated SPECT enhances the reliability of nitrate-enhanced sestamibi SPECT when used to predict reversible dysfunction in hypokinetic segments, whereas perfusion quantification remains superior in adyskinetic segments. ©2001 by Excerpta Medica, Inc.

(Am J Cardiol 2001;87:1346–1350)

Quantitative technetium-99m sestamibi (sestamibi) single-photon emission computed tomography (SPECT) is a reliable method for the detection of myocardial viability, particularly when nitrate-enhanced imaging is used.^{1–6} Perfusion imaging with technetium-labeled agents, however, is increasingly acquired using the gated SPECT modality, which offers advantages in terms of artifact detection and ad-

ditional functional data.^{7,8} Great interest has been given to the implications of gated SPECT for viability detection, but no definitive results have been reached.^{9–12} An interesting proposal has been to associate gated SPECT with low-dose dobutamine infusion to assess the contractile reserve of asynergic segments.¹³ The feasibility of this procedure has been demonstrated,^{14,15} but its predictive value for postrevascularization outcome and its optimal combination with quantitative perfusion imaging are still unclear. In this study, we used dobutamine gated SPECT to evaluate the contractile reserve of asynergic segments with the aim to verify the contribution of functional data to perfusion quantification for the prediction of postrevascularization recovery.

From the Division of Cardiology and Nuclear Medicine Unit, Misericordia e Dolce Hospital, Prato; and Nuclear Medicine Unit, Department of Clinical Physiopathology, University of Florence, Florence, Italy. Manuscript received November 17, 2000; revised manuscript received and accepted January 10, 2001.

Address for reprints: Mario Leoncini, MD, Via del Cittadino 24, 59100, Prato, Italy. E-mail: r.sciagra@dfc.unifi.it.

METHODS

Patient population: We studied 33 consecutive patients (31 men, mean age 65 ± 9 years) who fulfilled the following inclusion criteria: prior myocardial infarction (anterior in 23, inferior in 10 cases), impaired left ventricular function (mean left ventricular ejection fraction $33.3 \pm 9.6\%$ (range 15% to 49%; 17 patients $<35\%$), and scheduled to undergo revascularization. Exclusion criteria were: recent (<1 month) myocardial infarction or unstable angina, heart disease other than coronary artery disease, atrial fibrillation, or history of sustained ventricular tachycardia. There were 11 patients with 1-vessel, 12 patients with 2-vessel, and 10 patients with 3-vessel coronary artery disease.

Study protocol: All patients underwent in a single-session nitrate-enhanced resting and dobutamine sestamibi gated SPECT. To assess functional outcome, baseline resting sestamibi gated SPECT was repeated after revascularization: ≥ 3 months for bypass grafting (13 patients) and ≥ 1 month for coronary angioplasty (20 patients). Nitrates and β -adrenergic blocking agents were discontinued 48 hours before the tests. All patients gave informed consent to participate in the study, which was approved by the Ethics Committee of our institution.

Sestamibi SPECT: The modality of nitrate infusion has been previously described.⁴ After 1 hour, baseline resting gated SPECT was acquired. Immediately thereafter, dobutamine infusion ($5 \mu\text{g}/\text{kg}$ body weight/min) was started, and increased after 5 minutes to $10 \mu\text{g}/\text{kg}/\text{min}$. Early interruption criteria were hypotension, angina, or significant ventricular arrhythmia. Gated SPECT acquisition was started after 3 minutes of the $10\text{-}\mu\text{g}$ dose that was maintained until acquisition was completed.¹⁶ For the postrevascularization study, the same dose of sestamibi ($1,111 \text{ MBq}$, 30 mCi) was injected, followed 1 hour later by SPECT acquisition. A dual-head gamma camera (ADAC Vertex, ADAC Laboratories, Milpitas, California) with high-resolution collimators and a 15% window centered on the 140-keV photopeak of technetium-99m was used. SPECT was performed with 32 projections over a 180° elliptical orbit at 45 s/projection, 64×64 matrixes, 8-frames/cardiac cycle. The studies were reconstructed using filtered back-projection without attenuation or scatter correction. The reconstructed slices were realigned along the heart axis and short-, horizontal long-, and vertical long-axis views were obtained. For tracer activity quantification, the gated SPECT images were summed, obtaining a standard perfusion study.

Data analysis: The left ventricle was divided into 16 segments and each of the segments assigned to the related coronary territory.¹⁷ For tracer activity quantification, the mean uptake of each segment was calculated, the activity of the segment with peak uptake equated to 100%, and the other segments scaled in percent of peak activity.⁶ Regional wall motion and thickening were assessed visually by consensus of 2 experienced observers, who were blinded to the data, and scored using a 4-point scale (1 = normal, 2 = hypokinesia; 3 = akinesia; 4 = dyskinesia).¹⁸ Previ-

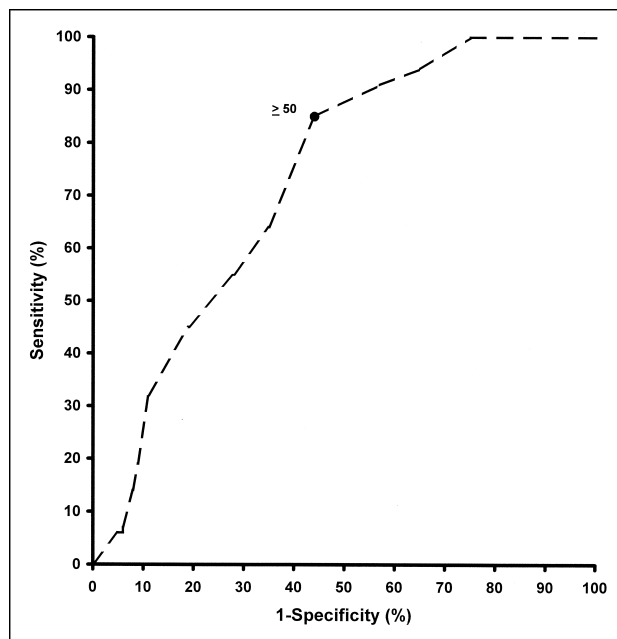


FIGURE 1. Receiver operating characteristics curve constructed using different sestamibi activity thresholds to define reversible dysfunction in asynergic segments.

ous data indicated a good reproducibility of these evaluations in our laboratory.¹⁵ Baseline dysfunctional segments (score > 1) that exhibited a decrease ≥ 1 grade in regional score during dobutamine administration were considered to have contractile reserve.¹⁹ Similarly, functional recovery was defined on the basis of decrease ≥ 1 grade in regional score at follow-up.^{19,20} However, a change from dyskinesia to akinesia was not considered to be significant.²¹

Statistical analysis: Receiver operating characteristics curve analysis was used to identify the best cut-off value of sestamibi activity for predicting functional recovery. The comparison of proportions was made using the Fisher's exact test or the chi-square test with Yates' correction, as appropriate. A p value <0.05 was considered statistically significant.

RESULTS

Baseline and follow-up gated SPECT: Fifty-one vascular territories including 356 segments were successfully revascularized. Baseline resting gated SPECT classified 86 segments as normokinetic, 107 as hypokinetic, and 163 as adyskinetic. After revascularization, 109 of 270 dysfunctional segments (43 hypokinetic) showed functional recovery, whereas 161 (64 hypokinetic) showed no functional changes.

Myocardial perfusion: According to receiver operating characteristics curve analysis, the optimal cut-off value to identify reversible dysfunction in asynergic segments was $\geq 50\%$ of peak activity (Figure 1). Using this threshold, perfusion imaging predicted functional recovery in 93 of 109 segments (85% sensitivity), and excluded it in 89 of 161 segments (55% specificity), with 67% global accuracy. In hypokinetic segments, sensitivity, specificity, and accuracy of ses-

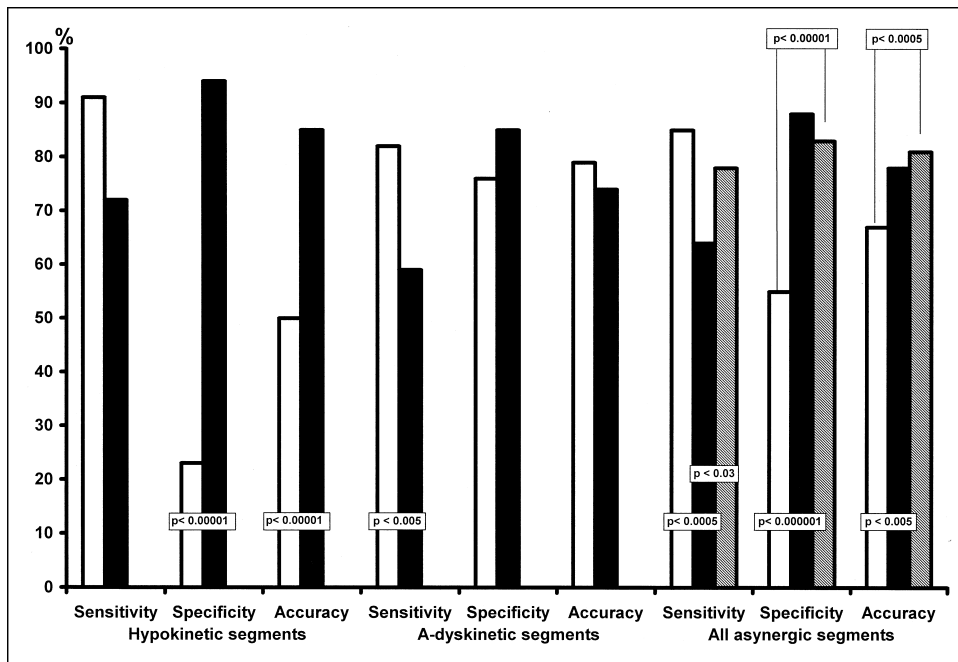


FIGURE 2. Sensitivity, specificity, and accuracy for recovery of segmental function in hypokinetic segments, adyskinetic segments, and all asynergic segments using perfusion imaging (white bars), contractile reserve (black bars), and using activity quantification in adyskinetic segments and contractile reserve detection in hypokinetic segments (hatched bars).

tamibi SPECT were 91% (39 of 43 segments), 23% (15 of 64 segments), and 50% (54 of 107 segments), respectively. In adyskinetic segments, sensitivity, specificity, and accuracy were 82% (54 of 66 segments) ($p = \text{NS}$ vs hypokinetic segments), 76% (74 of 97 segments) ($p < 0.00001$ vs hypokinetic), and 79% (128 of 163 segments) ($p < 0.00001$ vs hypokinetic), respectively (Figure 2).

Dobutamine gated SPECT: Dobutamine stimulation elicited contractile reserve in 89 dysfunctional segments (35 hypokinetic). Of these, 70 segments (31 hypokinetic) showed reversible dysfunction at follow-up (sensitivity 64%, $p < 0.0005$ vs perfusion quantification). Only 39 of 181 segments (12 hypokinetic) without response to dobutamine showed functional improvement after revascularization (specificity 88%, $p < 0.00001$ vs perfusion quantification). In hypokinetic segments, contractile reserve showed higher specificity (94% vs 23%, $p < 0.00001$) and global accuracy (85% vs 50%, $p < 0.00001$) than perfusion quantification, and similar sensitivity (72% vs 91%, $p = \text{NS}$). In adyskinetic segments, contractile reserve showed lower sensitivity (59% vs 82%, $p < 0.005$) than sestamibi activity, without significant differences in specificity (85% vs 76%, $p = \text{NS}$) or overall accuracy (74% vs 79%, $p = \text{NS}$) (Figure 2).

Combination of perfusion quantification and contractile reserve: When adyskinetic segments were considered to be viable if they had nitrate sestamibi activity $\geq 50\%$, and hypokinetic segments were considered to be viable if they had contractile reserve independently of tracer activity, the specificity (134 of 161 segments, 83%; $p < 0.00001$) and the global accuracy (219 of 270 segments, 81%; $p < 0.0005$) improved significantly compared with perfusion quantification alone, whereas sensitivity did not change significantly (85 of 109 segment, 78%), but remained higher than using

contractile reserve alone (70 of 109 segments, 64%, $p < 0.03$) (Figure 2).

DISCUSSION

For detecting viable hibernating myocardium, the role of functional imaging, mainly echocardiography, is to recognize the contractile reserve of asynergic regions under dobutamine.^{16,19,21-23} Most recently, gated SPECT has also been shown to be reliable for contractile reserve evaluation.^{14,15} Thus, the simultaneous assessment of myocardial cellular integrity using perfusion imaging and of contractile reserve using dobutamine gated SPECT has been suggested as a new approach to viability detection.¹³ In general, the demonstration of contractile reserve has a higher specificity than myocardial perfusion imaging.^{19,24,25} The latter approach is usually more sensitive, particularly in the clinically most important subgroup of akinetic segments.¹⁹ In our series, the higher specificity of contractile reserve versus perfusion quantification was confirmed. This finding was particularly conspicuous in the hypokinetic segments, where the low specificity of perfusion imaging was explained by tracer uptake within the layer of viable tissue that sustained contractility. Despite preserved tracer activity, if this tissue coexists with scarred myocardium, contractile reserve is absent and functional recovery cannot be expected. Conversely, hypokinetic segments including normal tissue and viable hibernating myocardium will show both contractile reserve during dobutamine and reversible dysfunction after revascularization. Tracer activity quantification, however, was significantly more sensitive than contractile reserve evaluation, especially in the more severely dysfunctional segments, as shown by other studies.¹⁹ Based on these observations, we used combined criteria to identify the segments with reversible dysfunction. Regional dysfunction

tion was assessed on the basis of gated SPECT evaluation at rest. If a segment was adyskinetic, it was classified according to the sestamibi activity value, using the best cut-off for viability. If a segment was hypokinetic, it was examined for the presence or absence of contractile reserve in dobutamine gated SPECT and classified accordingly as probably viable or nonviable, respectively. This approach achieved high sensitivity, specificity, and overall accuracy, and was significantly superior to perfusion imaging or contractile reserve evaluation applied separately. These results support the proposal of taking advantage of the combination of perfusion and contractile reserve data made possible by dobutamine gated SPECT.¹³ In contrast, prior studies about the use of baseline gated SPECT to improve the detection of viable hibernating myocardium have failed to demonstrate major diagnostic gains over perfusion images alone.⁹⁻¹²

The results of the present study must be evaluated cautiously because of several limitations. As in many other studies using functional recovery as the reference standard to define myocardial viability, the patient population is quite small.^{9,11,12} A limitation of gated SPECT compared with echocardiography is the impossibility to monitor changes during dobutamine infusion, and so to differentiate between lack of improvement and biphasic response, which is considered the most reliable marker of preserved viability in dobutamine echocardiography.^{26,27} Conversely, we did not perform a quantitative analysis of wall motion and thickening on gated SPECT images.^{28,29} This approach could increase the reliability and reproducibility of gated SPECT functional assessment and represents a potential advantage of this method. Finally, we did not consider the global left ventricular ejection fraction data, neither to establish the outcome of the revascularization nor to identify a possible relation between dobutamine-induced and postrevascularization changes. Recent echocardiographic data suggest a very good accuracy of the dobutamine ejection fraction to predict global functional response after the intervention.³⁰ Taking into account the good reproducibility of gated SPECT measurements,⁷ further studies are warranted to establish the predictive value of the ejection fraction response to dobutamine.

1. Udelson JE, Coleman PS, Metherall J, Pandian NG, Gomez AR, Griffith JL, Shea NL, Oates E, Konstam MA. Predicting recovery of severe regional ventricular dysfunction: comparison of resting scintigraphy with 201Tl and 99mTc-sestamibi. *Circulation* 1994;89:2552-2561.
2. Kauffman GJ, Boyne TS, Watson DD, Smith WH, Beller GA. Comparison of rest thallium-201 imaging and rest technetium-99m sestamibi imaging for assessment of myocardial viability in patients with coronary artery disease and severe left ventricular dysfunction. *J Am Coll Cardiol* 1996;27:1592-1597.
3. Maes AF, Borgers M, Flameng W, Nuyts JL, van de Werf F, Ausma JJ, Sergeant P, Mortelmans LA. Assessment of myocardial viability in chronic coronary artery disease using technetium-99m sestamibi SPECT: correlation with histologic and positron emission tomographic studies and functional follow up. *J Am Coll Cardiol* 1997;29:62-68.
4. Bisi G, Sciarra R, Santoro GM, Fazzini PF. Rest technetium-99m sestamibi tomography in combination with short-term administration of nitrates: feasibility and reliability for prediction of postrevascularization outcome of asymptomatic territories. *J Am Coll Cardiol* 1994;24:1282-1289.
5. Li ST, Liu XJ, Lu ZL, Shi RF, Zhu XD, Chen WQ, Wu QW, Liu YZ.

- Quantitative analysis of technetium 99m 2-methoxyisobutyl isonitrile single-photon emission computed tomography and isosorbide dinitrate infusion in assessment of myocardial viability before and after revascularization. *J Nucl Cardiol* 1996;3:457-463.
6. Sciarra R, Bisi G, Santoro GM, Zerausck F, Sestini S, Pedenovi P, Pappalardo R, Fazzini PF. Comparison of baseline-nitrate technetium-99m-sestamibi with rest-redistribution thallium-201 tomography in detecting viable hibernating myocardium and predicting postrevascularization recovery. *J Am Coll Cardiol* 1997;30:384-391.
 7. Mansoor MR, Heller GV. Gated SPECT imaging. *Semin Nucl Med* 1999;29:271-278.
 8. ASNC Executive Council. American Society of Nuclear Cardiology position statement on electrocardiographic gating of myocardial perfusion SPECT scintigrams. *J Nucl Cardiol* 1999;6:470-471.
 9. Gonzalez P, Massardo T, Munoz A, Jofre J, Rivera A, Yovanovich J, Maiers E, Ayala F, Humeres P, Ramirez A, Arriagada M, Zavala A. Is the addition of ECG gating to technetium-99m sestamibi SPECT of value in the assessment of myocardial viability? An evaluation based on two-dimensional echocardiography following revascularization. *Eur J Nucl Med* 1996;23:1315-1322.
 10. Levine MG, McGill CC, Ahlberg AW, White MP, Giri S, Shareef B, Waters D, Heller GV. Functional assessment with electrocardiographic gated single-photon emission computed tomography improves the ability of technetium-99m sestamibi myocardial perfusion imaging to predict myocardial viability in patients undergoing revascularization. *Am J Cardiol* 1999;83:1-5.
 11. Stollfuss JC, Haas F, Matsunari I, Neverve J, Nekolla S, Ziegler S, Schwaiger M. 99mTc-tetrofosmin SPECT for prediction of functional recovery defined by MRI in patients with severe left ventricular dysfunction: additional value of gated SPECT. *J Nucl Med* 1999;40:1824-1831.
 12. Duncan BH, Ahlberg AW, Levine MG, McGill CC, Mann A, White MP, Mather JF, Waters DD, Heller GV. Comparison of electrocardiographic-gated technetium-99m sestamibi single-photon emission computed tomographic imaging and rest-redistribution thallium-201 in the prediction of myocardial viability. *Am J Cardiol* 2000;85:680-684.
 13. Iskandrian AE, Acio E. Methodology of a novel myocardial viability protocol. *J Nucl Cardiol* 1998;5:206-209.
 14. Everaert H, Vanhove C, Franken PR. Effects of low-dose dobutamine on left ventricular function in normal subjects as assessed by gated single-photon emission tomography myocardial perfusion studies. *Eur J Nucl Med* 1999;26:1298-1303.
 15. Leoncini M, Marcucci G, Sciarra R, Frascarelli F, Traini AM, Mondanelli D, Magni M, Bini L, Bellandi F, Mennuti A, Dabizzi RP. Nitrate-enhanced gated Tc-99m sestamibi SPECT for evaluating regional wall motion at baseline and during low dose dobutamine infusion in patients with chronic coronary artery disease and left ventricular dysfunction. Comparison with two-dimensional echocardiography. *J Nucl Cardiol* 2000;7: 426-431.
 16. Baer FM, Theissen P, Schneider CA, Voth E, Sechtem U, Schicha H, Erdmann E. Dobutamine magnetic resonance imaging predicts contractile recovery of chronically dysfunctional myocardium after successful revascularization. *J Am Coll Cardiol* 1998;31:1040-1048.
 17. Segar D, Brown SE, Sawada SG, Ryan T, Feigenbaum H. Dobutamine stress echocardiography: correlation with coronary lesion severity as determined by quantitative angiography. *J Am Coll Cardiol* 1992;19:1197-1202.
 18. Chua T, Kiat H, Germano G, Maurer G, van Train K, Friedman J, Berman DS. Gated technetium-99m sestamibi for simultaneous assessment of stress myocardial perfusion, postexercise regional ventricular function and myocardial viability. Correlation with echocardiography and rest thallium-201 scintigraphy. *J Am Coll Cardiol* 1994;23:1107-1114.
 19. Perrone-Filardi P, Pace L, Prastaro M, Squame F, Betocchi S, Soricelli A, Piscione F, Indolfi C, Crisci T, Salvatore M, Chiariello M. Assessment of myocardial viability in patients with chronic coronary artery disease. Rest-4-hour-24-hour ²⁰¹Tl tomography versus dobutamine echocardiography. *Circulation* 1996;94:2712-2719.
 20. Leoncini M, Marcucci G, Sciarra R, Mondanelli D, Traini AM, Magni M, Frascarelli F, Mennuti A, Dabizzi RP. Comparison of baseline and low-dose dobutamine technetium-99m sestamibi scintigraphy with low-dose dobutamine echocardiography for predicting functional recovery after revascularization. *Am J Cardiol* 2000;86:153-157.
 21. Meluzin J, Cerný J, Frélich M, Stetka F, Spinarova L, Popelova J, Stipal R. Prognostic value of the amount of dysfunctional but viable myocardium in revascularized patients with coronary artery disease and left ventricular dysfunction. *J Am Coll Cardiol* 1998;32:912-920.
 22. Cigarroa CG, de Filippi CR, Brickner ME, Alvarez LG, Wait MA, Grayburn PA. Dobutamine stress echocardiography identifies hibernating myocardium and predicts recovery of left ventricular function after coronary revascularization. *Circulation* 1993;88:430-436.
 23. Zafir N, Vidne B, Sulkes J, Sclarovsky S. Usefulness of dobutamine radionuclide ventriculography for prediction of left ventricular function improvement after coronary bypass grafting for ischemic cardiomyopathy. *Am J Cardiol* 1999;83:691-695.
 24. Amese M, Cornel JH, Salustri A, Maat APWM, Elhendy A, Reijs AEM, Ten Cate FJ, Keane D, Balk AHMM, Roelandt JRTC, Fioretti PM. Prediction of improvement of regional left ventricular function after surgical revascularization: a comparison of low-dose dobutamine echocardiography with 201-Tl SPECT. *Circulation* 1995;91:2748-2752.
 25. Bax JJ, Wijns W, Cornel JH, Visser FC, Boersma E, Fioretti P. Accuracy of

the currently available techniques for prediction of functional recovery after revascularization in patients with left ventricular dysfunction due to chronic coronary artery disease: comparison of pooled data. *J Am Coll Cardiol* 1997;30:1451-1460.

26. Afridi I, Kleiman NS, Raizner AE, Zoghbi WA. Dobutamine echocardiography in myocardial hibernation. Optimal dose and accuracy in predicting recovery of ventricular function after coronary angioplasty. *Circulation* 1995;91:663-670.

27. Qureshi U, Nagueh SF, Afridi I, Vaduganathan P, Blaustein A, Verani MS, Winters WL Jr, Zoghbi WA. Dobutamine echocardiography and quantitative rest-redistribution ²⁰¹Tl tomography in myocardial hibernation. Relation of contractile reserve to ²⁰¹Tl uptake and comparative prediction of recovery of function. *Circulation* 1997;95:626-635.

28. Germano G, Erel J, Lewin H, Kavanagh PB, Berman DS. Automatic quantitation of regional myocardial wall motion and thickening from gated technetium-99m sestamibi myocardial perfusion single-photon emission computed tomography. *J Am Coll Cardiol* 1997;30:1360-1367.

29. Shen MY, Liu YH, Sinusas AJ, Fetterman R, Bruni W, Drozhinin OE, Zaret BL, Wackers FJ. Quantification of regional myocardial wall thickening on electrocardiogram-gated SPECT imaging. *J Nucl Cardiol* 1999;6:583-595.

30. Pasquet A, Lauer MS, Williams MJ, Secknus MA, Lytle B, Marwick TH. Prediction of global left ventricular function after bypass surgery in patients with severe left ventricular dysfunction. Impact of pre-operative myocardial function, perfusion, and metabolism. *Eur Heart J* 2000;21:125-136.