



UNIVERSITÀ  
DEGLI STUDI  
FIRENZE

## FLORE

# Repository istituzionale dell'Università degli Studi di Firenze

### **Usefulness of dobutamine Tc-99m sestamibi-gated single-photon emission computed tomography for prediction of left ventricular**

Questa è la Versione finale referata (Post print/Accepted manuscript) della seguente pubblicazione:

*Original Citation:*

Usefulness of dobutamine Tc-99m sestamibi-gated single-photon emission computed tomography for prediction of left ventricular ejection fraction outcome after coronary revascularization for ischemic cardiomyopathy / LEONCINI M; R. SCIAGRA'; MAIOLI M; BELLANDI F; MARCUCCI G; SESTINI S; CHIOCCHINI S; DABIZZI RP.. - In: THE AMERICAN JOURNAL OF CARDIOLOGY. - ISSN 0002-9149. - STAMPA. - 89:(2002), pp. 817-821.

*Availability:*

This version is available at: 2158/222314 since:

*Publisher:*

EXCERPTA MEDICA INC, 650 AVENUE OF THE AMERICAS, NEW YORK, USA, NY, 10011 editore precedente:

*Terms of use:*

Open Access

La pubblicazione è resa disponibile sotto le norme e i termini della licenza di deposito, secondo quanto stabilito dalla Policy per l'accesso aperto dell'Università degli Studi di Firenze (<https://www.sba.unifi.it/upload/policy-oa-2016-1.pdf>)

*Publisher copyright claim:*

(Article begins on next page)

# Usefulness of **Dobutamine Tc-99m Sestamibi-Gated Single-Photon Emission Computed Tomography** for Prediction of **Left Ventricular Ejection Fraction Outcome After Coronary Revascularization for Ischemic Cardiomyopathy**

Mario Leoncini, MD, Roberto Sciagrà, MD, Mauro Maioli, MD, Francesco Bellandi, MD, Gabriella Marcucci, MD, Stelvio Sestini, MD, Silvia Chiocchini, MD, and Roberto P. Dabizzi, MD

Gated single-photon emission computed tomography (SPECT) imaging allows analysis of myocardial perfusion and assessment of baseline global and regional left ventricular (LV) function and their changes during low-dose dobutamine infusion. The study examined whether the changes in LV ejection fraction induced by dobutamine and evaluated using technetium-99m sestamibi-gated SPECT predict the evolution of ejection fraction after revascularization in patients with ischemic cardiomyopathy. Thirty-seven patients underwent resting and dobutamine nitrate-enhanced sestamibi-gated SPECT before revascularization and baseline-resting sestamibi-gated SPECT after intervention to assess global functional changes. A postrevascularization improvement in ejection fraction  $\geq 5$  U was defined as significant. At follow-up, ejection fraction increased significantly in 19

patients. According to receiver-operating characteristic curve analysis, an increase in ejection fraction  $\geq 5$  U during dobutamine was the optimal cutoff value for predicting a significant postrevascularization improvement, with 79% sensitivity, 78% specificity, and 78% accuracy. A significant correlation was found between dobutamine and postrevascularization ejection fraction ( $r = 0.85$ ;  $p < 0.0001$ ). The increase in ejection fraction during dobutamine is a good predictor of an improvement in ejection fraction after revascularization. This represents another important diagnostic contribution obtained using gated SPECT imaging for the assessment of myocardial viability in patients with ischemic cardiomyopathy. ©2002 by Excerpta Medica, Inc.

(Am J Cardiol 2002;89:817–821)

**T**he acquisition of perfusion images using gated single-photon emission computed tomography (SPECT) allows the assessment of regional and global left ventricular (LV) function.<sup>1</sup> These additional data are useful in detecting myocardial viability.<sup>2–4</sup> Moreover, the acquisition of gated SPECT images during low-dose dobutamine infusion permits assessment of the regional contractile reserve of asynergic segments.<sup>5–8</sup> On the other hand, using gated SPECT, LV volumes and ejection fraction can be estimated in a reliable and reproducible way.<sup>1</sup> Thus, this study examines whether the changes in LV ejection fraction during dobutamine stimulation, evaluated using technetium-99m sestamibi-gated SPECT, predict changes in ejection fraction after revascularization in patients with ischemic cardiomyopathy.

From the Division of Cardiology and Nuclear Medicine Unit, Misi-cordia e Dolce Hospital, Prato, Italy; and Nuclear Medicine Unit, Department of Clinical Physiopathology, University of Florence, Florence, Italy. Manuscript received September 5, 2001; revised manuscript received and accepted December 14, 2001.

Address for reprints: Mario Leoncini, MD, Via del Cittadino 24, 59100, Prato, Italy. E-mail: r.sciagra@dfc.unifi.it.

## METHODS

**Patient group:** We prospectively evaluated 63 consecutive patients (57 men, mean age  $65 \pm 9$ ) with coronary artery disease and impaired LV function (mean LV ejection fraction  $32 \pm 9\%$ , range 9% to 49%) referred to our laboratory for viability assessment using dobutamine nitrate-enhanced gated sestamibi SPECT. Patients with recent ( $< 1$  month) myocardial infarction or unstable angina, heart disease other than coronary artery disease, atrial fibrillation, or history of sustained ventricular tachycardia were excluded. Of this group, 37 patients (33 men, mean age  $63 \pm 9$ ) who underwent complete myocardial revascularization (14 with coronary artery bypass grafting and 23 with coronary angioplasty) within 1 month of the scintigraphic analysis were included in this study. The decision for revascularization was based on the independent judgment of the referring physician. All patients but 2 had a history of previous myocardial infarction.

**Study protocol:** All patients underwent in a single session resting and dobutamine nitrate-enhanced sestamibi-gated SPECT. Baseline resting sestamibi-gated

SPECT was repeated after revascularization ( $\geq 3$  months for bypass grafting and 1 month for coronary angioplasty) to assess global functional outcome and myocardial perfusion. Studies were performed after overnight fasting. Nitrates and  $\beta$ -adrenergic blocking agents were withdrawn 48 hours before the tests. All patients gave informed consent to participate in the study, which was approved by the ethics committee of our institution.

**Sestamibi-gated SPECT:** The method of nitrate-enhanced sestamibi imaging has been described.<sup>9,10</sup> One hour after sestamibi (1,111 MBq, 30 mCi) injection, baseline resting gated SPECT was performed. Immediately thereafter, the dobutamine study was performed. Infusion was started at a dose of 5  $\mu\text{g/kg}$  body weight/min and increased after 5 minutes to 10  $\mu\text{g/kg/min}$ . Criteria for early interruption included hypotension, angina, or significant ventricular arrhythmia. Gated SPECT acquisition was started after 3 minutes of the 10- $\mu\text{g}$  dose, which was maintained until acquisition was completed. For the postrevascularization study, the same dose of sestamibi was injected at rest, followed 1 hour later by SPECT acquisition. A dual-head gamma camera (ADAC Vertex, Milpitas, California) equipped with high-resolution collimators and with a 15% window centered on the 140-keV photopeak of technetium-99m was used for image collection. SPECT was performed in step-and-shoot mode, with 32 projections over a 180° elliptical orbit, matrix size 64  $\times$  64, 45 seconds/projection, 8 frames/cardiac cycle. The studies were reconstructed using filtered back-projection without attenuation or scatter correction and realigned along the heart axis. For perfusion and functional analysis, the left ventricle was divided into 16 segments and 3 coronary territories were considered.<sup>7,8</sup> Tracer uptake was quantified with an automatic program that calculated the mean uptake of each segment, identified the segment with peak uptake, set it to 100% activity, and scaled the other segments as a percentage of peak activity.<sup>10</sup> Regional function was assessed visually by consensus of 2 experienced observers and scored using a 4-point scale (1 = normal; 2 = hypokinesia; 3 = akinesia; 4 = dyskinesia).<sup>7,8,11</sup> The reproducibility of regional functional scoring in our laboratory has been reported.<sup>7</sup> The assessment of viability was restricted to the revascularized segments with abnormal function at rest (score 2 to 4). Two criteria for detecting viability were considered: nitrate-sestamibi activity  $\geq 50\%$  in perfusion study,<sup>12</sup> and contractile reserve on dobutamine-gated SPECT study (defined by a decrease of  $\geq 1$  grade in regional wall motion score during dobutamine administration).<sup>7,8</sup> Data processing and calculation of LV end-diastolic and end-systolic volumes and LV ejection fraction were performed by an automated and validated method.<sup>13</sup> Significant improvement in global LV ejection fraction after revascularization was defined as an increase of  $\geq 5$  ejection fraction units in the follow-up control compared with the baseline value.<sup>14,15</sup>

**Statistical analysis:** Results are expressed as mean  $\pm$  SD. The comparison of variables within and be-

tween groups was performed with the Student's *t* test for paired or independent samples as appropriate. The comparison of proportions was made using the Fisher's exact test. The correlation between LV volumes and LV ejection fraction during dobutamine and after revascularization was calculated using Pearson's correlation coefficient. The sensitivity and the specificity of dobutamine sestamibi-gated SPECT to predict an increase in LV ejection fraction after revascularization were calculated using receiver-operating characteristics curve analysis. A *p* value  $< 0.05$  was considered statistically significant.

## RESULTS

**Gated SPECT after revascularization versus baseline gated SPECT:** On follow-up gated SPECT, none of the patients had worsening of perfusion in the coronary territories submitted to revascularization. In the whole study cohort, mean LV ejection fraction improved from  $34 \pm 10\%$  before to  $39 \pm 11\%$  after revascularization ( $p < 0.001$ ). According to the changes in ejection fraction, patients were divided into 2 groups: group A (19 patients) had improvement in LV ejection fraction  $\geq 5$  U after revascularization; group B (18 patients) did not have an increase in LV ejection fraction  $\geq 5$  U after revascularization. No significant differences in the 2 groups were observed regarding demographic, clinical, and instrumental variables (Table 1). Compared with baseline values, group A had a reduction in end-diastolic ( $p < 0.05$ ) and end-systolic ( $p < 0.002$ ) volumes so that after revascularization these values were significantly lower than those observed in group B (Table 1). The mean number of viable asynergic segments was higher in group A than in group B (Table 2). With use of a threshold of  $> 4$  viable segments to identify patients with LV ejection fraction increase  $\geq 5$  U,<sup>15</sup> sestamibi activity achieved 89% sensitivity, 67% specificity, and 78% accuracy.

**Dobutamine-gated SPECT:** During dobutamine there was a marked variation (from  $-3$  to  $+19$  ejection fraction units) of the LV ejection fraction with respect to baseline values. Mean dobutamine ejection fraction was  $40 \pm 12\%$  in group A ( $p < 0.001$  vs baseline) and  $35 \pm 13\%$  in group B ( $p < 0.05$  vs baseline). According to receiver-operating characteristics curve analysis, the increase in LV ejection fraction  $\geq 5$  U during dobutamine was the optimal cutoff value for predicting a significant postrevascularization increase. An improvement in ejection fraction  $\geq 5$  U during dobutamine was observed in 15 group A patients and in 4 group B patients ( $p < 0.005$ ). The dobutamine increase in LV ejection fraction  $\geq 5$  U predicted a significant increase in ejection fraction after revascularization, with a sensitivity, specificity, and overall accuracy of 79%, 78%, and 78%, respectively. The individual changes in LV ejection fraction at baseline, during dobutamine, and after revascularization are seen in Figure 1. A significant correlation was found between dobutamine LV ejection fraction and postrevascularization ejection fraction ( $r = 0.85$ ;  $p < 0.0001$ ) (Figure 2). Moreover, there was a significant correlation be-

<b>TABLE 1</b> Comparison of Clinical, Angiographic, and Scintigraphic Characteristics Between Patients With (group A) and Without (group B) Improvement of $\geq 5$ U in LV Ejection Fraction After Revascularization			
Variable	Group A (n = 19)	Group B (n = 18)	p Value
Mean age (yrs)	64 $\pm$ 9	63 $\pm$ 10	
Previous myocardial infarction			
Anterior	12	14	
Inferior	5	4	
No. of narrowed coronary arteries			
1	7	9	
2–3	12	9	
Mode of revascularization			
Coronary angioplasty	10	13	
Coronary bypass	9	5	
Ejection fraction (%)			
Baseline	34 $\pm$ 9	33 $\pm$ 12	
Postrevascularization	44 $\pm$ 8*	32 $\pm$ 11	<0.001
End-diastolic volume (ml)			
Baseline	168 $\pm$ 69	201 $\pm$ 66	
Postrevascularization	149 $\pm$ 52†	195 $\pm$ 62	0.01
End-systolic volume (ml)			
Baseline	116 $\pm$ 68	141 $\pm$ 68	
Postrevascularization	86 $\pm$ 45‡	135 $\pm$ 99	0.01

\*p < 0.00001 versus baseline; †p = 0.03 versus baseline; ‡p = 0.001 versus baseline.

<b>TABLE 2</b> Comparison of Revascularized Asynergic Segments Classified as Viable According to Sestamibi Activity and Contractile Reserve in Patients With (group A) Versus Without (group B) Improvement of $\geq 5$ U in LV Ejection Fraction After Revascularization		
	Group A	Group B
Sestamibi activity $\geq 50\%$		
All asynergic segments	7 $\pm$ 2.9	4 $\pm$ 3*
Adyskinetic segments	3 $\pm$ 1.7	2 $\pm$ 1.6†
Contractile reserve		
All asynergic segments	3.9 $\pm$ 2.6	2 $\pm$ 1.7†

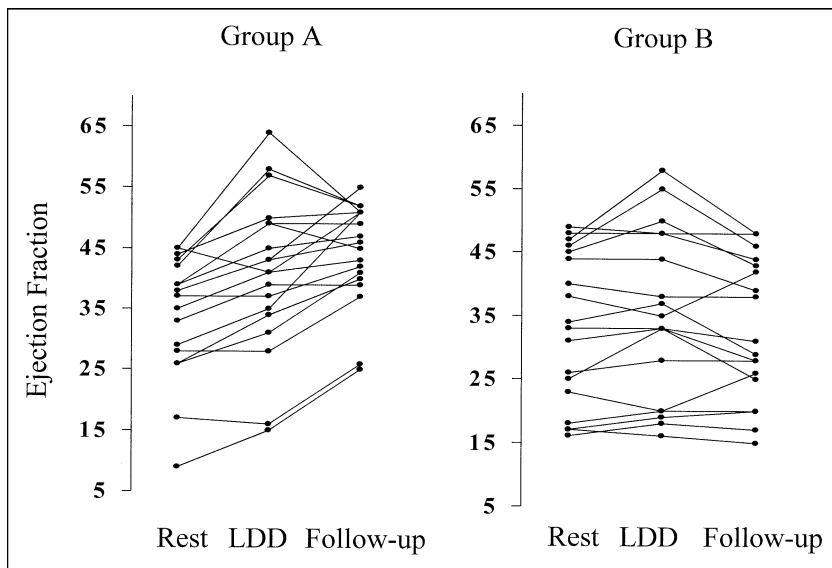
\*p = 0.002; †p < 0.005.

tween dobutamine end-diastolic ( $r = 0.86$ ;  $p < 0.0001$ ) and end-systolic ( $r = 0.89$ ;  $p < 0.0001$ ) volumes and the related values after revascularization.

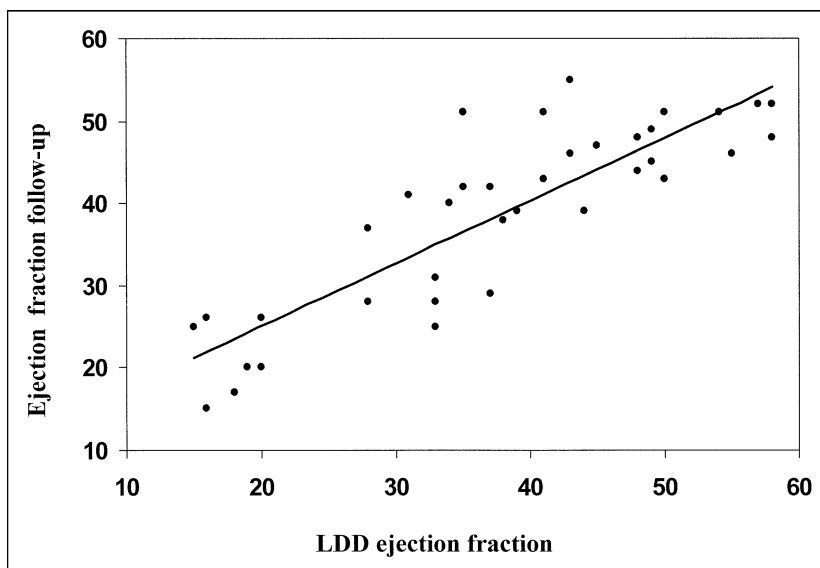
## DISCUSSION

An important advantage of gated SPECT perfusion imaging over other methods is the possibility of obtaining data about myocardial perfusion and regional and global function during the same acquisition. The simultaneous assessment of perfusion and regional function improves the accuracy of simple perfusion study for the detection of myocardial viability.<sup>2–4</sup> Gated SPECT imaging may also provide evaluation of wall motion and thickening changes during inotropic stimulation.<sup>5–8</sup> A good agreement between gated SPECT and other imaging techniques in evaluating contractile reserve elicited by dobutamine infusion was demonstrated.<sup>5,7</sup> In detecting hibernating viable myocardium, the assessment of contractile reserve adds diagnostic power to perfusion imaging, and the combination of perfusion and functional data significantly im-

proved the accuracy of sestamibi-gated SPECT for predicting regional reversible dysfunction.<sup>8</sup> However, the most important clinical goal of coronary revascularization is improvement in global LV function.<sup>16</sup> Global functional improvement after revascularization was correlated with the extent of viable myocardium, defined by the number of the asynergic segments with preserved cellular membrane integrity,<sup>17</sup> maintained metabolism,<sup>18</sup> or contractile reserve.<sup>17,18</sup> Also, according to our results, the group of patients with improved LV ejection fraction of  $\geq 5$  U after revascularization had significantly more revascularized viable asynergic segments with preserved cellular membrane integrity or contractile reserve than patients without significant LV ejection fraction improvement. Gated SPECT also allows automated calculation of LV volumes and ejection fraction, which can be estimated in a reliable and reproducible way.<sup>1</sup> The results of this study suggest that dobutamine ejection fraction changes predict global functional response after revascularization. A global increase of at least 5 U in LV ejection fraction in response to dobutamine is a good predictor of a significant increase in LV ejection fraction after intervention. The relation between dobutamine-induced and postrevascularization ejection fraction changes confirms and expands the results of previous studies performed using more established imaging techniques.<sup>18–20</sup> Zafrir et al<sup>20</sup> found that dobutamine radionuclide ventriculography had a sensitivity of 67% and specificity of 93% for predicting improvement in global LV function after revascularization. In the study of Sanchis et al,<sup>19</sup> dobutamine contrast ventriculography predicted an increase in LV ejection fraction after revascularization with sensitivity and specificity of 80% and 83%, respectively. Using dobutamine echocardiography, Pasquet et al<sup>18</sup> obtained a sensitivity of 93% and specificity of 90% for the prediction of ejection fraction outcome. The increase in LV ejection fraction during dobutamine echocardiography was a stronger predictor of overall improvement in postrevascularization ejection fraction than either the number of viable asynergic segments identified by maintained metabolism or preserved contractile reserve.<sup>18</sup> In our study, dobutamine LV ejection fraction showed a good diagnostic accuracy (79% sensitivity and 78% specificity) for significant global function improvement after revascularization. These results confirm that dobutamine-induced ejection fraction changes provide important diagnostic information for assessing myocardial viability in patients with ischemic cardiomyopathy. This information can be easily achieved using gated SPECT together with quantifi-



**FIGURE 1.** Individual data of LV ejection fraction at rest, during dobutamine infusion, and after revascularization in groups A and B. LDD = low-dose dobutamine.



**FIGURE 2.** Correlation between LV ejection fraction during dobutamine stimulation and after revascularization. Abbreviation as in Figure 1.

cation of regional perfusion and evaluation of regional contractile reserve.

The results of the present study must be evaluated cautiously because of several limitations. A general limitation of gated SPECT is that it cannot be used in patients with atrial fibrillation or frequent ectopic beats. As in many other studies using postrevascularization global functional recovery as the reference standard to define myocardial viability, the patient group is quite small. Angiography was not performed at follow up; thus, silent restenosis or graft occlusion could not be completely ruled out, although resting perfusion was maintained or improved. However, recurrent ischemia was excluded by clinical observation and negative exercise stress testing whenever necessary.

1. Mansoor MR, Heller GV. Gated SPECT imaging. *Semin Nucl Med* 1999;29:271–278.

2. Levine MG, McGill CC, Ahlberg AW, White MP, Giri S, Shareef B, Waters D, Heller GV. Functional assessment with electrocardiographic gated single-photon emission computed tomography improves the ability of technetium-99m sestamibi myocardial perfusion imaging to predict myocardial viability in patients undergoing revascularization. *Am J Cardiol* 1999;83:1–5.

3. Duncan BH, Ahlberg AW, Levine MG, McGill CC, Mann A, White MP, Mather JF, Waters DD, Heller GV. Comparison of electrocardiographic-gated technetium-99m sestamibi single-photon emission computed tomographic imaging and redistribution thallium-201 in the prediction of myocardial viability. *Am J Cardiol* 2000;85:680–684.

4. Stollfuss JC, Haas F, Matsunari I, Neverve J, Nekolla S, Ziegler S, Schwaiger M. 99mTc-tetrofosmin SPECT for prediction of functional recovery defined by MRI in patients with severe left ventricular dysfunction: additional value of gated SPECT. *J Nucl Med* 1999;40:1824–1831.

5. Everaert H, Vanhove C, Franken PR. Low-dose dobutamine gated single-photon emission tomography: comparison with stress echocardiography. *Eur J Nucl Med* 2000;27:413–418.

6. Kumina SS, Cho K, Nakajo H, Toba M, Kijima T, Mizumura S, Oshina T, Kumazaki T, Sano J, Sakurai K, Munakata K. Serial assessment of left ventricular function during dobutamine stress by means of electrocardiography-gated myocardial SPECT: combination with dual-isotope myocardial perfusion

SPECT for detection of ischemic heart disease. *J Nucl Cardiol* 2001;8:152–158.

7. Leoncini M, Marcucci G, Sciagrà R, Frascarelli F, Traini AM, Mondanelli D, Magni M, Bini L, Bellandi F, Mennuti A, Dabizzi RP. Nitrate-enhanced gated Tc-99m sestamibi SPECT for evaluating regional wall motion at baseline and during low dose dobutamine infusion in patients with chronic coronary artery disease and left ventricular dysfunction. Comparison with two-dimensional echocardiography. *J Nucl Cardiol* 2000;7:426–431.

8. Leoncini M, Marcucci G, Sciagrà R, Frascarelli F, Simonetti I, Bini L, Maioli M, Mennuti A, Dabizzi RP. Prediction of functional recovery in patients with chronic coronary artery disease and left ventricular dysfunction combining the evaluation of myocardial perfusion and contractile reserve using nitrate-enhanced technetium-99m sestamibi gated single-photon emission computed tomography and dobutamine stress. *Am J Cardiol* 2001;87:1346–1350.

9. Bisi G, Sciagrà R, Santoro GM, Fazzini PF. Rest technetium-99m sestamibi tomography in combination with short-term administration of nitrates: feasibility and reliability for prediction of postrevascularization outcome of asynergic territories. *J Am Coll Cardiol* 1994;24:1282–1289.

10. Sciagrà R, Bisi G, Santoro GM, Zeraushek F, Sestini S, Pedenovi P, Pappagallo R, Fazzini PF. Comparison of baseline-nitrate technetium-99m-sestamibi with rest-redistribution thallium-201 tomography in detecting viable hi-

bernating myocardium and predicting postrevascularization recovery. *J Am Coll Cardiol* 1997;30:384–391.

11. Chua T, Kiat H, Germano G, Maurer G, van Train K, Friedman J, Berman DS. Gated technetium-99m sestamibi for simultaneous assessment of stress myocardial perfusion, postexercise regional ventricular function and myocardial viability. Correlation with echocardiography and rest thallium-201 scintigraphy. *J Am Coll Cardiol* 1994;23:1107–1114.

12. Maes AF, Borgers M, Flameng W, Nuyts JL, van de Werf F, Ausma JJ, Sergeant P, Mortelmans LA. Assessment of myocardial viability in chronic coronary artery disease using technetium-99m sestamibi SPECT: correlation with histologic and positron emission tomographic studies and functional follow-up. *J Am Coll Cardiol* 1997;29:62–68.

13. Germano G, Erel J, Lewin H, Kavanagh PB, Berman DS. Automatic quantitation of regional myocardial wall motion and thickening from gated technetium-99m sestamibi myocardial perfusion single-photon emission computed tomography. *J Am Coll Cardiol* 1997;30:1360–1367.

14. Bax JJ, Poldermans D, Elhendy A, Cornel JH, Boersma E, Rambaldi R, Roelandt JR, Fioretti P. Improvement in left ventricular ejection fraction, heart failure symptoms and prognosis after revascularization in patients with chronic coronary artery disease and viable myocardium detected by dobutamine echocardiography. *J Am Coll Cardiol* 1999;34:163–169.

15. Sciagra R, Leoncini M, Marcucci G, Dabizzi RP, Pupi A. Technetium-99m sestamibi imaging to predict left ventricular ejection fraction outcome after

revascularization in patients with chronic coronary artery disease and left ventricular dysfunction: comparison between baseline and nitrate-enhanced imaging. *Eur J Nucl Med* 2001;28:680–687.

16. Marwick TH. The viable myocardium: epidemiology, detection, and clinical implications. *Lancet* 1998;351:815–819.

17. Vanoverschelde JL, D'Hondt AM, Marwick T, Gerber BL, Kock M, Dion R, Wijns W, Melin JA. Head-to-head comparison of exercise-redistribution-reinjection thallium single-photon emission computed tomography and low dose dobutamine echocardiography for prediction of reversibility of chronic left ventricular dysfunction. *J Am Coll Cardiol* 1996;28:432–442.

18. Pasquet A, Lauer MS, Williams MJ, Secknus MA, Lytle B, Marwick TH. Prediction of global left ventricular function after bypass surgery in patients with severe left ventricular dysfunction. Impact of pre-operative myocardial function, perfusion, and metabolism. *Eur Heart J* 2000;21:125–136.

19. Sanchis J, Bodi V, Insa L, Gomez-Aldaravi R, Berenguer A, Lopez-Lereu MP, Chorro FJ, Lopez-Merino V. Low-dose dobutamine testing using contrast left ventriculography in the same session as coronary angiography predicts the improvement of left ventricular function after coronary angioplasty in postinfarction patients. *Am J Cardiol* 1999;83:15–20.

20. Zafirir N, Vidne B, Sulkes J, Sclarovsky S. Usefulness of dobutamine radionuclide ventriculography for prediction of left ventricular function improvement after coronary bypass grafting for ischemic cardiomyopathy. *Am J Cardiol* 1999;83:691–695.