



UNIVERSITÀ
DEGLI STUDI
FIRENZE

FLORE

Repository istituzionale dell'Università degli Studi di Firenze

Prediction of post-revascularization functional recovery of asynergic myocardium using quantitative 201Tl rest-redistribution tomography:

Questa è la Versione finale referata (Post print/Accepted manuscript) della seguente pubblicazione:

Original Citation:

Prediction of post-revascularization functional recovery of asynergic myocardium using quantitative 201Tl rest-redistribution tomography: has the reverse redistribution pattern an independent significance? / R. SCIAGRA'; PUPI A; PELLEGRINI M; MATTEINI M; SANTORO GM; BISI G; FAZZINI PF.. - In: EUROPEAN JOURNAL OF NUCLEAR MEDICINE. - ISSN 0340-6997. - STAMPA. - 25:(1998), pp. 594-600.

Availability:

This version is available at: 2158/222307 since:

Publisher:

Springer Verlag Germany:Tiergartenstrasse 17, D 69121 Heidelberg Germany:011 49 6221 3450, EMAIL:

Terms of use:

Open Access

La pubblicazione è resa disponibile sotto le norme e i termini della licenza di deposito, secondo quanto stabilito dalla Policy per l'accesso aperto dell'Università degli Studi di Firenze (<https://www.sba.unifi.it/upload/policy-oa-2016-1.pdf>)

Publisher copyright claim:

(Article begins on next page)

Prediction of post-revascularization functional recovery of asynergic myocardium using quantitative thallium-201 rest-redistribution tomography: has the reverse redistribution pattern an independent significance?

Roberto Sciagrà¹, Alberto Pupi¹, Marco Pellegri¹, Maria Matteini¹, Giovanni M. Santoro², Gianni Bisi¹, Pier Filippo Fazzini²

¹ Nuclear Medicine Unit, Department of Clinical Physiopathology, University of Florence, Italy

² Division of Cardiology, Careggi Hospital, Florence, Italy

Received 19 November 1997 and in revised form 20 February 1998

Abstract. The significance of reverse redistribution on rest-redistribution thallium-201 myocardial scintigraphy is unclear. Previous studies suggested that reverse redistribution segments with normal resting activity include viable myocardium, whilst resting defects with further worsening correspond to scar. We evaluated whether reverse redistribution has an independent significance for the prediction of post-revascularization recovery, particularly as compared with the quantification of redistribution activity. We studied 26 coronary artery disease patients with left ventricular dysfunction, who underwent ²⁰¹Tl rest-redistribution single-photon emission tomography (SPET) and echocardiography before revascularization. Viability was defined by the detection of wall motion improvement on follow-up echocardiography. ²⁰¹Tl activity was considered normal if $\geq 80\%$, moderately reduced if $< 80\%$ but $\geq 50\%$, and severely decreased if $< 50\%$. Reverse redistribution was defined as a defect in redistribution images with $\geq 10\%$ decrease in relative ²⁰¹Tl activity compared with the resting value. Reverse redistribution was detected in 33 segments (10%). Baseline dysfunction was equally observed in the reverse redistribution and in the non-reverse redistribution segments (64% vs 56%, $P=0.40$) and the rate of asynergic segments with post-revascularization recovery was not different between the two groups (33% vs 54%, $P=0.11$). The rate of functional recovery in redistribution defects without reverse redistribution was 53% in moderate and 30% in severe defects; the corresponding values for the reverse redistribution segments were 50% and 27% (all non-significant versus non-reverse redistribution segments). For the prediction of post-revascularization recovery in asynergic segments, the detection of reverse redistribution on rest-redistribution ²⁰¹Tl SPET does not

add any information to the quantitative analysis of redistribution activity.

Key words: Myocardium – Perfusion – Revascularization – Scintigraphy – Thallium-201

Eur J Nucl Med (1998) 25:594–600

Introduction

Reverse redistribution, i.e. decreased tracer uptake in redistribution as compared to early post-stress or rest images, is a most intriguing finding on thallium-201 myocardial scintigraphy. The meaning of reverse redistribution together with its possible mechanisms has been addressed in several reports and reviews [1–21]. Recently, attention has been given to the implications of reverse redistribution for detection of viability in patients with chronic coronary artery disease [13, 14, 17–19, 21]. The presence of viable myocardium within regions with reverse redistribution on stress ²⁰¹Tl scintigraphy has been demonstrated using tracer reinjection [13, 17] and by fluorine-18 fluorodeoxyglucose uptake in positron emission tomography [13, 18, 19]. More uncertain are the results of other studies performed using the rest-redistribution protocol [14, 21]. Apparently, most segments with an initially normal resting uptake, but with reverse redistribution are different from the other normally perfused segments because they have impaired function and are related to severe coronary stenosis [14]. However, their response to coronary revascularization suggests that they mainly include viable myocardium [21]. Conversely, segments with a significant resting uptake defect and further worsening in redistribution images are not different from irreversible defects and do not usually show functional improvement after revascularization [14, 21].

Correspondence to: R. Sciagrà, Nuclear Medicine Unit, Department of Clinical Physiopathology, University of Florence, Viale Morgagni 85, I-50134 Florence, Italy

A major limitation of this classification of reverse redistribution segments is that major emphasis is given to their resting activity. Recent data, however, suggest that the best predictor of post-revascularization functional recovery of asynergic regions in rest-redistribution imaging is redistribution activity [22–27]. Accordingly, it seems interesting to examine the relationship between reverse redistribution and post-revascularization recovery, taking into account ^{201}Tl activity in redistribution images. The present study therefore aimed to evaluate whether the detection of reverse redistribution is related to the probability of post-revascularization functional improvement in asynergic segments and whether this relationship is independent of redistribution ^{201}Tl activity.

Materials and methods

Patients. From among the patients with chronic coronary artery disease and left ventricular dysfunction referred to our laboratory for the evaluation of myocardial viability, 26 consecutive patients (24 men and 2 women, mean age 69.4 ± 9.2 years) for whom coronary revascularization had been planned were included in the study. Exclusion criteria were: recent (<3 months) myocardial infarction or unstable angina, heart disease other than coronary artery disease, and history of prior revascularization procedures. The mean left ventricular ejection fraction at enrolment was $35.9\% \pm 6.8\%$. The location of the previous myocardial infarction was anterior in 18 patients and inferior in eight.

The study protocol included the performance of two-dimensional echocardiography and rest-redistribution ^{201}Tl single-photon emission tomography (SPET) before revascularization. All major epicardial branches with significant stenosis underwent revascularization, by coronary artery bypass grafting in eight cases and by percutaneous transluminal coronary angioplasty in the remaining 18 patients. Peri- or postoperative myocardial infarction was excluded in all patients using the usual clinical, enzymatic and electrocardiographic criteria. After revascularization (at least 1 month in the case of angioplasty and at least 3 months in the case of bypass grafting) follow-up two-dimensional echocardiography was performed to evaluate the evolution of regional and global left ventricular function. In patients treated with coronary angioplasty, restenosis was excluded on the basis of a negative exercise stress test. All patients gave their informed consent to participation in the study, which had previously been approved by the Ethics Committee of our institution.

Coronary angiography. Coronary angiography was performed using the percutaneous transfemoral technique. Percent diameter stenosis was evaluated by two experienced observers who were unaware of patient data, using multiple projections including angulated views. Vessels showing $\geq 50\%$ lumen reduction were considered diseased. The presence or absence of collaterals was assessed and the quality of collateral circulation was scored in four grades (from 0=none to 3=complete filling of the epicardial vessels) [28].

Two-dimensional echocardiography. Both echocardiographic studies were collected at rest with the patient lying in the left lateral decubitus position using a commercially available echocardiograph (Aloka SSD-870) with 2.5–3.5-MHz transducers. Multiple imaging sections were obtained for each study and recorded on video-

tape. All studies were analysed off line by two experienced observers, unaware of the clinical, angiographic and scintigraphic data and of the acquisition sequence. Discrepancies were resolved by consensus. The left ventricle was divided into 13 segments [29], which were assigned to the related coronary artery using a modification of a previously described scheme [30]. Wall motion and thickening of each segment were analysed using a semiquantitative score: 1=normal, 2=hypokinesis, 3=akinesis, 4=dyskinesis [31, 32]. To evaluate the presence of functional recovery, the evolution of regional wall motion in the asynergic segments was assessed by comparing the pre- and post-revascularization scores. A significant improvement was defined by a post-revascularization score decrease ≥ 1 point [25, 29, 32]. However, a change from dyskinesis to akinesis was considered not significant [32, 33].

^{201}Tl SPET. Patients were studied after overnight fasting, with the injection at rest of 3 mCi (111 MBq) of ^{201}Tl followed 30 min later by SPET acquisition. The redistribution images were collected after a 3- to 4-h delay. Both studies were acquired using an Elscint Apex SP4 gamma camera equipped with a low-energy all-purpose collimator, with a 15% window centred on the 68- to 80-keV peak and a second 10% window centred on the 167-keV peak of ^{201}Tl . Sixty projections of 25 s each were collected in step and shoot mode over a 180° arc (from the 45° right anterior oblique to the 45° left posterior oblique projection) on a 64×64 matrix. Filtered backprojection using a Butterworth filter with a 0.35 cut-off and an order of 5.0 was used to reconstruct the transaxial slices, which were then realigned along the heart axis. For the quantitative evaluation of SPET images, the short-axis slices from the first with apical activity, to the last with activity at the base were used. Their count profiles were generated by computer software and plotted onto a two-dimensional volume-weighted polar map, which was then divided into 13 segments. Each segment was assigned to a coronary artery territory and then matched with an echocardiographic one, having as a reference previously described schemes [30, 34], modified to take into account the application of the 13-segment model. Using an automated computer procedure, the tracer activity within each segment was calculated as the total of the normalized counts of the pixels included within the segment divided by their number. The segment with maximal activity in each polar map was then normalized to 100 and the activity of the other segments was expressed as a percentage of that peak activity segment. Normal ^{201}Tl uptake was defined as $\geq 80\%$ relative activity [14, 21, 25, 32]. ^{201}Tl activity was defined as moderately reduced when $< 80\%$ and $\geq 50\%$ and as severely decreased when $< 50\%$ [22, 25, 32]. The difference between redistribution and rest ^{201}Tl mean percent activity (reversibility) was calculated and expressed as a percentage of the rest value; it was considered significant if there was an increase $\geq 10\%$ of the resting activity [23]. Reverse redistribution was defined as present if a segment with redistribution activity $< 80\%$ also had a $\geq 10\%$ decrease in relative activity in redistribution compared with resting images [13, 17].

Statistical analysis. Data are expressed as the mean \pm SD. Baseline data were compared by means of the chi-square test for categorical variables and the unpaired *t* test for continuous variables, with the Bonferroni correction for multiple comparisons as appropriate. The comparison of proportions was made using the chi-square test with Yates correction as applicable. A probability value of $P < 0.05$ was considered statistically significant.

Results

General findings

According to the results of coronary angiography, 50 coronary arteries were found to be affected by significant stenosis. In particular, nine patients had one-vessel, ten two-vessel and seven three-vessel coronary artery disease. A complete obstruction was demonstrated in 17 vessels and a severe stenosis ($\geq 90\%$) in a further 16 coronary arteries.

A total of 338 segments were analysed in the 26 patients. In the baseline echocardiogram, 146 segments (43%) showed normal wall motion, 73 (22%) hypokinesis, 109 (32%) akinesis and 10 (3%) dyskinesis. In the follow-up control, a wall motion score improvement was registered in 37/73 (51%) hypokinetic segments, which reverted to normokinesis, and in 63/109 (58%) akinetic segments (32 of which became hypokinetic and 31 of which became normokinetic). Thus, of a total of 192 asynergic segments, 100 (52%) had a significant functional recovery after revascularization, while the remaining 92 (48%), showed no significant change. The main baseline features of the two groups of segments are summarised in Table 1. On resting ^{201}Tl SPET, 106 segments (31%) had normal activity and 232 (69%) an uptake defect. In redistribution imaging, 99 segments (29%) had normal activity, 110 segments (33%) were classified as irreversible defects, 96 (28%) had reversibility $\geq 10\%$, and 33 (10%) showed reverse redistribution.

Features of the segments with reverse redistribution

At least one reverse redistribution segment was registered in 15 patients (mean 2.2 ± 1.2 segments/patient). Of the 33 reverse redistribution segments, 7 (21%) had normal resting activity ($90\% \pm 5.3\%$) and 26 (79%) had an abnormal resting uptake ($53.1\% \pm 16.6\%$). The involved left ventricular wall was the anteroseptal in 17 segments, the inferior wall in nine segments and the lateral wall in seven segments. Reverse redistribution segments were related to a coronary artery with significant stenosis in 24/33 cases (73%); the segments without reverse redistribution were subtended by a diseased vessel in 186/305 cases (61%, $P=0.19$). The rate of segments related to an occluded coronary artery was 8/33 (24%) for the segments with reverse redistribution and 85/305 (28%) for the remaining segments ($P=0.66$). The incidence of good collateral circulation to an occluded territory was 7/8 (88%) for the reverse redistribution segments and 42/85 (49%) for the other segments ($P=0.09$). The proportion of segments with baseline wall motion abnormalities was 21/33 (64%) for the segments with reverse redistribution and 171/305 (56%) for the remaining segments ($P=0.4$). The main baseline features of the two groups of segments (with versus without reverse redistribution) are summarised in Table 2.

Reverse redistribution and reversible dysfunction

Taking into account the presence or absence of functional recovery after revascularization, a significant improvement was observed in 7 of 21 reverse redistribution

Table 1. Main baseline features of the asynergic segments with versus those without functional recovery on follow-up echocardiography

	Functional recovery		P
	Yes (n=100)	No (n=92)	
Coronary artery disease			
LAD	63%	60%	} 0.85
RCA	23%	23%	
LCX	14%	14%	
Severity of stenosis			
100%	47%	41%	} <0.03
$\geq 90\%$	47%	43%	
$\geq 50\%$	6%	16%	
Collaterals to occluded vessels			
Score 2-3	55%	55%	} 1
Score 0-1	45%	45%	
WMS	2.62 \pm 0.49	2.72 \pm 0.65	0.19
Rest ^{201}Tl activity (%)	67.1 \pm 17	56.5 \pm 0.65	<0.0002
Redistribution ^{201}Tl activity (%)	71.6 \pm 17.6	58.9 \pm 21.4	<0.00005

LAD, Left anterior descending artery; LCX, left circumflex artery; RCA, right coronary artery; WMS, wall motion score

Table 2. Main baseline features of the segments with versus those without reverse redistribution

	Reverse redistribution		P
	Yes (n=33)	No (n=305)	
Coronary artery disease			
No	27%	39%	} <0.01
LAD	49%	40%	
RCA	18%	11%	
LCX	6%	10%	
Severity of stenosis			
100%	33%	46%	} <0.005
≥90%	46%	42%	
≥50%	21%	12%	
Collaterals to occluded vessels			
Score 2–3	88%	49%	} 0.09
Score 0–1	12%	51%	
WMS	2.15±1.03	1.93±0.92	0.07
Rest ²⁰¹ Tl activity (%)	60.9±21.3	70.1±17.6	<0.0005
Redistribution ²⁰¹ Tl activity (%)	47.7±22	75.2±17.4	<0.00001

Abbreviations as defined in Table 1

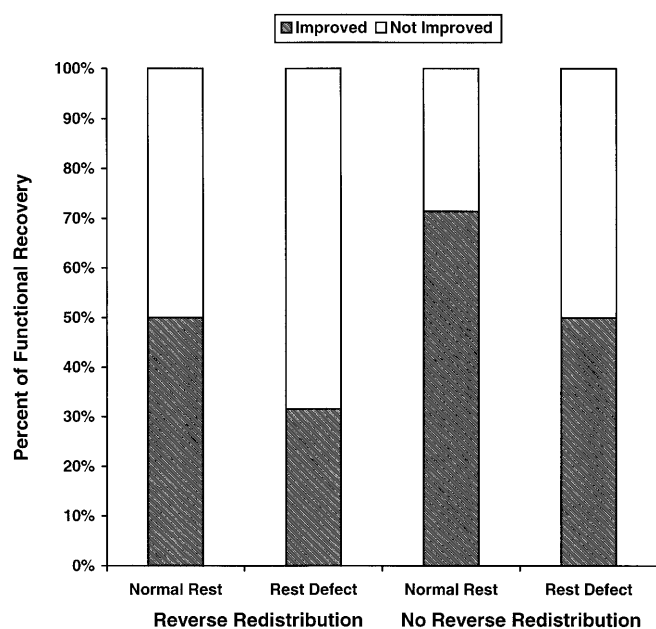


Fig. 1. Bar graph showing the proportion of segments with post-revascularization functional recovery (Improved) versus those with unchanged dysfunction (Not Improved) in the segments with or without reverse redistribution subdivided according to the presence of normal resting ²⁰¹Tl activity or resting uptake defect

segments with baseline dysfunction (33%). Among the 171 asynergic segments without reverse redistribution, 93 showed functional recovery (54%) ($P=0.11$ vs reverse redistribution). On the other hand, reverse redistribution was registered in 7/100 (7%) asynergic segments with functional recovery and in 14/92 (15%) segments with-

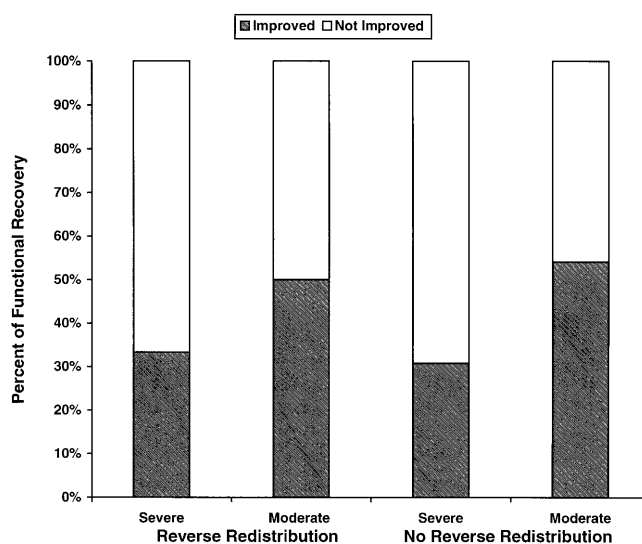


Fig. 2. Bar graph showing the proportion of segments with post-revascularization functional recovery (Improved) versus those with unchanged dysfunction (Not Improved) in the segments with or without reverse redistribution subdivided according to ²⁰¹Tl redistribution activity. Moderate = moderate ²⁰¹Tl uptake defect; Severe = severe ²⁰¹Tl uptake defect (see text)

out ($P=0.11$). The proportion of segments with post-revascularization recovery was higher in those with normal resting activity than in those with resting uptake defect, independently of the finding of reverse redistribution (Fig. 1).

The incidence of post-revascularization recovery was compared in the asynergic segments with and in those without reverse redistribution taking into account their

redistribution activity. Of 27 asynergic segments without reverse redistribution and with severe ^{201}Tl defect on redistribution SPET, eight (30%) showed reversible dysfunction, as compared with 4 of 15 (27%) reverse redistribution segments with similar redistribution activity ($P=0.88$). Likewise, 47 of 88 (53%) moderate defects on redistribution SPET without reverse redistribution and three of six (50%) with reverse redistribution had functional recovery at follow-up control ($P=0.79$) (Fig. 2). Thus, the overall negative predictive value of redistribution activity $<50\%$ was 71% and was not significantly influenced by the presence of reverse redistribution, being 73% when reverse redistribution segments were examined separately. Conversely, the overall positive predictive value of redistribution activity $\geq 50\%$ was 59%; this value decreased to 57% if reverse redistribution was considered always to be a sign of absent viability.

Discussion

Although several reports have described the pattern of reverse redistribution on ^{201}Tl myocardial scintigraphy, its mechanisms, clinical significance and practical implications are not yet completely clear [1–21]. Abnormalities of ^{201}Tl washout and coexistence of scarred, normal or ischaemic tissue were postulated as possible mechanisms to explain reverse redistribution [1–3]. Other groups demonstrated that in planar ^{201}Tl imaging an apparent reverse redistribution pattern could also be caused by inappropriate background subtraction and suggested that this might be the most likely explanation in patients with a low pre-test probability of coronary artery disease [5, 6]. However, reverse redistribution in patients with normal coronary arteries has also been registered using SPET, thus excluding the interference of background subtraction problems [8]. In patients recently treated with thrombolytic therapy for acute myocardial infarction the finding of reverse redistribution in resting imaging appeared to be valuable for viability detection and prediction of functional recovery in salvaged myocardium [4]. In patients with chronic coronary artery disease, however, several regions with reverse redistribution were found to have impaired regional function, indicating the possible presence of scarred tissue [2]. The presence of viability within reverse redistribution segments on stress-redistribution scintigraphy was more thoroughly investigated using the reinjection of ^{201}Tl [13, 17] or the evaluation of glucose metabolism by means of ^{18}F -fluorodeoxyglucose positron emission tomography [13, 18, 19]. The results of these studies were consonant in suggesting the presence of viable myocardium within most of the reverse redistribution areas [13, 17–19].

In patients with chronic coronary artery disease submitted to rest redistribution imaging the meaning of reverse redistribution for the issue of viability definition is still uncertain [14, 21]. In two studies using quantitative planar ^{201}Tl scintigraphy, Pace et al. [14, 21] demonstrat-

ed that reverse redistribution segments with normal resting activity presented with more severe wall motion abnormalities and underlying coronary stenosis than the other normal segments [14], but included mostly viable tissue, as demonstrated by the high rate of functional recovery after revascularization [21]. On the other hand, the few resting uptake defects with reverse redistribution appeared to be comparable in terms of wall motion and related coronary artery disease with the other irreversible defects [14] and showed mainly an unchanged regional dysfunction [21].

According to our data, neither the related coronary vessel status nor the incidence of baseline wall motion abnormalities differentiated the reverse redistribution segments from the segments without reverse redistribution. More importantly, when the functional outcome after revascularization was examined in the asynergic segments, the overall incidence of recovery was not significantly different in the segments with reverse redistribution when compared with the remaining segments. Furthermore, no difference was registered in our population when the segments with normal resting activity were separately examined. We also divided the asynergic segments according to their redistribution activity and we could observe that the incidence of functional recovery after revascularization became higher with the increase in redistribution activity, but within the various groups (moderate and severe defects) there was no difference between reverse redistribution segments and segments without reverse redistribution.

These data would indicate that the finding of reverse redistribution does not add any major information to what can be derived from the quantitative analysis of redistribution images. This was not completely unexpected given previous data. In the study by Pace et al. [21], a clearly higher redistribution activity could be noted in the segments with normal resting uptake as compared with the resting uptake defects. Moreover, the redistribution activity of the initial uptake defects with reverse redistribution appeared to be relatively high in most of the segments of this group with wall motion recovery [21]. Likewise, in the study by Marin-Neto et al. [13], the mean redistribution activity of the reinjection-positive segments was clearly higher than that registered in the reinjection-negative segments and, furthermore, Dey and Soufer [17] found a higher rate of enhanced uptake in segments with mild as compared to those with moderate or severe reverse redistribution.

The elucidation of the mechanisms of reverse redistribution in rest-redistribution ^{201}Tl imaging was beyond the aim of this study, which was explicitly conceived to examine the practical implications of the finding. However, our data support the possible role of the admixture of scarred and viable tissue in the presence of preserved resting blood flow [15, 21]. As regards coronary flow, the incidence of well-developed collaterals to occluded vessels subtending reverse redistribution segments was higher than that observed in the corresponding non-re-

verse redistribution segments (88% vs 49%), with a value close to statistical significance ($P=0.09$). As regards myocardial tissue, it is reasonable that the reverse redistribution regions with unchanged wall motion abnormality include a higher proportion of scarred tissue than those with post-revascularization recovery. Accordingly, the former areas will be expected to have a relatively faster washout and, thus, a lower redistribution activity than the latter ones.

The limitations of the present study must be considered when interpreting its results. First of all, the patient population is small, as in most studies which employ the detection of functional recovery after revascularization to define the presence of viable myocardium within asynergic regions [21, 22–27]. The need to select patients who will be submitted to a revascularization procedure precluded the enrolment of a consecutive population of patients with left ventricular dysfunction and could have introduced some pre-referral bias. Thus, our results should be cautiously applied to the general population of patients with chronic coronary artery disease. The adopted cut-off values to define the tracer uptake categories and significant redistribution are arbitrary, although supported by several other studies [13, 14, 17, 21–23, 25, 26, 32]: thus, different results could be obtained by changing these thresholds. The use of post-revascularization recovery as the reference standard to define the presence of viable myocardium within asynergic areas is not devoid of important limitations [35, 36]. Baseline wall motion abnormalities, in particular hypokinesia, may be caused by myocardial hibernation or scarring, but also by an admixture of fully viable and functioning tissue with subendocardial scarring [35]. In the last instance, ^{201}Tl uptake in the viable layers will be detected, but no post-revascularization recovery is to be expected. Furthermore, it is still debated whether segments without recovery but with preserved ^{201}Tl uptake behave differently than segments without tracer activity in terms of future ventricular remodelling, risk of arrhythmic disturbances and prognostic implications [35–37]. Other problems might derive from the arbitrary time points chosen for the follow-up control, because the theoretical possibility of a later improvement in contractility cannot be excluded. However, whilst no earlier controls were performed, in several patients the timing of follow-up echocardiography was actually more delayed than that indicated in the protocol. On the other hand, this time interval and the lack of a post-revascularization control of myocardial perfusion do not allow exclusion of the possibility of restenosis or bypass dysfunction, although in all patients clinical evaluation and in angioplasty patients also exercise stress testing were negative in this regard.

In summary, our data indicate that on rest redistribution ^{201}Tl imaging: (1) reverse redistribution segments may or may not include enough viable tissue to achieve a significant functional improvement after revascularization; and (2) the quantification of redistribution activity

allows one to effectively affirm or exclude the presence of viable myocardium within most asynergic segments showing the reverse redistribution pattern. For this specific issue and taking into account the uncommon occurrence of reverse redistribution, the possible non-observation of this phenomenon does not seem to imply any important consequences in terms of viability detection. Therefore, the sole acquisition of a redistribution study with the quantitative analysis of ^{201}Tl uptake could give most of the needed information for a reliable prediction of the post-revascularization functional outcome of the asynergic territories and might be a cost-effective approach.

References

1. Tanasescu D, Berman D, Staniloff H, Brachman M, Ramanna L, Waxman A. Apparent worsening of thallium-201 myocardial defects during redistribution – What does it mean? [abstract] *J Nucl Med* 1979; 20: 688.
2. Hecht HS, Hopkins JM, Rose JG, Blumfield DE, Wong M. Reverse redistribution: worsening of thallium-201 myocardial images from exercise to redistribution. *Radiology* 1981; 140: 177–181.
3. Silberstein EB, DeVries DF. Reverse redistribution phenomenon in thallium-201 stress tests: angiographic correlation and clinical significance. *J Nucl Med* 1985; 26: 707–710.
4. Weiss AT, Maddahi J, Lew AS, Shah PK, Ganz W, Swan HJC, Berman DS. Reverse redistribution of thallium-201: a sign of nontransmural myocardial infarction with patency of the infarct-related coronary artery. *J Am Coll Cardiol* 1986; 7: 61–67.
5. Brown KA, Benoit L, Clements JP, Wackers FJT. Fast washout of thallium-201 from area of myocardial infarction: possible artifact of background subtraction. *J Nucl Med* 1987; 28: 945–949.
6. Lear JL, Raff U, Jain R. Reverse and pseudo redistribution of thallium-201 in healed myocardial infarction and normal and negative thallium-201 washout in ischemia due to background oversubtraction. *Am J Cardiol* 1988; 62: 543–550.
7. Touchstone DA, Beller GA, Nygaard TW, Watson DD, Tedesco C, Kaul S. Functional significance of pre-discharge exercise thallium-201 findings following intravenous streptokinase therapy during acute myocardial infarction. *Am Heart J* 1988; 116: 1500–1507.
8. Popma JJ, Smitherman TC, Walker BS, Simon TR, Dehmer GJ. Reverse redistribution of thallium-201 by SPECT imaging after dipyridamole in angina pectoris. *Am J Cardiol* 1990; 65: 1176–1180.
9. Fukuzawa S, Osawa S, Nobuyoshi M, Inagaki Y. Reverse redistribution on Tl-201 SPECT images after reperfusion therapy for acute myocardial infarction: possible mechanism and prognostic implications. *Heart Vessels* 1992; 7: 141–147.
10. Langer A, Burns RJ, Freeman MR, Liu P, Morgan CD, Wilson R, Armstrong PW. Reverse redistribution on exercise thallium scintigraphy: relationship to coronary patency and ventricular function after myocardial infarction. *Can J Cardiol* 1992; 8: 709–715.
11. Yamagishi H, Itagane H, Akioka K, Ohmura T, Iida H, Tahara A, Toda I, Teragaki M, Takeuchi K, Takeda T. Clinical significance of reverse redistribution on thallium-201 single-photon

- emission computed tomography in patients with acute myocardial infarction. *Jpn Circ J* 1992; 56: 1095–1105.
12. Sakata K, Yoshida H, Ono N, Ohtani S, Mori N, Yokoyama S, Hoshiro T, Kaburagi T, Kurata C. Implications of delayed image on simultaneous thallium-201/ technetium-99m pyrophosphate dual emission computed tomography early after acute myocardial infarction. *Jpn Circ J* 1993; 57: 27–36.
 13. Marin-Neto JA, Dilsizian V, Arrighi JA, Freedman NMT, Perrone-Filardi P, Bacharach SL, Bonow RO. Thallium reinjection demonstrates viable myocardium in regions with reverse redistribution. *Circulation* 1993; 88: 1736–1745.
 14. Pace L, Cuocolo A, Maurea S, Nicolai E, Imbriaco M, Nappi A, Morisco C, Chiariello M, Trimarco B, Salvatore M. Reverse redistribution in resting thallium-201 myocardial scintigraphy in patients with coronary artery disease: relation to coronary anatomy and ventricular function. *J Nucl Med* 1993; 34: 1688–1692.
 15. Liu P, Burns RJ. Easy come, easy go: time to pause and put thallium reverse redistribution in perspective. *J Nucl Med* 1993; 34: 1692–1694.
 16. Dudzic EM, Sridhara BS, Lahiri A. Reverse redistribution: fact or fiction? *Eur J Nucl Med* 1994; 21: 449–453.
 17. Dey HM, Soufer R. Reverse redistribution on planar thallium scintigraphy: relationship to resting thallium uptake and long-term outcome. *Eur J Nucl Med* 1995; 22: 237–242.
 18. Ohte N, Hashimoto T, Banno T, Narita H, Kobayashi K, Akita S, Fujinami T. Clinical significance of reverse redistribution on 24-hour delayed imaging of exercise thallium-201 myocardial SPECT: comparison with myocardial fluorine-18-FDG-PET imaging and left ventricular wall motion. *J Nucl Med* 1995; 36: 86–92.
 19. Soufer R, Dey HM, Lawson AJ, Wackers FJT, Zaret BL. Relationship between reverse redistribution on planar thallium scintigraphy and regional myocardial viability: a correlative PET study. *J Nucl Med* 1995; 36: 180–187.
 20. Maddahi J, Berman DS. Reverse redistribution of thallium-201. *J Nucl Med* 1995; 36: 1019–1021.
 21. Pace L, Cuocolo A, Marzullo P, Nicolai E, Gimelli A, De Luca N, Ricciardelli B, Salvatore M. Reverse redistribution in resting thallium-201 myocardial scintigraphy in chronic coronary artery disease: an index of myocardial viability. *J Nucl Med* 1995; 36: 1968–1973.
 22. Ragosta M, Beller GA, Watson DD, Kaul S, Gimple LW. Quantitative planar rest-redistribution ²⁰¹Tl imaging in detection of myocardial viability and prediction of improvement in left ventricular function after coronary bypass surgery in patients with severely depressed left ventricular function. *Circulation* 1993; 87: 1630–1641.
 23. Udelson JE, Coleman PS, Metherall J, Pandian NG, Gomez AR, Griffith JL, Shea NL, Oates E, Konstam MA. Predicting recovery of severe regional ventricular dysfunction: comparison of resting scintigraphy with ²⁰¹Tl and ^{99m}Tc-sestamibi. *Circulation* 1994; 89: 2552–2561.
 24. Charney R, Schwinger ME, Chun J, Cohen MV, Nanna M, Menegus MA, Wexler J, Spindola Franco H, Greenberg MA. Dobutamine echocardiography and resting-redistribution thallium-201 scintigraphy predicts recovery of hibernating myocardium after coronary revascularization. *Am Heart J* 1994; 128: 864–869.
 25. Perrone-Filardi P, Pace L, Prastaro M, Squame F, Betocchi S, Soricelli A, Piscione F, Indolfi C, Crisci T, Salvatore M, Chiariello M. Assessment of myocardial viability in patients with chronic coronary artery disease. Rest-4-hour-24-hour ²⁰¹Tl tomography versus dobutamine echocardiography. *Circulation* 1996; 94: 2712–2719.
 26. Qureshi U, Nagueh SF, Afridi I, Vaduganathan P, Blaustein A, Verani MS, Winters WL, Zoghbi WA. Dobutamine echocardiography and quantitative rest-redistribution ²⁰¹Tl in myocardial hibernation. Relation of contractile reserve to ²⁰¹Tl uptake and comparative prediction of recovery of function. *Circulation* 1997; 95: 626–635.
 27. Sciagrà R, Bisi G, Santoro GM, Zeraushek F, Sestini S, Pedenovi P, Pappagallo R, Fazzini PF. Comparison of baseline-nitrate technetium-99m-sestamibi with rest-redistribution thallium-201 tomography in detecting viable hibernating myocardium and predicting postrevascularization recovery. *J Am Coll Cardiol* 1997; 30: 384–391.
 28. Rentrop KP, Cohen M, Blanke M, Phillips RA. Changes in collateral channel filling after controlled coronary artery occlusion by an angioplasty balloon in human subjects. *J Am Coll Cardiol* 1985; 5: 587–592.
 29. Picano E, Marzullo P, Gigli G, Reichenhofer B, Parodi O, Distanti A, L'Abbate A. Identification of viable myocardium by dipyridamole-induced improvement in regional left ventricular function assessed by echocardiography in myocardial infarction and comparison with thallium scintigraphy at rest. *Am J Cardiol* 1992; 70: 703–710.
 30. Pozzoli M, Fioretti PM, Salustri A, Reijs AEM, Roelandt JRTC. Exercise echocardiography and technetium-99m MIBI single-photon emission computed tomography in the detection of coronary artery disease. *Am J Cardiol* 1991; 67: 350–355.
 31. Schiller NB, Shah PM, Crawford M, DeMaria A, Devereux R, Feigenbaum H, Gutgesell H, Reichek N, Sahn D, Schnittger I, Silverman AH, Tajik AJ. Recommendations for quantification of the left ventricle by two-dimensional echocardiography. *J Am Soc Echocardiogr* 1989; 2: 358–67.
 32. Perrone-Filardi P, Pace L, Prastaro M, Piscione F, Betocchi S, Squame F, Vezzuto P, Soricelli A, Indolfi C, Salvatore M, Chiariello M. Dobutamine echocardiography predicts improvement of hypoperfused dysfunctional myocardium after revascularization in patients with coronary artery disease. *Circulation* 1995; 91: 2556–2565.
 33. Baer FM, Voth E, Deutsch HJ, Schneider CA, Schicha H, Sechtem U. Assessment of viable myocardium by dobutamine transesophageal echocardiography and comparison with fluorine-18 fluorodeoxyglucose positron emission tomography. *J Am Coll Cardiol* 1994; 24: 343–353.
 34. Bisi G, Sciagrà R, Santoro GM, Briganti V, Leoncini M, Fazzini PF. Evaluation of coronary artery disease extent using ^{99m}Tc-sestamibi: comparison of dipyridamole versus exercise and of planar versus tomographic imaging. *Nucl Med Commun* 1993; 14: 946–954.
 35. McGhie AI, Weyman A. Searching for hibernating myocardium: time to reevaluate investigative strategies? *Circulation* 1996; 94: 2685–2688.
 36. Bonow RO. Identification of viable myocardium. *Circulation* 1996; 94: 2674–2680.
 37. Beller GA. Comparison of ²⁰¹Tl scintigraphy and low-dose dobutamine echocardiography for the noninvasive assessment of myocardial viability. *Circulation* 1996; 94: 2681–2684.