



UNIVERSITÀ
DEGLI STUDI
FIRENZE

FLORE

Repository istituzionale dell'Università degli Studi di Firenze

Detecting myocardial salvage after primary PTCA: early myocardial contrast echocardiography versus delayed Sestamibi perfusion

Questa è la Versione finale referata (Post print/Accepted manuscript) della seguente pubblicazione:

Original Citation:

Detecting myocardial salvage after primary PTCA: early myocardial contrast echocardiography versus delayed Sestamibi perfusion imaging / R. SCIAGRA'; BOLOGNESE L; ROVAI D; SESTINI S; SANTORO GM; CERISANO G; MARINI C; BUONAMICI P; ANTONIUCCI D; FAZZINI; PF.. - In: THE JOURNAL OF NUCLEAR MEDICINE. - ISSN 0161-5505. - STAMPA. - 40:(1999), pp. 363-370.

Availability:

This version is available at: 2158/222308 since:

Publisher:

Society of Nuclear Medicine:1850 Samuel Morse Drive:Reston, VA 20190:(703)708-9001, EMAIL:

Terms of use:

Open Access

La pubblicazione è resa disponibile sotto le norme e i termini della licenza di deposito, secondo quanto stabilito dalla Policy per l'accesso aperto dell'Università degli Studi di Firenze (<https://www.sba.unifi.it/upload/policy-oa-2016-1.pdf>)

Publisher copyright claim:

(Article begins on next page)

Detecting Myocardial Salvage After Primary PTCA: Early Myocardial Contrast Echocardiography Versus Delayed Sestamibi Perfusion Imaging

Roberto Sciagrà, Leonardo Bolognese, Daniele Rovai, Stelvio Sestini, Giovanni M. Santoro, Giampaolo Cerisano, Cecilia Marini, Piergiorgio Buonamici, David Antonucci and Pier Filippo Fazzini

Nuclear Medicine Unit, Department of Clinical Physiopathology, University of Florence, Florence; Division of Cardiology, Careggi Hospital, Florence; and CNR Clinical Physiology, Pisa, Italy

The extent of myocardial salvage after primary percutaneous transluminal coronary angioplasty (PTCA) in acute myocardial infarction (AMI) is variable and cannot be predicted on the basis of either vessel patency or early regional wall motion assessment. The aim of this study was to evaluate the reliability of microvascular integrity, as shown by myocardial contrast echocardiography (MCE), as an indicator of tissue salvage and a predictor of late functional recovery, and to compare MCE with the quantification of tracer activity in sestamibi perfusion imaging. **Methods:** Twenty-six patients with AMI who received successful treatment with primary PTCA were examined with MCE during cardiac catheterization immediately before and after vessel recanalization. Myocardial contrast effect was scored as 0 (absent), 0.5 (partial) or 1 (normal). Wall motion was assessed by two-dimensional echocardiography on admission and 1 mo later with a 16-segment model and 4-point score. Resting sestamibi SPECT was collected within 1 wk after AMI. The risk area was defined by MCE as the sum of the segments with no perfusion (score 0) before PTCA. Myocardial viability was defined by MCE as an increase in contrast score in the same segments after PTCA and by sestamibi SPECT as a preserved tracer activity (>60% of peak activity). The functional recovery after 1 mo detected by two-dimensional echocardiography was the reference standard for viability. **Results:** A total of 50 segments showed perfusion defects before PTCA (risk area). Immediately after PTCA, the MCE score increased in 44 of 50 segments, whereas sestamibi SPECT showed preserved activity in 22 of 50 segments. After 1 mo, the wall motion score decreased in 22 of 50 segments (viable segments) and was unchanged in the remaining 28 segments. Thus, MCE showed a sensitivity of 91% and a specificity of 14% in detecting viable myocardium, whereas sestamibi SPECT showed a lower sensitivity (68%) but a significantly higher specificity (75%; $P < 0.00001$). The positive predictive values were 45% and 68% for MCE and SPECT ($P < 0.005$), respectively, and the negative predictive values were 67% and 71%, respectively. On a patient basis, SPECT was more specific (79% versus 21%; $P < 0.01$) and showed a higher overall

predictive accuracy (88% versus 50%; $P < 0.01$) than MCE. **Conclusion:** The demonstration of microvascular integrity by MCE performed immediately after primary PTCA has a limited diagnostic value in predicting salvaged myocardium. Conversely, tracer activity quantification in resting sestamibi SPECT performed in a later stage is confirmed to be a reliable approach for recognizing myocardial stunning and predicting functional recovery.

Key Words: myocardial contrast echocardiography; acute myocardial infarction; percutaneous transluminal coronary angioplasty; sestamibi

J Nucl Med 1999; 40:363-370

In patients with acute myocardial infarction (AMI) and early hospital admission, primary percutaneous transluminal coronary angioplasty (PTCA) usually allows prompt restoration of coronary blood flow to the jeopardized myocardium. However, the angiographic demonstration of vessel patency after the procedure does not necessarily imply effective reflow (1-3) or actual myocardial salvage within the infarcted area (3,4). Furthermore, because of myocardial stunning, regional wall motion abnormalities persist, despite early recanalization (5). Therefore, various imaging techniques have been proposed to assess the effectiveness of myocardial reperfusion in acute infarction.

Two main approaches are currently used to this aim (5). The first is based on the prediction of late functional recovery of asynergic regions by means of their response to inotropic stimuli, mainly by using low-dose dobutamine echocardiography (6-8). The other is based on the demonstrated relationship between recognition of tissue viability in dysfunctional segments and subsequent spontaneous recovery (6,9-13). The assessment of myocardial viability may be performed with metabolic imaging with PET (6,10), but myocardial perfusion imaging with single-photon tracers is the more frequently used technique (9,11-13). In particular, ^{99m}Tc -sestamibi myocardial perfusion imaging has been

Received Apr. 3, 1998; revision accepted Jul. 10, 1998.

For correspondence or reprints contact: Roberto Sciagrà, MD, Nuclear Medicine Unit, Department of Clinical Physiopathology, University of Florence, Viale Morgagni 85, 50134 Florence, Italy.

extensively used in this field, mainly because of the possibility to directly evaluate the extent of tissue salvage by comparing pre-reperfusion and post-reperfusion images (11–13).

Recently, myocardial contrast echocardiography (MCE) has been introduced as a new method to assess microvascular integrity (1–3,14–18). The demonstration of microvascular integrity within an infarcted area has been found to be a requisite of tissue viability, and consequently, a possible indirect sign of effective reperfusion and a potential predictor of late functional recovery (14–16). At present, the main limitation to the widespread use of MCE is the need to inject the contrast agent in the coronary artery. However, in the setting of primary PTCA, which requires the execution of left heart catheterization, this does not represent an obstacle to the use of MCE. On the contrary, the possibility of estimating the results of primary PTCA directly during the same catheterization session would be a major advantage over the above mentioned techniques that may be used with some delay after vessel reopening (1,4).

Previous data suggested a good agreement between MCE and sestamibi SPECT for the evaluation of myocardial perfusion in chronic coronary artery disease (CAD) (19). The aim of this study was to evaluate the diagnostic reliability of microvascular integrity by MCE performed immediately after vessel recanalization in detecting the presence of effective tissue reperfusion in AMI treated by primary PTCA and predicting late functional recovery of stunned salvaged myocardium. Furthermore, we compared MCE results with the assessment of myocardial viability obtained from the quantification of tracer uptake in resting sestamibi SPECT.

MATERIALS AND METHODS

Patient Population

The patient population included 26 patients with AMI (22 men, 4 women; mean age 57 ± 12 y) who were admitted to our coronary care unit within 6 h of symptom onset (mean 137 ± 72 min, range 30–300 min) and referred to the catheterization laboratory for emergency primary PTCA. In all patients, the diagnosis of AMI was based on the presence of typical chest pain for >30 min associated with >0.1 mV S-T segment elevation in at least two contiguous electrocardiographic (ECG) leads. Other inclusion criteria were total occlusion of the infarct-related artery, successful primary PTCA (defined as thrombolysis in myocardial infarction [TIMI] trial flow grade 3 and residual stenosis <30% of lumen diameter) and willingness to participate in the study. Patients were excluded in the case of clinical instability or cardiogenic shock and if the echocardiographic window was inadequate for satisfactory visualization of the entire left ventricular wall. In particular, 2 of 28 otherwise potentially eligible patients had to be excluded from the study cohort according to this last criterion.

Study Protocol

The study protocol included the acquisition of MCE (a) during acute coronary occlusion, immediately after diagnostic coronary angiography and (b) immediately after successful completion of primary PTCA. Two-dimensional echocardiography to evaluate regional wall motion was performed at patient admission and was

repeated 1 mo later to assess the functional outcome. Resting sestamibi SPECT was performed at a mean of 6.5 ± 1.2 d (range 4–9 d) after index infarction. The ethics committee of our institution approved the study protocol.

Myocardial Contrast Echocardiography

The studies were collected immediately before PTCA and after completion of the procedure with the patients lying in the supine position, using commercially available imaging systems (SSD-830 2.5- and 3.5-MHz transducers [Aloka Co., Tokyo, Japan] and Sonos 2500 2.5-MHz transducer [Hewlett-Packard Co., Andover, MA]). MCE was performed by injecting 3 mL hand-agitated iopamidol, followed by a 3-mL saline flush directly into the left main and right coronary ostia through the standard catheter used for diagnostic angiography (14,20). The echocardiographic view that best visualized the most asynergic wall was identified before contrast medium injection, the most appropriate gain setting was chosen and both were kept unchanged throughout the study. Image collection began immediately before contrast medium injection and ended approximately 3 min later. All images were recorded on videotape for later analysis. Continuous 12-lead ECG monitoring was performed during the whole procedure.

Two-Dimensional Echocardiography

Regional wall motion was evaluated at the time of admission in the coronary care unit and 1 mo later. In both instances, the patients were studied in left lateral decubitus, with a commercially available scanner (Aloka SSD 870 2.5- and 3.5-MHz transducers). All standard views were acquired and recorded on videotape for off-line evaluation.

Sestamibi SPECT

The tracer dose was 20–25 mCi (740–925 MBq) and was injected into the resting patient lying supine. Images were collected 60 min later with a single-head, large-field-of-view tomographic gamma camera equipped with an ultra-high-resolution collimator, and with a 20% window centered on the 140-keV photopeak of ^{99m}Tc . Sixty projections of 20 s each were acquired. Image reconstruction was performed with filtered backprojection. No attenuation or scatter correction was used. The transaxial slices were realigned along the heart axis. For the quantitative evaluation of SPECT images, the short-axis slices from the first with apical activity to the last with activity at the base were used. Their count profiles were generated by computer software and plotted onto a two-dimensional volume-weighted polar map, which was then divided into 16 segments, matching the echocardiographic ones. With an automated procedure, segment tracer activity was calculated as the total of the normalized counts of the pixels included within the segment divided by the pixel number. The segment with maximal activity was then normalized to 100 and the activity of the other segments was expressed as a percentage of the peak activity segment (21).

Data Analysis

For the analysis of the echocardiographic images, a 16-segment model was adopted (22). Anterior and inferior infarct zones were defined, both including 9 segments (7). Taking into account the infarct-related vessel, the appropriate infarct zone for each patient was identified. In each examined segment within the infarct zone, the myocardial contrast effect was scored visually by three blinded observers, using a 3-point scheme: 0 = no visible contrast effect, i.e., no apparent perfusion; 0.5 = patchy contrast effect or enhancement of the epicardial layer only, i.e., reduced perfusion;

and 1 = homogeneous contrast effect in the entire myocardial wall, i.e., normal perfusion (15,18). In case of disagreement between the observers, consensus was established by the majority. Wall motion was assessed with a 4-point scoring scheme: 1 = normal wall motion, 2 = hypokinesia, 3 = akinesia and 4 = dyskinesia (22). Two experienced observers blinded to all other information performed the scoring. Discrepancies were resolved by consensus agreement. Previous studies in our laboratory demonstrated high levels of intraobserver and interobserver reproducibility of echocardiographic scoring both as regards MCE and wall motion assessment (23).

Criteria for Myocardial Viability

The perfusion risk area was defined by the segments with absent perfusion (score 0 in pre-PTCA MCE) included within the infarct zone. Only the segments included within the perfusion risk area were considered for follow-up evaluation of regional function and a significant wall motion improvement was defined as a ≥ 1 point decrease in segment wall motion score between admission and follow-up. For the patient analysis, a patient was considered improved on follow-up echocardiography if the wall motion score decreased ≥ 1 point in at least 2 contiguous segments. For the MCE definition of myocardial viability, a segment was considered to be viable if it showed either grade 1 or grade 0.5 contrast effect in the post-PTCA study. On a patient basis, MCE was considered to demonstrate viability if at least half of the segments included in the patient's perfusion risk area showed improved perfusion in the post-PTCA study. For the SPECT definition of myocardial viability, a percentage activity $>60\%$ of peak was required (24,25). For the patient analysis, the mean activity value in the segments included within the perfusion risk area was considered by using the same $>60\%$ cutoff.

Statistical Analysis

Data are expressed as appropriate as the mean \pm SD. The comparisons of continuous variables within and between groups were performed with 2-way analysis of variance (ANOVA) for repeated measures, with the Tukey post-hoc test. The comparison between groups of ordinal variables was made with nonparametric ANOVA (Kruskal-Wallis rank test). The comparison of proportion was made with the Fisher exact test. P value < 0.05 was considered statistically significant.

RESULTS

General Findings

The ECG changes of AMI involved the anterior leads in 14 patients and the inferior leads in 12. The infarct-related artery was the left anterior descending in 14 patients, the left circumflex in 2 and the right coronary artery in 10 patients. A total of 15 patients were affected by single-vessel CAD, 10 by two-vessel CAD and 1 by three-vessel CAD. The echocardiographic left ventricular ejection fraction on admission was $43\% \pm 10\%$. Primary PTCA was successful in all patients and was performed without complications. The peak creatine phosphokinase release reached 3162 ± 1986 IU.

Myocardial Contrast Echocardiography During Coronary Occlusion

Because the analysis of MCE images was limited to one cross-sectional view, only 96 segments among the 234 infarct zone segments could be evaluated by MCE during coronary occlusion. Before PTCA, 40 segments showed a homogeneous contrast effect (score 1), 6 segments showed a partial contrast effect (score 0.5) and 50 no apparent contrast effect (score 0). All 50 segments were considered to constitute the area of myocardium at risk and all showed wall motion abnormalities at the two-dimensional echocardiography on admission (wall motion score 3 ± 0.3 , range 2–4). Two patients did not show any segment with score 0 before PTCA, but only segments with partial contrast effect. The remaining 24 patients had 1–3 segments with score 0, with a mean of 1.9 ± 1 .

Myocardial Contrast Echocardiography After Primary PTCA

Immediately after completion of primary PTCA, a homogeneous contrast effect was observed in 34 segments. In 10 additional segments within the risk area, MCE showed an incomplete contrast effect after PTCA. Thus, a total of 44 segments were defined viable by post-PTCA MCE. Finally, 6 segments did not show any apparent contrast enhancement despite the recanalization of the infarct-related artery (Fig. 1).

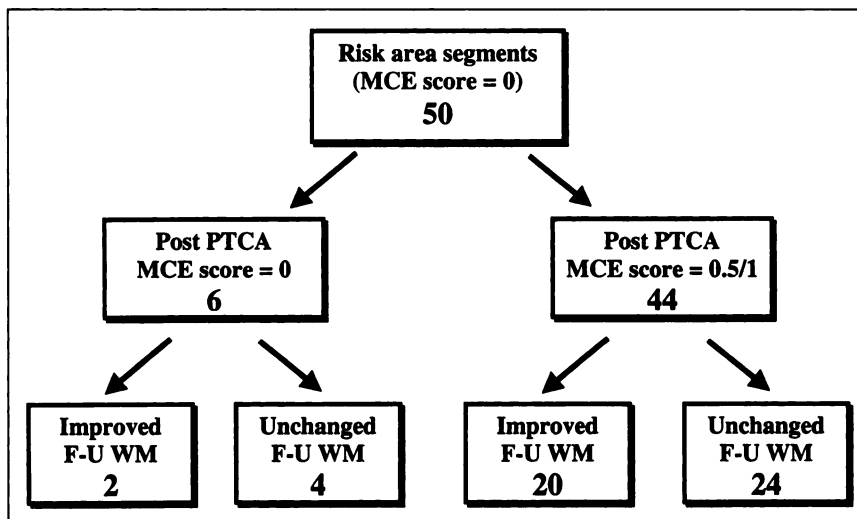


FIGURE 1. Diagram shows myocardial contrast echocardiography (MCE) score changes in perfusion risk area segments and their relationship with functional outcome assessed using wall motion (WM) evolution on follow-up (F-U) echocardiography.

Of the 24 patients with perfusion defects during coronary occlusion, 17 showed a significant improvement in myocardial perfusion after PTCA, whereas 7 did not show any significant change in MCE findings.

Sestamibi SPECT

The mean tracer activity in the 96 segments evaluated with MCE was $65\% \pm 19\%$. No segments with abnormal sestamibi uptake were observed outside the infarct zone. In the 50 segments constituting the MCE risk area, the tracer activity was $61\% \pm 20\%$ (range 23.5%–100%). More specifically, the tracer activity was $>60\%$ in 22 segments (defined as viable) and less than this threshold in 28 segments. On a patient basis, 13 patients showed a mean activity in the perfusion risk area $>60\%$, and 11 a value below this cutoff.

Follow-up Evaluation

One month after AMI, all patients were catheterized and all showed a patent infarct-related artery. The echocardiographic left ventricular ejection fraction was $50\% \pm 11\%$ ($P < 0.01$ versus admission). On the follow-up echocardiogram, 22 segments of the 50 included in the perfusion risk area showed functional recovery, whereas 28 had an unchanged wall motion abnormality (Fig. 1). In terms of patients, 10 showed a recovery in wall motion and 14 did not.

Early Myocardial Contrast Echocardiography and Myocardial Viability

The post-PTCA MCE scoring was not significantly different in the group of viable versus that of nonviable segments ($P = 0.89$). Table 1 summarizes the results of the segment analysis. On the basis of the above data, MCE performed shortly after primary PTCA showed a sensitivity of 91% and a specificity of 14% in detecting viable segments. The positive and negative predictive values of MCE were 45% and 67%, respectively. On a patient basis, MCE had a specificity of 21% and an overall predictive accuracy of 50% (Table 2).

Sestamibi Imaging and Myocardial Viability

A significant difference was observed in the sestamibi activity between the segments, which improved after 1 mo

TABLE 1
Diagnostic Reliability of Reflow in Myocardial Contrast Echocardiography (MCE) and of Activity $>60\%$ in Sestamibi SPECT to Identify Segments with Stunned Myocardium Within Perfusion Risk Area

	MCE		Sestamibi SPECT	
	Segments	%	Segments	%
Sensitivity	20/22	91	15/22	68
Specificity	4/28	14	21/28	75
Positive predictive value	20/44	45	15/22	68
Negative predictive value	4/6	67	21/28	71
Accuracy	24/50	48	36/50	72

TABLE 2
Diagnostic Reliability of Reflow in Myocardial Contrast Echocardiography (MCE) and of Activity $>60\%$ in Sestamibi SPECT to Identify Patients with Stunned Myocardium Within Perfusion Risk Area

	MCE		Sestamibi SPECT	
	Patients	%	Patients	%
Sensitivity	9/10	90	10/10	100
Specificity	3/14	21	11/14	79
Positive predictive value	9/20	45	10/13	77
Negative predictive value	3/4	75	11/11	100
Accuracy	12/24	50	21/24	88

(viable) and those permanently asynergic: ($71.8\% \pm 17.6\%$ versus $51.5\% \pm 17\%$, respectively; $P < 0.0005$) (Fig. 2). The results of segment analysis are shown in Table 1 and those of patient analysis in Table 2. Sestamibi SPECT showed a sensitivity of 68%, a specificity of 75% ($P < 0.00001$ versus MCE) and an overall accuracy of 72% ($P < 0.03$ versus MCE) (Fig. 3). The positive and negative predictive values of SPECT were 68% and 71%, respectively, and the former was higher than that of MCE ($P < 0.005$) (Fig. 3). On a patient basis, delayed SPECT was more specific (79%; $P < 0.01$) and showed a higher overall predictive accuracy (88%; $P < 0.01$) than MCE (Fig. 4). We also tested the use of the $>50\%$ threshold to define segment viability: In segment analysis this increased SPECT sensitivity to the same level of MCE (91%) and decreased its

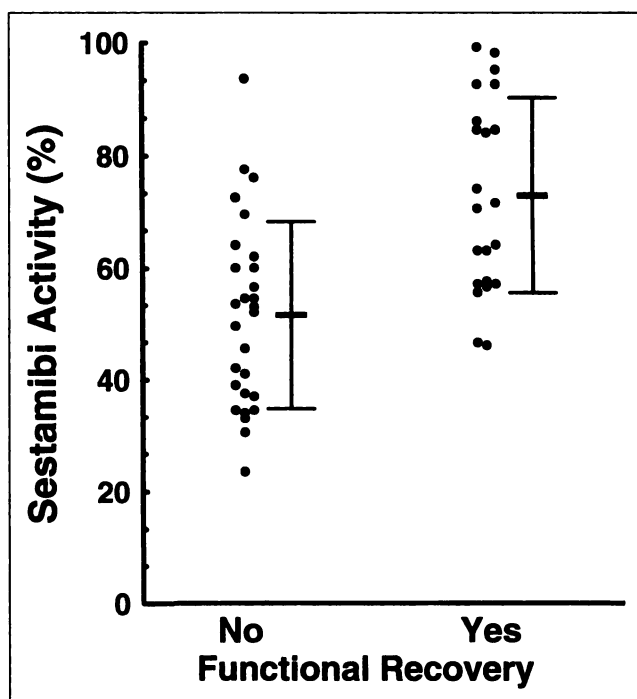


FIGURE 2. Scatterplot of sestamibi activity in perfusion risk area segments divided according to presence or absence of functional recovery in follow-up echocardiography. Individual data points and mean \pm SD are shown.

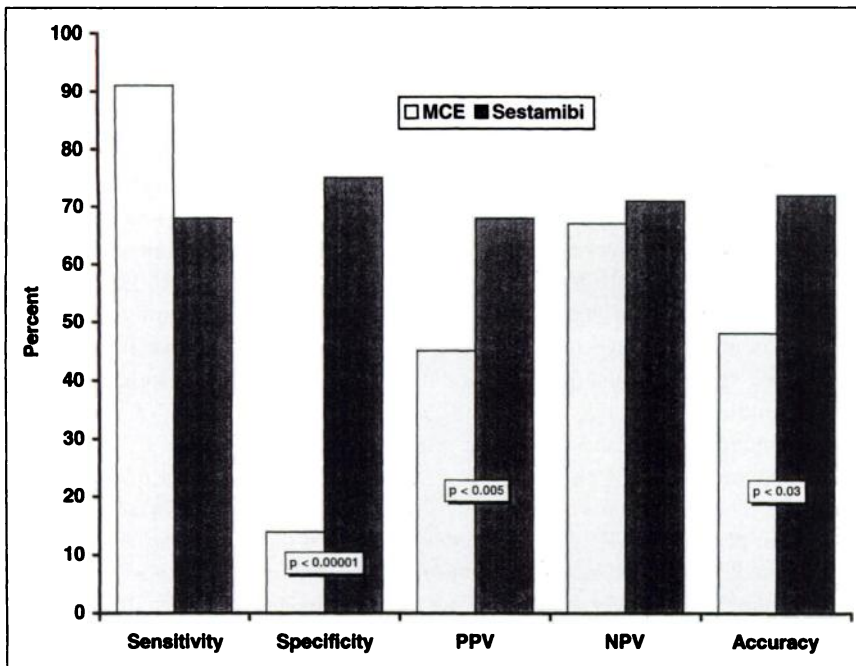


FIGURE 3. Bar graph compares on segment basis results of MCE and those of sestamibi SPECT in identification of myocardial salvage.

specificity to 57% ($P < 0.002$ versus MCE), so that overall accuracy did not change.

DISCUSSION

MCE has been recently introduced as a very attractive method for the evaluation of myocardial perfusion and the demonstration of microvascular integrity (1,14-18,26). MCE is based on the visualization of the contrast effect produced during the passage of an intravascular ultrasonic contrast medium, such as microbubbles, through the ventricular wall (26). The presence of a contrast effect has been demonstrated to depict the spatial distribution of microvascular

perfusion and therefore implies preserved microvascular integrity (1-3,14-18). In the setting of AMI treated with reperfusion with either thrombolysis or primary PTCA, MCE allowed the identification of the so-called no-reflow phenomenon, which accounts for the discrepancy between the achievement of vessel patency and tissue salvage (1-4). This phenomenon has been demonstrated in a variable, but usually low proportion of patients undergoing primary PTCA, and, accordingly, the absence of perfusion in MCE has been shown to imply the lack of functional recovery of the involved region (1,3,16,18). Conversely, other data suggest the possibility of identifying the presence of cellular

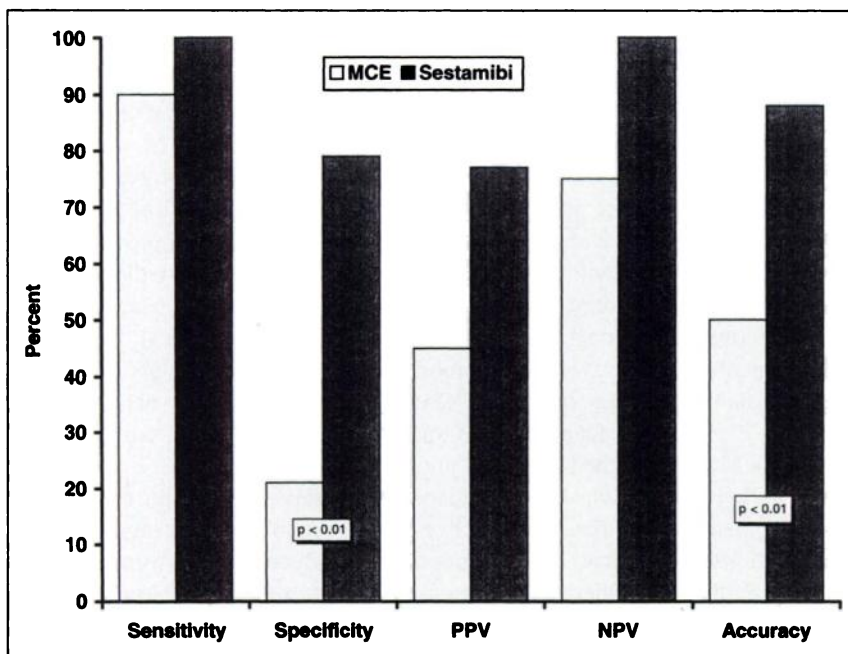


FIGURE 4. Bar graph compares on patient basis results of MCE and those of sestamibi SPECT in identification of myocardial salvage.

integrity and, thus, of myocardial salvage in patients with myocardial infarction by means of the recognition of microvascular integrity obtained by using MCE. In particular, Ragosta et al. (15) demonstrated the relationship between microvascular and myocellular integrity in patients studied during the subacute phase of myocardial infarction. Agati et al. (16) reported that residual perfusion within segments with abnormal function may imply a further reduction in ventricular dysfunction in a later phase. Lim et al. (17), however, by studying patients both before and after recanalization, observed that many of those with contrast enhancement immediately after reperfusion did not show signs of myocardial salvage in the long term. Similarly, Camarano et al. (18) registered the absence of functional recovery in almost half of the segments with homogeneous contrast effect after previous myocardial infarction. Therefore, although the unfavorable implications of absent perfusion after vessel reopening appear quite established, the meaning of perfusion restoration seems more uncertain.

At present, the most important obstacle to the use of MCE is the need for intracoronary injection of the contrast medium. This limitation is not applicable to the use of MCE in combination with primary PTCA. On the contrary, the possibility to obtain immediate information about tissue perfusion without the need of additional tests would be highly desirable, because the currently used methods to detect salvaged myocardium are generally performed in a later phase after the recanalization procedure (1,4). Previous data from our group, however, suggest that low-dose dobutamine echocardiography is significantly more effective than MCE for the prediction of functional recovery of infarct areas in patients who received treatment with primary PTCA (23). The different signal explored by the two techniques (contractile reserve versus microvascular integrity) could partly explain these discrepancies. Regarding the comparison of MCE with myocardial perfusion scintigraphy, prior data showed a good correlation between MCE and sestamibi SPECT in patients with chronic CAD studied at rest, indicating the relative equality of the two methods in depicting resting myocardial perfusion (19). However, differences between the two methods could be expected in other settings, taking into account that MCE agents are pure flow tracers, whereas sestamibi uptake is also significantly influenced by myocardial viability (27–29). In this study, we tested the reliability of MCE for the detection of stunned salvaged tissue and the prediction of late functional recovery comparing MCE demonstration of reflow with the evaluation of viability according to the quantification of sestamibi activity in perfusion SPECT.

According to our results, an absent contrast effect in MCE performed immediately after primary PTCA was followed by the lack of functional recovery in most segments. Conversely, the detection of reperfusion in post-PTCA MCE did not necessarily imply the presence of myocardial salvage, as shown by the very low predictive value of the positive result. These unsatisfactory results were fully

replicated when the analysis was performed on a patient instead of on a segment basis. Regarding the comparison with sestamibi perfusion imaging, both the segment and the patient analysis showed a significant superiority of the latter technique over MCE in terms of both specificity and overall accuracy, without significant loss in sensitivity. These data suggest that the demonstration of reperfusion and microvascular integrity obtained immediately after primary PTCA with MCE does not imply the subsequent detection of activity levels in the viability range on sestamibi perfusion imaging and, more importantly, late functional recovery. Thus, the early finding of preserved microvascular integrity cannot always be assimilated to the proof of ultimately preserved cellular integrity.

With regard to sestamibi SPECT, the data of this study support its use for the assessment of tissue viability after AMI (5,30). More specifically, the execution of a single post-revascularization study, including the assessment of tracer uptake and the use of a threshold value to differentiate viable from nonviable myocardium, appears to be an easy and effective approach to the recognition of stunned myocardium in asynergic segments and to the prediction of a patient's functional outcome (25,30). Unlike the execution of both pre- and post-revascularization imaging, this approach can be easily performed in almost every nuclear medicine laboratory (30). Furthermore, the effectiveness of a threshold about 60% of peak activity confirms what has been shown in patients who were studied for myocardial viability in chronic CAD (21,24).

Various possible explanations can be invoked to account for the low accuracy of MCE. Certainly, the time interval between MCE and sestamibi SPECT in our protocol precludes a straight comparison of the two techniques in terms of tissue perfusion assessment. The possible interference of reperfusion hyperemic flow on MCE performed immediately after vessel reopening and in the absence of flow-limiting residual obstruction is probably an important factor to explain the low specificity of MCE (31,32). More in general, the possibility of a temporal dissociation between microvascular and cellular damage should be considered (33,34). Recently, a possible role of intramyocardial hemorrhage was suggested to explain the delayed appearance of MCE defects and the lack of functional improvement in patients with MCE evidence of reflow immediately after primary PTCA (35). The availability in the near future of contrast agents that can be injected intravenously will solve many of these problems, because MCE might easily be repeated after PTCA, when the hyperemic response has subsided and both microvascular and cellular damage have reached their final and full extent.

Subsequent evidence of preserved sestamibi uptake and late functional recovery was seen in segments (and patients) without MCE signs of early effective reperfusion. This is another important observation of this study, but one that is more difficult to interpret. A possible explanation might be that flow restoration could be slower in some cases (36–38).

Also in this case, the availability of intravenous contrast agents and the possibility to perform repeated evaluations will probably improve the diagnostic power of MCE. Technical problems could also be invoked, however, given the need to perform the MCE study acquisition with the patient lying supine and the limited number of adequately visualized segments.

The small patient population and the scanty number of evaluated segments are the first major limitations of this study. Another important limitation derives from the timing of MCE and SPECT in this protocol. We already noted that the time interval between the two investigations precludes their direct comparison in terms of perfusion assessment. On the other hand, both methods were applied at their most convenient time points, i.e., MCE immediately during the PTCA catheterization session and SPECT in a later phase, when patient conditions are stable and execution of radionuclide studies is simplest. In this study, the rationale of the use of both methods was not to identify which patients should undergo PTCA, but to evaluate the effectiveness of the procedure in terms of functional recovery. In particular, we did not use sestamibi SPECT to directly identify the salvaged area through the comparison between pre- and post-revascularization images, as previously performed by our group and by other investigators (11–13). However, both the rationale of a single post-revascularization study performed immediately after thrombolysis (39) and the high informative content of the pre-discharge assessment of myocardial perfusion (25,30) have already been indicated. The late execution of post-revascularization scintigraphy is reasonable to obtain the most reliable estimate of final infarct size and the best prediction of the patient's final outcome (30). At last, delayed perfusion imaging appears particularly acceptable in those patients in whom further revascularization procedures cannot be considered because of the optimal angiographic result of primary PTCA. Therefore, the comparison of MCE and sestamibi SPECT in this protocol makes sense in terms of clinical usefulness and reliability. Naturally, no data can be derived from this study about the role of sestamibi SPECT in patients with acute chest pain. The very early acquisition time of the post-PTCA MCE images was also already mentioned as a possible limitation because of the problems related to the post-reperfusion hyperemia. The administration of dipyridamole to increase coronary flow in the other territories and, therefore, to compensate for the hyperemia in the infarcted region has been proposed (4,40). So far, however, there are no data to support the real usefulness of this approach, which may also pose hazards and logistic complications. Furthermore, most recent data based on intracoronary Doppler flow measurements and on PET imaging in patients who received treatment with primary PTCA indicate that coronary reserve may be depressed even in the non-infarct-related vessels (41). This circumstance could limit the potential usefulness of dipyridamole administration to counterbalance the reperfusion hyperemia of the infarct region. The difficulty of

perfectly matching the segments in MCE and two-dimensional echocardiography was also mentioned. It is hard to believe, however, that these difficulties were larger than those potentially existing in the comparison between two different imaging modalities such as two-dimensional echocardiography and SPECT (19), and which were certainly also present in this study cohort. Furthermore, it must be considered that MCE is also affected by the common limitations to echocardiography in patients with suboptimal ultrasonic window. The adopted threshold for the definition of viability in sestamibi images was arbitrary, although supported by previous studies (24,25). The small dimensions of the study sample did not allow a systematic analysis of the most optimal cutoff value. However, when another widely adopted threshold was considered (>50% of peak activity), the superiority of SPECT over MCE was maintained, with an increase in sensitivity, a decrease in specificity and the same overall accuracy as using the >60% cutoff. Finally, it is undeniable that the detection of functional recovery at the 1-mo follow-up control is just an imperfect reference standard for myocardial viability: More delayed improvement cannot be excluded, and other parameters of preserved viability, such as prevention of ventricular remodeling, could be considered (42,43).

CONCLUSION

This study suggests that early demonstration of reflow in MCE performed during the same catheterization session has a limited value as a routine diagnostic tool to assess the effectiveness of primary PTCA in terms of tissue salvage. This is confirmed by comparing its results with the later quantification of myocardial viability achieved using sestamibi SPECT. With regard to this last technique, this study supports its role for the evaluation of myocardial viability in AMI. In particular, the quantitative assessment of tracer uptake using an activity threshold is able to give a useful estimate of myocardial viability and an effective prediction of subsequent functional recovery of stunned myocardium independently of the comparison of pre- and post-revascularization images.

REFERENCES

1. Ito H, Tomooka T, Sakai N, et al. Lack of myocardial perfusion immediately after successful thrombolysis. A predictor of poor recovery of left ventricular function in anterior myocardial infarction. *Circulation*. 1992;85:1699–1705.
2. Kenner MD, Zajac EJ, Kondos GT, et al. Ability of the no-reflow phenomenon during an acute myocardial infarction to predict left ventricular dysfunction at one-month follow-up. *Am J Cardiol*. 1995;76:861–868.
3. Ito H, Okamura A, Iwakura K, et al. Myocardial perfusion patterns related to thrombolysis in myocardial infarction perfusion grades after coronary angioplasty in patients with acute anterior myocardial infarction. *Circulation*. 1996;93:1993–1999.
4. Kaul S, Villanueva FS. Is the determination of myocardial perfusion necessary to evaluate the success of reperfusion when the infarct-related artery is open? *Circulation*. 1992;85:1942–1944.
5. Dilsizian V, Bonow RO. Current diagnostic techniques of assessing myocardial viability in patients with hibernating and stunned myocardium. *Circulation*. 1993; 87:1–20.
6. Pierard LA, De Landsheere CM, Berthe C, et al. Identification of viable myocardium by echocardiography during dobutamine infusion in patients with

- myocardial infarction after thrombolytic therapy: comparison with positron emission tomography. *J Am Coll Cardiol.* 1990;15:1021-1031.
7. Smart SC, Sawada S, Ryan T, et al. Low-dose dobutamine echocardiography detects reversible dysfunction after thrombolytic therapy of acute myocardial infarction. *Circulation.* 1993;88:405-415.
 8. Watada H, Ito H, Oh H, et al. Dobutamine stress echocardiography predicts reversible dysfunction and quantitates the extent of irreversibly damaged after reperfusion of anterior myocardial infarction. *J Am Coll Cardiol.* 1992;24:624-630.
 9. Maddahi J, Ganz W, Ninomiya K, et al. Myocardial salvage by intracoronary thrombolysis in evolving myocardial infarction: evaluation using intracoronary injection of thallium-201. *Am Heart J.* 1981;102:664-674.
 10. Schwaiger M, Brunken R, Grover-McKay M, et al. Regional myocardial metabolism in patients with acute myocardial infarction assessed by positron emission tomography. *J Am Coll Cardiol.* 1986;8:800-808.
 11. Wackers FJ, Gibbons RJ, Verani MS, et al. Serial quantitative planar technetium-99m isonitrite imaging in acute myocardial infarction: efficacy for noninvasive assessment of thrombolytic therapy. *J Am Coll Cardiol.* 1989;14:861-873.
 12. Santoro GM, Bisi G, Sciarà R, Leoncini M, Fazzini PF, Meldolesi U. Single photon emission computed tomography with technetium-99m hexakis 2-methoxyisobutyl isonitrite in acute myocardial infarction before and after thrombolytic treatment: assessment of salvaged myocardium and prediction of late functional recovery. *J Am Coll Cardiol.* 1990;15:301-314.
 13. Behrenbeck T, Pellikka PA, Huber KC, Bresnahan JF, Gersh BJ, Gibbons RJ. Primary angioplasty in myocardial infarction: assessment of improved myocardial perfusion with technetium-99m isonitrite. *J Am Coll Cardiol.* 1991;17:365-372.
 14. Ito H, Tomooka T, Sakai N, et al. Time course of functional improvement in stunned myocardium in risk area in patients with reperfused anterior infarction. *Circulation.* 1993;87:355-362.
 15. Ragosta M, Camarano G, Kaul S, Powers ER, Sarembock IJ, Gimble LW. Microvascular integrity indicates myocellular viability in patients with recent myocardial infarction. New insights using myocardial contrast echocardiography. *Circulation.* 1994;89:2562-2569.
 16. Agati L, Voci P, Bilotta F, et al. Influence of residual perfusion within the infarct zone on the natural history of left ventricular dysfunction after acute myocardial infarction: a myocardial contrast echocardiographic study. *J Am Coll Cardiol.* 1994;24:336-342.
 17. Lim YJ, Nanto S, Masuyama T, Kohama A, Hori M, Kamada T. Myocardial salvage: its assessment and prediction by the analysis of serial myocardial contrast echocardiograms in patients with acute myocardial infarction. *Am Heart J.* 1994;128:649-656.
 18. Camarano G, Ragosta M, Gimble LW, Powers ER, Kaul S. Identification of viable myocardium with contrast echocardiography in patients with poor left ventricular systolic function caused by recent or remote myocardial infarction. *Am J Cardiol.* 1995;75:215-219.
 19. Meza MF, Mobarek S, Sonnemaker R, et al. Myocardial contrast echocardiography in human beings: correlation of resting perfusion defects to sestamibi single photon emission computed tomography. *Am Heart J.* 1996;132:528-535.
 20. Nanto S, Masuyama T, Lim Y, et al. Demonstration of functional border zone with myocardial contrast echocardiography in human hearts. Simultaneous analysis of myocardial perfusion and wall motion abnormalities. *Circulation.* 1993;88:447-453.
 21. Sciarà R, Bisi G, Santoro GM, et al. Comparison of baseline-nitrate technetium-99m-sestamibi with rest-redistribution thallium-201 tomography in detecting viable hibernating myocardium and predicting postrevascularization recovery. *J Am Coll Cardiol.* 1997;30:384-391.
 22. Schiller NB, Shah PM, Crawford M, et al. for the American Society of Echocardiography Committee of Standards, Subcommittee on Quantification of Two-Dimensional Echocardiography. Recommendation for quantification of the left ventricle by two-dimensional echocardiography. *J Am Soc Echocardiogr.* 1989; 5:358-367.
 23. Bolognese L, Antoniucci D, Rovai D, et al. Myocardial contrast echocardiography versus dobutamine echocardiography for predicting functional recovery after acute myocardial infarction treated with primary coronary angioplasty. *J Am Coll Cardiol.* 1996;28:1677-1683.
 24. Udelson JE, Coleman PS, Metherall J, et al. Predicting recovery of severe regional ventricular dysfunction: comparison of resting scintigraphy with ²⁰¹Tl and ^{99m}Tc-sestamibi. *Circulation.* 1994;89:2552-2561.
 25. Christian TF, O'Connor MK, Hopferspirger MR, Gibbons RJ. Comparison of reinjection thallium-201 and resting technetium-99m sestamibi tomographic images for the quantification of the infarct size after acute myocardial infarction. *J Nucl Cardiol.* 1994;1:17-28.
 26. Kaul S, Kelly P, Oliner JD, Glasheen WP, Keller MW, Watson DD. Assessment of regional blood flow with myocardial contrast two-dimensional echocardiography. *J Am Coll Cardiol.* 1989;13:468-482.
 27. Pivnicka-Worms D, Kronauge JF, Chiu ML. Uptake and retention of hexakis (2-methoxyisobutyl isonitrite) technetium(I) in cultured chick myocardial cells. Mitochondrial and plasma membrane potential dependence. *Circulation.* 1990; 82:1826-1838.
 28. Sinusas AJ, Trautman KA, Bergin JD, et al. Quantification of area at risk during coronary occlusion and degree of myocardial salvage after reperfusion with technetium-99m methoxyisobutyl isonitrite. *Circulation.* 1990;82:1424-1437.
 29. Beanlands RSB, Dawood F, Wen W-H, et al. Are the kinetics of technetium-99m methoxyisobutyl isonitrite affected by cell metabolism and viability? *Circulation.* 1990;82:1802-1814.
 30. Christian TF. The use of perfusion imaging in acute myocardial infarction: applications for clinical trials and clinical care. *J Nucl Cardiol.* 1995;2:423-436.
 31. White FC, Sanders M, Bloor CM. Regional distribution of myocardial blood flow after coronary occlusion and reperfusion in the conscious dog. *Am J Cardiol.* 1978;42:234-243.
 32. Kaul S, Pandian NG, Guerrero JL, Gillam LD, Okada RD, Weyman AE. The effects of selectively altering the collateral driving pressure on regional perfusion and function in the occluded coronary bed in the dog. *Circ Res.* 1987;61:77-85.
 33. Olafsson B, Forman MB, Puett DW, et al. Reduction of reperfusion injury in the canine preparation by intracoronary adenosine: importance of the endothelium and the no-reflow phenomenon. *Circulation.* 1987;76:1135-1145.
 34. Kloner RA, Rude RE, Carlson N, Maroko PR, DeBoer LWV, Braunwald E. Ultrastructural evidence of microvascular damage and myocardial cell injury after coronary artery occlusion: which comes first? *Circulation.* 1980;62:945-952.
 35. Anasuma T, Tanabe K, Ochiai K, et al. Relationship between progressive microvascular damage and intramyocardial hemorrhage in patients with reperfused anterior myocardial infarction. *Circulation.* 1997;96:448-453.
 36. Bolli R, Triana JF, Jeroudi MO. Prolonged impairment of coronary vasodilation after reversible ischemia: evidence for microvascular 'stunning.' *Circ Res.* 1990; 67:332-343.
 37. Ito H, Iwakura K, Oh H, et al. Temporal changes in myocardial perfusion patterns in patients with reperfused anterior wall myocardial infarction: their relation to myocardial viability. *Circulation.* 1995;91:656-662.
 38. Neumann F-J, Kósa I, Dickfeld T, et al. Recovery of myocardial perfusion in acute myocardial infarction after successful balloon angioplasty and stent placement in the infarct-related coronary artery. *J Am Coll Cardiol.* 1997;30:1270-1276.
 39. Wackers FJT. Thrombolytic therapy for myocardial infarction: assessment of efficacy by myocardial perfusion imaging with technetium-99m sestamibi. *Am J Cardiol.* 1990;66:36E-41E.
 40. Villanueva FS, Glasheen WP, Sklenar J, Kaul S. Characterization of spatial patterns of flow within the reperfused myocardium using myocardial contrast echocardiography: implications in determining the extent of myocardial salvage. *Circulation.* 1993;88:2596-2606.
 41. Stewart RE, Miller DD, Bowers TR, et al. PET perfusion and vasodilator function after angioplasty for acute myocardial infarction. *J Nucl Med.* 1997;38:770-777.
 42. Beller GA. Comparison of ²⁰¹Tl scintigraphy and low-dose dobutamine echocardiography for the noninvasive assessment of myocardial viability. *Circulation.* 1996;94:2681-2684.
 43. Ito H, Maruyama A, Iwakura K, et al. Clinical implications of the 'no reflow' phenomenon. A predictor of complications and left ventricular remodeling in reperfused anterior wall myocardial infarction. *Circulation.* 1996;93:223-228.