



UNIVERSITÀ  
DEGLI STUDI  
FIRENZE

## FLORE

# Repository istituzionale dell'Università degli Studi di Firenze

### **Early apoptosis plays an important role in the healing mechanism of cutaneous basal cell carcinomas after photodynamic therapy**

Questa è la Versione finale referata (Post print/Accepted manuscript) della seguente pubblicazione:

*Original Citation:*

Early apoptosis plays an important role in the healing mechanism of cutaneous basal cell carcinomas after photodynamic therapy / F. PRIGNANO; B. BIANCHI; L. DOMENICI; R. ROSSI; P. ROMAGNOLI; N. PIMPINELLI; P. CAPPUGI; B. GIANNOTTI. - In: BRITISH JOURNAL OF DERMATOLOGY. - ISSN 0007-0963. - STAMPA. - 149:(2003), pp. 205-206.

*Availability:*

The webpage <https://hdl.handle.net/2158/312905> of the repository was last updated on

*Terms of use:*

Open Access

La pubblicazione è resa disponibile sotto le norme e i termini della licenza di deposito, secondo quanto stabilito dalla Policy per l'accesso aperto dell'Università degli Studi di Firenze (<https://www.sba.unifi.it/upload/policy-oa-2016-1.pdf>)

*Publisher copyright claim:*

La data sopra indicata si riferisce all'ultimo aggiornamento della scheda del Repository FloRe - The above-mentioned date refers to the last update of the record in the Institutional Repository FloRe

(Article begins on next page)

## CORRESPONDENCE

**Bexarotene reverses alopecia in cutaneous T-cell lymphoma**

SIR, Mycosis fungoides (MF) is characterized by clonal helper/memory (CD4+ CD45RO+) T-cells in the epidermis, whereas follicular mucinosis or alopecia mucinosis has perifollicular T-cell infiltrates and may clinically resemble alopecia areata.<sup>1,2</sup> Bexarotene is the first retinoid X receptor (RXR)-selective retinoid shown to be effective for cutaneous T-cell lymphoma.<sup>3,4</sup> Bexarotene has recently been shown to induce T-cell apoptosis *in vitro*.<sup>5</sup> Although bexarotene oral and topical gel are effective for MF, this is the first report, to our knowledge, of reversal of associated alopecia.

Five patients with alopecia secondary to MF or follicular mucinosis were observed among a cohort of over 90 patients receiving bexarotene therapy at the M.D. Anderson Cancer Center. Their demographic data, degree of hair loss, skin biopsy results and drug administration are shown in Table 1. The location of the hair loss was confined to the scalp in four patients and to the extremities in a fifth. All of the skin biopsy specimens revealed atypical CD4+ CD8+ perifollicular lymphocytic infiltrates, and two showed mucin deposits consistent with follicular mucinosis. Three patients had scaling with negative fungal cultures. Patients with early stage MF were treated with topical bexarotene therapy and advanced stage patients with oral bexarotene. The MF as well as the alopecia

improved in all five patients, irrespective of the route of delivery. Hair regrowth began within 2–9 months and full regrowth was evident by 1·5 years.

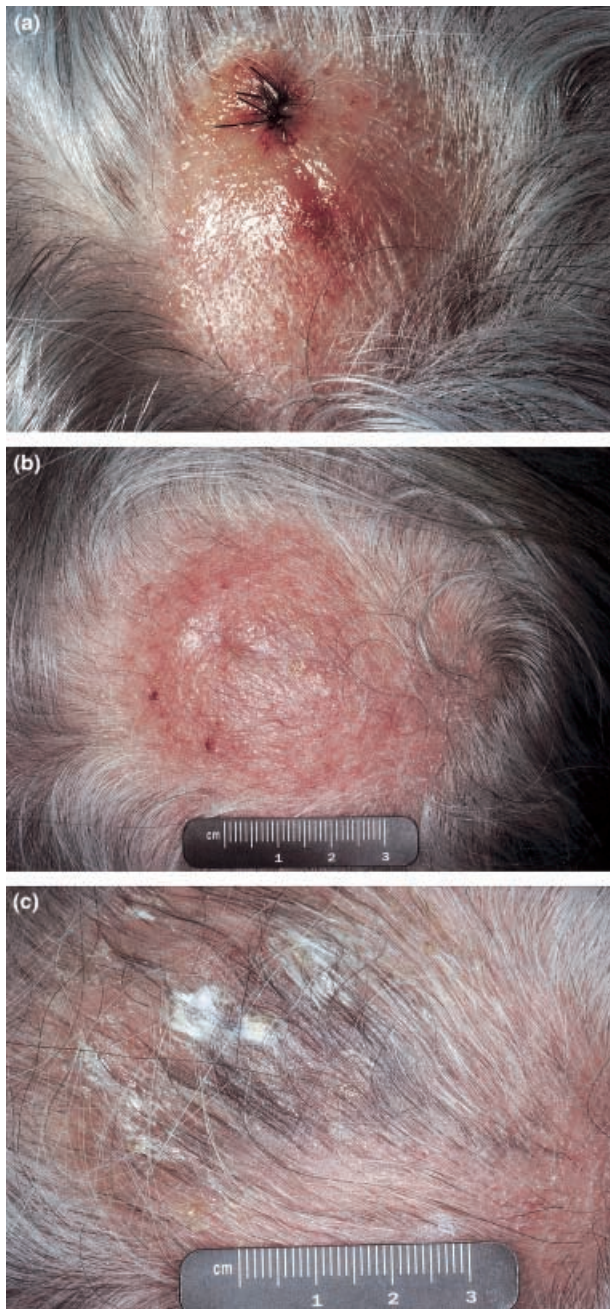
*Patient 1.* A 77-year-old Native American woman presented with a 3-month history of a single patch of alopecia accompanied by pruritus and mild tenderness, generalized xerosis, fatigue and a 4·5-kg unintentional weight loss. Asthma and childhood eczema were noted. There was a 4 × 5 cm alopecia areata-like lesion with scaling on the scalp (Fig. 1a) and macular erythema of less than 1%. An atypical CD4+ CD8– clonal lymphocytic infiltrate and mucin deposits were present in the follicular epithelium. After applying 1% bexarotene gel daily to the leg and scalp lesions, partial hair regrowth was present at 3 months (Fig. 1b), with full regrowth of terminal grey hair covering the former patch of alopecia at 5 months (Fig. 1c).

*Patient 2.* A 64-year-old Hispanic man with dermatitis for 30 years developed generalized exfoliative erythroderma, patchy alopecia, and a skin biopsy consistent with MF. He had increased fatigue, chills, night sweats and intense pruritus. On examination, he had generalized exfoliative erythroderma and lymphadenopathy. On the scalp, multiple round alopecia areata lesions, patches of white hair, and exclamation point hairs were observed (Fig. 2a,b). An atypical CD4+ CD8+ dermal infiltrate with epidermotropism and a clonal T-cell receptor gene rearrangement were observed in

**Table 1.** Response of alopecia to bexarotene therapy in patients with cutaneous T-cell lymphoma

Patient	Race	Age (years)	Stage	Location of alopecia	Description of alopecia	Skin biopsy	TCR gene rearrangement	Bexarotene treatment	Hair regrowth
1	Native American	77	Ia with follicular mucinosis	Scalp	4 × 5 cm patch with fine, white scale	CD4, CD8 perifollicular infiltrate + mucin	Positive	Topical 1% four times daily	Partial (3 months), almost full (5 months), still undergoing treatment
2	Hispanic	64	IVa	Scalp	Patchy with erythema and scale	CD4, CD8 infiltrate with epidermal involvement	Positive	Oral 300 mg m <sup>-2</sup> daily	Partial (9 months), almost full (1·5 years)
3	African American	59	Iib	Scalp	6 × 4 cm, 4 × 2 cm patches with erythema and scale	CD4, CD8 infiltrate with epidermal involvement	Negative	Oral 300 mg m <sup>-2</sup> daily	Partial (2 months), full (3 months)
4	Caucasian	20	Ia with follicular mucinosis	Left anterior thigh, right forearm, right shoulder	6 × 6 cm, 4 × 2 cm, 4 × 3 cm patches without erythema or scale	CD4, CD8 perifollicular infiltrate + mucin	Negative	Topical 1% four times daily	Partial (4 months), still undergoing treatment
5	Caucasian	63	III, with progression to IVa with SS	Scalp	4 × 2 cm patch with erythema and scale	CD4, CD8 infiltrate with epidermal involvement	Positive	Oral 300 mg m <sup>-2</sup> daily	Partial (3 months), full (6 months)

TCR, T-cell receptor; SS, Sézary syndrome.



**Figure 1.** Patient 1. (a) Large patch of alopecia with fine white scale on crown of the scalp. (b) Partial hair regrowth after 3 months of topical bexarotene therapy. (c) Almost full regrowth with terminal grey hairs after 5 months of topical bexarotene therapy.

the skin, and bone marrow and lymph nodes were also involved. He was staged as IVa (T4N3B2M0) with Sézary syndrome.

After 6 months on photopheresis without improvement, he began a trial of oral bexarotene 450 mg daily (300 mg m<sup>-2</sup> daily).<sup>3</sup> Significant improvement of the skin lesions and

alopecia (partial response) was observed at 9 months. After 1.5 years on bexarotene therapy, his involved body surface area had decreased from 100% to 1%, adenopathy had resolved, and full hair regrowth and restoration of normal hair colour was present (Fig. 2c,d). A complete clinical remission at a reduced dose of 225 mg daily has been sustained.

MF is characterized by a clonal proliferation of helper/memory (CD4+ CD45RO+) T cells in the epidermis, but folliculotrophic variants are also described and lead to local or more generalized alopecia.<sup>1,2</sup> Alopecia areata, on the other hand, has 'benign' peribulbar clonal T-cell infiltrates that may also be CD4+ and can downregulate epidermal proliferation by production of interferon- $\gamma$  and tumour necrosis factor- $\alpha$ .<sup>6</sup> Our work has shown that both diseases are associated with HLA-DR5 and DQB1\*03 alleles.<sup>7,8</sup> In both MF and alopecia areata, De Panfilis has hypothesized that activated T cells become resistant to apoptosis, escape activation-induced cell death (AICD) mediated through Fas/Fas ligand, and accumulate in skin lesions.<sup>9</sup> In the absence of AICD, 'abnormal/malignant' clones may evolve.

Retinoids control differentiation, proliferation and apoptosis through interactions with tissue-specific retinoic acid receptor RAR or RXR isotypes.<sup>10</sup> Whereas RAR retinoids have frequently been associated with the unwanted side-effect of alopecia, we were surprised to observe the opposite in five MF patients treated successfully with the first RXR-selective agent, bexarotene. Retinoids form heterodimers with other steroid receptors, including thyroid, vitamin D, as well as peroxisome proliferation-activating receptors that can down-regulate the expression of inflammatory cytokines.<sup>11</sup>

Although bexarotene appears to be effective for treating MF in both topical and oral forms,<sup>3,4,12</sup> there are no other reports of its effect on hair growth in either MF or alopecia areata. While hair regrowth following other MF treatments is not mentioned in the literature, and we have not personally observed it with other standard MF treatments, systemic steroids both induce T-cell apoptosis and are quite effective in treating alopecia areata. Whether the hair regrowth in these five patients was a direct result of reducing the T-cell infiltrates or of other effects on hair follicles is unknown at this time. Two phase II trials of topical and oral bexarotene for alopecia areata and alopecia totalis, respectively, are in progress to address this issue.

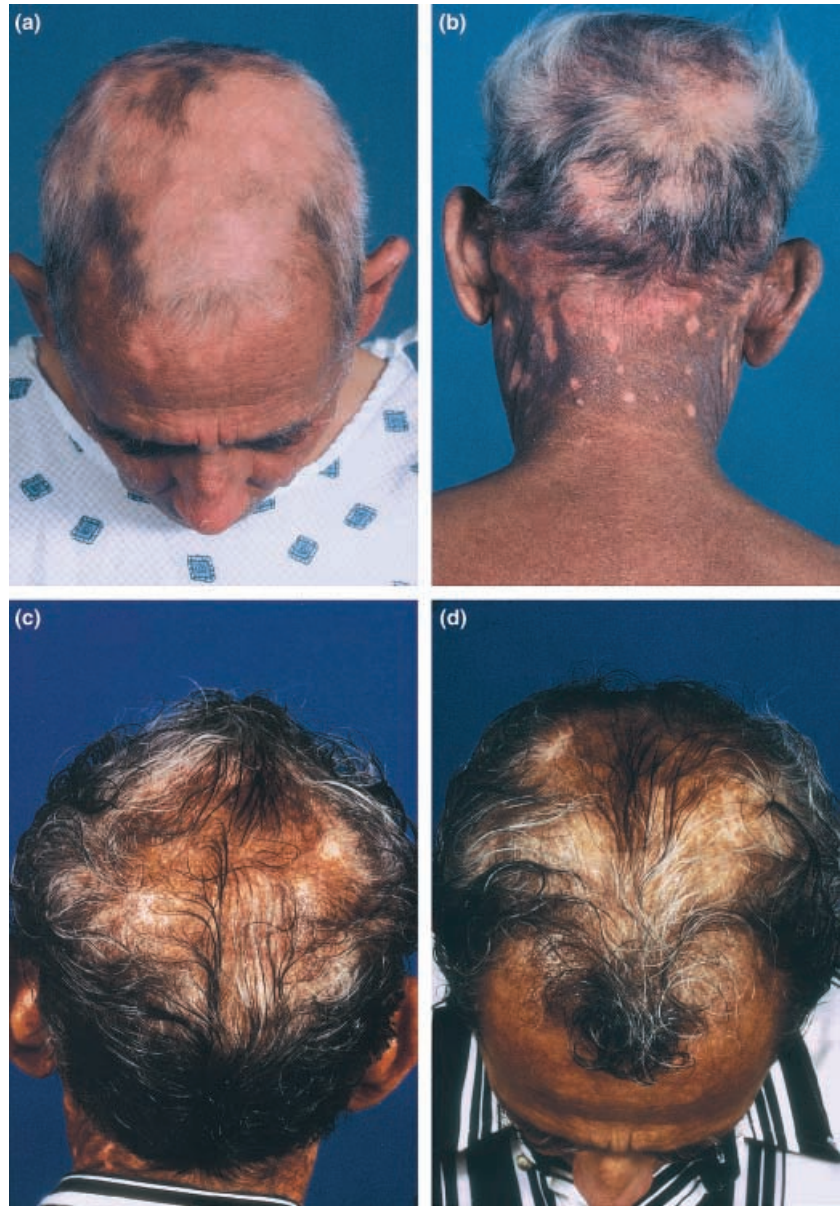### Acknowledgments

This work was supported in part by NIH K24 CA86815A and the Sherry L. Anderson CTCL Research Fund.

Baylor College of Medicine, Houston, TX, U.S.A., and \*Department of Dermatology, M.D. Anderson Cancer Center, 1515 Holcombe Blvd, Box 434, Houston, TX 77030, U.S.A.  
Correspondence: M.Duvic.  
E-mail: mduvic@mdanderson.org

M.HANSON  
A.HILL  
M.DUVIC\*





**Figure 2.** Patient 2. (a,b) Multiple round patches of hair loss with associated exclamation point hairs and patches of white hair. (c,d) Almost full hair regrowth and the patches of white hair returning to normal colour after 18 months of oral bexarotene therapy.

## References

- 1 Jackow CM, Papadopoulos E, Nelson B *et al*. Follicular mucinosis associated with scarring alopecia, oligoclonal T-cell receptor Vbeta expansion, and *Staphylococcus aureus*: when does follicular mucinosis become mycosis fungoides? *J Am Acad Dermatol* 1997; **37**: 828–31.
- 2 van Doorn R, Scheffer E, Willemze R. Follicular mycosis fungoides, a distinct disease entity with or without associated follicular mucinosis. *Arch Dermatol* 2002; **138**: 191–8.
- 3 Duvic M, Martin AG, Kim Y *et al*. Phase 2 and 3 clinical trial of oral bexarotene (Targretin capsules) for the treatment of refractory or persistent early-stage cutaneous T-cell lymphoma. *Arch Dermatol* 2001; **137**: 581–93.
- 4 Duvic M, Hymes K, Heald P *et al*. Bexarotene is effective and safe for treatment of refractory advanced-stage cutaneous T-cell lymphoma: multinational phase II–III trial results. *J Clin Oncol* 2001; **19**: 2456–71.
- 5 Zhang C, Hazarika P, Ni X *et al*. Induction of apoptosis by bexarotene in cutaneous T-cell lymphoma cells: relevance to mechanism of therapeutic action. *Clin Cancer Res* 2002; **8**: 1234–40.
- 6 Thein C, Strange P, Hansen ER, Baadsgaard O. Lesional alopecia areata T lymphocytes downregulate epithelial cell proliferation. *Arch Dermatol Res* 1997; **289**: 384–8.
- 7 Welsh EA, Clark HH, Epstein SZ *et al*. HLA-DQB1\*03 alleles are associated with alopecia areata. *J Invest Dermatol* 1994; **103**: 758–63.
- 8 Jackow CM, McHam JB, Friss A *et al*. HLA-DR5 and DQB1\*03 class II alleles are associated with cutaneous T-cell lymphoma. *J Invest Dermatol* 1996; **107**: 373–6.

- 9 De Panfilis G. 'Activation-induced cell death': a special program able to preserve the homeostasis of the skin? *Exp Dermatol* 2002; **11**: 1–11.
- 10 Boehm MF, Zhang L, Zhi L *et al.* Design and synthesis of potent retinoid X receptor selective ligands that induce apoptosis in leukemia cells. *J Med Chem* 1995; **38**: 3146–55.
- 11 Cheng S, Kupper T. A new retinoid for cutaneous T-cell lymphoma. *Arch Dermatol* 2001; **137**: 649–52.
- 12 Breneman D, Duvic M, Kuzel T *et al.* Phase 1 and 2 trial of bexarotene gel for skin-directed treatment of patients with cutaneous T-cell lymphoma. *Arch Dermatol* 2002; **138**: 325–32.

### Immunohistological characterization of a Japanese case of pityriasis rotunda

SIR, We describe a 25-year-old Japanese woman who was diagnosed as having pityriasis rotunda (PR). She presented with multiple, round, well-demarcated hyperkeratotic lesions, approximately 7–10 cm in diameter, slightly brown in colour, on the lateral side of both upper arms and lower limbs (Fig. 1). The condition was otherwise asymptomatic, the skin anomaly being present since her early childhood. None of the other members of the family showed ichthyotic lesions. In order to rule out the possibility of other skin disorders with similar symptoms, a histological examination was performed on both lesional and unaffected skin. Histopathology of lesional skin revealed a moderate degree of compact hyperkeratosis without a granular layer (Fig. 2a), and follicular plugs were seen within hair follicles. Few keratohyaline granules were detected in the affected areas by electron microscopy, in keeping with the results of light

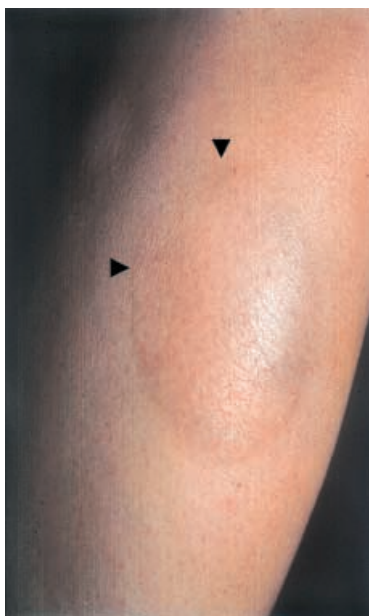microscopy. However, ultrastructural observation of the unaffected areas showed keratohyaline granules of normal size and number in the granular layer (data not shown).

Immunohistochemical studies were performed on samples of both lesional and unaffected skin. Both types of sample were labelled identically by antihuman keratin 1 and 10, anti-transglutaminase (TGase) I and anti-involucrin antibodies (data not shown for keratin and TGase; Fig. 2g,h for involucrin). However, there was a marked decrease in filaggrin and loricrin expression in the affected skin (Fig. 2c,e). An *in situ* TGase assay showed no differences between affected and unaffected skin (data not shown). Results of routine haematological and blood chemistry tests were normal. Tumour marker screening tests and abdominal ultrasound tests were negative. Culture and KOH tests for dermatophytes in the scales taken from the lesions were negative.

PR is an uncommon keratinization disorder originally described in Japanese subjects.<sup>1–3</sup> It is characterized by multiple, round or oval, sharply demarcated, scaling patches. Although in previous reports this disease was considered to be a form of acquired ichthyosis<sup>4,5</sup> or the expression of a systemic disorder,<sup>6–8</sup> the clinical phenotype and histology of the eruption resemble those of autosomal dominant ichthyosis vulgaris.<sup>1,2</sup> In order to characterize the keratinization disorders overlying PR and to assess their aetiology, we examined the expression patterns of marker proteins in epidermal differentiation.

The results of the examination showed that both the affected and unaffected areas were labelled almost identically by antihuman keratin 1 and 10, anti-TGase I and anti-involucrin antibodies. In contrast, there was a marked decrease in filaggrin and loricrin expression in the affected regions. Although there are few reports describing the immunohistochemical features of PR, the localized downregulation of these proteins indicates that the dysfunction of the terminal differentiation process may play a significant role behind the patchy formation of hyperkeratotic regions. Furthermore, these findings also may serve as a useful diagnostic marker for identifying PR.

To our knowledge, more than 180 cases of PR have been reported worldwide.<sup>9,10</sup> Hitherto, only one English report and two Japanese reports<sup>2,3</sup> have documented ultrastructural studies in PR,<sup>10</sup> in which no abnormalities could be found in the shape, size or number of keratohyaline granules. In view of the fact that the results of the other Japanese studies, while not precisely duplicating our results, confirmed salient aspects of our ultrastructural findings,<sup>2,3</sup> the classification of PR into two heterogeneous types, with or without abnormalities in keratohyaline granules, is highlighted as a valid topic for further inquiry.

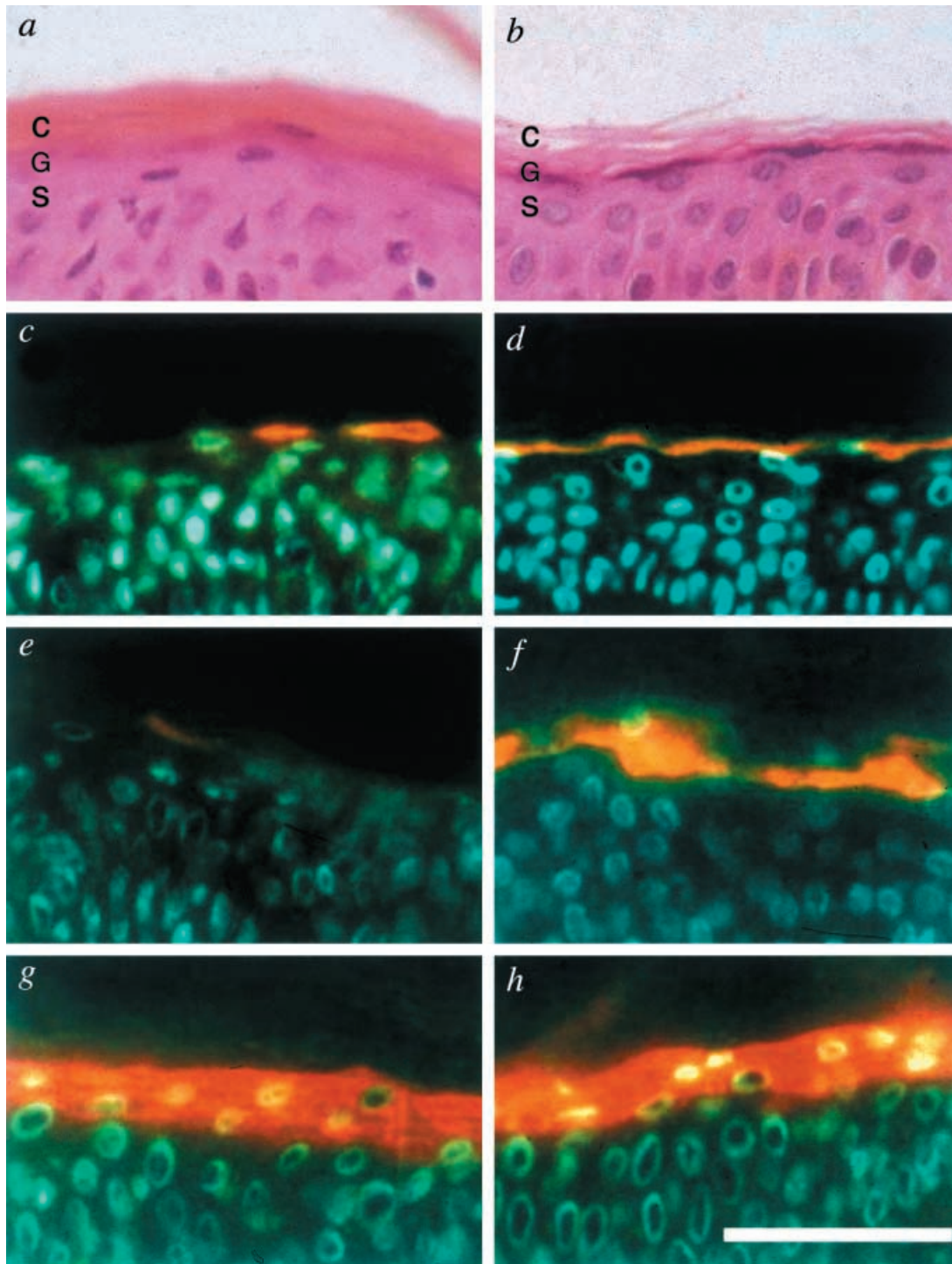


**Figure 1.** Clinical appearance of pityriasis rotunda. A round, sharply demarcated, flat, uniformly scaly and hyperpigmented lesion is evident on the upper right thigh. Arrowheads indicate the margin of the hyperkeratotic lesion.

Department of Dermatology,  
Juntendo University School of  
Medicine, Hongo 2-1-1, Bunkyo-ku,  
Tokyo 113-8421, Japan  
Correspondence: Yasushi Suga.  
E-mail: ysuga@med.juntendo.ac.jp

Y. HASHIMOTO  
Y. SUGA  
T. CHIKENJI  
S. MATSUBA  
M. MIZOGUCHI  
M. KAKUTA  
H. OGAWA





**Figure 2.** Histological and immunohistological findings from lesional (a,c,e,g) and unaffected (b,d,f,h) skin. (a,b) Haematoxylin and eosin staining; (c,d), (e,f) and (g,h) show the immunohistochemistry of filaggrin, loricrin and involucrin, respectively, labelled with streptavidin, Alexa 594 conjugate (red) staining in cryosections of the biopsy specimens. Nuclear counterstaining was performed using 4,6-diamino-2-phenylindole (blue). Antifilaggrin monoclonal antibody (Biomedical Technologies, Stoughton, MA, U.S.A.), antilorocrin monoclonal antibody (gift from Dr D.R. Roop) and anti-involucrin monoclonal antibody (Neomakers, Union City, CA, U.S.A.) were used as the primary antibodies. Biotinylated goat antimouse IgG antibody (ScyTek, Logan, UT, U.S.A.) was used as a secondary antibody. The sections were then incubated with Alexa 594 conjugate (Molecular Probes, Eugene, OR, U.S.A.). C, Cornified layer; G, granular layer; S, spinous layer. Scale bar = 50  $\mu$ m.

## References

- 1 Toyama T. Über eine bisher noch nicht beschriebene Dermatose: Pityriasis Circinata. *Arch Dermatol Syphilol* 1906; **116**: 243–58.
- 2 Aoshima T. Ultrastructural characterization of pityriasis rotunda. *Hifuka-Kiyou* 1982; **77**: 229–34 (in Japanese).
- 3 Mizuno F. Comparative electron microscopic study on ichthyosis vulgaris, pityriasis rotunda and skin disorders caused by alkylbenzyl-trimethyl ammonium chloride. *Jpn J Dermatol* 1973; **83**: 297–313 (in Japanese).
- 4 Ikeda J, Oki M. Concurrent pityriasis rotunda and acquired ichthyosis with IgG myeloma. *Br J Dermatol* 1974; **91**: 585–6.
- 5 Griffin LJ, Massa MC. Acquired ichthyosis and pityriasis rotunda. *Clin Dermatol* 1993; **11**: 27–32.
- 6 Leibowitz MR, Weiss R, Smith EH. Pityriasis rotunda. A cutaneous sign of malignant disease in two patients. *Arch Dermatol* 1983; **119**: 607–9.
- 7 DiBisceglie AM, Hodgkinson HJ, Berkowitz I *et al.* Pityriasis rotunda. A cutaneous marker of hepatocellular carcinoma in South African blacks. *Arch Dermatol* 1986; **122**: 802–4.
- 8 Etoh T, Nakagawa H, Ishibashi Y. Pityriasis rotunda associated with multiple myeloma. *J Am Acad Dermatol* 1991; **24**: 303–4.
- 9 L'Henaff N, Combemale P. Pityriasis rotunda. Review of the literature. *Ann Dermatol Venerol* 1993; **120**: 305–9.
- 10 Grimalt R, Gelmetti C, Brusasco A *et al.* Pityriasis rotunda: report of a familial occurrence and review of the literature. *J Am Acad Dermatol* 1994; **31**: 866–71.

## Ciclosporin A-induced sebaceous gland hyperplasia

SIR, we report on two kidney transplant recipients who developed pronounced hyperplasia of multiple sebaceous glands under long-term treatment with ciclosporin A. Sebaceous gland hyperplasia (SGH) is a benign disorder characterized by the development of multiple hyperplastic sebaceous glands. They are clinically detected as disseminated epithelial tumours that may occur as a congenital disorder, sporadically in advanced age, in association with immunosuppressive

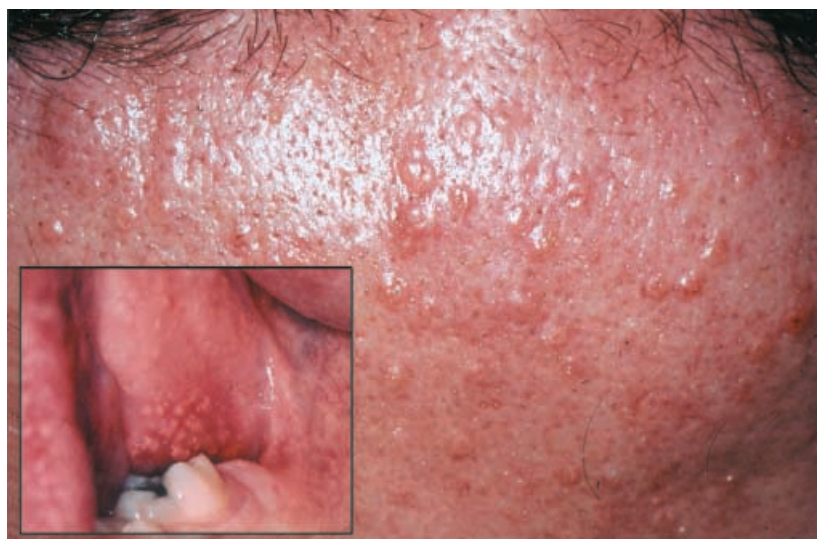medication in transplant recipients, or as a sign of the Muir–Torre syndrome.<sup>1</sup>

Since transplantation, both patients (a 33-year-old male with a terminal kidney insufficiency due to Alport syndrome who received a kidney transplant in 1991, and a 66-year-old male with two kidney transplantations in 1978 and in 1991 due to renal shrinkage) have been receiving ciclosporin A and prednisolone. Over the last 10 years, the daily doses of the younger patient (73 kg) have been 2 mg kg<sup>-1</sup> ciclosporin A and 0.07 mg kg<sup>-1</sup> prednisolone, and of the elderly patient (61 kg) over the last 23 years, 2.5 mg kg<sup>-1</sup> ciclosporin A and 0.06 mg kg<sup>-1</sup> prednisolone. Nine years after initiation of the immunosuppressive treatment, the younger patient recognized multiple asymptomatic skin-coloured lesions on the face, neck and chest that continuously increased in number. The older patient recognized facial sebaceous gland hyperplasia 7 years after the second kidney transplantation.

At admission, both patients demonstrated a seborrhoeic facial skin with multiple—approximately 40—disseminated, yellowish to skin-coloured, 1–5 mm large papules mainly on the forehead, the nose, and the cheeks (Fig. 1). The younger patient also presented hyperplastic sebaceous glands at the décolleté and the oral mucosa.

Histological examination in both patients showed an abnormal superficial localization of the sebaceous glands in the upper dermis, enlargement of their volume, and characteristic morphology which comprised a broad rim of increased numbers of undifferentiated, proliferating sebocytes and only central clusters of advanced differentiated to mature sebocytes (Fig. 2).

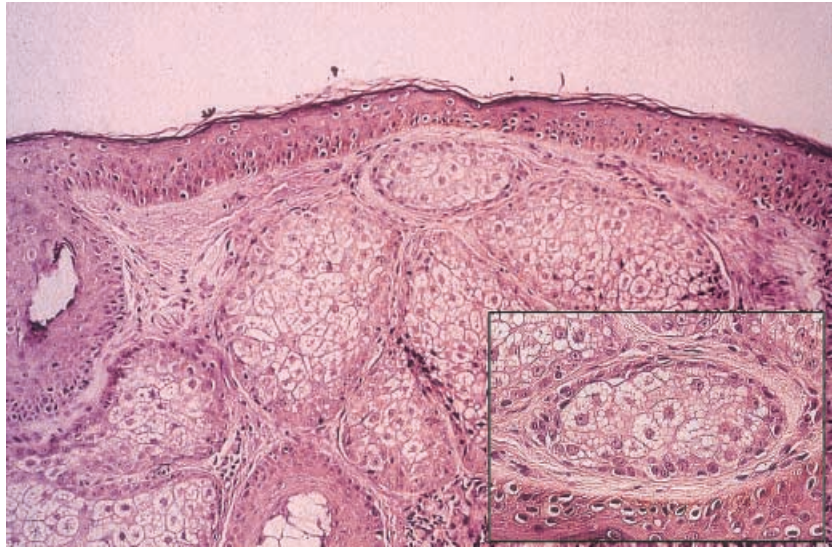
As sebaceous glands are mostly considered by dermatologists in association with acne and seborrhoea, the antiproliferative and sebostatic effects of isotretinoin and antiandrogens have been extensively studied. In contrast, little attention has been paid to compounds that enhance the activity of sebaceous glands. Indeed, development of multiple cutaneous tumours has often been associated with ciclosporin A therapy.<sup>2,3</sup> Although benign and malignant sebaceous



**Figure 1.** Multiple hyperplastic sebaceous glands seen as yellowish to skin-coloured papules disseminated over the entire forehead and at the buccal area (detail) of a 33-year-old kidney transplant recipient under long-term ciclosporin A treatment.



**Figure 2.** Histological findings of sebaceous gland hyperplasia under long-term ciclosporin A treatment. Sharply demarcated lobules of enlarged sebaceous glands almost adjusted to a thinned epidermis. The glands are separated from the dermis by a cellular fibrous stroma (fibrous pseudocapsule) (33-year-old patient). Detail: higher magnification of a sebaceous gland lobule shows that the sebaceous lobules are composed of two major sebocyte populations: an unusually broad peripheral rim of multilayered small, undifferentiated, proliferating sebocytes and aggregates of fully differentiated to mature sebocytes with large basophilic nuclei and abundant multivacuolated clear cytoplasm in the centre. Original magnification  $\times 40$ , detail  $\times 400$ .



gland tumours are generally rare, 10–16% of organ transplant recipients with long-term ciclosporin A treatment in combination with corticosteroids develop SGH compared with 1% of a nonimmunosuppressed control group.<sup>2,4</sup> Interestingly, development of SGH has previously been considered to be dose-dependent, being observed in patients receiving 5–10 mg kg<sup>-1</sup> per day<sup>5</sup> but not in patients treated with lower doses.<sup>3</sup> However, both our patients have been receiving only low-dose ciclosporin A, 2–2.5 mg kg<sup>-1</sup> per day. As in our patients, only male transplant recipients have been reported.<sup>2,4,5</sup> On the other hand, SGH has not been observed in transplant recipient children, a fact that has been explained due to the immaturity of the pilosebaceous unit in childhood.<sup>4</sup> An association between the duration of ciclosporin A treatment and the development of SGH can be recognized. In the majority of cases, SGH occurred after a long period of high-dose immunosuppressive therapy, after a minimum of 4 years.<sup>4–6</sup> In our patients, the disease presented after 9 and 19 years of ciclosporin A treatment, respectively.

Other immunosuppressive drugs, like prednisolone or azathioprine, have not been suggested to induce SGH in transplant recipients.<sup>3,5,6</sup> Therefore, we consider SGH under ciclosporin A treatment to be a direct and causal effect of ciclosporin A on the sebaceous gland rather than as a result of immunosuppression.<sup>5</sup> The histological findings in hyperplastic sebaceous glands reported in our work differ markedly from the ones reported in patients with senile SGH.<sup>1</sup> While in senile SGH a reduced turnover occurs with low numbers of differentiating, lipid-producing cells, in ciclosporin A-induced SGH hyperproliferation of undifferentiated sebocytes and inhibition of differentiation lead to multilayered basal cells with only a few islands of differentiated sebocytes (differentiation arrest).

On the other hand, an association between sebaceous gland carcinoma and iatrogenic immunosuppression has been reported recently, as sebaceous gland carcinomas may be overrepresented in immunosuppressed renal transplant

patients.<sup>7</sup> As in Muir–Torre syndrome, a microsatellite instability in posttransplant sebaceous carcinoma DNA was found together with a loss of mismatch repair genes,<sup>8</sup> indicating a possible interaction between DNA mismatch repair gene proteins and immunosuppressive drugs. Immunosuppressive treatment may possibly unmask a latent Muir–Torre syndrome or promote tumour progression in genetically susceptible patients.

Department of Dermatology,  
University Medical Centre Benjamin  
Franklin, The Free University of  
Berlin, Fabekstrasse 60–62, 14195  
Berlin, Germany

A. BOSCHNAKOW  
T. MAY  
C. ASSAF  
B. TEBBE  
CH. C. ZOUBOULIS

Correspondence: Professor  
Dr Christos C. Zouboulis.  
E-mail: zouboulis@medizin.  
fu-berlin.de

## References

- 1 Zouboulis ChC, Boschnakow A. Chrono- and photoageing of the human sebaceous gland. *Clin Exp Dermatol* 2001; **26**: 600–7.
- 2 Bencini PL, Montagnino G, Salsa F *et al*. Cutaneous lesions in 67 cyclosporin-treated renal transplant recipients. *Dermatologica* 1986; **172**: 24–30.
- 3 Lugo-Janer G, Sanchez JL, Santiago-Delpin E. Prevalence and clinical spectrum of skin diseases in kidney transplant recipients. *J Am Acad Dermatol* 1991; **3**: 410–14.
- 4 de Berker DA, Taylor AE, Quinn AG *et al*. Sebaceous hyperplasia in organ transplant recipients: shared aspects of hyperplastic and dysplastic processes? *J Am Acad Dermatol* 1996; **35**: 696–9.
- 5 Marini M, Saponaro A, Remorino L *et al*. Eruptive lesions in a patient with bone marrow transplantation. *Int J Dermatol* 2001; **40**: 133–52.
- 6 Taylor AEM, Shuster S. Skin cancer after renal transplantation: the causal role of azathioprine. *Acta Derm Venerol (Stockh)* 1992; **72**: 115–19.



- 7 Harwood CA, Swale VJ, Bataille VA *et al.* An association between sebaceous carcinoma and microsatellite instability in immunosuppressed organ transplant recipients. *J Invest Dermatol* 2001; **116**: 246–53.
- 8 Entius MM, Keller JJ, Drillenburger P *et al.* Microsatellite instability and expression of hMLH-1 and hMSH-2 in sebaceous gland carcinomas as markers for Muir–Torre syndrome. *Clin Cancer Res* 2000; **6**: 1784–9.

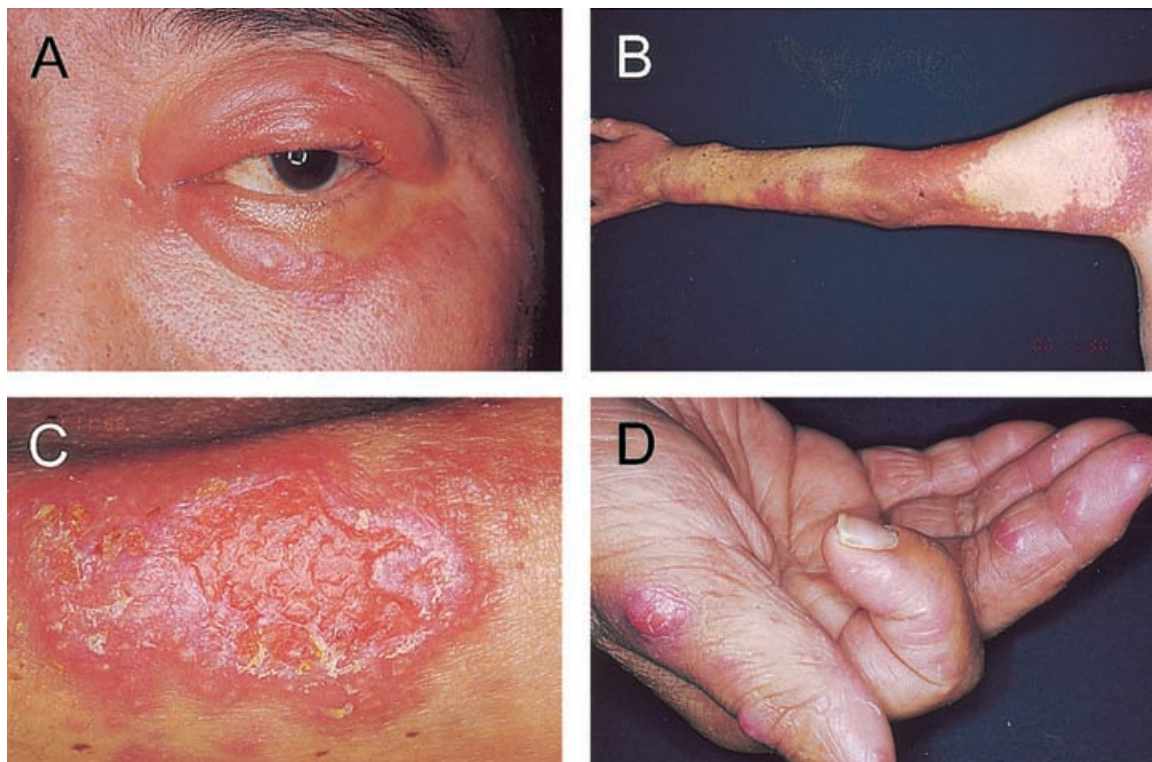
**Disseminated cutaneous *Mycobacterium haemophilum* infection with severe hypercalcaemia in a failed renal transplant recipient**

SIR, *Mycobacterium haemophilum* was first identified in 1978 from ulcerating skin lesions in a patient with Hodgkin's disease.<sup>1</sup> More than 120 cases have been reported, mostly in immunocompromised hosts such as AIDS patients and organ transplant recipients.<sup>2</sup> As it is a fastidious organism with unique growth requirements, *M. haemophilum* infection is usually underdiagnosed.<sup>3</sup> We report a disseminated cutaneous *M. haemophilum* infection in a renal transplant recipient who had chronic graft rejection necessitating haemodialysis. Extensive cutaneous involvement and associated severe hypercalcaemia were noteworthy features.

A 44-year-old Taiwanese man presented to our Dermatology Clinics in October 2000 with a 10-week history of

progressive generalized asymptomatic skin rash, swelling of the left eyelids and arthralgia. He had been on long-term multiple immunosuppressants since cadaveric renal transplantation in November 1991 due to end-stage renal failure. In August 2000, immunosuppressive therapy was discontinued because of graft failure, and he resumed haemodialysis with normal calcium dialysate (Ca 2.5 mEq L<sup>-1</sup>). From July 2000, calcium carbonate 1.5 g three times daily was prescribed, and in October the serum calcium rose to 11.9 mg dL<sup>-1</sup> (normal 8.1–10.1).

Examination revealed swelling of the left eyelids and multiple erythematous scaly patches and plaques, some arcuate or annular in shape, over the upper and lower proximal extremities. Histopathology of two skin biopsies taken from the right arm and left upper eyelid showed follicular hyperkeratosis, mild epidermal hyperplasia, extensive infiltration of lymphocytes and epithelioid histiocytes, and palisading granulomas in the upper dermis. Three weeks later, drowsiness and general weakness associated with severe hypercalcaemia (19.6 mg dL<sup>-1</sup>) were found, and two sessions of emergency haemodialysis with low-calcium dialysate (Ca 1.25 mEq L<sup>-1</sup>) were initiated to normalize the serum calcium level to 9.2 mg dL<sup>-1</sup>. Ultrasonography of the neck ruled out any parathyroid lesion. There were decreased levels of intact parathyroid hormone (i-PTH; 6.8 pg mL<sup>-1</sup>, normal 10–65), elevated 1 $\alpha$ , 25-dihydroxyvitamin D (127 n mL<sup>-1</sup>, normal 15.9–55.6) and parathyroid hormone-related protein



**Figure 1.** *Mycobacterium haemophilum* infection manifesting as (A) swelling of the left eyelids, (B) large annular erythematous scaly papules and plaques on the upper proximal extremities, (C) ulcerative infiltrating plaques on the left calf, and (D) tender erythematous nodules on the fingers.

(PTHrP;  $9.98 \text{ pmol L}^{-1}$ , normal  $< 9.2$ ), and normal 25-hydroxyvitamin D ( $18.24 \text{ pg mL}^{-1}$ , normal  $9.7\text{--}41.7$ ).

During hospitalization, the skin lesions continued to progress, with aggravating arthralgia. The left eyelids became more swollen with some pustules (Fig. 1A). The arcuate or annular lesions enlarged (Fig. 1B). There were erythematous fluctuating ulcerative plaques dotted with pustules over the right thigh and left calf (Fig. 1C). Multiple tender erythematous papules, pustules and plaques appeared on the volar sides of the fingers and dorsa of the hands, especially the knuckles (Fig. 1D). Two further skin biopsies, taken from a plaque and a pustule, showed pseudocarcinomatous epidermal hyperplasia, and suppurative and palisading granulomatous dermatitis (Fig. 2A). Compared with previous skin biopsies the inflammation was more extensive, with more numerous multinucleated giant cells and neutrophils with microabscesses, focal haemorrhage and necrosis in the dermis. Numerous acid-fast bacilli were detected in all four biopsy specimens by Ziehl–Neelsen stain, but cultures of the draining pus for mycobacteria in Lowenstein–Jensen medium and for common bacteria yielded negative results. A 435-bp DNA fragment was amplified by polymerase chain reaction (PCR) with the specific primer pair for the heat shock protein 65 gene (*hsp65*) of mycobacteria from all four paraffin-embedded tissue specimens.<sup>4</sup> Digestion of the amplicon by *Bst*EI and *Hae*III revealed restriction fragments compatible with the pattern of *M. haemophilum* (Fig. 2B),<sup>5</sup> which was confirmed by direct DNA sequencing. Chest computed tomography showed a  $0.4 \times 0.3\text{-cm}$  well-defined nodule in the right lower lobe of the lung.

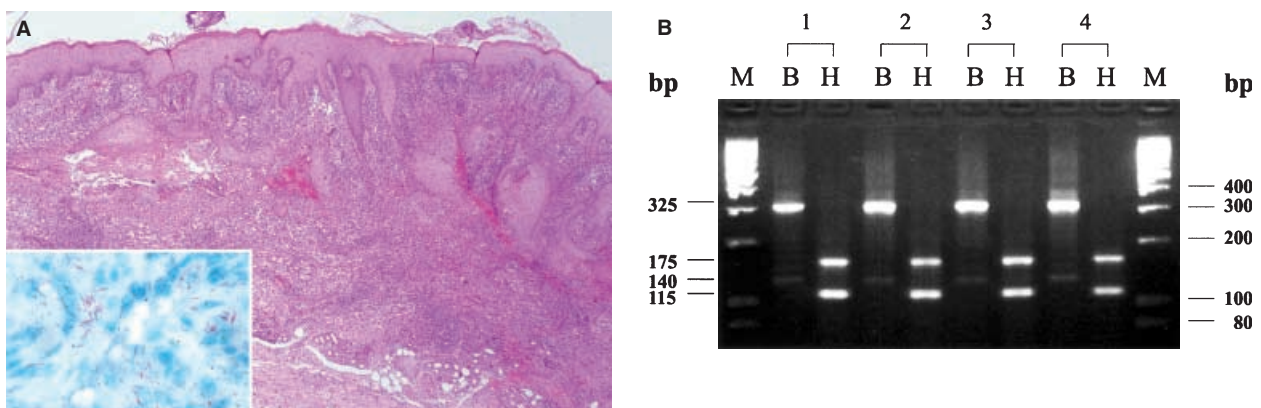
Under the diagnosis of disseminated cutaneous *M. haemophilum* infection, antimycobacterial therapy was initiated with clarithromycin 500 mg twice daily, ciprofloxacin 200 mg four times daily and rifampin 600 mg four times daily. The skin lesions became more inflamed and oozing in

the first few weeks after commencing treatment, and then gradually improved over the next 3 months with postinflammatory hyperpigmentation, scarring and milia formation. The arthralgia also improved in parallel. Histopathology performed 8 months following initiation of treatment showed oedematous fibrosing granulation tissue and focal small granulomas without evidence of acid-fast bacilli. Repeated tissue culture under appropriate conditions for 8 weeks failed to isolate *M. haemophilum*, and PCR demonstrated no further *hsp65* product.

Low-calcium dialysate was initially needed to maintain normal serum calcium level, while normal-calcium dialysate was used for haemodialysis 2 weeks after initiation of antimycobacterial therapy. Follow-up after 1 year of treatment showed normal levels of i-PTH ( $63.2 \text{ pg mL}^{-1}$ ),  $1\alpha$ , 25-dihydroxyvitamin D ( $24.95 \text{ pg mL}^{-1}$ ) and 25-hydroxyvitamin D ( $38.33 \text{ ng mL}^{-1}$ ). The pulmonary nodule was no longer detected.

Cultures remain the gold standard for the diagnosis of *M. haemophilum* infection. Early correct diagnosis of the infection is difficult if strict culture conditions are not followed. The bacterium grows slowly at an optimal temperature of  $30\text{--}32^\circ\text{C}$  in  $5\text{--}10\%$   $\text{CO}_2$ , as opposed to  $37^\circ\text{C}$  for most other pathogenic mycobacteria.<sup>6</sup> A medium supplemented with iron compounds such as ferric ammonium citrate or haemin is needed.<sup>6</sup> In our case, the initial culture failed to grow *M. haemophilum* because the culture conditions were not suitable for this organism. Fortunately, PCR study was able to detect *M. haemophilum* DNA in the biopsy specimens. As *M. haemophilum* is rarely detected by PCR in our hospital, the possibility of contamination was small.

*Mycobacterium haemophilum* infection most commonly affects the skin, manifesting as erythematous papules or nodules that may become suppurative with painful draining ulcers.<sup>3</sup> Cysts, erythema, cellulitis, scaly plaques, focal



**Figure 2.** (A) Histopathology of the third and fourth skin biopsies showed pseudocarcinomatous hyperplasia, severe suppurative and necrotizing granulomatous dermatitis, microabscesses and focal haemorrhage (insert) with numerous acid-fast bacilli singly or in clusters (haematoxylin and eosin, original magnification  $\times 400$ ; insert: Ziehl–Neelsen, original magnification  $\times 1000$ ). (B) Digestion of the amplicons from the four biopsy specimens by *Bst*EI and *Hae*III revealed restriction fragments (*Bst*EI: 325, 140 bp; *Hae*III: 175, 115 bp) compatible with the pattern of *Mycobacterium haemophilum*.<sup>5</sup> M, Marker ladders; B, *Bst*EI; H, *Hae*III.

panniculitis and annular plaques have also been reported.<sup>3,6,7</sup> Skin lesions may be localized or diffuse, and are most often found on the extremities, especially over the joints.<sup>6</sup> Uncommon extracutaneous manifestations include septic arthritis, osteomyelitis<sup>6</sup> and pulmonary nodules.<sup>3,8</sup> *Mycobacterium haemophilum* infection in our patient was unusually extensive, probably precipitated by chronic immunosuppressive and uraemic status. Periorbital lesions and concurrent joint and pulmonary involvement has rarely been described.<sup>6</sup>

Hypercalcaemia caused by extrarenal production of  $1\alpha$ , 25-dihydroxyvitamin D by granulomatous infiltrates has been reported in various granulomatous diseases, but its association with *M. haemophilum* infection has not been documented in the English language literature.<sup>9</sup> In our case, the decreased i-PTH, normal 25-hydroxyvitamin D, but elevated  $1\alpha$ , 25-dihydroxyvitamin D and PTHrP indicated extrarenal production of the last two, which appeared to be normalized by antimycobacterial therapy.

Disseminated infection with *M. haemophilum* requires systemic antibiotics.<sup>6</sup> The organism is usually sensitive to ciprofloxacin, clarithromycin, rifabutin and rifampin, but resistant to ethambutol, isoniazid and pyrazinamide in *in vitro* tests.<sup>3,6</sup> Treatment is recommended for at least 1 year.<sup>3</sup> An initial exacerbation of skin lesions at the beginning of treatment, as seen in our patient, is not uncommon.<sup>3</sup>

To summarize, in immunocompromised or uraemic patients, hypercalcaemia associated with extensive suppurative and granulomatous cutaneous lesions with predilection for the extremities should raise suspicion of *M. haemophilum* infection. PCR analysis of the mycobacterial *hsp65* gene can be an effective tool for early identification of this infection.

Departments of Dermatology,  
\*Pathology and †Internal Medicine,  
National Cheng Kung University  
Hospital, 138 Sheng-Li Road, Tainan  
70428, Taiwan  
Correspondence: Jeng-Jong Huang,  
E-mail: jjhuang@mail.ncku.edu.tw

J.-H. LIN  
W. CHEN  
J.-Y.-Y. LEE  
J.-J. YAN\*  
J.-J. HUANG†

## References

- 1 Sompolinsky D, Lazgiel A, Naveh D *et al.* *Mycobacterium haemophilum* sp. nov., a new pathogen of humans. *Int J Syst Bacteriol* 1978; **28**: 67–75.
- 2 Paech V, Lorenzen T, von Krosigk A *et al.* Remission of cutaneous *Mycobacterium haemophilum* infection as a result of antiretroviral therapy in a human immunodeficiency virus-infected patient. *Clin Infect Dis* 2002; **34**: 1017–9.
- 3 Shah MK, Sebt A, Kiehn TE *et al.* *Mycobacterium haemophilum* in immunocompromised patients. *Clin Infect Dis* 2001; **33**: 330–7.
- 4 Telenti A, Marchesi F, Balz M *et al.* Rapid identification of mycobacteria to the species level by polymerase chain reaction and restriction enzyme analysis. *J Clin Microbiol* 1993; **31**: 175–8.
- 5 Devallois A, Goh KS, Rastogi N. Rapid identification of mycobacteria to species level by PCR-restriction fragment length polymorphism analysis of the *hsp65* gene and proposition of an algorithm to differentiate 34 mycobacterial species. *J Clin Microbiol* 1997; **35**: 2969–73.

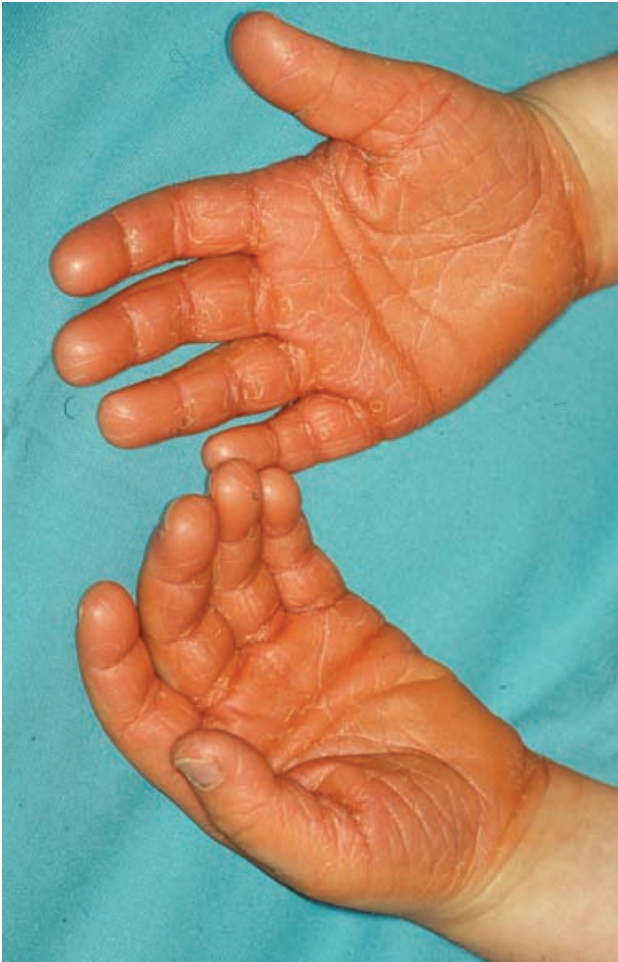- 6 Saubolle MA, Kiehn TE, White MH *et al.* *Mycobacterium haemophilum*: microbiology and expanding clinical and geographic spectra of disease in humans. *Clin Microbiol Rev* 1996; **9**: 435–47.
- 7 Friedli A, Krischer J, Hirschel B *et al.* An annular plaque due to *Mycobacterium haemophilum* infection in a patient with AIDS. *J Am Acad Dermatol* 2000; **43**: 913–5.
- 8 White DA, Kiehn TE, Bondoc AY *et al.* Pulmonary nodule due to *Mycobacterium haemophilum* in an immunocompetent host. *Am J Respir Crit Care Med* 1999; **160**: 1366–8.
- 9 Adams JS. Vitamin D metabolite-mediated hypercalcemia. *Endocrinol Metab Clin N Am* 1989; **18**: 765–78.

## Juvenile pityriasis rubra pilaris: successful treatment with ciclosporin

SIR, Pityriasis rubra pilaris (PRP), first described by Tarral in 1835, is an idiopathic, papulosquamous disease.<sup>1</sup> Progression of PRP can result in erythroderma with islands of sparing ('nappes claires'). The age distribution is bimodal, with PRP characteristically occurring during the first and fifth decades of life. PRP affects both sexes, all races, and has been reported worldwide. Most cases are acquired, although familial variants of the disease exist.<sup>2</sup> Griffiths classified PRP into five groups differing with respect to clinical features, course and prognosis.<sup>2</sup> Several therapeutic approaches for treating PRP have been published, including vitamins, retinoids, antime-tabolites, antibiotics and psoralen plus ultraviolet A.<sup>3</sup> The use of retinoids as first-line treatment of adult-onset PRP is well established. However, childhood cases of PRP remain a therapeutic problem.

A 4-year-old boy was admitted to the department of dermatology with a 2-week history of an erythematous eruption affecting the face. On examination, follicular papules and plaques were found on the knees, elbows and axillae. The palms and soles showed waxy-yellow diffuse hyperkeratosis (Fig. 1). The patient's medical history was unremarkable and there was no personal or family history of skin disease. A skin biopsy from the left axilla showed psoriasiform acanthosis, alternating orthokeratosis and parakeratosis, and a moderate lymphocytic perivascular infiltrate in the dermis. There was no spongiosis and no microabscesses in the epidermis. The boy was diagnosed clinically as having type III PRP and was treated with topical, low-potency corticosteroids and urea 10% ointment. Within 4 weeks the PRP rapidly progressed to result in erythroderma. At this time he was febrile with a temperature of up to 39.5 °C. Full blood count, erythrocyte sedimentation rate, urea, electrolytes, liver function tests, serum creatinine, serum iron levels, hepatitis profile, anti-streptolysin-O antibodies and C-reactive protein were within normal limits. He had no clinical symptoms or signs suggesting an infection. Because of his poor condition, treatment was initiated with oral ciclosporin 3.0 mg kg<sup>-1</sup> daily and topical emollients. The thick scaly skin and erythroderma dramatically regressed within 5 weeks. Serum creatinine, serum urea nitrogen and blood pressure were monitored regularly and remained within the standard range. After clinical remission, the dose of ciclosporin was gradually





**Figure 1.** Waxy-yellow diffuse hyperkeratosis of palms.

tapered down to zero within 18 weeks. Complete clearance of PRP was achieved with no recurrence for over 8 months.

PRP is marked by epidermal hyperproliferation with abnormal keratinization, and dermal inflammation. Abnormal vitamin A metabolism in the skin has been discussed for a long time as a major cause of PRP, but convincing evidence has not been provided. PRP has been observed after various infections and trauma, but most cases occur without any obvious preceding event.<sup>1</sup> Documented cases of PRP in patients with autoimmune disease or infection, e.g. with human immunodeficiency virus, have led to speculation on a possible underlying immune mechanism.<sup>4</sup> Magro and Crowson<sup>5</sup> hypothesized that the pathogenesis of PRP may be related to an abnormal immune response to antigenic triggers.

Normally, juvenile PRP has a relatively rapid course and resolves spontaneously within a year. Accordingly, potentially harmful drugs should be used cautiously.<sup>6</sup> However, systemic treatment is necessary in patients with erythroderma and disabling disease. The use of retinoids in prepubertal patients, as recommended for adult-onset PRP, is problematic on the basis of possible toxic effects on bone metabolism. In

this context, the short-term treatment of juvenile-onset PRP with ciclosporin could be an alternative. Ciclosporin has been shown to be a highly effective drug for the treatment of severe inflammatory dermatoses in childhood.<sup>7</sup> At present, the use of ciclosporin for PRP has been reported only in adult-onset cases, with conflicting results concerning its efficacy.<sup>8–12</sup> In our case, low-dose, short-term ciclosporin treatment resulted in clearance of PRP within 5 weeks. The time-course suggests that the improvement was due to the ciclosporin rather than coincidental. Remission was achieved without hypertension or adverse effects on renal function. During follow-up for over 8 months after withdrawal of ciclosporin there has been no recurrence of PRP. The positive effects of ciclosporin in our patient support the hypothesis of a possible underlying immune mechanism for PRP. Ciclosporin therapy has potential side-effects such as nephrotoxicity, hypertension and carcinogenesis, mainly after prolonged use. However, short-term treatment with ciclosporin seems to be safe. We suggest the use of ciclosporin in PRP patients with erythroderma and disabling disease who have not responded to topical treatment.

Department of Dermatology,  
University of Leipzig, Liebigstr. 21,  
04103 Leipzig, Germany.  
E-mail: wett@medizin.uni-leipzig.de

T. WETZIG  
M. STICHERLING

## References

- 1 Albert MR, Mackool BT. Pityriasis rubra pilaris. *Int J Dermatol* 1999; **38**: 1–11.
- 2 Griffiths WA. Pityriasis rubra pilaris. *Clin Exp Dermatol* 1980; **5**: 105–12.
- 3 Cohen PR, Prystowsky JH. Pityriasis rubra pilaris. A review of diagnosis and treatment. *J Am Acad Dermatol* 1989; **20**: 801–7.
- 4 Sanchez RM, Fuentes CG, Creus L *et al.* Pityriasis rubra pilaris and HIV infection: a part of the spectrum of HIV-associated follicular syndrome. *Br J Dermatol* 1995; **133**: 818–9.
- 5 Magro CM, Crowson AN. The clinical and histomorphological features of pityriasis rubra pilaris. A comparative analysis with psoriasis. *J Cutan Pathol* 1997; **24**: 416–24.
- 6 Gelmetti C, Schiuma AA, Cerri D, Gianotti F. Pityriasis rubra pilaris in childhood: a long-term study of 29 cases. *Pediatr Dermatol* 1986; **3**: 446–51.
- 7 Mahe E, Bodemer C, Pruszkowski A *et al.* Cyclosporine in childhood psoriasis. *Arch Dermatol* 2001; **137**: 1532–3.
- 8 Meyer P, van Voorst Vader PC. Lack of effect of cyclosporin A in pityriasis rubra pilaris. *Acta Derm Venereol (Stockh)* 1989; **69**: 272.
- 9 Ghazi A, Laso-Dosal F. Cyclosporin A and pityriasis rubra pilaris. *Acta Derm Venereol (Stockh)* 1990; **70**: 181.
- 10 Gupta AK, Ellis CN, Nickoloff BJ *et al.* Oral cyclosporine in the treatment of inflammatory and noninflammatory dermatoses. A clinical and immunopathologic analysis. *Arch Dermatol* 1990; **126**: 339–50.
- 11 Rosenbach A, Lowe NJ. Pityriasis rubra pilaris and cyclosporin. *Arch Dermatol* 1993; **129**: 1346–8.
- 12 Usuki K, Sekiyama M, Shimada T *et al.* Three cases of pityriasis rubra pilaris successfully treated with cyclosporin A. *Dermatology* 2000; **200**: 324–7.

### Neurogenic pruritus: a case of pruritus induced by transverse myelitis

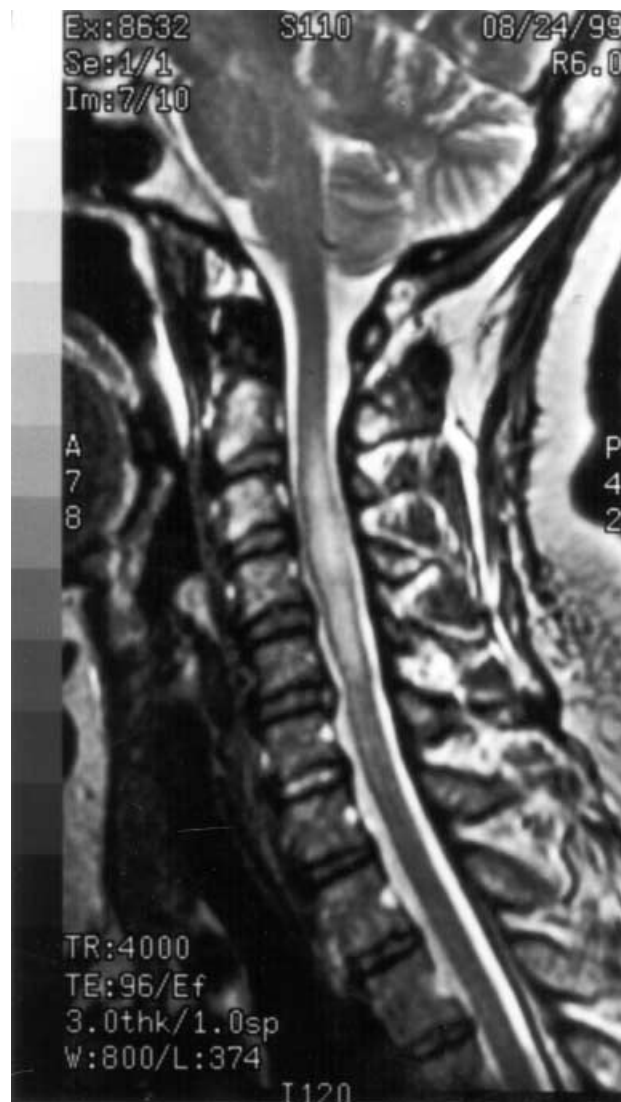SIR, Pruritus without a primary skin eruption generally indicates an underlying medical disorder.<sup>1</sup> Pruritus is a well-known complaint in some medical illnesses such as cholestasis, uraemia, diabetes mellitus, malignancy, lymphoma, polycythaemia vera and other myeloproliferative disorders. Neurogenic pruritus is rare. We report the first case of pruritus induced by transverse myelitis, an uncommon neurological condition which initially presents with bilateral lower extremity weakness, sensory loss with a distinct dermatomal distribution, and urinary retention.<sup>2</sup>

A 43-year-old black woman initially presented with pain and paraesthesiae in her legs. Three weeks after initial presentation, she complained of terrible pruritus and hyperaesthesia of a well-demarcated area of her proximal upper extremities, associated with difficulty in urinating. The pruritus and allodynia were so severe that they prevented her from falling asleep at night. Intravenous and oral medications, including steroids, hydroxyzine, doxepin and moisturizers, did not alleviate the symptoms. Oxycodone, however, was an effective analgesic for her pain and pruritus. Our patient's past medical history was unremarkable. She reported no history of any other medical problems including multiple sclerosis or nerve tumours, recent upper respiratory tract infection or recent vaccinations.

Physical examination revealed well-defined, hyperpigmented, lichenified plaques with pink excoriations present on the lateral aspect of both upper extremities distal to the deltoid, consistent with the C3-5 dermatomal distribution. Sensory examination was significant for hyperaesthesia and allodynia of the lichenified areas. Motor examination was normal. Laboratory data, including full blood count, electrolytes, liver function tests, thyroid-stimulating hormone, vitamin B<sub>12</sub>, human immunodeficiency virus, Venereal Disease Research Laboratory test, antinuclear antibody and cerebrospinal fluid studies, were all normal. An electromyographic study was not revealing. However, magnetic resonance imaging of the cervical spine revealed an oval-shaped, hyperintense region extending from C2-3 to C5-6 in the T2 weighted images, which enhanced with gadolinium (Fig. 1). This image is consistent with transverse myelitis of the spinal cord. Our patient was observed for a period of months. Her symptoms of pruritus and allodynia gradually abated as the transverse myelitis resolved.

Neurogenic pruritus is an uncommon cause of pruritus, but must be considered when pruritus follows a dermatomal distribution. Other central nervous system lesions that may cause localized pruritus include stroke,<sup>3</sup> basilar artery aneurysm,<sup>4</sup> brain tumours<sup>5</sup> and brain abscesses.<sup>6</sup> In many of these cases of central neurogenic pruritus, the affected pruritic area was also either hypoaesthetic or hyperaesthetic, findings which may help the clinician distinguish cases of central neurogenic pruritus.

The physiological basis for pruritus has not yet been completely worked out. Several observations and studies



**Figure 1.** Magnetic resonance imaging of the cervical spine reveals an oval, hyperintense region extending from C2-3 to C5-6 in the T2 weighted images, which enhanced with gadolinium.

support the hypothesis that pruritus is a submodality of pain.<sup>7</sup> The sensation of itch is thought to originate from the nerve endings of myelinated delta A fibres and unmyelinated C fibres near the dermoepidermal junction.<sup>8</sup> Physiological itch is believed to be transmitted by the rapidly conducting myelinated delta A fibres, whereas unmyelinated C fibres in the dermis that transmit pain are thought to transmit the sensation of pathological or unpleasant pruritus, as well as pain.<sup>7</sup>

Our patient's pruritus was probably not caused by the traditional peripheral mediators such as histamine and the endopeptidases,<sup>8</sup> but by a pathophysiological process in the spinal cord. The exact mechanism by which our patient experienced pruritus is not clear, but it is interesting that only

opioids relieved her pruritus. The observation that itching occurs with opioid spinal analgesia seems to indicate that the spinal cord or the spinal roots are involved in the pruritic effect. Whether the itch is due to a direct effect of the opioid, or whether it lowers the threshold to other stimuli, is not known.<sup>9</sup>

This report of transverse myelitis of the cervical spinal cord inducing pruritus is, to our knowledge, the first report of transverse myelitis causing pruritus. Importantly, the affected pruritic area was hyperaesthetic, a finding which may help the clinician distinguish cases of central neurogenic pruritus. Our patient's pruritus was not caused by the traditional peripheral mediators such as histamine and the endopeptidases, but by a pathophysiological process in the spinal cord, which resulted in pruritus, with subsequent lichenification caused by scratching. The exact mechanism by which our patient experienced pruritus is not clear, but it may have been caused by interruption of a yet undefined spinal pathway that is capable of modulating the sensations of pain and pruritus. Only opioids relieved her pruritus, and it is possible that oxycodone, the opioid that relieved our patient's pain, may have modulated the spinal cord's ability to transmit the sensation of pruritus.

Department of Dermatology, New York Medical College, Valhalla, New York, NY, and \*Knoxville, TN, U.S.A.  
E-mail: drbond\_2000@yahoo.com

L.D.BOND JR  
G.C.KEOUGH\*

## References

- 1 Beare JM. Generalized pruritus. a study of 43 cases. *Clin Exp Dermatol* 1976; **1**: 343–52.
- 2 Plum F, Olson ME. Myelitis and myelopathy. In: *Clinical Neurology* (Baker AB, ed.), Vol. 3. Hagerstown, MD: Harper & Row, 1997: 24–49.
- 3 Massey EW. Unilateral neurogenic pruritus following stroke. *Stroke* 1984; **15**: 901–3.
- 4 Shapiro PE, Braun CW. Unilateral pruritus after a stroke. *Arch Dermatol* 1987; **123**: 1527–30.
- 5 King CA, Huff J, Jorizzo JL. Unilateral neurogenic pruritus: paroxysmal itching associated with central nervous system lesions. *Ann Intern Med* 1982; **97**: 222–3.
- 6 Sullivan MJ, Drake ME. Unilateral pruritus and *Nocardia* abscess. *Neurology* 1984; **34**: 828–9.
- 7 Kunkle EC, Chapman WP. Insensitivity to pain in man: a research. *Nev Ment Dis Processes* 1943; **23**: 100–9.
- 8 Herndon JH. Itching: the pathophysiology of pruritus. *Int J Dermatol* 1975; **14**: 465–84.
- 9 Scott PV, Fischer HBJ. Spinal opiate analgesia and facial pruritus: a neural theory. *Postgrad Med J* 1982; **58**: 531–5.

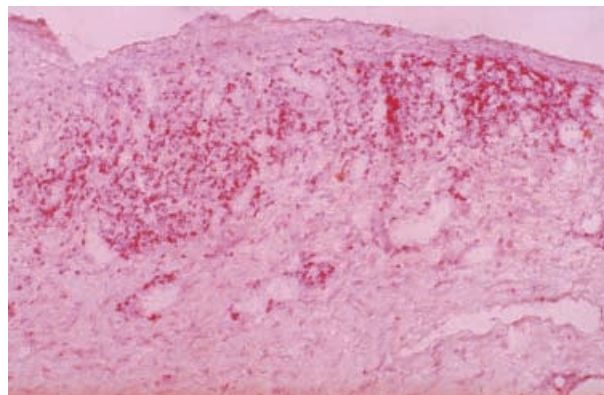## Early apoptosis plays an important role in the healing mechanism of cutaneous basal cell carcinomas after photodynamic therapy

SIR, Topical photodynamic therapy (PDT) with  $\delta$ -5-amino-laevulinic acid (5-ALA) is increasingly used in precancerous

skin lesions (actinic keratoses) and nonmelanoma skin cancer [superficial basal cell carcinoma (BCC); Bowen's disease].<sup>1</sup> The mechanism of PDT depends on the activation of a photosensitizing compound by visible light of an appropriate wavelength that correlates with the absorption spectrum of the photosensitizing compound in the presence of molecular oxygen. The exogenous prodrug 5-ALA is converted intracellularly to the endogenous photosensitizer protoporphyrin IX, with preferential accumulation in neoplastic/dysplastic tissue and consequent absorption of photons.<sup>2</sup> This latter results in a cascade of events, in which apoptosis has been suggested to play an important role.<sup>3</sup>

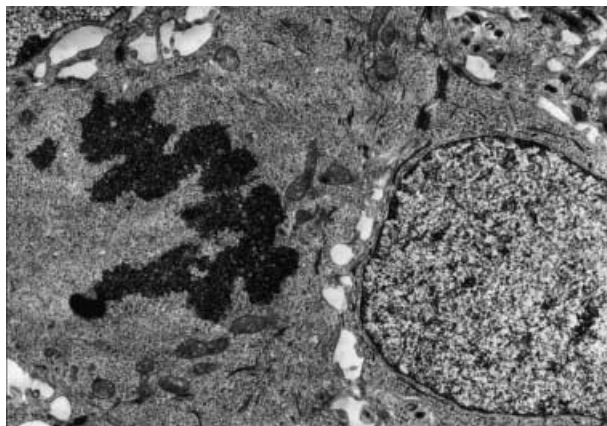
In the present study, we have investigated the possible role of apoptosis by the sequential analysis of lesional skin after 5-ALA-PDT (5-ALA in a 20% oil-in-water emulsion under occlusion, and visible light by the lamp Fotoec 3 H250, Loto, Florence, Italy: wavelength within the 630-nm range) in eight patients with superficial BCC after informed consent. The neoplastic skin samples were collected 15 min and 4, 24, 48 and 72 h after the irradiation in order to investigate the possible modifications at the cellular and subcellular level (by electron microscopy), the expression of apoptotic markers [alkaline phosphatase–anti-alkaline phosphatase (APAAP) and terminal deoxynucleotidyl transferase-mediated deoxy-uridine triphosphate nick end labelling (TUNEL) methods], and the immunophenotypic profile of the inflammatory cell infiltrate (APAAP).

At 15 min after PDT, cells positive for annexin V, which labels apoptotic cells after the phosphatidylserine translocation to the outer leaflet of plasma membranes and is considered an early marker of apoptosis,<sup>4,5</sup> were already found in the neoplastic lobules and the overlying epidermis. The largest amount of annexin V+ cells was found at 4 h (Fig. 1). Later on, annexin V expression progressively and clearly diminished until it disappeared. Fas and its ligand FasL were expressed slightly at 15 min, showed much greater expression at 4 h, and were progressively lost thereafter. These results are in agreement with others from the



**Figure 1.** Four hours after photodynamic therapy. Cells expressing annexin V within the neoplastic lobules (alkaline phosphatase–anti-alkaline phosphatase; original magnification  $\times 200$ ).





**Figure 2.** Electron microscopy. Twenty-four hours after photodynamic therapy. A mitotic figure in the basal epidermal layer (original magnification  $\times 15\,000$ ).

literature,<sup>6</sup> which showed a significant time-dependent increase in the expression of Fas and FasL until 60 min after PDT, followed by a progressive decrease thereafter. TUNEL staining<sup>7</sup> also showed a progressive increase of apoptotic cells, starting at 15 min and reaching a maximum at 24 h, followed by rapid disappearance thereafter.

By electron microscopy, clear-cut morphological signs of apoptosis (cytoplasmic and nuclear condensation, margination of chromatin and intercellular oedema) were already shown by basal keratinocytes at 15 min; at later time-points, these modifications were also found at progressively upper epidermal levels. At 24 h, organelle remnants and cell membrane interruptions (later signs of apoptosis) were observed. Interestingly, at this time-point mitotic figures were found in the basal cell layer at the edge of the specimen (Fig. 2), indicating the start of the re-epithelialization process. Regarding the expression of Bcl-2 protein, which generally has a protective role in PDT-induced apoptosis and is uniformly expressed by all neoplastic cells in BCC,<sup>8</sup> this was already reduced at 15 min, in line with the hypothesis of an early activation of apoptotic pathways.

Regarding the time-related sequence of cell types infiltrating neoplastic BCC tissue and overlying epidermis after the treatment, this was overall as expected: mast cells at the very beginning (15 min), mostly polymorphonuclear granulocytes up to 24 h, and progressive infiltration by CD3+, CD4+ lymphocytes (driving the late stage of the apoptotic pathway) and CD68+ macrophages (mainly devoted to removing apoptotic bodies by phagocytosis) thereafter.

In conclusion, in full agreement with data from the literature,<sup>9,10</sup> our results seem to indicate that apoptosis plays an important role in the healing mechanism of superficial BCC after PDT, in keeping with the clinically observed type of healing: few, if any, signs of acute inflammation and definitely no necrosis of the lesion.

## Acknowledgments

This research was supported by the Italian Ministry of University, Science and Technology (University funds, 60%) and the Cassa di Risparmio di Firenze.

Departments of Dermatological  
Sciences and \*Anatomy, Histology  
and Forensic Medicine, University of  
Florence Medical School, Via degli  
Alfani 37, 50121 Florence, Italy.  
E-mail: fprignano@dfc.unifi.it

F. PRIGNANO  
B. BIANCHI  
L. DOMENICI\*  
R. ROSSI  
P. ROMAGNOLI\*  
N. PIMPINELLI  
P. CAPPUGI  
B. GIANNOTTI

## References

- 1 Cairnduff F, Stringer MR, Hudson EJ *et al.* Superficial photodynamic therapy with topical 5-aminolaevulinic acid for superficial primary and secondary skin cancer. *Br J Cancer* 1994; **69**: 605–8.
- 2 Kennedy JC, Pottier RH. Photodynamic therapy with endogenous protoporphyrin IX: basic principles and current experience. *J Photochem Photobiol B* 1990; **6**: 143–8.
- 3 Godar DE. Light and death: photons and apoptosis. *J Invest Dermatol* 1999; **4**: 17–23.
- 4 Ruck A, Heckelsmiller K, Kaufmann R *et al.* Light-induced apoptosis involves a defined sequence of cytoplasmic and nuclear calcium release in AIPcS4-photosensitized rat bladder RR 1022 epithelial cells. *Photochem Photobiol* 2000; **72**: 210–16.
- 5 Schindl A, Klosner G, Honigsmann H *et al.* Flow cytometric quantification of UV-induced cell death in a human squamous cell carcinoma-derived cell line: dose and kinetic studies. *J Photochem Photobiol B* 1998; **44**: 97–106.
- 6 Jou P, Kou CJ, Yuan J, Blenis J. Essential requirement for caspase-8/FLICE in the initiation of the Fas-induced apoptotic cascade. *Curr Biol* 1998; **8**: 1001–8.
- 7 Wrone-Smith T, Bergstrom J, Quevedo ME *et al.* Differential expression of cell survival and cell cycle regulator in cutaneous squamoproliferative lesions. *J Dermatol Sci* 1999; **19**: 53–67.
- 8 Morales-Ducret CR, van de Rijn M, LeBrun DP, Smoller BR. Bcl-2 expression in primary malignancies of the skin. *Arch Dermatol* 1995; **13**: 909–12.
- 9 Oleinick NL, Evans HH. The photobiology of photodynamic therapy: cellular targets and mechanisms. *Radiat Res* 1998; **150** (Suppl.): 146–56.
- 10 Ketabchi A, MacRobert A, Speight PM, Bennet JH. Induction of apoptotic cell death by photodynamic therapy in human keratinocytes. *Arch Oral Biol* 1998; **43**: 143–9.

## Dead Sea extract sold under-the-counter

SIR, Atopic eczema and other chronic skin diseases are conventionally treated with topical corticosteroids, but systemic corticosteroids are also sometimes used. Some patients do not always use the prescribed medication but seek other remedies. One reason for this is fear of side-effects, e.g. from corticosteroids. Complementary medicine is becoming increasingly popular, particularly among patients with long-standing conditions such as eczema, where conventional medicine has not provided satisfactory solutions.<sup>1</sup> The most frequently used treatment modalities comprise homoeopathy, herbalism and food supplements.<sup>1–3</sup> Patients tend to

regard herbal remedies as natural products without side-effects.<sup>4</sup> However, undeclared potent corticosteroids have been found in Chinese herbal creams.<sup>4,5</sup>

In spring 1998 a woman with severe atopic eczema enthusiastically reported to her clinician (A.B.) about the prompt effect of the cream 'Psorial', which, according to the label, has a Dead Sea extract as the active component, obtained in a local health food shop. Psorial was also sold in Denmark and an analysis of the cream performed at the Danish 'Miljøstyrelsen' showed it to contain two undeclared corticosteroids, triamcinolone acetonide and halcinonide, both in therapeutic concentrations.<sup>6</sup>

One year later, another patient visited A.B. with severe perioral dermatitis. She had used a cream that seemed identical to Psorial, because it was said to contain a Dead Sea extract, but in this case the jar was unlabelled. We suspected that the cream contained corticosteroids and therefore analysed it using high-performance liquid chromatography according to a previously reported procedure.<sup>7</sup> The chromatogram showed two peaks, with retention times corresponding to those for triamcinolone acetonide and halcinonide. When triamcinolone acetonide and halcinonide were added to the sample, both peaks increased in height, indicating that the sample contained triamcinolone acetonide and halcinonide. The presence of triamcinolone acetonide and halcinonide was verified by liquid chromatography/mass spectrometry analyses. The calculated concentrations of triamcinolone acetonide and halcinonide in the cream were 0.12% and 0.13%, respectively.

This is not the first time over-the-counter products have been found to contain wilfully added corticosteroids. Several reports in the medical literature give evidence of this. The Skin-Cap intended for treatment of psoriasis contained clobetasol propionate.<sup>8,9</sup> Psorial cream, meant for treating psoriasis and atopic dermatitis, contained both triamcinolone acetonide and halcinonide in therapeutic concentrations,<sup>6</sup> and eight of 11 Chinese herbal creams contained dexamethasone.<sup>4</sup> The most recent report is a warning against a cream called Wau Wa Cream. Chemical investigations showed it to contain clobetasol propionate.<sup>10</sup>

The two corticosteroids detected in our cream were both present in therapeutic concentrations, which means that use of the product could have led to unwanted side-effects had the cream been used *ad libitum* without medical advice. In our case, the jar containing the cream was unlabelled and our patient had used the cream daily for a long period, resulting in severe perioral dermatitis. When one of the investigators (A.B.) tried to buy another jar at the health food shop where the patient had obtained her sample, she was refused, probably because she started asking questions.

As has been the case with Chinese herbal creams, Psorial cream and the unlabelled Dead Sea extract cream were marketed by word of mouth as safe and corticosteroid free. The creams were used by adults as well as children for long periods to treat different skin diseases. Not only were they hazardous because of the potential side-effects due to the content of potent corticosteroids, but they were also very expensive. As many people with chronic skin diseases tend to turn to

complementary medicine, we wish to stress once again that we must be suspicious of over-the-counter products with unexpectedly but miraculously good clinical effects.

### Acknowledgments

We are grateful to Lena Persson, Department of Occupational and Environmental Dermatology, Malmö, Sweden for the HPLC analyses and the Department of Occupational and Environmental Medicine, Lund, Sweden for the LC/MS/MS analysis. This work was supported by grants from The Swedish Foundation for Health Care Sciences and Allergy Research and The Swedish Asthma and Allergy Association's Research Foundation.

Department of Dermatology,  
Sahlgrenska University Hospital,  
SE-413 45 Göteborg

A. BROBERG  
B. GRUVBERGER\*  
M. ISAKSSON\*

\*Department of Occupational and  
Environmental Dermatology, Malmö  
University Hospital, SE-205 02  
Malmö, Sweden.

Correspondence: Marlene Isaksson.  
E-mail: marlene.isaksson@skane.se

### References

- 1 Zollman C, Vickers A. Users and practitioners of complementary medicine. *Br Med J* 1999; **319**: 836–8.
- 2 Ernst E. Adverse effects of herbal drugs in dermatology. *Br J Dermatol* 2000; **143**: 923–9.
- 3 Ernst E. The usage of complementary therapies by dermatological patients: a systematic review. *Br J Dermatol* 2000; **142**: 857–61.
- 4 Keane FM, Munn SE, du Vivier AWP *et al.* Analysis of Chinese herbal creams prescribed for dermatological conditions. *Br Med J* 1999; **318**: 563–4.
- 5 Wood B, Wishart J. Potent topical steroid in a Chinese herbal cream. *NZ Med J* 1997; **110**: 420–1.
- 6 Serup J. Psorial from Sweden, another cosmetic product containing highly potent corticosteroid. *Forum Nord Dermatol Venereol* 1998; **3**: 27.
- 7 Isaksson M, Gruvberger B, Persson L, Bruze M. Stability of corticosteroid patch test preparations. *Contact Dermatitis* 2000; **42**: 144–8.
- 8 Mrowietz U. The 'antipsoriatic' Skin-Cap contains a non-declared potent corticosteroid. *Hautarzt* 1997; **48**: 947.
- 9 Weismann K. Skin-Cap sequelae. *Forum Nord Dermatol Venereol* 1997; **2**: 3.
- 10 Daniels J, Shaw D, Atherton D. Use of Wau Wa in dermatitis patients. *Lancet* 2002; **360**: 1025.

### Tazarotene 0.1% gel for psoriasis of the fingernails and toenails: an open, prospective study

SIR, Nail psoriasis is reported in 10–55% of adults with psoriasis, is uncommon in children (7–13%) and is more frequent (up to 80%) in psoriatic arthritis.<sup>1</sup> Its clinical presentation is dependent on which part of the nail apparatus

is affected (matrix, nail bed, nail plate, periungual skin). Clinical signs include oil spots (yellowish or pinkish nail bed discoloration surrounded by an erythematous halo), pitting (irregular, nongeometrical depressions on the nail plate), onycholysis (detachment of the nail plate from the nail bed), subungual hyperkeratosis (hyperparakeratosis of the nail bed), ridging (Beau's lines, trachonychia), thickened and brittle nails, splinter haemorrhages and paronychia.<sup>1</sup> Oil spots, pitting, onycholysis and subungual hyperkeratosis are considered specific signs, with only the oil spots being strictly diagnostic for psoriasis, whereas thickened and brittle nails, splinter haemorrhages and paronychia are considered nonspecific. Psoriatic onychodystrophy and its response to therapy are not related to the extent or severity of cutaneous involvement. Treatment of nail psoriasis is motivated by cosmetic problems, dysfunction or restriction in daily activities, or pain, as experienced by most patients. Besides systemic drugs, therapeutic options include corticosteroids,<sup>2</sup> vitamin D<sub>3</sub> derivatives,<sup>3</sup> 5-fluorouracil,<sup>4</sup> urea,<sup>4</sup> dithranol,<sup>5</sup> ciclosporin<sup>6</sup> and radiotherapy.<sup>7</sup> Tazarotene has recently been used successfully for fingernail psoriasis.<sup>8</sup> This drug is approved for treating psoriasis, acne, photoageing, precancerous lesions and established cancers.<sup>9</sup>

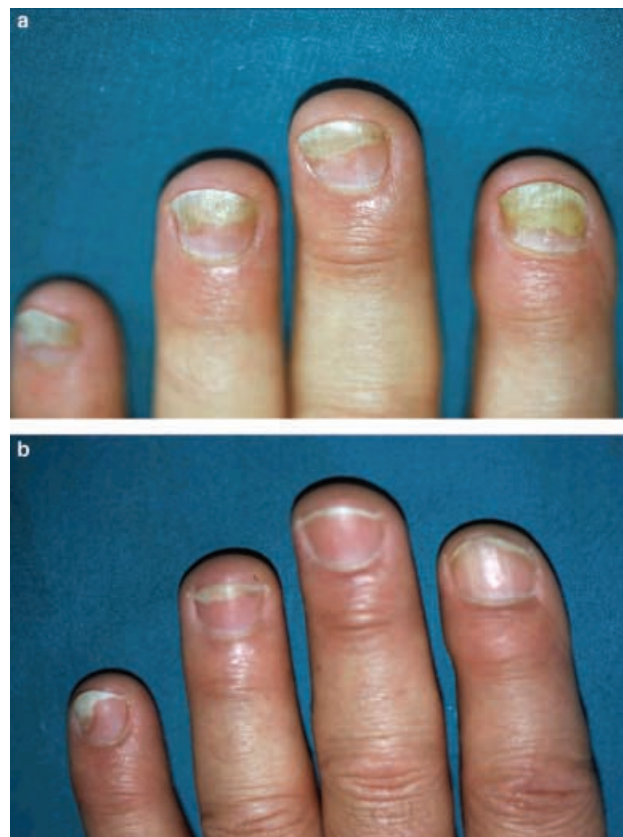We performed a randomized, open study to evaluate the effectiveness of tazarotene 0.1% gel on unoccluded psoriatic fingernails and toenails. Thirty-five psoriatic patients with significant onychodystrophy were enrolled, of whom 25 (20 men and five women, age range 22–66 years) completed the present study. Four patients were withdrawn for protocol violation and six were started on systemic therapy because of worsening of the concurrent cutaneous condition. The mean duration from the onset of psoriasis was 5.7 years. There was a 12-week washout period for topical and systemic medications. Onychomycosis was excluded by direct microscopy and culture. Tazarotene 0.1% gel was applied topically, without occlusion, to the affected nail plates, surrounding nail folds and periungual skin, at bed time, for a 12-week period. Outcome measures were assessed at baseline and at 4, 8 and 12 weeks. Follow-up evaluations took place 12 and 24 weeks after the end of treatment. Each fingernail and toenail was clinically scored using a simple rating scale,<sup>7</sup> the Visual Assessment Score (0, normal; 1, moderately affected; 2, severely affected), for each of the specific and nonspecific signs.

Nineteen of 25 patients showed a good clinical response. The specific signs showed a statistically significant Visual Assessment Score reduction after 12 weeks of application ( $P < 0.0001$ ), when compared with the mean pretreatment score, and the nonspecific signs demonstrated substantial clinical improvement (Table 1, Figs 1 and 2). The results were observed in both fingernails and toenails, the initial changes being detectable in the fingernails after only 4 weeks. Among the clinical signs, hyperkeratosis and oil spots showed better and faster improvement, whereas pitting seemed to be most persistent. The tolerability was reported by the patients as excellent (74%), good (13%) and poor (13%), this latter group mostly having toenail involvement. Mild erythema (70%), peeling of the proximal nail fold (15%) and

**Table 1.** Mean Visual Assessment Score at baseline and after 12 weeks of application of tazarotene 0.1% gel

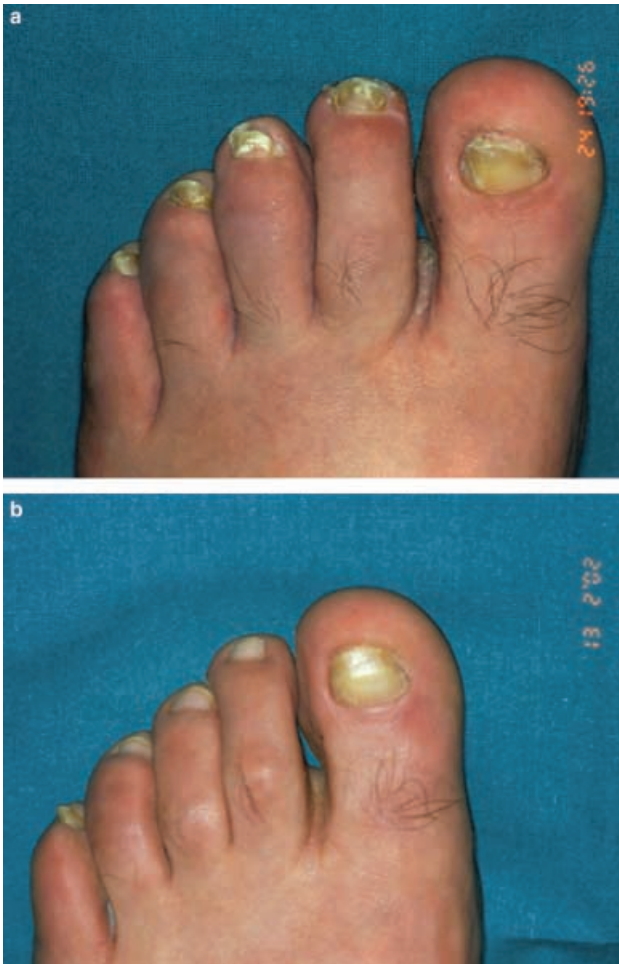Specific signs	Visual Assessment Score	
	Baseline	12 weeks
Onycholysis	26	2*
Hyperkeratosis	25	2*
Oil spots	18	3*
Pitting	13	1*
Nonspecific signs		
Thickened/brittle nails	20	3
Paronychia	7	0
Splinter haemorrhages	1	0

\* $P < 0.0001$ . Statistically significant clearing ( $P < 0.0001$ ) of the specific signs and substantial improvement of the nonspecific signs were seen after 12 weeks of tazarotene application. Statistical analysis was performed using the SPSS program (*Statistical Package for the Social Sciences*, 5th edn, M. J. Norusis/SPSS Inc., Chicago, IL, U.S.A.). For each parameter the mean, SEM and range were calculated. Differences were evaluated by the *t*-test and nonparametric Mann–Whitney *U*-test;  $P < 0.05$  was considered statistically significant.



**Figure 1.** (a) The fingernails show evident hyperkeratosis, onycholysis, pitting and oil spots at baseline. (b) Clearing of the clinical signs after 12 weeks of tazarotene application.





**Figure 2.** (a) Mainly hyperkeratotic toenails are seen at baseline. (b) Substantial improvement after 12 weeks of therapy.

burning (15%) were the side-effects reported. Most patients (60%) estimated the efficacy of the treatment as good.

After 24 weeks of follow-up, moderate recurrences were observed, mainly as mild relapsing hyperkeratosis. Even though assessment of the therapeutic response was based on a visual score without an objective measurement of the nail changes, the results of our 4-month study indicate that topical self-application of tazarotene 0.1% gel without occlusion in the evening is effective, well tolerated, and not time-consuming. Spontaneous remission is possible during the course of the disease, but the timing and degree of clinical responses observed in our series were strongly suggestive of a causative effect between tazarotene application and improvement of most of the nail signs. The results obtained were not related to the extent of skin involvement with psoriasis (data not shown). Our study extends to the toenails the study by Scher *et al.*<sup>8</sup> who reported a randomized, double-blind, vehicle-controlled study of tazarotene treatment of fingernail psoriasis.

Tazarotene is a synthetic acetylenic retinoid that is selective for  $\beta$  and  $\gamma$  isotypes of the retinoic acid receptor.<sup>9</sup> This drug

acts on proliferation, differentiation and apoptosis of keratinocytes and modulates inflammatory cells, processes which are all known to be involved in the pathogenesis of psoriasis.<sup>10</sup> It may be assumed that tazarotene exerts its action on psoriatic matrix and nail bed cells. To assure an increase absorption, even in unoccluded nails, we suggest careful application of tazarotene to the nail plate and the surrounding periungual skin, including the nail folds and, to increase patient compliance, provision of detailed information on the common but usually moderate side-effects of tazarotene.

Department of Dermatology, Tor  
Vergata University of Rome, viale  
Oxford 81, 00173 Rome, Italy  
E-mail: luca.bianchi@uniroma2.it

L. BIANCHI  
R. SODA  
L. DILUVIO  
S. CHIMENTI

## References

- 1 Baran R, Dawber RPR. The nail in dermatological diseases. In: *Diseases of the Nails and their Management* (Baran R, Dawber RPR, eds), 2nd edn. Oxford: Blackwell Scientific Publications, 1984: 135–73.
- 2 De Berker DAR, Lawrence CM. A simplified protocol of steroid injection for psoriatic nail dystrophy. *Br J Dermatol* 1998; **138**: 90–5.
- 3 Tosti A, Piraccini BM, Cameli N *et al.* Calcipotriol ointment in nail psoriasis: a controlled double-blind comparison with betamethasone dipropionate and salicylic acid. *Br J Dermatol* 1998; **139**: 655–9.
- 4 de Jong EMGJ, Menke HE, van Praag MCG *et al.* Dystrophic psoriatic fingernails treated with 1% 5-fluorouracil in a nail penetration-enhancing vehicle: a double-blind study. *Dermatology* 1999; **99**: 313–18.
- 5 Yamamoto T, Katayama I, Nishioka K. Topical anthralin therapy for refractory nail psoriasis. *J Dermatol* 1998; **25**: 231–3.
- 6 Tosti A, Guerra L, Bardazzi F *et al.* Topical cyclosporin in nail psoriasis. *Dermatologica* 1990; **180**: 110–12.
- 7 Yu RCH, King CM. A double-blind study of superficial radiotherapy in psoriatic nail dystrophy. *Acta Derm Venereol (Stockh)* 1992; **72**: 134–6.
- 8 Scher RK, Stiller M, Zhu YI. Tazarotene 0.1% gel in the treatment of fingernail psoriasis: a double-blind, randomized, vehicle-controlled study. *Cutis* 2001; **68**: 355–8.
- 9 Johnson A, Chandraratna RA. Novel retinoids with receptor selectivity and functional selectivity. *Br J Dermatol* 1999; **140** (Suppl. 54): 12–17.
- 10 Gottlieb AB. Psoriasis. Immunopathology and immunomodulation. *Dermatol Clin* 2001; **19**: 649–57.

## Stigmatization and psoriasis

SIR, We read with interest the article by Vardy *et al.*<sup>1</sup> reporting increased experiences of stigmatization for psoriasis patients over a comparison group of other dermatological conditions. Experiences of stigmatization were found to mediate the impact of severity of psoriasis on quality of life for these individuals. Such an effect was not demonstrated for

the comparison group. The paper recognizes the psychosocial impact of psoriasis and highlights the need to consider options beyond those available in the pharmacy when managing patients with the disease. This view is encouraging and is commensurate with findings and recommendations from our work.<sup>2</sup> Both research groups highlight that perceptions of stigmatization, along with depression, are the most important variables in predicting everyday disability for patients with psoriasis.

Given that a major component of stress experienced by patients with psoriasis is due to both anticipation of the potential for stigmatization as well as to actual experiences of discrimination by others,<sup>2-4</sup> we need to ask what can be done to moderate the effects of such experiences. At an individual level we report a 32-year-old man with a 15-year history of psoriasis who presented with social anxiety. He was referred by a consultant dermatologist due to high levels of social avoidance because of his psoriasis. At initial assessment the severity of his psoriasis on the Psoriasis Area and Severity Index (PASI) was 3.9, with plaques located on his elbows, trunk and scalp (PASI range 0–72; PASI > 12 = severe psoriasis). At clinical assessment he reported a high degree of anticipatory anxiety and social avoidance. These difficulties were related specifically to fears of being questioned, humiliated or rejected because of his psoriasis. He had never previously encountered any actual experiences of stigmatization because of his psoriasis. As research suggests,<sup>4</sup> the fear of being stigmatized and humiliated contributed to him engaging in avoidance coping behaviours and thus aborting his social plans. Such avoidance behaviour served to maintain his difficulties by preventing him from experiencing any positive nonstigmatizing social encounters. He underwent seven sessions of cognitive-behavioural therapy focusing on managing appraisals, misinterpretations and maladaptive beliefs about his psoriasis and its potential consequences in everyday life. Self-report measurements were taken at each appointment in relation to perceptions of being stigmatized, social anxiety and social avoidance (the therapist was blind to these ratings). Linear regression analysis indicated a significant linear trend over the course of treatment for perceived stigmatization ( $F = 8.29$ ,  $P < 0.05$ ), social anxiety ( $F = 6.19$ ,  $P < 0.05$ ) and social avoidance ( $F = 16.30$ ,  $P < 0.01$ ). Additionally, global improvements were shown on the Psoriasis Disability Index (PDI) between baseline (PDI = 7) and end of treatment (PDI = 0). In line with this, at clinical interview the patient described being less socially anxious and had engaged in social activities that he had previously avoided. The improvements on these parameters at an individual level correspond with those reported in our recent controlled trial.<sup>5</sup> In this trial a 6-week group cognitive-behavioural psychological approach for patients with psoriasis significantly improved anxiety ( $P = 0.001$ ), depression ( $P = 0.001$ ), psoriasis-related stress ( $P = 0.001$ ) and disability ( $P = 0.04$ ), in addition to improving severity of psoriasis as assessed by PASI ( $P = 0.001$ ), in comparison with patients continuing with standard pharmacological treatment alone.<sup>5</sup> This work further highlights the utility

of psychological approaches, in particular cognitive-behavioural therapy, in the management of psychological aspects of psoriasis.

Such cognitive-behavioural approaches are perhaps limited by the availability of appropriate healthcare services. Department of Health initiatives have recently been instigated to tackle the stigma and discrimination associated with mental health difficulties. Perhaps we can learn from research conducted in antistigma campaigns in the U.S.A. These antistigma programmes tend to be of three main types: media protest, where healthcare professionals, patient groups and patient charities protest at inaccurate or unhelpful media portrayals of, for instance, disfiguring skin conditions; education, where information is provided to counteract unhelpful stereotyping of stigmatized groups; and contact, where members of the public meet people from 'stigmatized' groups so that inaccurate and stigmatizing assumptions can be challenged and changed. Research on people who have been given diagnoses such as anxiety, depression or other mental health difficulties demonstrates the superiority of contact in reducing stigma and discriminating attitudes.<sup>6</sup> Clearly further research is needed to highlight how best to integrate the targets of such campaigns into clinical practice.

Psoriasis is a stigmatizing condition. Patients with psoriasis may have to contend with stigma arising from uninformed public attitudes to psoriasis as well as feelings of stigma that may arise from such discrimination. Given the clear difficulties associated with the management of psoriasis, stigma, either perceived or actual, has major implications for healthcare. As such, and given the data presented by Vardy *et al.*<sup>1</sup> and ourselves,<sup>2</sup> we need to move forward from mere consideration of a biopsychosocial approach in the management of psoriasis to embracing it fully in our assessments and interventions.

Department of Behavioural Medicine  
and the Dermatology Centre,  
University of Manchester School of  
Medicine, Hope Hospital, Manchester  
M6 8HD, U.K.

E-mail: hrichard@fs1.ho.man.ac.uk

H.L.RICHARDS  
D.G.FORTUNE  
C.J.MAIN  
C.E.M.GRIFFITHS

## References

- 1 Vardy D, Besser A, Amir M *et al.* Experiences of stigmatization play a role in mediating the impact of disease severity on quality of life in psoriasis patients. *Br J Dermatol* 2002; **147**: 736–42.
- 2 Richards HL, Fortune DG, Main CJ, Griffiths CEM. The contribution of perceptions of stigmatization to disability in patients with psoriasis. *J Psychosom Res* 2001; **50**: 10–15.
- 3 Fortune DG, Main CJ, O'Sullivan TM, Griffiths CEM. Quality of life in patients with psoriasis: the contribution of clinical variables and psoriasis-specific stress. *Br J Dermatol* 1997; **137**: 755–60.
- 4 Fortune DG, Main CJ, O'Sullivan TM, Griffiths CEM. Assessing illness-related stress in psoriasis: the psychometric properties of the Psoriasis Life Stress Inventory. *J Psychosom Res* 1997; **42**: 467–75.

- 5 Fortune DG, Richards HL, Main CJ *et al.* A cognitive-behavioural symptom management programme as an adjunct in psoriasis therapy. *Br J Dermatol* 2002; **146**: 458–65.
- 6 Corrigan PW. Mental health stigma as social attribution: implications for research methods and attitude change. *Clin Psychol Sci Pract* 2000; **7**: 48–67.

### Suggestions for uniform outcome variables when reporting treatment effects in hidradenitis suppurativa

SIR, Hidradenitis suppurativa (HS) is a chronic recurrent disease causing inflammation, suppuration and scarring of inverse areas, i.e. the axilla, groin or inframammary folds.<sup>1</sup> Treatment consists mainly of surgery, while medical therapies principally serve as adjunct therapy.<sup>2,3</sup> Randomized controlled trials (RCT) in HS have, however, found that cyproterone acetate and ethinylestradiol, topical clindamycin and tetracycline may all be useful.<sup>4–6</sup>

Surgical technique does not lend itself to the concept of RCT, and large cohort studies therefore represent the best level of evidence for surgical procedures. In order for such a cohort to be established, uniform outcome variables must be used. Having reviewed the papers on the surgical treatment of HS, the HS European Research Group (HISERG) found great variation in the reporting of results, making comparison of techniques difficult, e.g. between radical surgery involving the excision of large areas of potentially involved skin and less extensive invasive techniques. Several inherent features of HS are commonly omitted from reports of treatment outcomes: lag time for recurrences is often only reported for groups, and no distinction is made between the sites of new elements, making it impossible to distinguish true recurrence from new disease. The location of recurrent disease is rarely given, e.g. local vs. regional vs. extraregional. Treatment has not failed if a new lesion appears in a previously untreated region. Treatment may prevent acute lesions but leave chronic lesions unaffected.

In the classic Hurley clinical grading system, stage I consists of one or more abscesses with no sinus tract or cicatrization, and stage II consists of one or more widely separated recurrent abscesses, with a tract and scarring. The most severe cases (stage III) are described as having multiple interconnected tracts and abscesses throughout the entire affected area. The Hurley grading system is very useful for overall classification of cases and may form the basis for selection of appropriate treatment in a selected anatomical region. Milder cases are often manageable with medical therapy, Hurley II cases need local surgery including carbon dioxide laser treatment with secondary-intention healing, while Hurley III cases generally require wide surgical excision of the entire affected region.

One of the major interests of the HISERG is to perform multicentre clinical treatment studies in order to have studies of sufficient statistical strength in HS. In this context, we have found that the Hurley staging system is not sufficiently

dynamic for assessing differences in treatment effects.<sup>7</sup> Among HS patients seeking help from dermatologists for their disease, cases graded as Hurley II form the majority, and within this common disease stage group there is a wide variation of clinical findings and symptoms. Milder cases with comparatively small problems exist in this group, while the more severe cases graded as Hurley II may have debilitating symptoms. It is therefore important to develop a more dynamic and precise scoring system for HS by adding clinical details to the staging process.

Ideally, uniform outcome variables should take into account the known characteristics of the specific disease. In HS this suggests that reporting should allow for the inherently multifocal nature of HS and the potentially long time-to-recurrence lag. It is therefore proposed that the following outcome variables are explicitly mentioned in future reports:

- 1 *Anatomical region involved* (axilla, groin, gluteal or other region or inframammary region left and/or right: 3 points per region involved).
- 2 *Number and scores of lesions* (abscesses, nodules, fistulas, scars: points per lesion of all regions involved: nodules 2; fistulas 4; scars 1; others 1).
- 3 *The longest distance between two relevant lesions*, i.e. nodules and fistulas, in each region, or size if only one lesion (< 5 cm, 2; < 10 cm, 4; > 10 cm, 8).
- 4 *Are all lesions clearly separated by normal skin?* In each region (yes 0/no 6).

By assigning numerical scores to these variables, disease intensity can be quantified in a more clinically meaningful way on an open-ended scale. A total score as well as scores of selected regions chosen for surgical or other intervention can be calculated and followed over time. In order to test this suggested new scoring system for HS we have performed a retrospective assessment using the proposed score in 34 patients previously carefully defined.<sup>2</sup> The results are shown in Table 1 and Figure 1, suggesting that the proposed system may be of practical use.

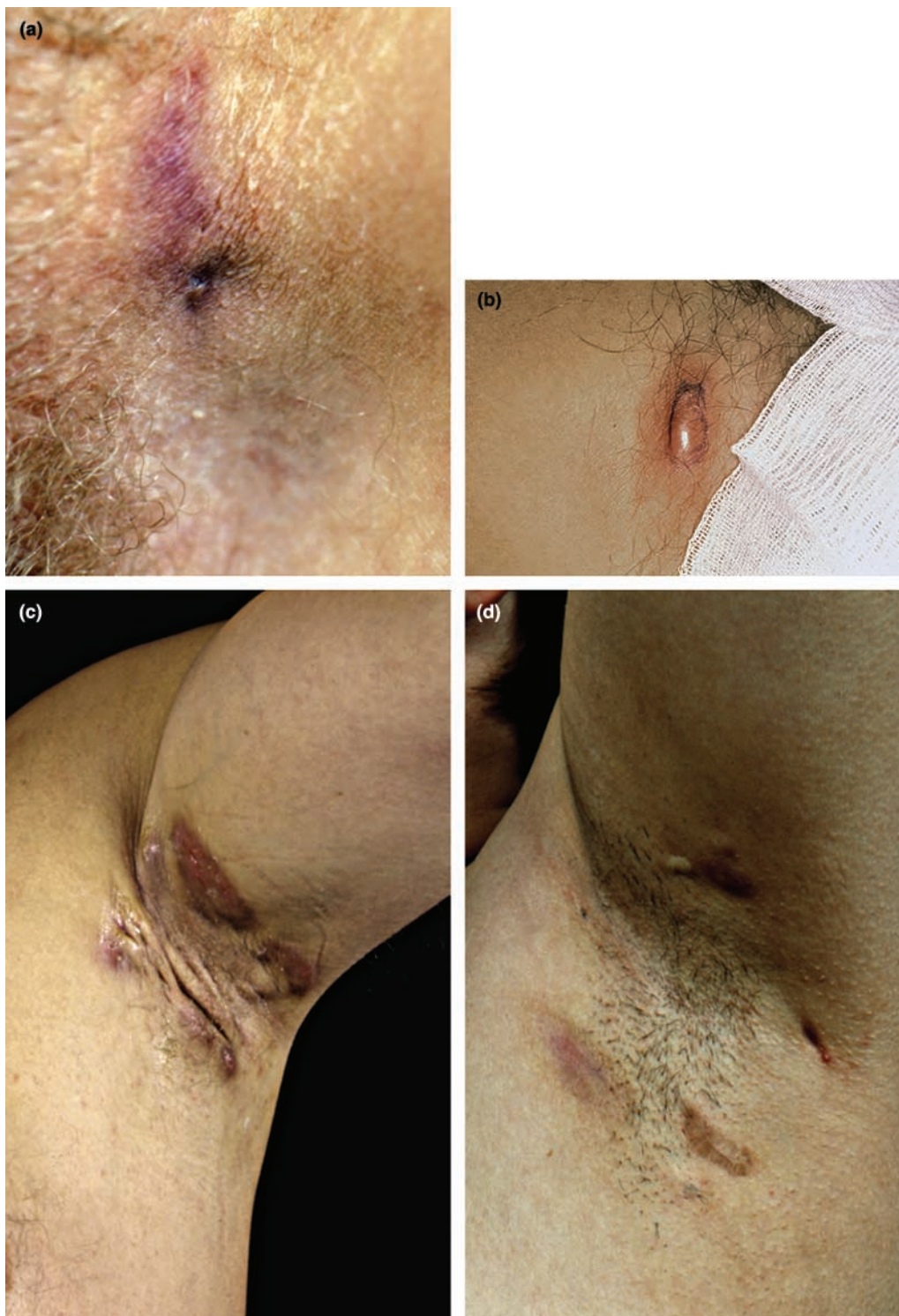
Furthermore, as pain is an important feature of HS a subjective evaluation should be included, preferably a visual analogue scale score of pain from the worst lesion as chosen by the patient.<sup>6</sup> The suggested baseline scoring system may be further improved by adding other subjective scoring systems, e.g. the Dermatology Life Quality Index, in future prospective trials.<sup>8</sup> With the reporting of these parameters the assessment of treatment outcome would be improved

**Table 1.** The results of evaluation of a new scoring system for patients with hidradenitis suppurativa (mean  $\pm$  SD values)

	Before treatment ( <i>n</i> = 34)	After treatment ( <i>n</i> = 29)
Total score	30.5 $\pm$ 24.2	12.0 $\pm$ 17.2
Regional score	11.4 $\pm$ 4.1	1.5 $\pm$ 3.6

For regional scores, representative regions treated with carbon dioxide laser and healing by secondary intention were chosen.





**Figure 1.** Representative pictures of hidradenitis suppurativa lesions. The regional score is given in parentheses. (a) A 26-year-old woman. The opening of a 4 cm long fistula of the groin (7 points). (b) A 25-year-old woman. A nodule of the groin (5 points). (c) A 44-year-old man. A combination of fistulas, scars and nodules of the armpit (37 points). This patient, graded as stage III according to Hurley, was not included in the study. (d) A 36-year-old woman. Nodules of the armpit (19 points).

significantly, aiding clinical management of this recalcitrant disease and the development of new treatments.

Department of Medicine, Section of  
Dermatology and Venereology, I 43,  
Karolinska Institutet at Huddinge  
University Hospital, SE-141 86  
Stockholm, Sweden, and \*Department  
of Medicine, Section of Dermatology,  
Roskilde Hospital, DK-4000  
Roskilde, Denmark  
E-mail: Karin.Sartorius@hs.se

K.SARTORIUS  
J.LAPINS  
L.EMTESTAM  
G.B.E.JEMEC\*

## References

- 1 Jemec GBE. Hidradenitis suppurativa. *J Cutan Medical Surg* 2003; **7**: 47–56.
- 2 Lapins J, Sartorius K, Emtestam L. Scanner-assisted carbon dioxide laser surgery: a retrospective follow-up study of patients with hidradenitis suppurativa. *J Am Acad Dermatol* 2002; **47**: 280–5.
- 3 Jansen T, Altmeyer P, Plewig G. Acne inversa (alias hidradenitis suppurativa). *J Eur Acad Dermatol Venereol* 2001; **15**: 532–40.
- 4 Mortimer PS, Dawber RPR, Gales MA, Moore RA. Mediation of hidradenitis suppurativa with androgens. *Br Med J* 1986; **292**: 245–8.
- 5 Clemmensen OJ. Topical treatment of hidradenitis suppurativa with clindamycin. *Int J Dermatol* 1983; **22**: 325–8.
- 6 Jemec GBE, Wendelboe P. Topical clindamycin versus systemic tetracycline in the treatment of hidradenitis suppurativa. *J Am Acad Dermatol* 1998; **39**: 971–4.
- 7 Hurley HJ. Axillary hyperhidrosis, apocrine bromhidrosis, hidradenitis suppurativa and familial benign pemphigus. Surgical approach. In: *Dermatologic Surgery. Principles and Practice* (Roenigk RK, Roenigk HH Jr, eds), 2nd edn. New York: Marcel Dekker, 1996: 623–45.
- 8 Finlay AY, Khan GK. Dermatology life quality index (DLQI)—a simple practical measure for routine clinical use. *Clin Exp Dermatol* 1994; **19**: 210–16.

## High-level ultraviolet A photoprotection is needed to prevent doxycycline phototoxicity: lessons learned in East Timor

SIR, Doxycycline is a commonly prescribed drug used to treat a number of inflammatory skin conditions such as acne and rosacea. As a member of the tetracycline group of antibiotics, it is a well-tolerated drug with occasional side-effects such as gastrointestinal irritation and vaginal candidosis. Rarer side-effects of doxycycline therapy include nonspecific drug rashes, phototoxic reactions and photoonycholysis. Phototoxic eruptions are thought to be due to radiation in the long wavelength ultraviolet (UV) A1 spectrum (340–400 nm) and appear to be dose dependent.<sup>1</sup> Incidence reports in the literature range from 3%<sup>2</sup> to 10%<sup>3</sup> in those taking doxycycline 100 mg daily.

Doxycycline 100 mg daily is also used for malaria prophylaxis in many endemic countries. In a recent United Nations

peacekeeping deployment to East Timor, a group of islands within the Malaysian archipelago, 22 of 135 (16%) Australian troops exhibited phototoxic reactions to doxycycline 100 mg daily. This study showed a high percentage of phototoxic reactions to a relatively low dose of doxycycline. UV intensity is primarily determined by factors such as solar angle, latitude, season, ozone levels and cloud cover. As East Timor is located close to the equator and experiences a sunny climate throughout the year, the resultant UV exposure is high. This may account for the high incidence of phototoxic eruptions compared with other studies that were conducted within the Northern hemisphere.<sup>1,2</sup> Clinically, the phototoxic reactions resembled exaggerated sunburn with diffuse erythematous plaques more pronounced on sun-exposed areas such as the face, neck and dorsum of hands. The fact that troops did not experience 'sunburn' prior to deployment at the very similar latitudes, comparable exposure times and photoprotective methods, but experienced continued and pronounced 'sunburn' while doxycycline was prescribed, suggested that the reactions were phototoxic in nature.

What was alarming was the fact that the sunscreen used by the troops did not prevent photosensitive individuals from sunburn. Most of the troops in the study were well educated and motivated in the frequent and adequate use of sunscreen, which was in constant supply throughout the 3-month deployment. The sunscreen type used by all the troops throughout this deployment was a sun protection factor 15 product that contained the following active ingredients: octyl methoxycinnamate 7.5%, octyl salicylate 4% and oxybenzone 3%.

Oxybenzone is a UVA-absorbing benzophenone commonly found in many 'broad spectrum sunscreens'. It constitutes the UVA-absorbing component of the sunscreen and partially absorbs UVA radiation up to 340–360 nm.<sup>4,5</sup> As phototoxicity of tetracycline is mediated in the long wavelength of the UVA spectrum, sunscreens containing oxybenzone as the primary UVA absorber are ineffective for preventing sunburn reactions as the phototoxic wavelengths lie outside the photoprotective wavelengths.

However, there are more effective UVA photoprotectors on the market that offer protection well into the UVA1 spectrum (Table 1). Dibenzoylmethane derivatives offer protection up to 400 nm; however, they may be irritant and photolabile.<sup>6</sup> Newer chemicals that are photostable and offer longwave UVA protection include terephthalylidene dicamphor sulphonc acid and drometrizole trisiloxane.

Physical blockers such as titanium dioxide are also effective in UVA protection. Formulation trends of reducing particle size, however, shift UV reflection from long wavelengths to shorter wavelengths, effectively rendering titanium dioxide as a UVB sunscreen, with less activity in the UVA range. Zinc oxide has a flatter response across the UV range and thus offers greater UVA protection.

Dermatologists frequently prescribe doxycycline and other tetracyclines. The results of this study show a high rate of phototoxic reactions at a low dose of this drug. We have been aware of the phototoxic potential of this group of drugs for

**Table 1.** Ultraviolet (UV) absorbers that provide protection into the UVA1 spectrum (340–400 nm)

UVA filter	Absorption spectrum (nm)
Titanium dioxide	290–350
Zinc oxide	290–380
Bis-ethylhexyloxyphenol methoxyphenol triazine (BEMT, Tinasorb S)	290–380
Butylmethoxydibenzoylmethane (Parsol 1789)	290–390
Terephthalylidene dicamphor sulphonc acid 2% (Mexoryl XL)	290–400
Drometrizole trisiloxane 2% (Mexoryl XS)	290–400
Methylene bis-benzotrizolyl tetramethyl butylphenol (MBBT, Tinasorb M)	290–400

many years; however, we are now better equipped to offer effective protection. While the sunscreen used in this deployment prevented sunburn reactions in the UVB range, it was ineffective in preventing phototoxic reactions to doxycycline.

Not only is there an important need for correct use of sunscreen by the user, but also choice by the physician of the right sunscreen for the job is paramount in providing effective photoprotection.

382 HF Amberley, Queensland,  
Australia and Department of  
Dermatology, Our Lady of Lourdes  
Hospital, Drogheda, Ireland

\*Department of Dermatology,  
Beaumont Hospital, Dublin, Ireland.  
E-mail: davinlim@hotmail.com

D.S.LIM  
G.M.MURPHY\*

## References

- 1 Bjellerup M, Ljunggren B. Differences in phototoxic potency should be considered when tetracyclines are prescribed during summer-time. A study on doxycycline and lymecycline in human volunteers, using an objective method for recording erythema. *Br J Dermatol* 1994; **130**: 356–60.
- 2 Layton AM, Cunliffe WJ. Phototoxic eruptions due to doxycycline—a dose-related phenomenon. *Clin Exp Dermatol* 1993; **18**: 425–7.
- 3 Rosen K, Swanbeck G. Phototoxic reactions from some common drugs provoked by a high intensity UVA lamp. *Acta Derm Venereol (Stockh)* 1982; **62**: 246–8.
- 4 Pathak M. Photoprotection against harmful effects of solar UVB and UVA radiation: an update. In: *Sunscreens. Development, Evaluation and Regulatory Aspects* (Lowe NJ, Shaath NA, eds). New York: Marcel Dekker, 1997: 59–82.
- 5 Baron ED, Stevens SR. Sunscreens and immune protection. *Br J Dermatol* 2002; **146**: 933–7.
- 6 Chetelain E, Gabard B. Photostabilization of butyl methoxydibenzoylmethane (Avobenzone) and ethylhexyl methoxycinnamate by bis-ethylhexyloxyphenol methoxyphenyl triazine (Tinosorb S), a new UV broadband filter. *Photochem Photobiol* 2001; **74**: 401–6.

## Cold urticaria responding to systemic ciclosporin

SIR, A 69-year-old-woman presented with acquired immediate cold contact urticaria of 3 months' duration, characterized by a weal and flare reaction to contact with anything cold, including her lips when she had cold food. She was severely disabled by the condition and was unable to leave her house without having a widespread rash on the face, trunk and limbs. General examination was otherwise unremarkable and laboratory tests including full blood count, immunoglobulins, cold agglutinins and cryoglobulins were all normal or negative. Over the course of 1 year, the following treatments were instigated without success: loratadine, chlorpheniramine, fexofenadine, hydroxyzine, cetirizine, double dose cetirizine, combined with ranitidine on a regular (daily) basis and short courses of oral prednisolone.

In view of the disability, 10 months ago our patient was commenced on ciclosporin 125 mg twice daily (just under 3 mg kg<sup>-1</sup> daily). Within 1 week she noted an improvement such that she was able to leave the house. Four weeks into treatment, lesions were only appearing on the hands and feet and the dose of ciclosporin was reduced to 100 mg twice daily (2.25 mg kg<sup>-1</sup> daily). The dosage was dropped 4 months into treatment to 75 mg twice daily (1.7 mg kg<sup>-1</sup> daily). She has remained in remission on this dose with no side-effects to date and is able to continue a normal pattern of life with minimal recurrence of weals on the extremities only.

Cold urticaria is a rare condition characterized by weal and flare that is triggered by cold, either by direct contact with cold objects or by lowering of core body temperature.<sup>1</sup> Patients may suffer considerable handicap as a result of their symptoms. Treatment is often a challenge and many patients fail to respond to the first-line treatments of oral antihistamines including combination H<sub>1</sub> and H<sub>2</sub> antihistamines. Short-term therapy with oral corticosteroids may partially suppress the symptoms temporarily,<sup>2</sup> but it was unsuccessful here. Desensitization may be helpful but is time-consuming and may be only partially successful.<sup>1</sup>

Chronic urticaria has been shown to respond to ciclosporin in a randomized controlled trial.<sup>3</sup> We are not aware of any published reports of acquired cold urticaria responding to ciclosporin. We believe further studies are warranted to assess the efficacy of ciclosporin in this potentially severely incapacitating condition.

Department of Dermatology,  
University of Manchester Medical  
School, Hope Hospital, Stott Lane,  
Manchester M6 8HD, U.K.  
E-mail: sacha.marsland@virgin.net

A.M.MARSLAND  
M.H.BECK

## References

- 1 Black AK. Cold urticaria. *Semin Dermatol* 1987; **6**: 292–301.
- 2 Black AK, Keahey TM, Eady RA *et al.* Dissociation of histamine release and clinical improvement following treatment of acquired cold urticaria by prednisone. *Br J Clin Pharmacol* 1981; **12**: 327–31.



3 Grattan CE, O'Donnell BF, Francis DM *et al.* Randomized double-blind study of cyclosporin in chronic 'idiopathic' urticaria. *Br J Dermatol* 2000; **143**: 365–72.

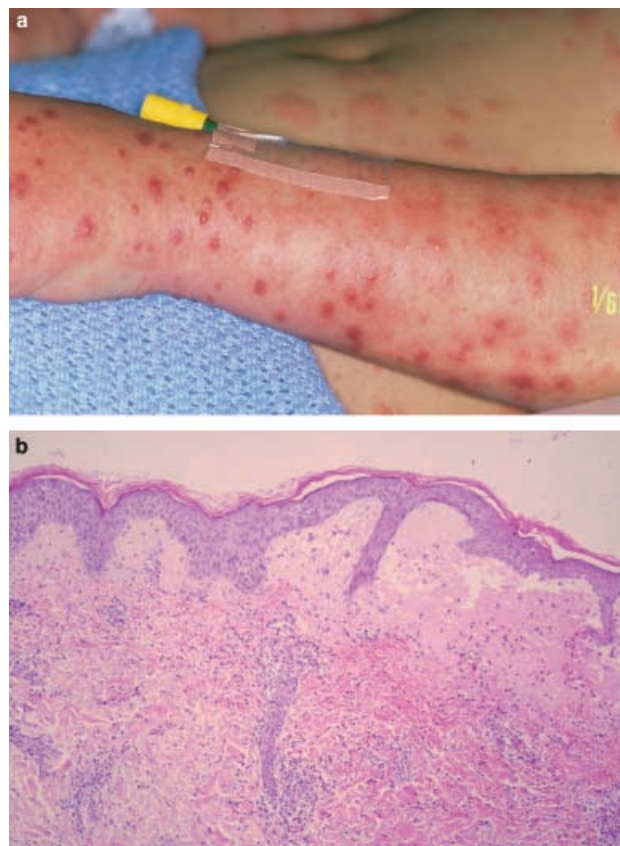
### Severe bullous drug eruption due to sibutramine (Reductil®)

SIR, Sibutramine (Reductil®; Abbott Laboratories) is a new centrally acting weight management drug, devoid of amphetamine-like abuse potential, which inhibits the neuronal reuptake of serotonin and norepinephrine. Structurally it is designated *N*-{1-[1-(4-chlorophenyl)cyclobutyl]-3-methylbutyl}-*N,N*-dimethylamine hydrochloride monohydrate. The primary and secondary pharmacologically active amine metabolites induce weight loss by enhancing satiety and by reducing the decline in energy expenditure during weight loss. The common adverse reactions include headache, dry mouth, insomnia, constipation, and increase in heart rate and blood pressure.<sup>1</sup> We report a new adverse reaction in a patient in whom sibutramine caused the unusual complication of erythema multiforme-like bullous drug eruption.

A 19-year-old Chinese woman with a body mass index of  $24 \text{ kg m}^{-2}$  presented with fever, erosive stomatitis and an erythematous targetoid cutaneous eruption. She had no significant past medical history, and had no history of a preceding viral infection. Two weeks prior to admission, her general practitioner had prescribed her sibutramine 10 mg daily, for weight reduction. She ingested the drug on the day of the consultation, and then on the third, fifth and seventh days after the visit. After the third dose, she developed urticarial plaques over the dorsum of her hands and feet. Two days later similar lesions appeared over the trunk, some of which developed blisters. She consulted a traditional Chinese physician who prescribed traditional Chinese medication on the presumptive diagnosis of varicella. The rash continued to spread extensively over the next 2 days.

On examination, the patient had a cutaneous eruption consisting of erythematous and purpuric targetoid papules and plaques over her trunk and limbs. Some of the lesions displayed a central bulla (Fig. 1a). She had erosions and crusting over her lips as well as ulcers affecting the buccal mucosa and soft palate. However, her conjunctivae and genitalia were unaffected. Her vital signs were stable, and the respiratory, cardiovascular and abdominal systems were unremarkable.

A full blood count showed a raised white cell count of  $13.4 \times 10^9 \text{ L}^{-1}$  with significant eosinophilia ( $1.2 \times 10^9 \text{ L}^{-1}$ ). Renal and liver function tests were normal. Levels of C3 and C4 were normal, and antinuclear antibody was absent. Tzanck smear of a bulla did not demonstrate any multinucleate giant cells. Serological tests for herpes simplex and varicella infections were negative, and culture for herpes simplex virus was negative. Skin biopsy from a bulla on the right thigh showed subepidermal bullae with eosinophils, red cell extravasation, and a superficial perivascular infiltrate consisting of eosinophils and lymphocytes. The epidermis was oedematous but keratinocyte necrosis was absent (Fig. 1b). These findings were consistent with a drug eruption. The



**Figure 1.** (a) Targetoid eruption with central bulla over the trunk and left forearm. (b) Subepidermal bullae containing eosinophils, red cell extravasation and a superficial perivascular infiltrate consisting of eosinophils and lymphocytes. The epidermis was oedematous but keratinocyte necrosis was absent (haematoxylin and eosin; original magnification  $\times 100$ ).

patient was treated with oral prednisolone, and she improved substantially by the fourth day of admission.

Our patient had a bullous drug eruption simulating erythema multiforme. As the eruption had occurred before the patient ingested traditional Chinese medicine, the only offending drug was sibutramine. Because of the rare occurrence of this adverse reaction, an extensive search of the literature and of the database of the drug manufacturer, Abbot Laboratories, was made. However, no similar adverse event has been reported. For comparison, we examined the side-effects of a drug with a similar mechanism of action. Venlafaxine, although structurally different from sibutramine, is an antidepressant that inhibits neuronal serotonin and norepinephrine reuptake. It is designated (R/S)-1-[(2-dimethylamino)-1-(4-methoxyphenyl)-ethyl] cyclohexanol hydrochloride. Included in its list of side-effects is erythema multiforme.<sup>2</sup> In an open-label study conducted to assess patient acceptance and safety of venlafaxine in 58 geriatric patients, one patient developed a rash that was judged to be a serious drug-related side-effect. However, it resolved without medical sequelae after venlafaxine was discontinued.<sup>3</sup>

This is the first report of a patient with a severe bullous eruption related to sibutramine. When treating patients with obesity, physicians should be familiar with this new drug, its indications for prescription, and its rare but potentially severe adverse effects.

National Skin Centre, 1 Mandalay  
Road, Singapore 308205  
E-mail: bkgoh@nsc.gov.sg

B.K. GOH  
P.P.L. NG  
Y.C. GIAM

## References

- McNeely W, Goa KL. Sibutramine: a review of its contribution to the management of obesity. *Drugs* 1998; **56**: 1093–124.
- Joint Formulary Committee. *British National Formulary* 42. London: British Medical Association, Royal Pharmacological Society of Great Britain, 2001: 196.
- Khan A, Rudolph R, Baumeister B *et al.* Venlafaxine in depressed geriatric outpatients: an open-label clinical study. *Psychopharmacol Bull* 1995; **31**: 753–8.

## Unusual, rapidly growing ulcerative genital mass due to herpes simplex virus in a human immunodeficiency virus-infected woman

SIR, Herpes simplex virus (HSV) type 2 infection is common in human immunodeficiency virus (HIV) type 1-infected subjects, and generally causes classical vesicular herpetic genital lesions<sup>1</sup> with several recurrent episodes,<sup>2</sup> sometimes severe and associated with extensive genital ulcerations and prolonged viral shedding.<sup>3</sup> Bacterial or fungal superinfections may occur.<sup>3</sup>

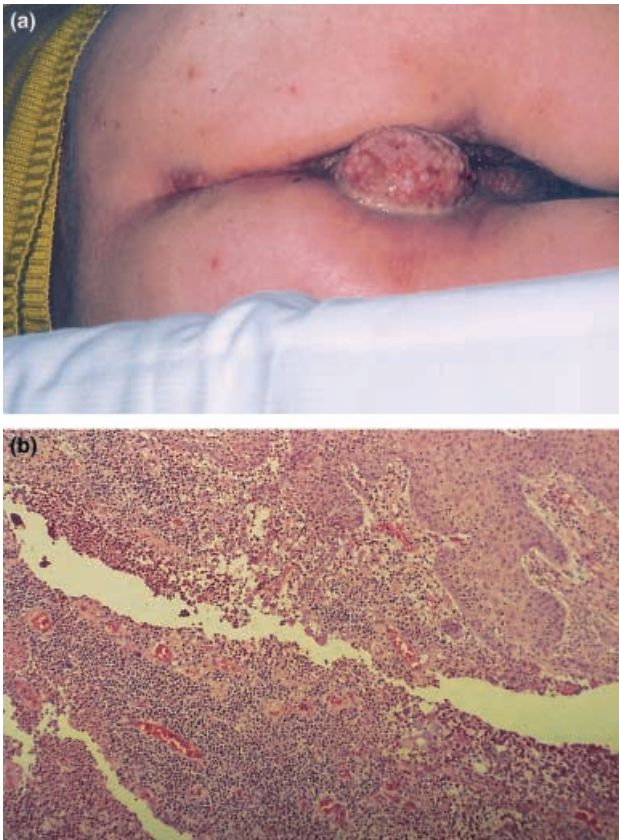
We report an HIV-infected woman with a history of recurrent genital HSV 2 infection who developed a rapidly growing ulcerative genital mass while on highly active antiretroviral therapy (HAART). A 39-year-old HIV+ woman with a previous history of severe immune depression [CD4 cell count 7 mm<sup>-3</sup> in 1996, when she had cytomegalovirus (CMV) retinitis] presented to us in June 2000 with a 10-day history of a painful, nonulcerative mass of the left labium majus extending to the perianal region. The left inguinal lymph nodes were swollen and ultrasound showed multiple enlarged hypoechoic lymph nodes. For the previous 14 months she had been on a triple antiretroviral regimen consisting of stavudine, lamivudine and nevirapine. Her CD4 cell count was 880 mm<sup>-3</sup> (22.7% of total lymphocytes), and HIV RNA was < 50 copies mL<sup>-1</sup> (Chiron Quantiplex 3.0 assay; Chiron, Emeryville, CA, U.S.A.). The patient had had a primary genital herpetic infection in 1990 and, due to periodic episodes of recurrence, had been on prophylaxis with oral aciclovir 800 mg daily since 1997. On the presumptive diagnosis of a bacterial superinfection presenting as a genital mass, the patient was treated empirically with amoxicillin/clavulanate for 15 days without any improvement. One month later a biopsy of the mass was performed: tissue cultures for viruses (HSV 1 and 2, CMV and varicella-zoster

virus), fungi, bacteria and mycobacteria (*Mycobacterium tuberculosis* and atypical mycobacteria) were negative, as were serological tests for syphilis and *Cryptococcus neoformans*.

Histology showed a chronic dermal and hypodermal inflammatory infiltrate accompanied by pseudoepitheliomatous hyperplasia with multinucleated giant epithelial cells, which suggested herpesvirus infection. Immunohistochemistry was negative for human papillomavirus (HPV) and for the CMV immediate early nonstructural antigen of 72 kDa, but was positive for HSV 2 using rabbit anti-HSV antibodies obtained using antigens prepared by sonication and extraction of HSV 2-infected rabbit cornea cells (Dako LSAB; Dako, Carpinteria, CA, U.S.A.); all the virus proteins are present in the antigens. *In situ* hybridization failed to demonstrate HPV 6, 11, 16, 18, 31, 33 and 51. Polymerase chain reaction (PCR) for HPV was performed using three sets of PCR primers for the L1 open reading frame (ORF) and two sets for E6/E7 ORFs. HPV DNAs in tissue specimens were amplified using PCR primer pairs LIC1 and LIC2/LIC2M, MY09 and MY11, GP17 and GP18, p U-1M-L and p U-2R, and p U-1 M-L and p U-2R-N. Use of PCR failed to reveal HPV DNA in the specimen.

The mass was surgically removed in September 2000 and the patient subsequently treated with intravenous foscarnet 40 mg kg<sup>-1</sup> three times daily for 20 days, on the presumptive diagnosis of an aciclovir-resistant HSV 2 infection. Intravenous cidofovir 5 mg kg<sup>-1</sup> was administered once every fortnight as maintenance therapy.

In December 2000 the patient returned because of the reappearance of a similar genital mass, at the same site, accompanied by left inguinal swelling. Perianal and inguinal ultrasound showed a solid mass with multiple homolateral enlarged hypoechoic lymph nodes. In February 2001 a biopsy of a left inguinal lymph node revealed only nonspecific lymphadenopathy. The genital mass grew rapidly in spite of a new cycle of antiviral therapy with intravenous foscarnet 40 mg kg<sup>-1</sup> three times daily for 3 weeks and despite a high CD4 cell count (644 mm<sup>-3</sup>, 25% of total lymphocytes) and undetectable HIV RNA. At the end of April 2001 the mass had a major axis of 5 cm and had a verrucous appearance (Fig. 1a). It was again surgically removed at the beginning of May and intravenous aciclovir 10 mg kg<sup>-1</sup> was administered three times daily for 3 weeks. Tissue cultures for bacteria, mycobacteria and fungi were negative while viral cultures were positive for HSV 2, and the isolate did not exhibit resistance to aciclovir or foscarnet on antiviral susceptibility testing. A new histological examination of the mass demonstrated a cutaneous, vegetative, ulcerative lesion characterized by pseudoepitheliomatous hyperplasia with severe intracellular oedema, condensation of nucleoplasm in steel-grey coloured nuclei with multinucleated cells and intranuclear inclusions, and a dense dermal infiltrate of mixed acute and chronic inflammatory cells extending into an area of granulation tissue at the base of the ulcer (Fig. 1b). HPV and CMV were negative by immunohistochemistry, and *in situ* hybridization and PCR did not reveal HPV. An immunophenotypic analysis of viral antigens was positive for HSV 1 (using rabbit anti-HSV antibodies obtained using antigens prepared



**Figure 1.** (a) Ulcerative genital mass of the left labium majus. (b) Ulcerative lesion with dermal infiltrate of polymorphonuclear leucocytes, vascular proliferation and multinucleated cells with nuclear inclusions (haematoxylin and eosin; original magnification  $\times 40$ ).

by sonication and extraction of HSV 1-infected rabbit cornea cells; Dako LSAB) and HSV 2 and negative for HPV and Epstein-Barr virus (EBV). This latter analysis was performed on formalin-fixed paraffin-embedded tissue sections by *in situ* hybridization using fluorescent-conjugated EBV-encoded RNA probes complementary to the two nuclear RNAs encoded by EBV. From May 2001 no recurrences of genital herpes have been observed on the same antiretroviral regimen and on oral aciclovir 800 mg daily.

This report is the first description of an ulcerative mass of the genitalia in an HIV 1-infected woman which was likely to have been induced by HSV 1 and/or 2, although a definite causative association cannot be proved as it cannot be excluded that the presence of the active viral infection occurred secondary to the proliferative mass. Assuming that HSV was the stimulus for the tissue growth, this case adds to the previously described atypical manifestations of HSV infections in HIV-infected individuals.<sup>4,5</sup> The detection of both HSV 1 and HSV 2 proteins by immunohistochemistry in the second excision specimen contrasts with the positivity of culture only for HSV 2; it may be that either the antibody preparations used for detection of HSV 1 and 2 proteins lack

specificity or that HSV 1, although present, failed to grow in culture. PCR analysis of the tissue samples should have solved this critical issue, but unfortunately we did not perform this type of analysis.

A similar clinical case (large scrotal lesion) has recently been reported in a man<sup>6</sup> but, in contrast with our patient, he was profoundly immune suppressed. In patients with HIV disease the degree of immune suppression strongly correlates with the HSV reactivation rate and the severity of disease.<sup>7-9</sup> Severe mucocutaneous HSV infections are thought to occur only when cellular immunity is markedly impaired.<sup>8</sup> At variance with this notion, our patient had a well-preserved CD4 cell count.

Others have shown that patients on HAART have restoration even of immune responses specific to HSV, as early as 4 weeks after starting treatment.<sup>10</sup> Perhaps in our patient a deficient restoration of HSV-specific immune responses induced the unusual severity and persistence of the lesions.

Section of Infectious Diseases,  
Department of Pathology,  
University of Verona and  
\*Morbidity, 'Civile Maggiore'  
Hospital, Verona, and †Division of  
Infectious Diseases, Padua Hospital,  
Padua, Italy  
E-mail: masino69@hotmail.com

M. LANZAFAME  
R. MAZZI  
C. DI PACE\*  
M. TREVENZOLI†  
E. CONCIA  
S. VENTO

## References

- 1 Schomogyi M, Wald A, Corey L. Herpes simplex virus-2 infection: an emerging disease? *Infect Dis Clin North Am* 1998; **12**: 47-61.
- 2 Safran S, Ashley R, Houlihan C *et al*. Clinical and serologic features of herpes simplex virus infection in patients with AIDS. *AIDS* 1991; **5**: 1108-10.
- 3 Ball SC. Persistent herpes simplex virus infection. *AIDS Reader* 2001; **11**: 249-51.
- 4 Quinnan GV, Masur H, Rook AH *et al*. Herpesvirus infections in the acquired immune deficiency syndrome. *JAMA* 1984; **252**: 72-7.
- 5 Penneys NS, Hicks B. Unusual cutaneous lesion associated with acquired immunodeficiency syndrome. *J Am Acad Dermatol* 1985; **13**: 845-52.
- 6 Sparling JD, Norwood CW, Turiansky GW *et al*. Diagnostic and therapeutic dilemmas of a large scrotal lesion in an AIDS patient. *AIDS Reader* 2001; **11**: 43-7.
- 7 Augenbraun M, Feldman J, Chirgwin K *et al*. Increased genital shedding of herpes simplex virus type-2 in HIV-positive women. *Ann Intern Med* 1995; **123**: 845-7.
- 8 Bagdades EK, Pillay D, Squire SB *et al*. Relationship between herpes simplex virus ulceration and CD4+ cell counts in patients with HIV infection. *AIDS* 1992; **6**: 1317-20.
- 9 Stewart JA, Reef SE, Pelett PE *et al*. Herpes virus infections in persons infected with the human immunodeficiency virus. *Clin Infect Dis* 1995; **21** (Suppl. 1): 114-20.
- 10 Fox PA, Barton SE, Francis N *et al*. Chronic erosive herpes simplex virus infection of the penis, a possible immune reconstitution disease. *HIV Med* 1999; **1**: 10-18.



### Share of research output in dermatology: a quantitative ranking

SIR, The share of published research seems to be an important indicator for evaluating each country's research activity in a particular field. On the basis of this principle, top-ranking countries in the biomedical field as a whole and also separately for different categories have been reported.<sup>1–10</sup> A study also reported the ranking of different countries in dermatology based on articles and citations using data from the period 1981–1996.<sup>11</sup> However, ranking based on the last decade's data, number of randomized controlled trials (RCTs) originating from a country, and the relationship of research productivity of a country with the impact factor of a journal has not been examined yet. This study was conducted to determine the top-ranking countries in the field of dermatology with respect to research productivity and generation of RCTs, along with the trend over time. In addition, the relationship of research productivity of a country with the impact factor of journals was also examined.

Twenty top-ranking journals, according to impact factor, were selected from a total of 38 journals listed in the category of 'Dermatology and Venereal Diseases' set by Institute for Scientific Information.<sup>12</sup> The selection criteria were that the journal: (i) is available in the Medline database, (ii) covers a broad range of dermatological and related fields, and (iii) publishes articles in English. The Medline database was searched in October 2002 to obtain information on the country affiliation of journal articles published in the selected journals during the period 1991–2000. Only journal articles were included in the analysis, i.e. letters, correspondence, editorials, book reviews and news items were excluded. In the first instance, one of the authors (M.R.) identified all the selected journals in the Medline database and downloaded the data on author affiliation, name of the journal, publication type and publication year. Next, these data were transformed into an Excel spreadsheet. After that, appropriate automatic coding procedures were used to perform descriptive and other specific statistics. We used the Internet to identify country affiliations when this information was not available from Medline. Research productivity of a country was judged by the number of articles affiliated to that country through the corresponding author. The proportion of contributions made by each of the countries during the last decade was ranked in descending order. Shares of 20 top-ranking countries were also generated for each year (1991–2000) to examine the time trend. Nonparametric tests for trend were conducted to elicit any significant change over time. In addition, the relationship between the contribution of each of the 10 top-ranking countries and journal impact factor was fitted into a cross-sectional time-series linear model and estimated using generalized least squares. In this model, the percentage contribution of each country to each journal in a year was considered as a dependent variable and the impact factor of each individual journal in a particular year was considered

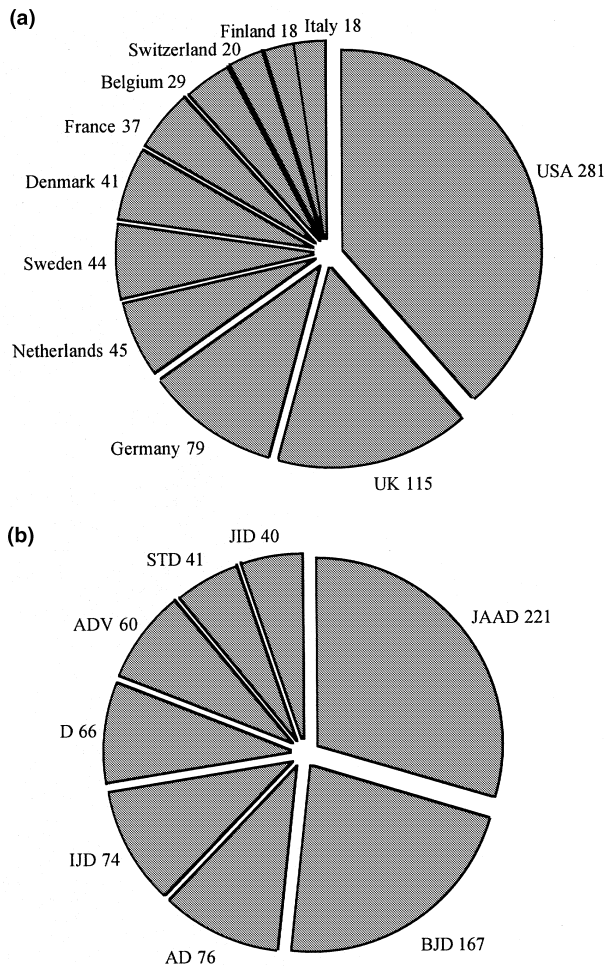
**Table 1.** Share of top-ranking 20 countries for articles in dermatology

Country	1991 (n = 2379)	2000 (n = 3195)	1991–2000 (n = 28 201)
U.S.A.↓	36.8	25.1	29.7
U.K.	11.7	12.1	11.7
Japan↑	8.2	10.4	9.5
Germany↑	5.8	9.7	7.7
Italy	4.9	5.3	5.3
France	3.7	3.6	4.3
Spain	2.5	3.5	3.4
Netherlands	4.4	2.1	2.9
Sweden	3.0	2.4	2.5
Switzerland	1.1	1.9	2.0
Denmark↓	2.5	1.4	1.8
Canada	1.6	1.6	1.7
Finland↑	1.2	1.6	1.6
Belgium	0.8	1.4	1.5
Israel	1.4	1.4	1.4
Australia	1.3	1.6	1.3
Austria	1.1	1.1	1.2
South Korea↑	0.5	1.7	1.0
India	0.8	1.4	0.9
Turkey↑	0.1	1.3	0.6
Other countries↑	6.6	9.8	8.1

Ranking based on total number of articles published during 1991–2000. (Data did not sum up to 100%, because the affiliations of about 1.1% articles were not available from the Medline database.) ↑Share of articles went up significantly over time. ↓Share of articles went down significantly over time. Journals selected (according to impact factor in descending order): *Journal of Investigative Dermatology*, *Sexually Transmitted Diseases*, *Archives of Dermatology*, *British Journal of Dermatology*, *Journal of American Academy of Dermatology*, *Sexually Transmitted Infections*, *Experimental Dermatology*, *Melanoma Research*, *Acta Dermato-Venereologica*, *Archives of Dermatological Research*, *Journal of Dermatological Science*, *Dermatologic Clinics*, *Contact Dermatitis*, *Journal of the European Academy of Dermatology and Venereology*, *Dermatology*, *International Journal of Dermatology*, *European Journal of Dermatology*, *Clinical and Experimental Dermatology*, *Pediatric Dermatology*, *Clinical Dermatology*.

as an independent variable. Five-year data (1996–2000)<sup>12</sup> were fitted into the model, as data on impact factor before that period were not available from the available sources. We performed all the statistical procedures using STATA statistical software.<sup>13</sup> All tests of significance were two-tailed and values of  $P \leq 0.05$  were considered significant.

In total, 28 201 articles were published during 1991–2000 in the selected journals (nine from the U.S.A. and 11 from Europe). Affiliation data were available for 27 881 (98.9%) articles. Table 1 shows 20 top-ranking countries in terms of share of total articles. The U.S.A. contributed 29.7% of the total articles and ranked top among all the countries, followed by the U.K. (11.7%), Japan (9.5%), Germany (7.7%) and Italy (5.5%). In time trend analysis, the share of articles by the U.S.A. ( $P = 0.02$ ) and Denmark ( $P = 0.04$ ) decreased significantly in the last decade (Table 1). On the other hand, Japan ( $P = 0.02$ ), Germany ( $P = 0.01$ ), Finland ( $P = 0.04$ ),



**Figure 1.** Top-ranking countries (a) and journals (b) with the number of randomized controlled trials. JAAD, *Journal of American Academy of Dermatology*; BJD, *British Journal of Dermatology*; AD, *Archives of Dermatology*; IJD, *International Journal of Dermatology*; D, *Dermatology*; ADV, *Acta Dermato-Venereologica*; STD, *Sexually Transmitted Diseases*; JID, *Journal of Investigative Dermatology*.

South Korea ( $P = 0.01$ ) and Turkey ( $P = 0.01$ ) showed a significant upward trend.

In total, 883 RCTs (3.1% of total articles) were published in the selected 20 journals without any positive trend over the period of time ( $P = 0.28$ ). The U.S.A. also ranked top (31.8%) in generating high-grade evidence (RCTs) followed by the U.K. (13.0%) (Fig. 1a). Among the top-ranking countries in dermatology, Japan contributed only 10 RCTs (15th in the world) while Spain had only five (18th in the world) in this field. No countries showed a significantly positive trend for RCTs over the period of time. Journal-wise, the *Journal of American Academy of Dermatology* published most of the RCTs (25.0%) followed by the *British Journal of Dermatology* (18.9%) (Fig. 1b).

The U.S.A.'s contribution was more to the journals with high impact factor ( $\beta = +7.5$ ,  $P = 0.001$ ) while the opposite was true for Spain ( $\beta = -1.0$ ,  $P = 0.01$ ) as elicited by cross-

sectional time-series linear model using generalized least squares. Other top-ranking countries did not show any significant relationship.

Although American publications dominate the biomedical literature, normalizing the proportion of contribution by population will certainly change the order in top-ranking countries. In a study where all journal articles in Medline were analysed for country affiliation, Sweden ranked top when the proportion of contribution was normalized by the population size, and the U.S.A.'s position slipped to seventh.<sup>2</sup> Small European nations and Israel remained in the upper part of the top-ranking countries when the contributions from different countries were normalized by the size of the population. In this study, we preferred to rank the countries according to the total contribution to identify 'who is contributing how much in dermatology'.

There is no doubt that the U.S.A. leads all other countries in productivity of medical research.<sup>1-11</sup> However, its share for research articles in dermatology decreased from 36.8% in 1991 to 25.1% in 2000. The U.S.A.'s contribution, as elicited in our study, was lower (30%) than that reported for the articles published in 24 dermatology journals during 1981-1996 (36%).<sup>11</sup> The U.S.A. showed a similar negative trend for basic science, general medicine, infectious disease, nuclear medicine, ophthalmology and epidemiology research output in the last decade.<sup>1,5-7,9</sup> One study also reported that the U.S.A.'s contribution during the 1980s had also shown a downward trend based on a group of journals.<sup>14</sup> This feature, along with our study, implies that the downward trend in the U.S.A.'s contribution is a continuous phenomenon. On the other hand, the U.K.'s contribution was almost similar (11% in 1981-1996 and 11.7% in 1991-2000). Collective contribution from the top 10 countries decreased slightly from 82% during 1981-1996<sup>11</sup> to 79% as found in our study for 1991-2000 data, which means that other countries are catching up gradually in research in dermatology.

Regarding RCTs, all top-ranking countries contributed almost proportionately except Japan and Spain. Appropriate initiatives in the respective countries are necessary to increase the number of RCTs from these two countries.

There are some limitations of this study. Firstly, although most of the publications had single country affiliation, some studies were conducted in joint collaboration by mixed teams of local and international researchers and only corresponding authors' affiliations were included as the origin of research in the Medline database. Secondly, some articles on dermatology might have been published in other clinical journals. If these factors were taken into account, the actual number for research output for each country would be higher than the results we obtained. However, these situations are not confined to a particular country, but rather are related to all the countries. Thus, the absolute number of articles shown here does not reflect the true situation in terms of research in dermatology, but estimates on the proportion of contribution should not be far from the real situation.

In conclusion, our analysis elicits 20 top-ranking countries for research output in the field of dermatology and reveals

that the shares of the U.S.A. and Denmark decreased while that of Japan, Germany, Finland, South Korea and Turkey increased in the last decade.

Department of Epidemiological and  
Clinical Research Information  
Management, Kyoto University  
Graduate School of Public Health,  
Yoshidakonoe-cho, Sakyo-ku, Kyoto  
606-8501, and \*Department of  
General Medicine and Clinical  
Epidemiology, Kyoto University  
Graduate School of Medicine, 54  
Kawahara-cho, Shogoin, Sakyo-ku,  
Kyoto 606-8507, Japan  
E-mail: rahman@pbh.med.kyoto-u.ac.jp

M. RAHMAN  
J. SAKAMOTO  
T. FUKUI\*

## References

- 1 Rahman M, Fukui T. A decline in the United States share of research articles. *N Engl J Med* 2002; **347**: 1211–12.
- 2 Rahman M, Fukui T. Biomedical publication: global profile and trend. *Public Health* 2003; in press.
- 3 de Jong JW, Schaper W. The international rank order of clinical cardiology. *Eur Heart J* 1996; **17**: 35–42.
- 4 Gagnon RE, Macnab AJ, Gagnon FA. A quantitative ranking of Canada's research output of original human studies for the decade 1989 to 1998. *CMAJ* 2000; **162**: 37–40.
- 5 Rahman M, Sakamoto J, Fukui T. Japan's share of published research in ophthalmology. *Jpn J Ophthalmol* 2003; **47**: in press.
- 6 Morimoto T, Rahman M, Fukui T. International comparison of research productivity in hematology. *Int J Hematol* 2003; **77**: 192–5.
- 7 Rahman M, Sakamoto J, Fukui T. Japan's contribution to nuclear medical research. *Ann Nucl Med* 2002; **16**: 383–5.
- 8 Rahman M, Sakamoto J, Fukui T. Japan's share of articles in orthopedics. *J Orthop Sci* 2002; **7**: 607–9.
- 9 Rahman M, Sakamoto J, Fukui T. Publications in epidemiology journals: Japanese perspectives. *J Epidemiol* 2003; **13**: 96–8.
- 10 Rahman M, Sekimoto M, Morimoto T, Fukui T. Randomized controlled trials conducted in Japan as a comparison with top-ranking countries. *J Epidemiol* 2001; **11**: 46–7.
- 11 Stern RS, Arndt KA. Growth of international contributions to dermatologic literature. *Arch Dermatol* 1999; **135**: 1074–6.
- 12 ISI Journal Citation Reports. Philadelphia: Institute for Scientific Information, 2001.
- 13 STATA Statistical Software, Version 7.0 (Intercooled). College Station, TX: STATA Corporation, 2001.
- 14 Stossel TP, Stossel SC. Declining American representation in leading clinical-research journals. *N Engl J Med* 1990; **322**: 739–42.

## Efficacy of fumaric acid ester monotherapy in psoriasis pustulosa palmoplantaris

SIR, Psoriasis pustulosa palmoplantaris (PPP) considerably affects the quality of life because of its location, its chronic course and its poor response to treatment. Treatment modalities include photochemotherapy, systemic retinoids,

methotrexate and immunosuppressive drugs such as ciclosporin and mycophenolate mofetil,<sup>1–3</sup> which are frequently associated with serious side-effects. Fumaric acid esters (FAE) have been shown to be safe and effective in severe plaque psoriasis.<sup>4–6</sup> Further observations indicate FAE effectiveness even for those complicating forms of psoriasis such as psoriatic arthropathy, nail involvement, erythrodermic and generalized pustular psoriasis<sup>4,5</sup> which are still difficult to treat. However, the efficacy of FAE on isolated PPP has not been explored so far. This report describes the results of an open prospective clinical study with the aim of evaluating the efficacy of FAE monotherapy in patients who suffered from isolated PPP.

Thirteen patients (eight female, five male) from 25 to 78 years of age (mean 52.5 years) suffering from isolated PPP were enrolled for treatment with FAE tablets [Fumaderm®, containing 120 mg dimethylfumarate (DMF) per tablet] for a period of 24 weeks. Patients were seen every 4 weeks for examination and laboratory investigations. The FAE dose was individually adjusted up to a maximum dose of 720 mg (six tablets) per day. Patients who had received active antipsoriatic treatment within the previous 3 weeks were excluded. During this study no accompanying antipsoriatic therapy was allowed except bland topical treatment with petrolatum either without or with 5% salicylic acid. A modified Psoriasis Area and Severity Index (PASI) called Psoriasis pustulosa palmoplantaris Area and Severity Index (PPPASI) was developed (Table 1). The score includes pustules and erosive lesions. A maximum score of 26 can be reached in the PPPASI. The PPPASI score was evaluated for each extremity separately (Table 1) and *P*-values were calculated with a *t*-test using the Microcal Origin program (OriginLab, Friedrichsdorf/Ts, Germany).

All 13 patients were treated for at least 8 weeks. Two patients (15.4%) dropped out after 9 and 11 weeks because of gastrointestinal complaints and increasing lipase values, respectively. Three patients (23.1%) discontinued the study after 8 and 12 weeks because of worsening or insufficient clinical response. A total of eight patients completed the study whose mean dose of FAE was 585 mg per day (SD ± 197.05). Side-effects were flushing (*n* = 6), gastrointestinal complaints (*n* = 9), lymphopenia (*n* = 3), increased liver enzymes (*n* = 3) and increased lipase (*n* = 1). Following dose reduction side-effects were tolerable in most patients.

Results were similar for palmar and plantar lesions. At week 8 two patients had a decrease of PPPASI score of more than 70%, three patients had a decrease between 30% and 70% and in six patients disease was stable with a decrease or increase of PPPASI less than 30%. In one patient palmar lesions increased to PPPASI 30–70% and in another there was an increase of more than 70%.

The palms of the eight patients who were treated for 24 weeks showed a decrease of PPPASI score of more than 70% in two patients, two patients showed a decrease between 30% and 70% and in four patients disease was stable with a decrease or increase of less than 30%. For plantar lesions there was an decrease of PPPASI of more than 70% in three



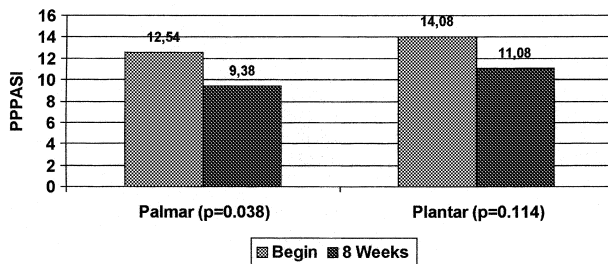
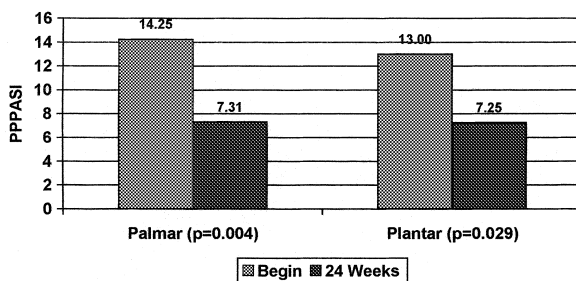
**Table 1.** Psoriasis pustulosa palmoplantar area and severity index

	Palmar right side	Palmar left side	Plantar right side	Plantar left side
Extent	0–6	0–6	0–6	0–6
Desquamation	0–4	0–4	0–4	0–4
Erythema	0–4	0–4	0–4	0–4
Erosion	0–4	0–4	0–4	0–4
Infiltration	0–4	0–4	0–4	0–4
Pustules	0–4	0–4	0–4	0–4
Total	0–26	0–26	0–26	0–26

patients, a decrease of between 30% and 70% in three patients, one had stable disease with PPPASI score decreasing or increasing less than 30% and one patient a score worsening by more than 70%.

The PPPASI after 8 weeks in the entire patient group dropped significantly from 12.5 to 9.4 ( $P = 0.04$ ) for palmar involvement and to a lesser degree from 14.1 to 11.1 ( $P = 0.11$ ) for the soles (Fig. 1). In the eight patients who completed the study after 24 weeks, PPPASI score showed a statistically significant reduction of involvement of both palmar and plantar skin from an initial score of 14.3 to 7.3 (palms,  $P = 0.004$ ) and from 13.00 to 7.2 (feet,  $P = 0.03$ ) (Fig. 2).

The time to relapse was not studied in this trial. The reasons are that our severely affected patients had a previous history of psoriasis pustulosa palmoplantar of more than 6 months. Therefore five of eight patients wanted to continue with successful FAE therapy after completing the study period of 24 weeks.

**Figure 1.** Mean total PPPASI scores of all patients after 8 weeks ( $n = 13$ ).**Figure 2.** Mean total PPPASI scores after 24 weeks ( $n = 8$ ).

The results of this study show for the first time that FAE monotherapy is an effective treatment for psoriasis pustulosa palmoplantar. The newly developed PPPASI score was an easy and valuable new tool. In this trial we found a reduction of PPPASI score of an average of 49% for palmar and 44% for plantar lesions at 24 weeks, i.e. an improvement of 75% at week 24. This was less improvement than in the German multicentre study, which revealed a mean reduction in the PASI score of 80% during a 16-week period,<sup>5</sup> suggesting that FAE monotherapy of PPP is not as effective as FAE therapy in other clinical types of psoriasis. On the other hand, other authors showed a decrease of the PASI score by 50% and a clinical improvement in 70% of the patients after 16 weeks of treatment<sup>4</sup> and an improvement in approximately 50% of patients receiving FAE for at least 3 months.<sup>7,8</sup> Our results also emphasize the need for a long-term treatment when giving FAE, which is typical for this drug.

In our clinical trial high doses of FAE were necessary. The mean dose of the eight patients who completed this trial was 584.4 mg FAE per day. Five of them (62.5%) required the maximum dose of 720 mg FAE per day. In two of these patients the dose could subsequently be reduced while maintaining the good therapeutic result. In one patient only two tablets FAE per day were necessary to achieve a therapeutic response. Only 46% of the patients with psoriasis vulgaris required the maximum dose of six tablets FAE per day.<sup>5</sup>

The side-effects consisted of flushing (46%) and of gastrointestinal complaints (69%) including diarrhoea and stomach ache, lymphopenia (23%) and increases of liver enzymes (23%). In agreement with previous studies side-effects were frequent, but could be controlled by dose reduction and were of transient nature. Individual adjustment of the dose of FAE is advisable to avoid severe side-effects. Gastrointestinal complaints usually disappear with prolonged use of FAE.<sup>8</sup>

Lymphopenia, which occurred in three patients (38%) in our trial, has also been reported in previous studies using FAE.<sup>1</sup> After discontinuation of the FAE treatment lymphopenia usually resolves completely.<sup>6,9</sup> In our trial three patients showed slightly increased liver enzymes. None of these patients had to discontinue the therapy because of this side-effect. Furthermore, it has been reported that increased liver enzymes normalized after reduction of the daily dosage.<sup>8</sup> To finally confirm our findings, further controlled clinical trials are required in PPP.

Department of Dermatology,  
University Hospital Münster,  
Von-Esmarch-Str. 58,  
48149 Münster, Germany  
E-mail: staender@uni-muenster.de

H. STÄNDER  
A. STADELMANN  
T. LUGER  
H. TRAUPE

## References

- 1 Feldman S. Advances in psoriasis treatment. *Dermatol Online J* 2000; **6**: 4.
- 2 Piraccini BM, Tosti A, Iorizzo M, Misciali C. Pustular psoriasis of the nails: treatment and long-term follow-up of 46 patients. *Br J Dermatol* 2001; **144**: 1000–5.
- 3 Rosen K, Mobacken H, Swanbeck G. PUVA, etretinate and PUVA-etretinate therapy for pustulosis palmoplantaris. *Arch Dermatol* 1987; **123**: 885–9.
- 4 Altmeyer P, Matthes U, Pawlak F *et al.* Antipsoriatic effect of fumaric acid derivatives. *J Am Acad Dermatol* 1994; **30**: 977–81.
- 5 Mrowietz U, Christophers E, Altmeyer P. Treatment of psoriasis with fumaric acid esters: results of a prospective multicentre study. *Br J Dermatol* 1998; **138**: 456–60.
- 6 Mrowietz U, Christophers E, Altmeyer P. Treatment of severe psoriasis with fumaric acid esters: scientific background and guidelines for therapeutic use. *Br J Dermatol* 1999; **141**: 424–9.
- 7 Kolbach D, Nieboer C. Fumaric acid therapy in psoriasis: results and side effects of 2 years of treatment. *J Am Acad Dermatol* 1992; **27**: 769–71.
- 8 Thio HB, van der Schroeff JG, Nugteren-Huying WM, Vermeer BJ. Long-term systemic therapy with dimethylfumarate and monomethylfumarate (Fumaderm®) in psoriasis. *J Eur Acad Dermatol Venerol* 1995; **4**: 35–40.
- 9 Nieboer C, de Hoop D, van Loenen AC *et al.* Systemic therapy with fumaric acid derivatives: new possibilities in the treatment of psoriasis. *J Am Acad Dermatol* 1989; **20**: 601–8.
- 10 Altmeyer P, Höxtermann S, Auer T. Verlaufsbeobachtungen der Lymphozytensubpopulationen bei Psoriasis-Patienten unter oraler Therapie mit Fumaraten. *Akt Dermatol* 1996; **22**: 272–7.

## Granulomatous blepharitis successfully treated with tranilast

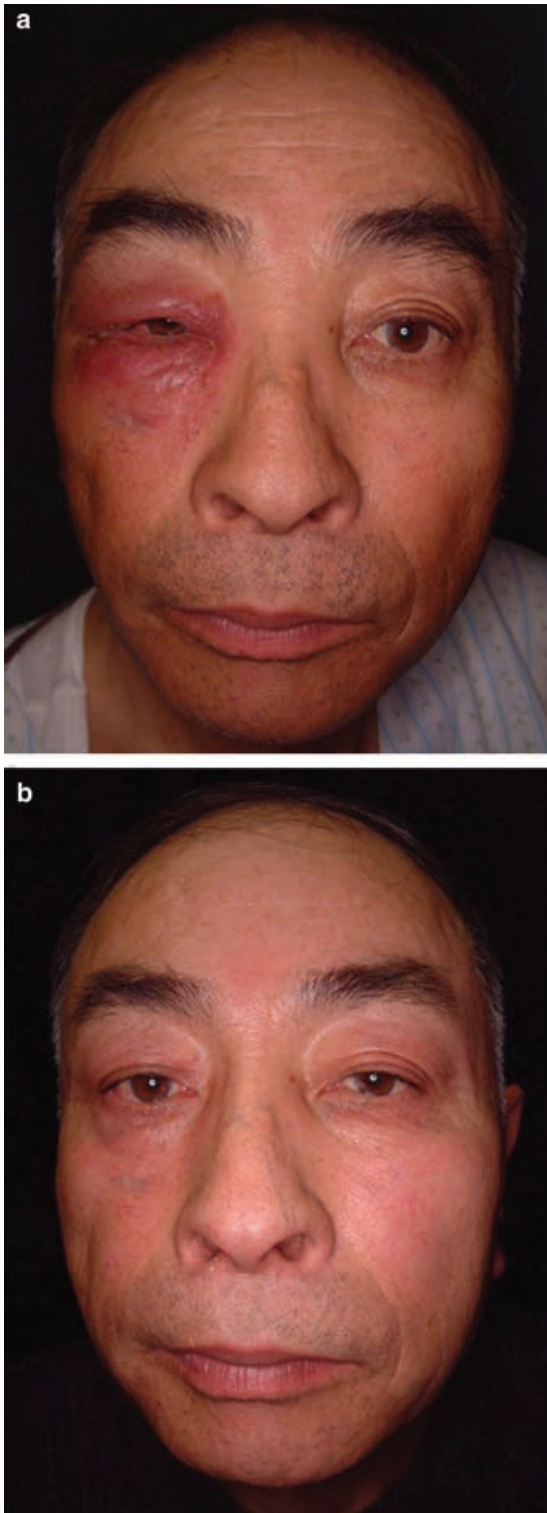
SIR, The complete triad of Melkersson–Rosenthal syndrome is orofacial swelling, facial palsy and lingua plicata. As a symptom on its own, orofacial swelling may occur in several sites such as the lips, cheeks, chin, labial mucosal surfaces and eyelids. Granulomatous blepharitis, which is a symptomatic variant of Melkersson–Rosenthal syndrome, is characterized clinically by diffuse, insensitive but soft or firm swelling of the eyelids and shows a histological noncaseating, epithelioid granulomatous inflammation.<sup>1,2</sup> N-[3,4-dimethoxycinnamoyl]-anthranilic acid (tranilast) inhibits the release of some chemical mediators by mast cells, and is widely used in Japan to treat patients with bronchial asthma, atopic dermatitis, allergic rhinitis, keloid and hypertrophic scars. Several case reports have demonstrated that tranilast is an effective treatment for Melkersson–Rosenthal syndrome and granulomatous cheilitis, a related symptomatic variant involving the lips.<sup>3–5</sup> Here we report the first case of granulomatous blepharitis successfully treated with tranilast.

A 69-year-old Japanese man with a 4-month history of persistent, asymptomatic eruptions on his right eyelid visited our hospital. Physical examination revealed oedematous erythema on his right eyelid with conjunctival hyperaemia with some associated discharge (Fig. 1a). He had no sign of facial palsy or a plicated tongue. An initial clinical diagnosis of Quincke's oedema was made, and the patient was first treated with oral fexofenadine hydrochloride for 1 week, which failed to improve his symptoms. A skin biopsy was taken from the medial-most quarter of the right upper eyelid with a 5-mm diameter dermal biopsy punch. The specimen showed no pathological changes within the horny, or lower epidermal layers, nor epidermal–dermal junction, although there was remarkable oedema and dilated lymphatic capillaries with a diffuse infiltration of histiocyte-like cells including erythrophagocytic cells and mononuclear large cells with a rich basophilic cytoplasm in the dermis and the subcutaneous tissue (Fig. 2a,b). Immunohistochemical analysis demonstrated these histiocyte-like cells were CD68+ (data not shown).

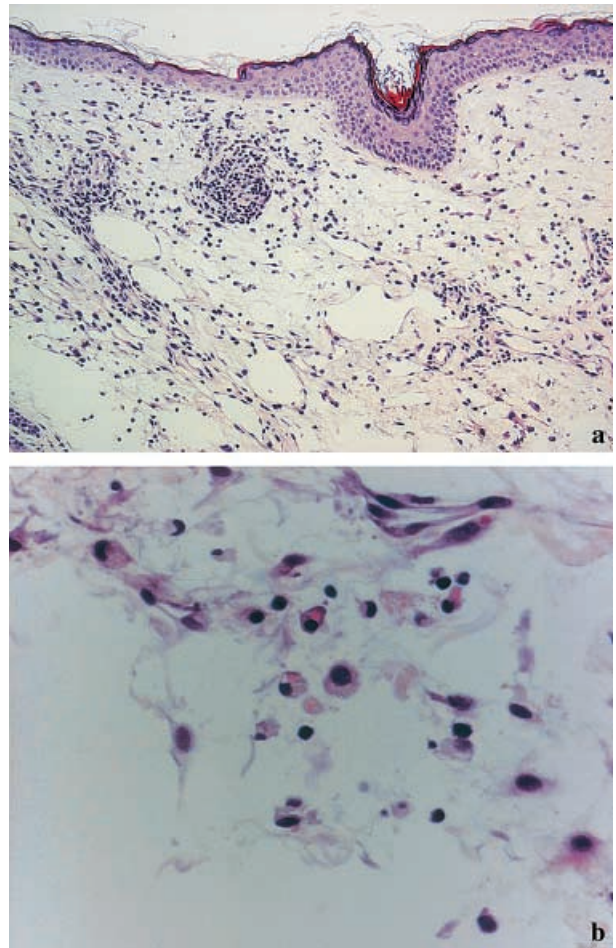
Routine laboratory tests including liver and renal function were within normal limits. Based on the clinical and histological findings, we diagnosed this patient as suffering from granulomatous blepharitis. As tranilast has been reported to be effective in some cases of this condition,<sup>5</sup> we prescribed an oral dose of 300 mg daily for a 7-week period. Three days after the start of this treatment, remarkable improvement was observed both objectively and subjectively. The swelling of right eyelid became dramatically reduced. Four months after treatment withdrawal, no signs of any recurrence were observed (Fig. 1b).

Tranilast has been used in the treatment of atopic dermatitis because of its antiallergic action. It affects the membranes of mast cells, resulting in the inhibition of release of chemical mediators including the histamines and prostaglandins.<sup>6</sup> Tranilast also inhibited collagen synthesis in scleroderma fibroblasts to the same extent as normal fibroblasts. In keloid fibroblasts, tranilast inhibited collagen production more than normal fibroblasts, attesting to its therapeutic potential as an antifibrotic drug.<sup>7</sup> Recently, tranilast was also shown to be a potent oral antiproliferative agent that inhibits the growth and migration of vascular smooth muscle cells.<sup>8</sup> Furthermore, there have been several case reports of the successful treatment of Melkersson–Rosenthal syndrome and granulomatous cheilitis with tranilast.<sup>3–5</sup>

Although the exact therapeutic mechanisms of tranilast in resolving these conditions remain unclear, there is enough evidence to suggest a hypothetical effector mechanism in these diseases. *In vitro* experiments have shown that tranilast directly inhibits the formation of multinucleated giant cells from their precursor human peripheral monocytes.<sup>9</sup> Tranilast was also demonstrated to decrease interferon (IFN)- $\gamma$  and interleukin (IL)-2 production from T-helper 1 cells of patients with atopic dermatitis.<sup>10</sup> Since IL-2 promotes macrophage maturation through macrophage activating factor, macrophage chemotactic factor, and migration inhibition factor production<sup>11</sup> and in addition IFN- $\gamma$  activates macrophages by



**Figure 1.** (a) Oedematous erythema on the right eyelid associated with conjunctival hyperaemia and some discharge was observed just before treatment. (b) Four months after the withdrawal of treatment with tranilast.



**Figure 2.** (a) Histological examination showed a remarkable dermal oedema with dilated lymphatic capillaries and a diffuse infiltration of histiocyte-like cells including mononuclear large cells with a rich basophilic cytoplasm (haematoxylin and eosin, original magnification  $\times 100$ ). (b) Erythrophagocytic cells were detected (haematoxylin and eosin, original magnification  $\times 200$ ).

increasing intercellular adhesion molecule-1 expression,<sup>12</sup> we speculate that the inhibition of IFN- $\gamma$  and IL-2 production is a possible tranilast therapeutic mechanism in granulomatous pathology.

The aetiology of Melkersson–Rosenthal syndrome (and granulomatous blepharitis) is unknown, and there is no standard treatment for this disease. Although tranilast is only currently available in Japan and Korea, the present case is the first report of granulomatous blepharitis successfully treated with this particular cytokine release inhibitor.

Department of Dermatology,  
Hokkaido University Graduate School  
of Medicine, North 15 West 7, Kita-  
ku, Sapporo 060-8638, Japan  
E-mail: mayamaya@viola.ocn.ne.jp

F. IWAO  
D. SAWAMURA  
K. YOKOTA  
H. SHIMIZU



## References

- 1 Yeatts RP, White WL. Granulomatous blepharitis as a sign of Melkersson–Rosenthal syndrome. *Ophthalmol* 1997; **104**: 1185–90.
- 2 Hornstein OP. Melkersson–Rosenthal syndrome: a neuro-mucocutaneous disease of complex origin. *Curr Probl Dermatol* 1973; **5**: 117–56.
- 3 Adachi N, Hagiwara K, Akasaka T. A case of Melkersson–Rosenthal syndrome. *Rinsho Derma* 1995; **49**: 901–3 [Japanese].
- 4 Chiba M, Kobayashi M, Shrohata T *et al.* Successful treatment of cheilitis granulomatosa with potent inhibitors of mediator release: possible involvement of mast cell in the pathogenesis. *Jpn J Dermatol* 1989; **99**: 883–9 [Japanese].
- 5 Kato T, Tagami H. Successful treatment of cheilitis granulomatosa with tranilast. *J Dermatol* 1986; **13**: 402–3.
- 6 Komatsu H, Kojima M, Tsutsumi N *et al.* Study of the mechanism of inhibitory action of tranilast on chemical mediator release. *Jpn J Pharmacol* 1988; **46**: 43–51.
- 7 Yamada H, Tajima S, Nishikawa T *et al.* Tranilast, a selective inhibitor of collagen synthesis in human skin fibroblasts. *J Biochem (Tokyo)* 1994; **116**: 892–7.
- 8 Fukuyama J, Ichikawa K, Hamano S *et al.* Tranilast suppresses the vascular intimal hyperplasia after balloon injury in rabbits fed on a high-cholesterol diet. *Eur J Pharmacol* 1996; **318**: 327–32.
- 9 Mizuno K, Okamoto H, Horio T. Inhibitory influences of tranilast on multinucleated giant cell formation from monocytes by supernatant of concanavalin A-stimulated mononuclear cells. *J Dermatol Sci* 2000; **24**: 166–70.
- 10 Kondo N, Fukutomi O, Shinbara M *et al.* Inhibition of interferon-gamma and interleukin-2 production from lymphocytes stimulated with food antigens by an anti-allergic drug, tranilast, in patients with food-sensitive atopic dermatitis. *Biotherapy* 1994; **8**: 19–22.
- 11 Suga M, Yamasaki H, Nakagawa K *et al.* Mechanisms accounting for granulomatous responses in hypersensitivity pneumonitis. *Sarcoidosis Vasc Diffuse Lung Dis* 1997; **14**: 131–8.
- 12 Fasis S, Burgio VL, Silvestri M *et al.* Multinucleated giant cell generation induced by interferon-gamma. Changes in the expression and distribution of the intercellular adhesion molecule-1 during macrophage fusion and multinucleated giant cell formation. *Lab Invest* 1994; **71**: 737–44.

### Topical treatment of Netherton's syndrome with tacrolimus ointment without significant systemic absorption

SIR, Netherton's syndrome (NS) is a rare autosomal recessive skin disease characterized by ichthyosis linearis circumflexa (ILC), trichorrhexis invaginata and atopy. Mutations of the secretory serine protease inhibitor Kazal type 5 gene (*SPINK5*) are responsible for desquamation and epidermal barrier dysfunction in NS by increased protease activity in the upper stratum corneum.<sup>1</sup> Cutaneous manifestations vary from localized ichthyosis to severe and persistent erythroderma which is often resistant to therapy.

Tacrolimus ointment is a topical immunomodulatory agent successfully tested for the therapy of atopic dermatitis (AD). Its exact mechanism of action in AD remains incompletely

understood, but the binding to a specific immunophilin (FKBP12) inhibits the transcription and synthesis of several proinflammatory cytokines in T cells.<sup>2</sup> Application of 0.1% or 0.03% ointment to extensive areas of atopic eczema does not lead to blood concentrations of more than 1.0 ng mL<sup>-1</sup> in adults<sup>3</sup> and children,<sup>4</sup> or does so only transiently.

Recently, Allen *et al.*<sup>5</sup> reported a marked improvement of NS ichthyosiform erythroderma in three children aged 3, 5 and 14 years using 0.1% tacrolimus ointment, but the blood tacrolimus concentration reached immunosuppressive levels when large areas were treated. Successful therapy with tacrolimus of isolated ILC in a 20-year-old adult has been described by Suga *et al.*<sup>6</sup> but in their paper the blood concentration was not monitored. We have evaluated the efficacy and percutaneous absorption of tacrolimus in a patient with particularly disfiguring erythrodermic NS who was treated with progressively increasing applications of tacrolimus ointment.

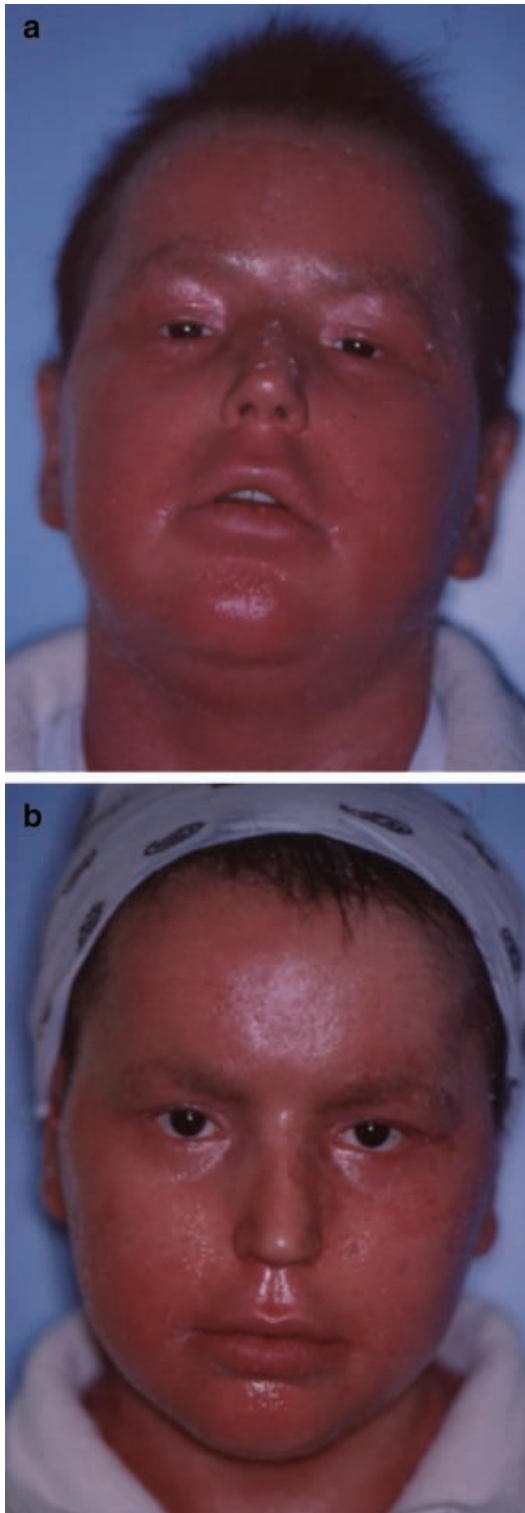A 17-year-old girl who was born from consanguineous parents had congenital ichthyosiform erythroderma, bamboo hairs and food allergies. She also had a history of recurrent bacterial conjunctivitis, otitis, vaginitis and chronic sinusitis. The diagnosis of erythrodermic NS was confirmed by *SPINK5* mutation analysis.<sup>7</sup> She had not responded to previous therapeutic attempts including topical corticosteroids, topical vitamin D analogues, retinoids and antihistamines.

As an in-patient, our patient applied a thin layer of 0.03% tacrolimus ointment twice daily to selected skin areas. The treated surface was extended progressively, and was monitored clinically and biologically. Full blood count, renal and liver function as well as blood tacrolimus level were assessed once weekly 12 h after the last application.

During the first month, the applications were limited to the left half of her face. Approximately 0.5 mg of tacrolimus was used daily. Our patient began to improve, as shown in sequential photographs (Fig. 1a,b). Facial erythema, scaling and pruritus were already less marked after 1 week on the treated side, with a slight diffusion to the right half of the face. After 4 weeks, the treated side of the face was nearly cleared. The treatment was well tolerated except for some slight local burning. Blood pressure, cell counts and chemistry profiles remained within normal ranges. The blood tacrolimus concentration was undetectable (laboratory threshold < 3 ng mL<sup>-1</sup>) at all determinations.

During the second month, the applications were extended to the whole face (1 mg tacrolimus daily), and improvement continued in this region without notable adverse events. The blood tacrolimus level remained below the detection threshold. For the following 4 months, our patient continued tacrolimus therapy on an out-patient basis with applications to the whole face and one breast, corresponding to the use of approximately 1.5 mg of tacrolimus daily.

Improvement of erythema was less marked on the breast than it had initially been on the face, and at follow-up visits a partial relapse was noted on the face that might have corresponded to reduced therapeutic compliance. No adverse effect was recorded and tolerance to treatment remained



**Figure 1.** Clinical appearance (a) before tacrolimus therapy and (b) after 19 days of topical treatment with 0.03% tacrolimus ointment twice daily only on the left half of the face.

satisfactory. During the whole treatment we observed no exacerbation of the known infections. The blood tacrolimus concentration as determined by another laboratory 6 weeks after the extension of applications to the breast was  $1.6 \text{ ng mL}^{-1}$ . All other weekly blood determinations, performed at the same laboratory, indicated undetectable drug levels (laboratory threshold  $< 1.5 \text{ ng mL}^{-1}$ ).

Tacrolimus therapy was discontinued 6 months after the first application. Its therapeutic benefit persisted on the face at 4 months of follow-up, whereas an erythrodermic flare occurred on the trunk.

Patients with NS have a significant risk of systemic absorption after exposure to topically applied treatments such as corticosteroids, paraffin from emollients, and tacrolimus.<sup>5</sup> In all published cases of tacrolimus therapy for NS, however, the topical immunomodulator proved effective.<sup>5,6</sup> Allen *et al.*<sup>5</sup> detected a decrease in blood tacrolimus concentration when the treated surface area or application frequency were reduced and when 0.03% ointment was used instead of the 0.1% adult form.

Our case illustrates the efficacy and tolerability of treatment with 0.03% tacrolimus ointment of limited, but progressively increasing, skin areas of NS. To avoid systemic absorption, we increased the applications progressively and treated less than 15% of the body surface, with regular monitoring of the blood tacrolimus concentration. Our protocol enabled significant limitation of percutaneous absorption. It offers a therapeutic option in NS for the treatment of the most severely involved areas under strict medical control.

*Paediatric Dermatology Unit and  
Department of Dermatology, Centre  
Hospitalier Universitaire, Bordeaux,  
France*

*Correspondence: Professor Alain  
Taïeb, Service de Dermatologie,  
Hôpital St-André, 33075 Bordeaux,  
France. E-mail: alain.taieb@  
chu-bordeaux.fr*

*G.BENS  
F.BORALEVI  
C.BUZENET  
A.TAÏEB*

## References

- 1 Komatsu N, Takata M, Otsuki N *et al.* Elevated stratum corneum hydrolytic activity in Netherton syndrome suggests an inhibitory regulation of desquamation by SPINK5-derived peptides. *J Invest Dermatol* 2002; **118**: 436–43.
- 2 Panhans-Gross A, Novak N, Kraft S, Bieber T. Human epidermal Langerhans cells are targets for the immunosuppressive macrolide tacrolimus (FK506). *J Allergy Clin Immunol* 2001; **107**: 345–52.
- 3 Soter NA, Fleischer AB, Webster GF *et al.* Tacrolimus Ointment Study Group. Tacrolimus ointment for the treatment of atopic dermatitis in adult patients. Part II, safety. *J Am Acad Dermatol* 2001; **44**: S39–46.
- 4 Paller A, Eichenfield LF, Leung DYM *et al.* Tacrolimus Ointment Study Group. A 12-week study of tacrolimus ointment for the treatment of atopic dermatitis in pediatric patients. *J Am Acad Dermatol* 2001; **44**: S47–57.

- 5 Allen A, Siegfried E, Silverman R *et al.* Significant absorption of topical tacrolimus in 3 patients with Netherton syndrome. *Arch Dermatol* 2001; **137**: 747–50.
- 6 Suga YS, Tsuboi R, Hashimoto Y *et al.* A case of ichthyosis linearis circumflexa successfully treated with topical tacrolimus. *J Am Acad Dermatol* 2000; **42**: 520–2.
- 7 Chavanas S, Bodemer C, Rochat A *et al.* Mutations in *SPINK5*, encoding a serine protease inhibitor, cause Netherton syndrome. *Nat Genet* 2000; **25**: 141–2.

## Book review

**Textbook of Facial Rejuvenation** (2002). Edited by Nicholas J Lowe. London: Martin Dunitz Ltd. Hardback, 406pp. ISBN: 1–84184–095–5. Price £125.95.

The last few decades have seen a marked shift of dermatology into cosmetic treatment, in particular in the treatment of the ageing skin. This multi-author textbook, edited by Professor N Lowe and a team of co-editors, has been put together to guide the dermatologist and dermatological surgeon in the range of treatment options which now may be selected and combined to give the best possible facial appearance.

The main 28 chapters have been written by the most experienced and often pioneering dermatologists in their particular field. Broadly speaking it is divided into resurfacing techniques such as peels and laser resurfacing, the use of botulinum toxin, dermal fillers and hair transplant techniques. Other chapters deal with hair transplantation or removal, endoscopic surgery and digital photography. Each chapter is written by an expert in its field with, inevitably, a heavy predominance of authors from the United States, with a smaller number of contributors from the United Kingdom and Europe. At the end there are appendices giving patient advice leaflets and consent forms which could be modified to the individual practitioner's needs.

Most of the chapters are extremely well illustrated with generally excellent photographs. Detailed practical information and advice is to be found in the appropriate chapters and the text and layout of the book leads to easy and almost

addictive reading. Most chapters are well referenced although in a few the references are little dated.

Given the very high quality maintained throughout this book, any criticisms levelled at it must be seen as minor. The 'combination treatment' text box at the end of each chapter, intent on linking various conditions with their potential combined treatments and the relevant chapter reference, is not all that helpful and this is perhaps this is compounded by its dull grey background. A few references are incomplete having been put down as being in press for 2000 or the journal being omitted.

Generally, however, I have found this book to be extremely attractive, easy to read, gives exceedingly good practical and down-to-earth advice combined with excellent clinical photographs. These features combined with the fact that the authors are all international authorities in their field, must make this book one of the most authoritative works presently available. Despite its expense, I really think that this book is a must for anyone with a serious interest in facial rejuvenation and this is one that I would recommend for personal purchase as a day-to-day guide in cosmetic procedures and patient information.

DAVID J. EEDY

## News and Notices

### Twenty-fifth Annual Samuel J. Zakon Award in the History of Dermatology

Papers are now being called for the twenty-fifth annual Samuel J. Zakon Award in the History of Dermatology. This competition is open to historians and dermatologists in practice or training. Manuscripts should be submitted to Mark C. Valentine, M.D., Chairman, Samuel J. Zakon Award Committee, 3327 Colby Avenue, Everett, WA 98201, by 1 November 2003. Essays may relate to any

aspect of the history of dermatology not heretofore published.

Both the Zakon Lectureship and Zakon Award are given in memory of Dr Samuel J. Zakon, outstanding Chicago dermatologist and historian, by his children.

### Paediatric Dermatology Course, Liverpool, UK

This clinical course is held annually in Liverpool and is aimed at Specialist Registrars and recently appointed Consultant

Dermatologists and Paediatricians. An important component of the course is small group clinical teaching. Numbers are limited to 12. The next two-day course will be held on 23 and 24 October. For further details contact: Dr G Sharpe, Course Organiser, The University of Liverpool, Dermatology Unit, Department of Medicine, UCD Building, Liverpool, UK, L69 3GA. Tel: 0151 706 4030; Fax: 0151 706 5842; Email: [lmf@liverpool.ac.uk](mailto:lmf@liverpool.ac.uk).

**11th Meeting of the European Society of Pigment Cell Research  
Gent, Belgium, 17–20 September 2003**

The scientific programme will include invited lectures by world-class speakers and six special lectures, some of which will be presented by outstanding scientists not working in the field. The clinical Satellite Meeting on Saturday is also the official autumn meeting of the Royal Belgian Society of Dermatology: prominent speakers will deliver state-of-the-art lectures on the pathogenesis and treatment of pigmentation disorders and Belgian dermatologists will present papers with a focus on pigmentary disorders and melanoma.

Please contact the Meeting Secretariat: Tel: +31 (0) 40 285 2212; Email: [info@mediscon.nl](mailto:info@mediscon.nl).

For further information see [www.espcrgent2003.org/](http://www.espcrgent2003.org/)

**Clinical Management of Children and Adults with Epidermolysis Bullosa  
23–24 October 2003**

An international Symposium, to be held at Great Ormond Street Hospital for Children, London WC1N 3JH.

Following the postponement of this meeting last year, we are pleased to announce that it will now go ahead this year. The focus of this symposium will be the multidisciplinary care

of patients with epidermolysis bullosa, and we are therefore keen to welcome participants from all relevant disciplines. The meeting is sponsored by DEBRA UK.

If you are interested in participating, please email Jill Hart-Sanderson at [courses@ich.ucl.ac.uk](mailto:courses@ich.ucl.ac.uk), quoting EB2003 or see our website [www.ich.ucl.ac.uk/shortcourses](http://www.ich.ucl.ac.uk/shortcourses).

**Fondation René Touraine  
Fellowships 2003**

Four fellowships of up to Eur 4500 each (for short exchange periods) and one up to Eur 18 000 (for a long exchange period) are given towards supporting a period spent in a research laboratory or clinical department of a different country in order to promote international collaboration.

Application forms for either type of grant may be requested from the office of the Foundation by email: [fond.r.touraine@chu-stlouis.fr](mailto:fond.r.touraine@chu-stlouis.fr) or at the following address: Fondation René Touraine, Hôpital St Louis, Pavillon Bazin, 1, avenue Claude Vellefaux, F-75475, Paris Cedex 10, France; Tel: +33 1 53 72 20 60; Fax: +33 1 53 72 20 61.

Deadline for applications by email or mail: 1 October 2003  
**Scientific Meeting 2003: T-cells and the skin immune system**

**Friday 7 November 2003**

Ministère de la Jeunesse, de l'Education nationale et de la Recherche, 1, rue Descartes, 75005 Paris.

Invited speakers: H. Von Boehmer, A. Trautmann, E. Shevach, E. Vivier, S. Beissert, M. Akdis, J. Prinz, H. Bachelez.

Registration: Fondation René Touraine, Hôpital St Louis, Pavillon Bazin, 1, avenue Claude Vellefaux, F-75475, Paris Cedex 10, France; Tel: +33 1 53 72 20 60; Fax: +33 1 53 72 20 61; by email: [fond.r.touraine@chu-stlouis.fr](mailto:fond.r.touraine@chu-stlouis.fr).