



UNIVERSITÀ  
DEGLI STUDI  
FIRENZE

FLORE

Repository istituzionale dell'Università degli Studi  
di Firenze

### **Myelolipoma Of The Adrenal-Gland Presenting With Dyspepsia And Epigastric Pain**

Questa è la Versione finale referata (Post print/Accepted manuscript) della seguente pubblicazione:

*Original Citation:*

Myelolipoma Of The Adrenal-Gland Presenting With Dyspepsia And Epigastric Pain / Muraro GB; Melone F; Dami A; Farina U; Colagrande S. - In: UROLOGIA INTERNATIONALIS. - ISSN 0042-1138. - STAMPA. - 52:(1994), pp. 217-219.

*Availability:*

This version is available at: 2158/318890 since:

*Terms of use:*

Open Access

La pubblicazione è resa disponibile sotto le norme e i termini della licenza di deposito, secondo quanto stabilito dalla Policy per l'accesso aperto dell'Università degli Studi di Firenze (<https://www.sba.unifi.it/upload/policy-oa-2016-1.pdf>)

*Publisher copyright claim:*

(Article begins on next page)

G.B. Muraro<sup>a</sup>

F. Melone<sup>a</sup>

A. Dami<sup>a</sup>

U. Farina<sup>a</sup>

S. Colagrande<sup>b</sup>

<sup>a</sup> Department of Urology, National Institute of Research INRCA, and

<sup>b</sup> Sezione di Radiodiagnostica, Dpto. Fisiopatologia Clinica, University of Florence, Italy

**Key Words**

Adrenal myelolipoma

Adrenal benign neoplasms

Adrenal 'incidentalomas'

Adrenal masses, nonfunctioning

Ultrasound

CT

MRI

Symptoms

Diagnosis

# Myelolipoma of the Adrenal Gland Presenting with Dyspepsia and Epigastric Pain

**Abstract**

Myelolipomas are rare benign neoplasms of the adrenal glands, characterized by the presence of adipose tissue and elements of bone marrow in various degrees of differentiation. Usually asymptomatic, they are discovered incidentally or at autopsy; sometimes larger masses may cause local symptoms. We report clinical, radiologic and therapeutic aspects of a large myelolipoma of the right adrenal gland, presenting with unusual epigastric symptoms.

**Introduction**

Myelolipomas of the adrenal gland are rare cortical, nonsecreting, benign neoplasms, characterized by the presence of both adipose tissue and elements of the bone marrow in various stages of differentiation [1-3].

It has been suggested that the myelolipoma is related to the high ACTH levels of Cushing's disease [4], but most cases have been found in patients with a normal hormonal function. It is more frequent in males in their 40s and 50s [5]; 70% of cases are asymptomatic and discovered incidentally or at autopsy and usually classified as adrenal 'incidentalomas'; larger masses may cause local symptoms [5]. We report a case of myelolipoma of the right adrenal gland presenting with dyspeptic symptoms.

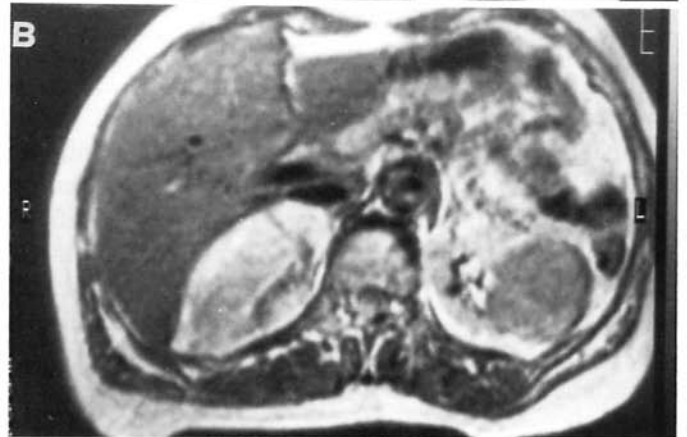
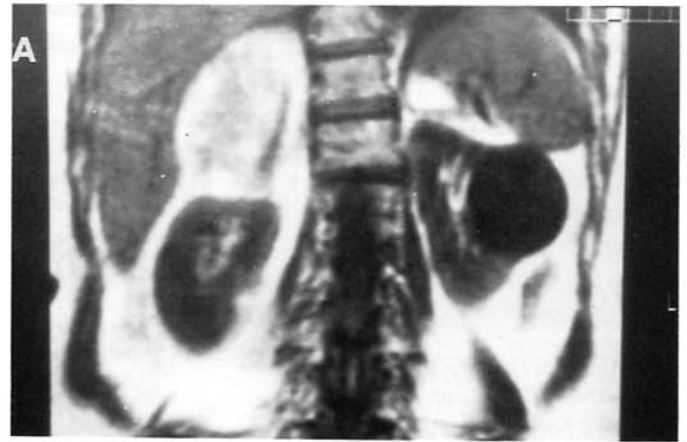
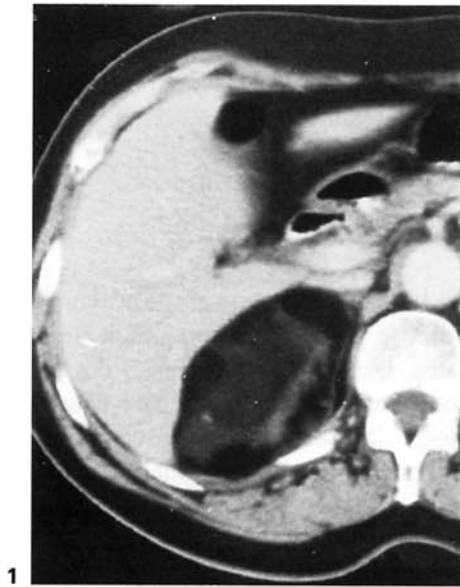
**Case Report**

D.T., a 63-year-old female, was admitted to our hospital for dyspepsia and epigastric pain. Symptoms began 2 years previously and had worsened during the preceding 2 months with the onset of pyrosis and abdominal meteorism. A sonographic scan of the abdomen

revealed a solid hyperechogenic mass about 10 cm in size which replaced the right adrenal gland. CT showed an ovoid adrenal mass with a clear-cut outline, touching the liver and displacing the right kidney into a lower position, without evidence of infiltration of surrounding tissues. The mass had the density of the adipose tissue (negative values in Hounsfield scale) and hyperdense areas were present. After intravenous contrast medium no mass impregnation was registered (fig. 1).

An additional MRI was performed and confirmed the prevalence of adipose tissue in the mass. T1-weighted images demonstrated a typical high signal with a short T1; in T2-weighted images the intensity of the signal was intermediate between muscle and water, superimposable on the retroperitoneal and subcutaneous fat signals. In homogeneous areas could be seen in T1-weighted images, being related to the presence of myeloid tissue and confirming the diagnosis of myelolipoma. A dilation of the stomach secondary to the compression of the mass on the duodenum was also noted (fig. 2).

Surgery was performed through a thoracoabdominal incision and revealed the presence of an ovoid yellowish grey mass just above the upper pole of the right kidney, compressing the duodenum and the inferior surface of the liver. No sign of infiltration was detected and the tumor was removed by smooth dissection. The histopathologic examination confirmed the clinical diagnosis of adipose tissue containing myeloid elements with different degrees of maturation. The patient was discharged completely recovered 8 days after surgery, and a sonographic scan 18 months later demonstrated the right kidney in its proper position with no evidence of local recurrence.



**Fig. 1.** CT. Right adrenal mass with a clear-cut outline, not infiltrating surrounding organs; it has the same density as adipose tissue. Inhomogeneous areas are evident, related to the presence of myeloid tissue. No impregnation after the intravenous administration of contrast medium is demonstrated.

**Fig. 2.** MRI. **A** T1-weighted retroperitoneal coronal scan. **B** Proton density-weighted transhepatic axial scan. Right adrenal enlargement embedded into the liver and displacing the right kidney, without peritumoral infiltration. The adipose content has the typical high signal in T1-weighted scans; signal intensity is intermediate between muscle and water as compared with the simple cyst of the left kidney. Inhomogeneous areas are evident as in CT. Gastric dilation is evident as a consequence of duodenal compression.

## Discussion

Myelolipomas and their histological aspects were first described by Oberling in 1929. Studies of autopsies show an incidence rate from 0.08% [13] to 0.2%, with a peak between the ages of 40 and 60; the myelolipoma is frequently associated with diabetes, obesity and hypertension. Its nature is uncertain and most authors consider it to be a benign neoplasm, while others believe it to be a hamartoma [6]. Most cases are asymptomatic and discovered incidentally; symptoms are reported as a consequence of hemorrhagic rupture or compression of the neighboring structures: abdominal pain, dyspnea [7], he-

maturia [8], nephrotic syndrome [9]. Generally they are identified by sonography because of the characteristic echogenicity of the adipose tissue [10], but differential diagnosis with an angiomyolipoma of the upper pole of the kidney or an adrenal nonfunctioning neoplasm may be required [11]. CT is very sensitive and can illustrate small lesions better, but abnormalities of 1.0 cm can also be detected by MRI. MRI has the distinct advantage of distinguishing between the various types of tumors, particularly in T2-heavily weighted images [12–14] even if a subacute intratumoral hemorrhage could simulate the myeloid component in a nonfunctioning carcinoma. Surgical removal is recommended for myelolipomas larger

than 5 cm [1]. A strict follow-up is required for smaller asymptomatic masses [14].

We do not believe that needle biopsy, reported by other authors, can be clinically useful. Our case presented a peculiar symptomatology characterized by dyspepsia and epigastric pain, not related to food intake, but to the com-

pression of the duodenum as shown with MRI (fig. 2). Modern imaging techniques played an irreplaceable role in diagnosing the nature of the adrenal mass because of their high specificity and sensitivity and in the planning of surgery performed extraperitoneally because of the complete absence of peritumoral tissue invasion.

---

## References

- 1 Haab F, Ponsot Y, Rolloy P, Fouret P, Gattengo B, Thibault P: Myéolipome surrénalien. Revue de la littérature – à propos d'un cas. *Prog Urol* 1991;1:313–318.
- 2 Rubin HB, Hirose F, Benfield J: Myelolipoma of the adrenal gland: Angiographic findings and review of the literature. *Am J Surg* 1975; 130:354.
- 3 Noble MJ, Montague DK, Levin HS: Myelolipoma: An unusual surgical lesion of the adrenal gland. *Cancer* 1982;49:952–958.
- 4 Bennett BD, McKenna TJ, Haugh AJ, Dean R, Page DL: Adrenal myelolipoma associated with Cushing's disease. *Am J Clin Pathol* 1980; 73:443–447.
- 5 Kazan E, Engel IA, Zirinsky K, Ho Auh Y, Rubenstein WA, Reckler JM, Markisz JA: Sectional imaging of the adrenal glands. Computed tomography and ultrasound; in Darracott Vaughan Jr E, Carey RM (eds): *Adrenal Disorders*. New York, Thieme Med Publ, 1989, p 37–80.
- 6 Amberson JB, Gray GF: Adrenal pathology; in Darracott Vaughan Jr E, Carey RM (eds): *Adrenal Disorders*. New York, Thieme, 1989, pp 13–36.
- 7 Del Gaudio A, Solidoro G: Myelolipoma of the adrenal gland: Report of two cases with a review of the literature. *Surgery* 1986;99:293–301.
- 8 Behan M, Martin EL, Mueke EC, Kazan E: Myelolipoma of the adrenal: Two cases with ultrasound and CT findings. *AJR* 1977;129: 993–996.
- 9 Danjani I, Katz SM, Catalano E, Mason O, Schwartz AB: Myelolipoma in a heterotopic adrenal gland. *Cancer* 1979;44:1350–1356.
- 10 Marshall G, Oyen R, Rigautz H: Diagnostica per immagini delle surrenopatie; in Dalla Palma P (ed): *Progressi in radiologia. Radiurologia* 1991. Trieste, Lint, 1991, pp 113–127.
- 11 Wilhelmus JL, Schrodt GR, Alberhasky MT, Alcorn MO: Giant adrenal myelolipoma: Case report and review of the literature. *Arch Pathol Lab Med* 1981;105:532–535.
- 12 Markisz JA, Kazan E: *Magnetic Resonance Imaging of the Adrenal Glands*. New York, Thieme Med Publ, 1989, pp 289–297.
- 13 Vick CW, Zema RK, Mannes E, Cronan, Walsh JW: Adrenal myelolipoma: CT and ultrasound findings. *Urol Radiol* 1984;6:7–13.
- 14 Dieckmann KP, Hamm B, Pickartz H, Jones D, Bauer HW: Adrenal myelolipoma: Clinical radiologic and histologic features. *Urology* 1987;29:1–8.