



UNIVERSITÀ  
DEGLI STUDI  
FIRENZE

FLORE

## Repository istituzionale dell'Università degli Studi di Firenze

### **Spiral computed tomography versus ultrasound in the follow up of cirrhotic patients previously treated for hepatocellular carcinoma: a**

Questa è la Versione finale referata (Post print/Accepted manuscript) della seguente pubblicazione:

*Original Citation:*

Spiral computed tomography versus ultrasound in the follow up of cirrhotic patients previously treated for hepatocellular carcinoma: a prospective study / Colagrande S; La Villa G; Bartolucci M; Lanini F; Barletta G; Villari N. - In: JOURNAL OF HEPATOLOGY. - ISSN 0168-8278. - STAMPA. - 39:(2003), pp. 93-98. [10.1016/S0168-8278(03)00159-4]

*Availability:*

This version is available at: 2158/311659 since:

*Published version:*

DOI: 10.1016/S0168-8278(03)00159-4

*Terms of use:*

Open Access

La pubblicazione è resa disponibile sotto le norme e i termini della licenza di deposito, secondo quanto stabilito dalla Policy per l'accesso aperto dell'Università degli Studi di Firenze (<https://www.sba.unifi.it/upload/policy-oa-2016-1.pdf>)

*Publisher copyright claim:*

(Article begins on next page)



ELSEVIER

Journal of Hepatology 39 (2003) 93–98

Journal of  
Hepatology

[www.elsevier.com/locate/jhep](http://www.elsevier.com/locate/jhep)

## Spiral computed tomography versus ultrasound in the follow-up of cirrhotic patients previously treated for hepatocellular carcinoma: a prospective study

Stefano Colagrande<sup>1</sup>, Giorgio La Villa<sup>2</sup>, Maurizio Bartolucci<sup>1</sup>, Fabio Lanini<sup>2</sup>,  
Giuseppe Barletta<sup>3</sup>, Natale Villari<sup>1</sup>

<sup>1</sup>Dipartimento di Fisiopatologia Clinica, Sezione di Radiologia Diagnostica, University of Florence School of Medicine,  
Viale Morgagni 85, 50134 Florence, Italy

<sup>2</sup>Dipartimento di Medicina Interna, University of Florence School of Medicine, Florence, Italy

<sup>3</sup>Cardiovascular Disease Unit, Azienda Ospedaliera Careggi, Florence, Italy

**Background/Aims:** To assess the value of hepatic-arterial-phase computed tomography (HAP-CT) versus ultrasound (US) plus  $\alpha$ -fetoprotein (AFP) in the surveillance of cirrhotic patients with previously treated hepatocellular carcinoma (HCC).

**Methods:** Thirty-six cirrhotic patients, treated for single nodular HCC < 4 cm with complete response and no evidence of other focal lesions, were enrolled in a prospective study and underwent simultaneous AFP/US/spiral-CT follow-up every 6 months. Focal lesions were considered recurrences when they appeared as globular enhancement areas (EA) at HAP-CT and increased in size during the follow-up.

**Results:** Fifteen of 36 patients showed at least one focal lesion for a total of 43 EA: 38/43 increased in size, four did not change and one disappeared. EA were first observed after a follow-up of  $9 \pm 4$  (range 6–18) months. At the same time, no patient had either nodular lesion at US examination or diagnostic levels of AFP. In 22 matched lesions, diagnosis by CT was  $8.2 \pm 3.5$  months earlier than by US. In 13 patients, one evolved EA was submitted to US-guided biopsy and histological examination showed HCC in all cases.

**Conclusions:** Periodical spiral-CT examination is more effective than US-AFP in early detection of HCC recurrence in cirrhotic patients successfully treated for HCC.

© 2003 European Association for the Study of the Liver. Published by Elsevier Science B.V. All rights reserved.

**Keywords:**  $\alpha$ -Fetoprotein; Cirrhosis; Diagnosis; Recurrent hepatocellular carcinoma; Spiral computed tomography; Ultrasonography

### 1. Introduction

Hepatocellular carcinoma (HCC) is the fifth most common malignancy worldwide and is commonly observed in the clinical course of chronic fibrotic liver diseases, particularly liver cirrhosis secondary to chronic hepatitis C virus (HCV) and HBV infection [1,2].

Surveillance for HCC in these clinical settings has become part of the clinical practice of hepatologists.

Received 10 December 2002; received in revised form 12 March 2003; accepted 17 March 2003

\* Corresponding author. Tel.: +39-055-437-7673; fax: +39-055-431970.

E-mail address: [s.colagrande@dfc.unifi.it](mailto:s.colagrande@dfc.unifi.it) (S. Colagrande).

Recommended screening for HCC in cirrhosis is based on measurement of  $\alpha$ -fetoprotein (AFP) and ultrasound (US) examination of the liver every 6 months, sensitivity and specificity of US being 71 and 93%, respectively [2,3]. US detects nodular lesions > 20 mm, but has a lower sensitivity when nodules are of 10–20 mm, and is often unable to detect nodules < 10 mm [4]. However, the positive predictive value of US is only 14%, at least in HBsAg carriers [2]. In the absence of specific recommendations, the same approach is currently used also for patients who have been successfully treated for HCC [2,3]. However, in this latter group of patients, the risk of recurrence of HCC and/or appearance of new lesions in other liver segments is dramatically high [5,6]. In addition, data regarding the

follow-up of this particular group of patients are scarce. It is therefore important to improve surveillance in this condition and to assess the effectiveness of different diagnostic techniques in detecting the occurrence of new neoplastic foci as early as possible.

Spiral computed tomography (SCT) allows to scan the upper abdomen in less than 25 s and so the entire liver parenchyma in a single breath hold, during the hepatic arterial phase (HAP) after administration of contrast material. Previous studies showed that HAP-CT has an excellent sensitivity in the detection of HCC < 1 cm [7–10]. To evaluate the role of HAP-CT in the screening for HCC in cirrhotic patients with previously treated HCC, we designed a prospective investigation comparing SCT with ultrasound examination.

## 2. Patients and methods

Thirty-six patients (21 males, mean age  $63.5 \pm 7.4$ , range 50–74 years) with cirrhosis of the liver, referred to the radiological unit, Department of Clinical Pathophysiology, University of Florence School of Medicine from January 2000 to December 2001 for surveillance after treatment for hepatocellular carcinoma (HCC), gave their informed written consent to participate in this prospective study, approved by the local Ethics Committee in November 1999. Cirrhosis was HCV-related in 22, HBV-related in three, and alcoholic in 11 patients. Twenty-one out of the 36 patients studied were in class A and 15 in class B, according to Child–Pugh classification [11]. The previous HCC always appeared as a single nodular lesion with a diameter < 4 cm and was diagnosed by pathological analysis in 14 patients and non-invasive, radiological criteria in the remaining 22 patients, according to the Barcelona EASL – 2000 Conference [3], i.e. focal lesion > 2 cm with arterial hypervascularization, as assessed using two coincident imaging techniques. For this purpose, we performed SCT and magnetic resonance (MR) imaging. All patients were treated by surgical resection ( $n = 8$ ) or percutaneous ethanol injection with complete response and no other focal lesions at both US and SCT, performed 4 weeks later [3]. At that time, AFP was < 10 ng/ml in all patients. Two patients also had a liver angioma, identified at SCT and confirmed by MR.

After treatment, patients underwent surveillance by US and AFP measurements every 6 months. In addition, they underwent SCT every 6 months. US and SCT were performed simultaneously (maximum interval: one week) by independent radiologists that were unaware of the purposes of the study.

### 2.1. Ultrasound

Ultrasound was performed using a 'ASTRO MP' echograph (Esa Ote-Ansaldo, Genoa, Italy) equipped with wide-angle convex probes of 3.5 MHz, pulsed waves and power Doppler module. All US examinations were performed by a skilled radiologist with 20 years of experience in this field.

### 2.2. Spiral computed tomography

SCT was performed using a Somatom Plus (Siemens, Erlangen, Germany) scanner. Spiral scans were obtained cephalocaudal with section thickness of 5 mm and pitch 1.5 (reconstruction 4.5 mm); matrix  $512 \times 512$ ; at 170 or 220 mAs, and 120 kV, in 25 patients. In the remaining 11 patients, who had a longer liver, spiral scans were obtained with section thickness of 8 mm and pitch 1.25 (reconstruction 6 mm). The entire liver parenchyma was thus scanned within a single breath hold of about 20 s. Three acquisitions were obtained in each patient: one before (basal acquisition or direct scan) and two after the intravenous administration of 1.5 ml/kg body weight of non-ionic iodinated contrast material (Ultravist 370 Schering, Berlin, 3 ml/s), respectively. The first enhanced CT scan

started 25 s after the beginning of the injection of contrast material (HAP), the second was initiated 70 s after the bolus (portal venous phase, PVP). Each examination was completed in approximately 5–6 min. The referred parameters allow detection of focal lesions > 3 mm.

Focal lesions observed at SCT were considered suspect for HCC when they appeared either as globular EA or hypovascular lesions at HAP [8,9,12–14]. Occurrence of the 'wash-out phenomenon' at PVP reinforced our suspicion [12]. However, suspect EA (SEA) having a diameter < 15 mm are usually undetectable at either baseline examination and PVP. Transient hepatic attenuation differences (THAD) were defined as perfusion abnormalities that are visible exclusively during HAP; they are usually wedge-shaped, but sometimes they appear round or round-like [15].

All CT scans were evaluated in blind fashion by the examiner and two other devoted radiologists from the SCT service at our Institution, who examined the images independently and were unaware of either the clinical characteristics of the patients or the results of US examination. Disagreement among the readers with regard to presence, number and characters of nodules was solved by consensus. Each EA was assigned, based on its diameter, to one of the following groups: < 5, < 10, > 10 and > 20 mm. All patients with at least one SEA continued with both SCT and AFP/US at 6 months' interval until at least one lesion was suitable for liver biopsy.

### 2.3. Statistical analysis

Data are given as the mean  $\pm$  SD. Correlation between US and SCT was analysed by Spearman's coefficient while chi-square test was used for distribution analysis. The significance level was set at  $P < 0.05$ .

## 3. Results

All patients had a good compliance with the surveillance program. In seven patients, however, SCT and/or US were performed with an interval ranging from 5 to 8 months. The mean follow-up in the 36 patients included in the study was  $18 \pm 6$  (range 6–33) months.

Twenty-one out of these 36 patients developed no focal lesions throughout the follow-up at either SCT and US. In this group of patients, AFP was within the normal range throughout the study. The remaining 15 patients (12 males, mean age  $64.5 \pm 8.0$ , range 50–74 years) showed at least one focal lesion during the follow-up. All but two focal lesions identified by SCT were SEA, the remaining two lesions (observed in patients 7 and 10, respectively) were THAD. We did not observe any hypovascular lesion. Individual data of the 15 patients with SEA are shown in Table 1. In four patients (nos. 1, 2, 4, and 8, Table 1), one SEA occurred in the same place of the previously treated HCC, and was therefore considered a treatment failure. In two out of these 15 patients (nos. 9 and 10) the pre-existing angiomas were also detected. The mean follow-up of these 15 patients was  $20 \pm 5$  (range 12–30) months. SEA were first observed after a follow-up of  $9 \pm 4$  (range 6–18) months. As shown in Table 1, at the first positive SCT, one patient had one SEA, five had two SEA, and nine had three or more SEA, for a total of 43 lesions. Among them, five had a diameter > 10 mm (Table 1); three of these latter lesions were also appreciable at PVP. Thirty-eight out the 43 SEA (88%) showed an increase in their size during the follow-up (Figs. 1 and 2), four did not change and one became undetectable (Fig. 3 and Table 1). Thirty-two evolving SEA

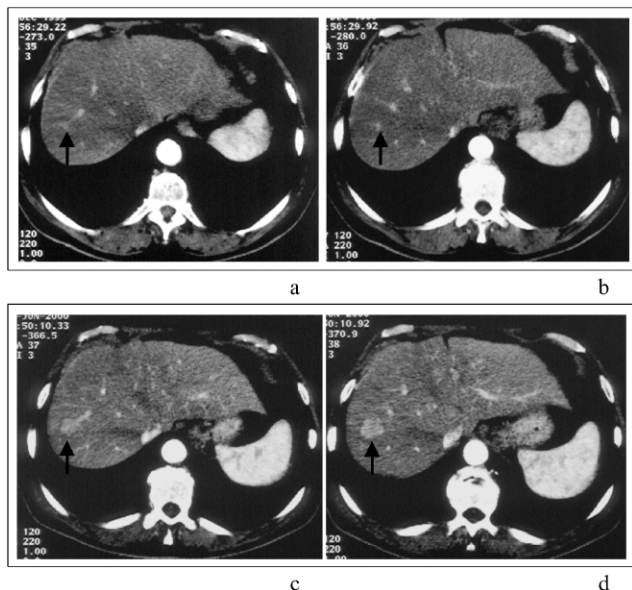
**Table 1**  
Individual data of the 15 patients who showed at least one suspect enhancement area at hepatic arterial phase of spiral computed tomography<sup>a</sup>

Patient no.	Age (years)	Sex	FU (months)	I exam		II exam		III exam		IV exam	
				SCT	Echo	SCT	Echo	SCT	Echo	SCT	Echo
1	62	M	24	<5	–	>10	>10	>10	>10	DD	DD
				<5	–	>10	–	>20	>20B		
				<10	–	>10	–	<20	>20		
				>10R	–	>20	>20	>20	>20		
2	68	F	18	<5	–	<10	–	>10	>10B		
				<10	–	<10	–	<10	–		
				<10R	–	<10	–	>10	>10		
				<10	–	<10	–	<10	–		
3	74	F	30	<5	–	<10	–				
				<5	–	<10	–				
				<10	–	<10	–				
				<10	–	<10	–				
4	71	M	24	<5	–	<10	–	>10	>10	>20	>20B
				<10R	–	<10	–	>10	>10	>10	>10
				>10	–	>10	–	–	–	–	–
5	70	F	27	<5	–	<10	–	<10	–	<10	–
				<5	–	<10	–	>10	>10B		
				<10	–	>10	>10	>10	>10		
						<10	–	>10	>10		
6	64	M	18	<10	–	>10	>10B				
				<10	–	<10	–				
				<10	–	>10	–				
7	54	M	16	<5	–	<10	–				
				<5	–	>10	>10B				
				<5	–	>10	>10				
				<5	–	>10	–				
8	53	M	18	<10	–	>10	–	>20	>20B		
				>10	–	>10	–	>10	>10		
				>10R	–	>10	–	>20	>20		
						<10	–	>10	–	>10	–
9	72	M	12	<5	–	<10	–				
				<5	–	<10	–				
				<5	–	<10	–				
				<5	–	<10	–				
10	63	M	24	>10	–	>20	>20B				
				<5	–	<10	–				
				<5	–	>20	>20B				
11	69	M	18	<5	–	<10	–	>10	>10B		
12	55	M	18	<5	–	<10	–	<10	–		
13	72	M	26	<10	–	<10	–	>10	>10B		
				<5	–	<10	–	<10	–		
				<5	–	<10	–	>10	>10B		
14	50	M	18	<10	–	<10	–	>10	>10		
				<5	–	<10	–				
				<5	–	<10	–				
15	71	M	18	<5	–	<5	–	<10	–		
				<10	–	>10	–	>10	>10B		

<sup>a</sup> B, biopsy; DD, diffuse disease; FU, follow-up; R, local recurrence.

had a detectable increase in their volume at the SCT performed 6 months later; in six more lesions the increase was detected at the 12 months' examination. In addition, four patients developed eight more lesions during the follow-up (Table 1). US performed at the same time of the

first positive SCT did not detect any nodular lesion. US performed 6 months later was able to identify eight lesions in six patients. Twelve months later, US detected 12 lesions in seven more patients. All together, in 22 matched lesions, diagnosis was  $8.2 \pm 3.5$  months earlier by SCT than by US.



**Fig. 1.** Case 10. Serial CT examinations in a patient who underwent partial right resection for single HCC nodule. HAP-CT contiguous slices. The 18 months' CT examination (a,b) showed a SEA < 5 mm (black arrow), that reached 20 mm in diameter at follow-up CT performed 6 months later (c,d).

Finally, in two patients with four evolving lesions, US performed 6 months later was negative (Table 1).

Ultrasound and SCT data were strictly related (Spearman's  $r = 0.995$ ,  $P < 0.0001$ ) without differences in distribution (chi-square test: not significant).

When SCT detected the first SEA, AFP was < 10 ng/ml in 12 patients, and slightly increased (12, 28 and 41 ng/ml) in the remaining three (nos. 8, 1 and 5, respectively). This parameter did not show appreciable changes in eight patients (from  $7.40 \pm 1.40$  to  $9.70 \pm 3.80$  ng/ml), while it increased in seven (from  $15.50 \pm 13.60$  to  $148.40 \pm 175.10$  ng/ml). However, AFP became > 100 ng/ml only in two patients (nos. 8 and 15) and > 400 ng/ml in the patient (no. 1) who developed a diffuse disease.

In 13 patients, one evolved SEA was submitted to US-guided biopsy. Histological examination showed HCC in all cases.

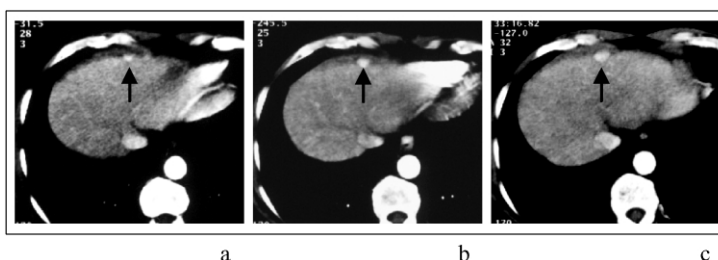
#### 4. Discussion

The limits of serial AFP measurements and repeated US in the screening of HCC are well known. In the opinion of some authors [16,17] these procedures have no substantial impact on the overall survival of cirrhotic patients with HCC. Indeed, the high rate of early recurrence of HCC after PEI or surgery in patients with a single nodule at US remarks the low sensitivity of US in the staging of originally multiple HCC [18]. On the other hand, pathological studies [19] suggest that only half of the nodules < 1 cm in size detected at US correspond to HCC.

Spiral computed tomography (or MR) is recommended for confirmation and staging but not for screening of HCC [3] due to its invasiveness and high cost. However, SCT is very accurate in the diagnosis of HCC, since it recognizes the development of the new, pathological arterial vascularization; the results of previous studies by us [12] and others [7–9] clearly indicate that SCT has a remarkably greater sensitivity than US in identifying HCC nodules, especially when they are < 10 mm. Of course, the neoplastic nature of these nodules cannot be established by biopsy, since they are observed only at HAP-CT, but it can be confirmed with confidence by observing a growth at the following SCT scans. In the present study, SEA were followed up every 6 months using SCT and were considered HCC when they had an arterial enhancement and increased in size over a 6–12-month interval (Figs. 1 and 2). Non-neoplastic nodules, even if they show arterial enhancement, do not increase in size for a long period [20]. The results of liver biopsy, performed on 13 SEA showing an increment in their size, confirm our assumption.

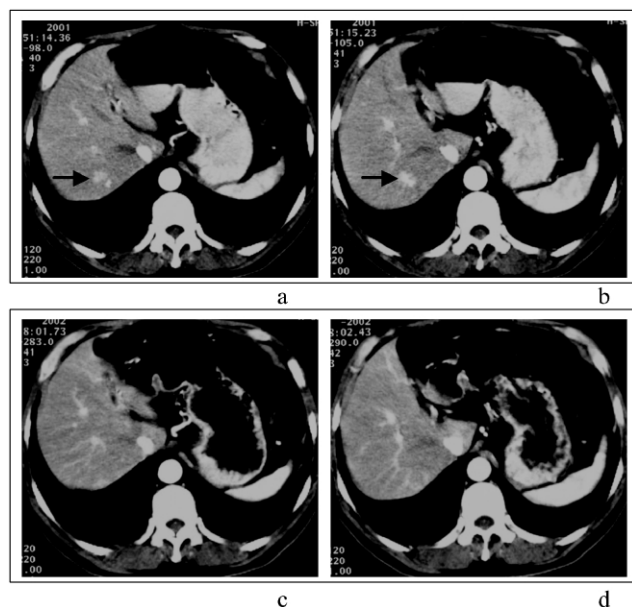
With this approach, diagnosis of HCC in our series of patients was earlier with SCT than with conventional, grey-scale US and could become even shorter if the second, confirmatory SCT is performed earlier (e.g. after 3 months). Data on HCC growth [21] suggest that the time from undetectable to 2 cm tumour is about 4–12 months. Further investigations are needed to identify the most appropriate interval.

Recently, contrast-enhanced ultrasound was found to improve the sensitivity of conventional US in the diagnosis of HCC [22]. Further studies are needed to establish whether



**Fig. 2.** Case 5. CT follow-up at 15 (a), 21 (b) and 27 (c) months. HAP-CT images at the same level of scan. Twelve months' evolution of a SEA (black arrow) located in a poorly detectable site by US.





**Fig. 3.** Case 4. Contiguous slices of HAP-CT at 6 (a,b) and 18 (c,d) months' follow-up examination. The SEA (black arrow) observed at first positive examination (a,b) disappeared at 12 months' follow-up examination (c,d) and it was of unknown cause (perhaps due to a round-shaped THAD).

this new technique would compare more favourably with SCT.

In the current study, 88% of all SEA showed an increment and could therefore be considered recurrent HCC. These data agree with those by Baron et al. [23], who reported that in patients with cirrhosis of the liver, 92% of all enhancement areas at HAP are HCC. With respect to this point, it should be noted that the current investigation was performed in patients with previous HCC. It is well known that a fundamental step in the natural history of HCC is the disappearance of portal vessels, which are substituted with arteries. Furthermore, the total amount of arterial vascularization was found to increase as HCC became more malignant. So, arterial vascularity could be related with the 'age' and/or the degree of dedifferentiation of HCC [24]. Therefore, recurrent tumours are more likely to be hypervascular with respect to primary nodules, so explaining the greater diagnostic accuracy of SCT at HAP in this setting. Whether the results of the current investigation also apply to patients with no previous tumour remains to be established.

In patients with cirrhosis, a small number of enhancement areas observed at the HAP of SCT are due to benign lesions, including THAD, haemangioma, hepatic peliosis, fibrosis, splenic lobule and cryptogenic causes [20,23,25], or, less probably, regenerating or dysplastic adenomatous nodules [26]. It has been reported that only 4% of the latter lesions show an enhancement during HAP and this enhancement precludes malignant transformation in most cases [26]. In our investigation, we found only four (9%) non evolving lesions. With respect to their nature, most of the above

possibilities can reliably be excluded, since all non evolving SEA in this study were not detected when SCT was performed before and 30 days after treatment. We also found one disappearing SEA (Fig. 3): in this case the most probable cause is a THAD, due to a little portal obstruction or artero-portal shunt.

In patients with cirrhosis and HCC, survival has improved because of early diagnosis [27]; so it is highly probable that an early diagnosis of recurrence in patients with previous HCC would also result in an improved survival and/or quality of life. In fact, patients with small tumours may be better candidates for liver transplantation and could remain in the waiting list for a longer time. Liver resection is also more feasible in patients with small lesions, as usually are those detected at HAP-CT. If these options are not suitable, patient could be referred to chemoembolization with cisplatin or doxorubicin, an approach found to improve survival in a recent meta-analysis [28]. Of course, percutaneous treatment such as ethanol injection or radio-frequency ablation is currently not suitable when HCC is detected only at HAP of SCT. Investigations are currently in progress at our Institution aiming at identifying and submit to percutaneous therapy small HCC detected at SCT using 'targeted' US with second-generation contrast agents. Whether this policy would enable an earlier treatment of small tumours remains to be confirmed; anecdotal cases encourage our attempt.

In conclusion, the results of the present investigation suggest that periodical SCT is more effective than conventional US for the screening of HCC in patients with cirrhosis of the liver successfully treated for a previous HCC. All nodules that show both an arterial enhancement at HAP and an increase in their size at subsequent SCT should be considered recurrent HCC. Further studies are needed to clarify whether SCT could be more effective than US also in cirrhotic patients without previous HCC.

## Acknowledgements

The authors gratefully acknowledge Massimo Pinzani, MD, PhD, for helpful suggestions and advice. Supported by grants from the Italian Ministero dell'Istruzione, dell'Università e della Ricerca and the University of Florence, Italy.

## References

- [1] Bosch FX, Ribes J, Borrás J. Epidemiology of primary liver cancer. *Semin Liver Dis* 1999;19:271–85.
- [2] Collier J, Sherman M. Screening for hepatocellular carcinoma. *Hepatology* 1998;27:273–8.
- [3] Bruix J, Sherman M, Llovet JM, Beaugrand M, Lencioni R, Burroughs A, et al. Clinical management of hepatocellular carcinoma. Conclusions of the Barcelona – 2000 EASL conference. *J Hepatol* 2001;35:421–30.

- [4] Bennett GL, Krinsky GA, Abitbol RJ, Kim SY, Theise ND, Teperman LW. Sonographic detection of hepatocellular carcinoma and dysplastic nodules in cirrhosis: correlation of pretransplantation sonography and liver explant pathology in 200 patients. *Am J Roentgenol* 2002;179:75–80.
- [5] Lai EC, Fan ST, Lo CM, Chu KM, Liu CL, Wong J. Hepatic resection for hepatocellular carcinoma. An audit of 343 patients. *Ann Surg* 1995;221:291–8.
- [6] Schwartz JD, Schwartz M, Mandali J, Sung M. Neoadjuvant and adjuvant therapy for resectable hepatocellular carcinoma: review of the randomized clinical trials. *Lancet Oncol* 2002;3:593–603.
- [7] Hollett MD, Jeffrey RB, Nino-Murcia M, Jorgensen MJ, Harris DP. Dual-phase helical CT of the liver: value of arterial phase scans in the detection of small (<1.5 cm) malignant hepatic neoplasms. *Am J Roentgenol* 1995;164:879–84.
- [8] Ohashi I, Hanafusa K, Yoshida T. Small hepatocellular carcinomas: two-phase dynamic incremental CT in detection and evaluation. *Radiology* 1993;189:851–5.
- [9] Takayasu K, Furukawa H, Wakao F, Muramatsu Y, Abe H, Terauchi T, et al. CT diagnosis of early hepatocellular carcinoma: sensitivity, findings, and CT–pathologic correlation. *Am J Roentgenol* 1995;164:885–90.
- [10] Bonaldi VM, Bret PM, Reinhold C, Atri M. Helical CT of the liver: value of an early hepatic arterial phase. *Radiology* 1995;197:357–63.
- [11] Pugh RNH, Murray-Lyon IM, Dawson JL, Pietroni MR, Williams R. Transection of the oesophagus for bleeding oesophageal varices. *Br J Surg* 1973;60:646–9.
- [12] Colagrande S, Fargnoli R, Dal Pozzo F, Bindi A, Rega L, Villari N. Value of hepatic arterial phase CT versus lipiodol ultrafluid CT in the detection of hepatocellular carcinoma. *J Comput Assist Tomogr* 2000;24:878–83.
- [13] Choi BI, Takayasu K, Han MC. Small hepatocellular carcinomas and associated nodular lesions of the liver: pathology, pathogenesis, and imaging findings. *Am J Roentgenol* 1993;160:1177–87.
- [14] Choi BI, Lee HJ, Han JK, Choi DS, Seo JB, Han MC. Detection of hypervascular nodular hepatocellular carcinomas: value of triphasic helical CT compared with iodized-oil CT. *Am J Roentgenol* 1997;168:219–24.
- [15] Itai Y, Matsui O. Blood flow and liver imaging. *Radiology* 1997;202:306–14.
- [16] Craig JR, Klatt EC, Yu M. Role of cirrhosis and development of HCC: evidence from histologic studies and large population studies. In: Tabor E, Di Bisceglie AM, Purcell RH, editors. Etiology, pathology, and treatment of hepatocellular carcinoma in North America. Houston, TX: Portfolio Publishing; 1991. p. 177–90.
- [17] Dodd GD, Miller WJ, Baron RL. Detection of malignant tumors in end stage cirrhotic livers: efficacy of sonography as a screening technique. *Am J Roentgenol* 1992;159:727–33.
- [18] Imari Y, Sakamoto S, Shiomiichi S. Hepatocellular carcinoma not with plain US: treatment with percutaneous ethanol injection under guidance with enhanced US. *Radiology* 1992;185:497–500.
- [19] Nakashima T, Kojiro M. Hepatocellular carcinoma. Tokyo: Springer; 1987.
- [20] Peterson MS, Baron RL. Radiologic diagnosis of hepatocellular carcinoma. *Clin Liver Dis* 2001;5:123–44.
- [21] Barbara L, Benzi G, Gaiani S, Fusconi F, Zironi G, Siringo S, et al. Natural history of small untreated hepatocellular carcinoma in cirrhosis: a multivariate analysis of prognostic factors of tumor growth rate and patient survival. *Hepatology* 1992;16:132–7.
- [22] Numata K, Isozaki T, Ozawa Y, Sakaguchi T, Kiba T, Kubota T, et al. Percutaneous ablation therapy guided by contrast-enhanced sonography for patients with hepatocellular carcinoma. *Am J Roentgenol* 2003;180:143–9.
- [23] Baron RL, Marsh W, Oliver III JH, Confer S, Hunt LE, Peterson MS. Screening cirrhosis for hepatocellular carcinoma (HCC) with helical contrast CT: specificity [abstract]. *Radiology* 1997;205P:143.
- [24] Ueda K, Terada T, Nakanuma Y, Matsui O. Vascular supply in adenomatous hyperplasia of the liver and hepatocellular carcinoma: a morphometric study. *Hum Pathol* 1992;23:619–26.
- [25] Torzilli G, Minagawa M, Takayama T, Inoue K, Hui AM, Kubota K, et al. Accurate preoperative evaluation of liver mass lesions without fine-needle biopsy. *Hepatology* 1999;30:889–93.
- [26] Krinsky GA, Theise ND, Rofsky NM, Mizrahi H, Tepperman LW, Weinreb JC. Dysplastic nodules in cirrhotic liver: arterial phase enhancement at CT and MR imaging—a case report. *Radiology* 1998;209:461–4.
- [27] Bruix J, Llovet JM. Prognostic prediction and treatment strategy in hepatocellular carcinoma. *Hepatology* 2002;35:519–24.
- [28] Llovet JM, Bruix J. Systematic review of randomized trials for unresectable hepatocellular carcinoma: chemoembolization improves survival. *Hepatology* 2003;37:429–42.