



UNIVERSITÀ  
DEGLI STUDI  
FIRENZE

FLORE

## Repository istituzionale dell'Università degli Studi di Firenze

### **Comparison of dobutamine echocardiography and 99mTc-sestamibi tomography for prediction of left ventricular ejection fraction**

Questa è la Versione finale referata (Post print/Accepted manuscript) della seguente pubblicazione:

*Original Citation:*

Comparison of dobutamine echocardiography and 99mTc-sestamibi tomography for prediction of left ventricular ejection fraction outcome after acute myocardial infarction treated with successful primary coronary angioplasty / R. SCIAGRA'; SESTINI S; BOLOGNESE L; CERISANO G; BUONAMICI P; PUPI A.. - In: THE JOURNAL OF NUCLEAR MEDICINE. - ISSN 0161-5505. - STAMPA. - 43:(2002), pp. 8-14.

*Availability:*

This version is available at: 2158/311773 since:

*Terms of use:*

Open Access

La pubblicazione è resa disponibile sotto le norme e i termini della licenza di deposito, secondo quanto stabilito dalla Policy per l'accesso aperto dell'Università degli Studi di Firenze (<https://www.sba.unifi.it/upload/policy-oa-2016-1.pdf>)

*Publisher copyright claim:*

(Article begins on next page)

---

# Comparison of Dobutamine Echocardiography and $^{99m}\text{Tc}$ -Sestamibi Tomography for Prediction of Left Ventricular Ejection Fraction Outcome After Acute Myocardial Infarction Treated with Successful Primary Coronary Angioplasty

Roberto Sciagrà, MD<sup>1</sup>; Stelvio Sestini, MD<sup>1</sup>; Leonardo Bolognese, MD<sup>2</sup>; Giampaolo Cerisano, MD<sup>2</sup>; Piergiorgio Buonamici, MD<sup>2</sup>; and Alberto Pupi, MD<sup>1</sup>

<sup>1</sup>Nuclear Medicine Unit, Department of Clinical Physiopathology, University of Florence, Florence, Italy; and <sup>2</sup>Division of Cardiology, Careggi Hospital, Florence, Italy

---

For patients with acute myocardial infarction who undergo primary percutaneous transluminal coronary angioplasty (PTCA), it is important to promptly identify those in whom a significant delayed improvement of global left ventricular function is to be expected as a result of successful treatment. **Methods:** In 51 patients with acute myocardial infarction who underwent primary PTCA with a good angiographic result, the late outcome of the left ventricular ejection fraction (LVEF) was established after a 6-mo follow-up. In the early phase after infarction (within ~1 wk of infarction), the contractile reserve of the infarct zone was evaluated using dobutamine echocardiography and compared with the assessment of infarct size, infarct severity, and mean tracer activity of the infarct zone obtained using resting  $^{99m}\text{Tc}$ -sestamibi SPECT. Receiver-operating-curve (ROC) analysis was used to define the reliability of the various parameters for identifying the patients with a follow-up LVEF increase of  $\geq 5$  LVEF units. **Results:** Of the 48 patients without restenosis at follow-up, 34 showed significant LVEF improvement. The evaluation of the contractile reserve of the infarct zone achieved an ROC curve area of  $0.75 \pm 0.07$  with 74% sensitivity, 71% specificity, and 73% overall accuracy. Of the  $^{99m}\text{Tc}$ -sestamibi SPECT parameters, the extent of the infarct had no diagnostic value according to ROC analysis. The mean activity of the infarct zone had an ROC curve area of  $0.64 \pm 0.09$  with 82% sensitivity, 50% specificity, and 73% overall accuracy. The infarct severity had an ROC area of  $0.76 \pm 0.08$  (not significant vs. mean activity and vs. contractile reserve) with 77% sensitivity, 71% specificity, and 75% overall accuracy. **Conclusion:** Evaluation of the contractile reserve of the infarct zone using dobutamine echocardiography and assessment of the tracer activity of the infarct zone or infarct severity using  $^{99m}\text{Tc}$ -sestamibi SPECT in the early phase after infarction are able to identify

the patients in whom successful primary PTCA will be followed by significant late LVEF improvement.

**Key Words:** acute myocardial infarction; echocardiography; primary percutaneous transluminal coronary angioplasty;  $^{99m}\text{Tc}$ -sestamibi

**J Nucl Med 2002; 43:8–14**

---

**T**he purpose of reperfusion therapy in patients with acute myocardial infarction is to achieve significant myocardial salvage and to limit the extent of irreversible tissue damage. Salvaged myocardium is defined precisely as the difference between the initial area at risk and the final infarct size. Perfusion SPECT with  $^{99m}\text{Tc}$ -sestamibi before and after treatment has been shown to be highly accurate for this evaluation (1–4). Unfortunately, although the acquisition of SPECT after treatment (usually at the time of the patient's discharge from the coronary care unit or from the hospital) is almost always feasible, performance of a study before reperfusion is often difficult because of technical and logistic problems (5). Perfusion images after treatment alone allow an accurate assessment of the infarct size but no direct visualization of salvaged myocardium (6–10). In clinical terms, the main features of salvaged myocardium are to be an area at high ischemic risk (11) and often to be dysfunctional because of postischemic stunning (12). The introduction of primary percutaneous transluminal coronary angioplasty (PTCA) has significantly improved the chance of restoring a normal coronary blood flow compared with thrombolysis, with a consequent decrease in the rate of ischemic events early and late after reperfusion (13). On the other hand, even a satisfactory angiographic result after primary PTCA with reestablished vessel patency does not always imply an effective tissue reperfusion with conse-

---

Received Mar. 21, 2001; revision accepted Aug. 29, 2001.  
For correspondence or reprints contact: Roberto Sciagrà, MD, Nuclear Medicine Unit, Department of Clinical Physiopathology, University of Florence, Viale Morgagni 85, 50134 Florence, Italy.  
E-mail: r.sciagra@dfc.unifi.it

quent actual myocardial salvage (14). Because the degree of left ventricular impairment, as expressed by the left ventricular ejection fraction (LVEF), remains a major prognostic factor even in patients who have undergone primary PTCA, there is still a need for methods that recognize viability within dysfunctioning segments and thus predict the final outcome of left ventricular function after infarction. The demonstration of contractile reserve within asynergic segments using dobutamine echocardiography is effective for the identification of stunned salvaged myocardium on a regional basis (15–20). Other data also suggest that the demonstration of tracer uptake over the viability threshold in  $^{99m}\text{Tc}$ -sestamibi SPECT after reperfusion predicts reversible regional dysfunction (21). However, in both instances, scanty data are available on the relationship between regional viability and prediction of functional outcome defined in terms of global LVEF improvement. The aim of this study was to verify whether the evaluation of the contractile reserve with dobutamine echocardiography and perfusion imaging with  $^{99m}\text{Tc}$ -sestamibi (both performed on the patient's discharge from the coronary care unit) can identify the patients in whom a significant delayed increase in the LVEF after reperfusion therapy with primary PTCA is to be expected or to be ruled out and to compare the 2 methods in the same patient population.

## MATERIALS AND METHODS

### Patient Population and Study Protocol

The patient population included 51 consecutive patients (43 men; mean age,  $59 \pm 12$  y) with acute myocardial infarction who were admitted to our coronary care unit within 6 h of the onset of symptoms (mean time,  $138 \pm 90$  min; range, 30–360 min) and who were referred to the catheterization laboratory for emergency primary PTCA. The diagnosis of acute myocardial infarction required the presence of typical chest pain lasting  $>30$  min together with a  $>0.1$ -mV ST segment elevation in at least 2 contiguous electrocardiographic leads. Other inclusion criteria were total occlusion of the infarct-related artery; successful primary PTCA (defined as Thrombolysis in Myocardial Infarction trial flow grade 3 (22) and residual stenosis of  $<30\%$  of lumen diameter); and willingness to participate in the study. Patients were excluded in the case of clinical instability or cardiogenic shock and if the echocardiographic window was inadequate for satisfactory visualization of the entire left ventricular wall. Of 62 otherwise eligible patients, 7 subjects (11%) were excluded on the basis of their clinical status and 4 (7%) were excluded because of poor quality of the echocardiographic images. The study protocol included the acquisition of 2-dimensional (2D) echocardiography to evaluate regional wall motion and global left ventricular function on admission of the patient. Dobutamine echocardiography was performed at a mean of  $3 \pm 1.1$  d (range, 2–5 d), and resting  $^{99m}\text{Tc}$ -sestamibi SPECT was performed at a mean of  $6.5 \pm 1.2$  d (range, 4–9 d) after index infarction. Follow-up 2D echocardiography and coronary angiography were repeated 6 mo later. The ethics committee of our institution approved the study protocol.

### Coronary Angiography

All angiograms were analyzed in a random sequence by 2 experienced observers who were unaware of other results. Dis-

crepancies were resolved by consensus. In all patients, the infarct-related artery was analyzed before and after primary PTCA to assess residual stenosis. The same views of coronary arteries were used on follow-up to assess the arterial patency and restenosis rate.

### Low-Dose Dobutamine Protocol

Dobutamine ( $5 \mu\text{g}/\text{kg}$  of body weight per minute) was infused under continuous electrocardiographic and blood pressure monitoring. Infusion was continued for 5 min and then increased to  $10 \mu\text{g}/\text{kg}/\text{min}$  for an additional 5 min. The criteria for early interruption of dobutamine infusion included hypotension, angina, and significant ventricular arrhythmia.

### 2D Echocardiography

Patients were studied at rest and under low-dose dobutamine infusion in the left lateral decubitus using a commercially available scanner (Aloka SSD 870, 2.5- and 3.5-MHz transducers; Aloka Co., Tokyo, Japan). All standard views were acquired and recorded on videotape for off-line evaluation of regional wall motion. For calculation of the LVEF, 2D echocardiographic images were transferred to the hard disk of a TomTec P90 (TomTec Imaging Systems, Munich, Germany) medical off-line computer analysis system and digitized. LVEF was calculated under baseline resting conditions on admission and follow-up examination.

### $^{99m}\text{Tc}$ -Sestamibi SPECT

The tracer dose was 740–925 MBq (20–25 mCi) and was injected to the resting patient lying supine. Images were collected 60 min later using a single-head, large-field-of-view tomographic gamma camera equipped with an ultra-high-resolution collimator and with a 20% window centered on the 140-keV photopeak of  $^{99m}\text{Tc}$ . Sixty projections of 20 s each were acquired. Image reconstruction was performed using filtered backprojection. No attenuation or scatter correction was used. The transaxial slices were realigned along the heart axis. For quantitative evaluation of SPECT images, the short-axis slices, from the first with apical activity to the last with activity at the base, were used. Their count profiles were generated by computer software and plotted onto a 2D volume-weighted polar map.

### Data Analysis

For the echocardiographic evaluation, the left ventricular wall was divided in 16 segments (23), and 2 infarct zones (anterior and inferior, the latter including also the lateral wall) were defined as theoretic maximal risk areas (17). Because the apical lateral and the apical inferior segments can be perfused by anterior (left anterior descending) and posterior (right coronary or left circumflex) arteries, they were considered as overlap segments; thus, each infarct zone included 9 segments (17). Two experienced observers, who were unaware of patient data and image sequence, examined independently the studies and scored the segmental wall motion as follows: 1 = normal, 2 = hypokinesis, 3 = akinesis, and 4 = dyskinesis (17). In evaluating wall motion abnormalities, attention was also paid to systolic thickening in the central portion of the segment. Discrepancies were resolved by consensus. The appropriate infarct zone was identified in each patient and its wall motion score index, which is the sum of the segment scores divided by 9, was derived for baseline and dobutamine echocardiograms. The contractile reserve was defined by the difference between baseline and the dobutamine wall motion score index (17). The LVEF was measured with the modified Simpson's rule algorithm (24). The mean values of 3 measurements of the tech-

nically best cardiac cycles were taken from each examination. Improvement of global LVEF after revascularization was arbitrarily defined as an increase of  $\geq 5$  LVEF units in the follow-up control compared with the baseline value (25).

For SPECT evaluation, the polar map displays were divided into 16 segments, matching with the echocardiographic ones. Using an automated procedure, segment tracer activity was calculated as the total of the normalized counts of the pixels included within the segment divided by the number of pixels. The segment with maximal activity was then normalized to 100, and the activity of the other segments was expressed as a percentage of the peak activity segment (26). Segmental  $^{99m}\text{Tc}$ -sestamibi activity was classified as mild to moderately abnormal if it was  $< 75\%$  and  $\geq 50\%$  of the peak value and as severely abnormal if it was  $< 50\%$  of the peak value. The same infarct zones defined for echocardiography were considered. For each infarct zone, the following parameters were determined: mean  $^{99m}\text{Tc}$ -sestamibi activity value, calculated as the sum of the activity in the related segments divided by 9; extent of infarct, expressed as the total number of segments with abnormal uptake; and severity index of the infarct, calculated as the number of segments with severely decreased  $^{99m}\text{Tc}$ -sestamibi uptake divided by the total number of segments with abnormal uptake.

### Statistical Analysis

Data are expressed as the mean  $\pm$  SD. Comparisons of continuous variables within and between groups were performed using the Student *t* test for paired or unpaired samples, with the Bonferroni correction for repeated measures, as appropriate. The diagnostic power of the echocardiographic and scintigraphic variables for predicting a significant improvement in LVEF was assessed using receiver-operating-characteristic (ROC) curves. Each area was expressed as  $\pm$ SE and compared using Wilcoxon statistics.  $P < 0.05$  was considered statistically significant.

## RESULTS

### Patient Characteristics

The location of the infarct, according to the electrocardiographic changes and the wall motion abnormalities, involved the anterior infarct zone in 26 patients and the inferior infarct zone in 25 patients. The infarct-related artery was the left anterior descending artery in 26 patients, the left circumflex artery in 2 patients, and the right coronary artery in 23 patients. Thirty-three patients were affected by single-vessel coronary artery disease, 12 by 2-vessel disease, and 6 by 3-vessel disease. The LVEF on admission was  $44\% \pm 9\%$ . Primary PTCA was successful in all patients and was performed without complications. Stenting of the dilated infarct-related artery was performed in 26 patients. The peak creatine phosphokinase release reached  $2,922 \pm 2,453$  IU/L.

### Follow-Up

On follow-up at 6 mo, 3 patients had severe ( $> 70\%$ ) stenosis of the infarct-related vessel and, therefore, were excluded from analysis. In the remaining 48 patients, the baseline LVEF ( $43.4\% \pm 8.6\%$ ) increased to  $51.9\% \pm 11.4\%$  at 6 mo ( $P < 0.00001$ ). However, only 34 patients showed a significant ( $\geq 5$  LVEF units) improvement. The

**TABLE 1**

Comparison of Clinical, Angiographic, Echocardiographic, and SPECT Variables in Patients With Versus Those Without Significant LVEF Improvement on Follow-Up

Variable	LVEF increase		P
	$\geq 5\%$	$< 5\%$	
Age (y)	$58.7 \pm 13.4$	$58 \pm 10$	NS
No. of stenotic coronary vessels	$1.6 \pm 0.7$	$1.3 \pm 0.6$	NS
Time to reperfusion (min)	$141 \pm 91$	$134 \pm 92$	NS
CK peak (IU/L)	$2,533 \pm 2,206$	$3,373 \pm 2,560$	NS
Admission LVEF (%)	$43.3 \pm 8.6$	$43.6 \pm 9.1$	NS
Baseline wall motion score index	$2.1 \pm 0.5$	$2.2 \pm 0.5$	NS
Dobutamine wall motion score index	$1.8 \pm 0.5$	$2.1 \pm 0.5$	NS
Delta wall motion score index	$0.26 \pm 0.23$	$0.08 \pm 0.15$	$< 0.05$
Infarct extent	$5.9 \pm 2.5$	$6.4 \pm 2.3$	NS
Mean sestamibi activity	$67.8 \pm 12$	$61.5 \pm 13.5$	NS
Infarct severity index	$0.19 \pm 0.23$	$0.45 \pm 0.26$	$< 0.02$

NS = not significant; CK = creatine phosphokinase; Delta = rest to dobutamine.

6-mo LVEF of these patients was  $55.6\% \pm 8.9\%$ , significantly higher than on admission ( $43.3\% \pm 8.6\%$ ;  $P < 0.00001$ ). The LVEF was unchanged in 14 patients ( $42.8\% \pm 12\%$  at 6 mo vs.  $43.6\% \pm 9.2\%$  on admission; not significant). Table 1 compares the main features of the 2 groups.

### Dobutamine Echocardiography

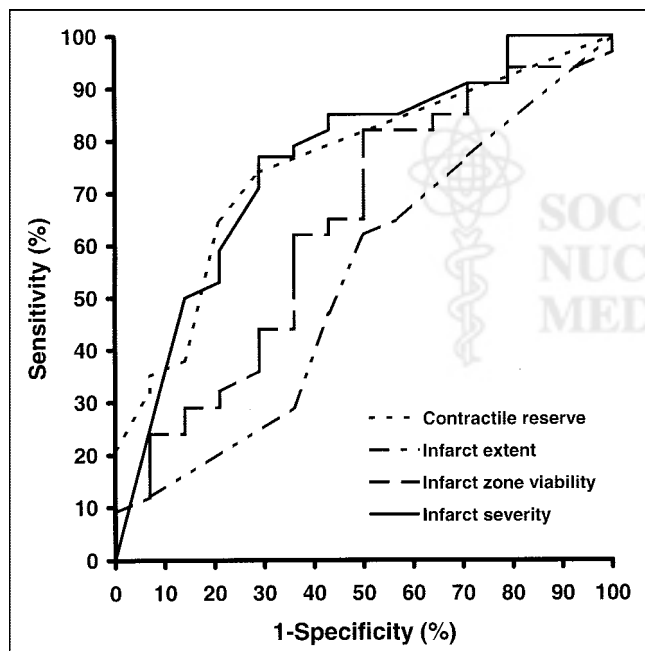
All 48 patients still had an abnormal infarct zone wall motion at the time of dobutamine echocardiography. The mean baseline wall motion score index was  $2.1 \pm 0.47$  (range, 1.22–2.77). The dobutamine infusion protocol was concluded in all patients without complications. According to the comparison between baseline and dobutamine wall motion score index, 19 patients showed no contractile reserve, and the remaining 29 had a decrease in wall motion score index ranging from 0.11 to 0.89 (mean,  $0.35 \pm 0.19$ ). A significant difference in the dobutamine-induced change in wall motion score index was registered between the 34 patients with significant LVEF improvement ( $0.26 \pm 0.23$ ) and the 14 without significant improvement ( $0.08 \pm 0.15$ ;  $P < 0.05$ ). The area under the ROC curve for contractile reserve was  $0.75 \pm 0.07$ . The best threshold of the decrease in wall motion score index to detect patients with significant global LVEF improvement was set at  $\geq 0.11$ . With this cutoff, sensitivity was 74% and specificity was 71%, with 86% positive predictive value, 53% negative predictive value, and 73% overall accuracy.

### $^{99m}\text{Tc}$ -Sestamibi SPECT

Of the 432 segments included within the infarct zones of the 48 patients in whom functional follow-up analysis was

completed, 290 showed an abnormal  $^{99m}\text{Tc}$ -sestamibi uptake, with a mean of  $6 \pm 2.4$  segments per patient (range, 0–9). The mean activity of the infarct zone was  $65.9\% \pm 12.7\%$  (range, 39.8%–86.2%). A severely depressed  $^{99m}\text{Tc}$ -sestamibi uptake was registered in 93 segments, with a mean of  $1.9 \pm 2.2$  (range, 0–7) segments per patient. The severity index of the infarct ranged from 0 to 0.78, with a mean of  $0.27 \pm 0.26$ . Table 1 compares the  $^{99m}\text{Tc}$ -sestamibi SPECT results in patients with LVEF improvement versus those without LVEF improvement. The single variable that was significantly different between the 2 groups was the severity index of the infarct.

Figure 1 and Table 2 compare the diagnostic reliability of the various SPECT variables for recognizing patients with significant LVEF improvement on follow-up. The area under the ROC curve for the extent of infarct was just above the limit of no discrimination. The area under the ROC curve for the mean  $^{99m}\text{Tc}$ -sestamibi activity of the infarct zone was significantly larger ( $P < 0.05$ ). With a cutoff of  $\geq 60\%$  of peak activity, sensitivity was 82%, specificity was 50%, and overall accuracy was 73%. The best ROC curve was obtained using the severity index of the infarct, with an area significantly larger than that of the extent of the infarct ( $P < 0.01$ ) but not larger than that of  $^{99m}\text{Tc}$ -sestamibi activity ( $P = 0.09$ ). Using a cutoff of  $\leq 0.33$ , 77% sensitivity, 71% specificity, and 75% overall accuracy were achieved. No significant difference in the area under the ROC curve was registered between the contractile reserve using dobutamine echocardiography and either the mean  $^{99m}\text{Tc}$ -sestamibi activity or the mean severity index of the



**FIGURE 1.** ROC curves constructed using contractile reserve assessed by dobutamine echocardiography and 3 different parameters derived from sestamibi SPECT for detection of significant late LVEF improvement after primary PTCA.

**TABLE 2**  
Diagnostic Reliability of Various Sestamibi SPECT Variables for Detecting Patients with Significant LVEF Improvement on Follow-Up

Variable	Sensitivity (%)	Specificity (%)	PPV (%)	NPV (%)	Accuracy (%)
Infarct extent	62	50	75	35	58
Mean sestamibi activity	82	50	80	53	73
Infarct severity index	77	71	87	59	75

PPV = positive predictive value; NPV = negative predictive value.

infarct in perfusion SPECT. Accordingly, the diagnostic reliability (sensitivity, specificity, predictive values, and overall accuracy) of the 3 parameters (contractile reserve, infarct severity, and mean  $^{99m}\text{Tc}$ -sestamibi activity) was closely comparable.

## DISCUSSION

The main finding of this study is that  $^{99m}\text{Tc}$ -sestamibi perfusion SPECT and dobutamine echocardiography are able to recognize with satisfactory accuracy the patients in whom the LVEF will spontaneously improve after successful primary PTCA for acute myocardial infarction. Therefore, independent of the extent of the initial area at risk and of the final infarct size, the presence of myocardial stunning caused by the presence of salvaged myocardium as a result of effective reperfusion can be inferred.

Reperfusion therapy is nowadays the standard treatment for patients with acute myocardial infarction who are admitted to the hospital within a reasonable time interval after the onset of symptoms (27). Thrombolytic therapy and primary PTCA have been shown to be effective in limiting the extent of myocardial necrosis, thereby improving symptoms and decreasing the rate of complications and the early and late mortality (13,28). However, the effectiveness of therapy in the individual patient is influenced by several factors and is more difficult to establish. This is especially true for systemic thrombolysis, because even the recanalization of the infarct-related vessel remains uncertain. However, in the case of direct PTCA, a satisfactory angiographic result with reestablished vessel patency does not always imply an effective tissue reperfusion with consequent actual myocardial salvage (14). Therefore, imaging techniques able to identify the risk area involved by the myocardial infarction, the final damage after reperfusion therapy, and, by difference, the extent of myocardial salvage would be desirable. Myocardial perfusion SPECT with  $^{99m}\text{Tc}$ -sestamibi before and after treatment fulfills all of the requirements of an ideal imaging modality for this particular issue (1–4), but various practical problems limit the wide application of imaging before reperfusion to all patients with acute myocardial infarction (5). Myocardial contrast echo-

cardiography performed immediately before reperfusion and repeated thereafter has been used, but published data indicate that this method has a low specificity (19,21,29). Thus, major efforts have been undertaken to identify imaging modalities that are able to give at least part of the needed information with a single examination performed after the reperfusion therapy has been completed but before the patient's discharge.

Dobutamine echocardiography is highly reliable in identifying the asynergic segments that will show spontaneous function recovery after acute myocardial infarction (15–20). These segments, which include viable stunned myocardium, can be differentiated because of the presence of contractile reserve during inotropic stimulation from the irreversibly damaged regions. So far, limited data on the relationship between the extent of contractile reserve and the presence of significant late increase of global LVEF have been available (20). According to our results, the detection of any contractile reserve in the infarct zone is able to recognize with good accuracy the patients in whom the LVEF will increase on late follow-up after myocardial infarction. Even a minimal wall motion improvement during dobutamine infusion appears predictive of late significant improvement of the LVEF, so that a lower threshold of the wall motion score change of the infarct zone was selected compared with that in previous reports (17,20). On the other hand, a remarkable proportion of patients without a contractile reserve showed a significant LVEF improvement on follow-up, and thus the low negative predictive value appears to be the most important limitation of dobutamine echocardiography in our series.

The assessment of infarct size in a  $^{99m}\text{Tc}$ -sestamibi SPECT study acquired at the time of hospital discharge is a very useful parameter for stratifying patients' risk and a possible endpoint for establishing the effectiveness of different therapeutic regimens (5,9). A close relationship exists between the infarct size assessed with  $^{99m}\text{Tc}$ -sestamibi SPECT performed at the time of hospital discharge and the LVEF late after acute myocardial infarction (6,7). In addition, this parameter has an important prognostic implication (8). However, myocardial salvage may be present independently from the degree of final impairment of left ventricular function. A discrepancy between infarct size and the LVEF at hospital discharge has been shown to be an indirect sign of the presence of myocardial stunning, but the diagnostic reliability of this approach is not defined (10). Other data suggest that the simple recognition of  $^{99m}\text{Tc}$ -sestamibi activity over the viability threshold in asynergic segments early after myocardial infarction is predictive of spontaneous recovery at 1 mo (21). Recently, Hambÿe et al. (30) reported that a specific pattern of decreased  $^{99m}\text{Tc}$ -sestamibi uptake and even more depressed  $\beta$ -methyl-*p*-iodophenyl-pentadecanoic acid activity is predictive of significant recovery of the LVEF after revascularization in infarct patients. Starting with these premises, we attempted to establish whether any parameters that can be obtained from

$^{99m}\text{Tc}$ -sestamibi SPECT after reperfusion are predictive of spontaneous LVEF increase. Because the initial extent of the area at risk was unknown, we chose to evaluate the SPECT data on the basis of standard infarct zones, as in previous studies using dobutamine echocardiography (17,19,20). Among the examined parameters, we considered the extent of infarct, the mean tracer activity of the infarct zone, and, finally, the severity of the residual damage, expressed by the incidence of segments with severely reduced activity over the segments with abnormal uptake. On the basis of our results, the first parameter did not differentiate the patients with late functional improvement from the others. This was shown by the lack of a significant difference in the mean extent of infarct between the 2 groups of patients. In addition, the results of ROC analysis showed an area under the curve just above the limit of diagnostic uncertainty. Conversely, the areas under the ROC curves constructed using the mean  $^{99m}\text{Tc}$ -sestamibi activity and, above all, the severity index were significantly larger and were not significantly different than that of the contractile reserve assessed by dobutamine echocardiography. Accordingly, the sensitivity, specificity, and overall accuracy of those parameters were very close to the related values achieved using dobutamine echocardiography. Interestingly, considering either the mean activity of the infarct zone or the severity of the infarct, instead of the extent of the infarct, the reliability of  $^{99m}\text{Tc}$ -sestamibi SPECT alone approached the diagnostic reliability of the combined evaluation of perfusion and metabolism proposed by Hambÿe et al. (30), with the advantage of a simpler and widely available imaging protocol. With regard to the possible physiopathologic explanation of our results, it is reasonable that patients in whom the residual damage after revascularization includes a prevalence of severely necrotic segments (with reduced mean tracer activity) do not to show a significant recovery on follow-up, because the proportion of residual viable stunned myocardium within the infarct area is probably limited and irreversible myocardial damage is already established.

The limitations of this study must be considered. The choice of analyzing the data on the basis of theoretic maximal risk areas (standard infarct zones) was justified by the lack of an objective criterion to define the true initial risk area. However, this is an important limitation because the possibility of infarcts extending over boundaries of the infarct zones cannot be ruled out. In our series we did not observe asynergic segments outside the infarct zone in any patient, but this remains theoretically possible. The use of a low-dose dobutamine protocol precluded the possibility of examining the presence of ischemia or biphasic responses. Similarly, the execution of stress imaging could have increased the value of perfusion scintigraphy. However, the study protocol required as inclusion criterion the optimal result of primary PTCA and, hence, a low likelihood of inducible ischemia early after the procedure had to be expected. Although all patients were in apparently stable

clinical conditions, the time interval between the execution of dobutamine echocardiography and  $^{99m}\text{Tc}$ -sestamibi SPECT is another potential limitation for a comparison of the 2 methods. With regard to the SPECT parameters that we evaluated, none of them is optimal and devoid of potential criticisms. The mean activity within the infarct zone attempts to approximate the threshold method that is widely adopted for the evaluation of myocardial viability in patients with chronic coronary artery disease and left ventricular dysfunction (26,31). It is noteworthy that the best threshold identified for this parameter by ROC analysis was set at  $\geq 60\%$  of peak activity, in agreement with previous studies (21,26,31). The estimate of the extent of the infarct in terms of the number of infarct zone segments with abnormal tracer uptake is very rough. Also, our proposal of a severity index could be criticized for the same reason. Most previous studies of infarct size used a fixed activity threshold over the entire left ventricular wall and did not consider a segment model (5–10), so this approach was difficult to reconcile with the concept of infarct zone and to compare with echocardiography. Furthermore, severity was not considered. The assessment of the extent and severity of the infarct using the comparison with a normalcy database could be a possible alternative (32), but, again, it would be difficult to adapt the data to the use of a standard infarct zone.

## CONCLUSION

The results of this study confirm the value of dobutamine echocardiography for the detection of stunned salvaged myocardium early after acute myocardial infarction and define its diagnostic reliability for the prediction of LVEF outcome. In addition, the perfusion pattern evaluated by means of a single  $^{99m}\text{Tc}$ -sestamibi SPECT study after reperfusion therapy is able to identify those patients in whom myocardial salvage will lead to a delayed increase in the LVEF. In particular, the presence of functional recovery is related to the infarct severity and mean tracer uptake. These parameters, together with the infarct size, could be useful in assessing the effectiveness of acute reperfusion therapy in patients with acute myocardial infarction and in guiding the subsequent management of the patient.

## REFERENCES

- Wackers FJ, Gibbons RJ, Verani MS, et al. Serial quantitative planar technetium-99m isonitrite imaging in acute myocardial infarction: efficacy for noninvasive assessment of thrombolytic therapy. *J Am Coll Cardiol.* 1989;14:861–873.
- Gibbons RJ, Verani MS, Behrenbeck T, et al. Feasibility of tomographic  $^{99m}\text{Tc}$ -hexakis-2-methoxy-2-methyl-propyl-isonitrite imaging for the assessment of myocardial area at risk and the effect of treatment in acute myocardial infarction. *Circulation.* 1989;80:1277–1286.
- Santoro GM, Bisi G, Sciagrà R, Leoncini M, Fazzini PF, Meldolesi U. Single photon emission computed tomography with technetium-99m hexakis 2-methoxyisobutyl isonitrite in acute myocardial infarction before and after thrombolytic treatment: assessment of salvaged myocardium and prediction of late functional recovery. *J Am Coll Cardiol.* 1990;15:301–314.
- Behrenbeck T, Pellikka PA, Huber KC, Bresnahan JF, Gersh BJ, Gibbons RJ. Primary angioplasty in myocardial infarction: assessment of improved myocardial perfusion with technetium-99m isonitrite. *J Am Coll Cardiol.* 1991;17:365–372.
- Christian TF. The use of perfusion imaging in acute myocardial infarction: applications for clinical trials and clinical care. *J Nucl Cardiol.* 1995;2:423–436.
- Christian TF, Behrenbeck T, Pellikka PA, Huber KC, Chesebro JH, Gibbons RJ. Mismatch of left ventricular function and perfusion with Tc-99m-isonitrite following reperfusion therapy for acute myocardial infarction: identification of myocardial stunning and hyperkinesia. *J Am Coll Cardiol.* 1990;16:1632–1638.
- Christian TF, Behrenbeck T, Gersh BJ, Gibbons RJ. Relation of left ventricular volume and function over one year after acute myocardial infarction to infarct size determined by technetium-99m sestamibi. *Am J Cardiol.* 1991;68:21–26.
- Miller TD, Christian TF, Hopfenspirger MR, Hodge DO, Gersh BJ, Gibbons RJ. Infarct size after acute myocardial infarction measured with quantitative tomographic  $^{99m}\text{Tc}$  sestamibi imaging predicts subsequent mortality. *Circulation.* 1995;92:334–341.
- Christian TF, Gitter MJ, Miller TD, Gibbons RJ. Prospective identification of myocardial stunning using technetium-99m sestamibi-based measurements of infarct size. *J Am Coll Cardiol.* 1997;30:1633–1640.
- Gibbons RJ, Miller TD, Christian TF. Infarct size measured by single photon emission computed tomographic imaging with  $^{99m}\text{Tc}$ -sestamibi: a measure of the efficacy of therapy in acute myocardial infarction. *Circulation.* 2000;101:101–108.
- Weiss AT, Maddahi J, Shah PK, et al. Exercise-induced ischemia in the streptokinase-reperfused myocardium: relationship to the extent of salvaged myocardium and degree of residual coronary stenosis. *Am Heart J.* 1989;118:9–16.
- Braunwald E, Kloner RA. The stunned myocardium: prolonged posts ischemic ventricular dysfunction. *Circulation.* 1982;66:1146–1149.
- Zijlstra F, Hoorntje JCA, de Boer M-J, et al. Long-term benefit of primary angioplasty as compared with thrombolytic therapy for acute myocardial infarction. *N Engl J Med.* 1999;341:1413–1419.
- Ito H, Okamura A, Iwakura K, et al. Myocardial perfusion patterns related to thrombolysis in myocardial infarction perfusion grades after coronary angioplasty in patients with acute anterior myocardial infarction. *Circulation.* 1996;93:1993–1999.
- Pierard LA, De Landsheere CM, Berthe C, Rigo P, Kulbertus HE. Identification of viable myocardium by echocardiography during dobutamine infusion in patients with myocardial infarction after thrombolytic therapy: comparison with positron emission tomography. *J Am Coll Cardiol.* 1990;15:1021–1031.
- Barilla F, Gheorghide M, Alam M, Khaja F, Goldstein S. Low-dose dobutamine in patients with acute myocardial infarction identifies viable but not contractile myocardium and predicts the magnitude of improvement in wall motion abnormalities in response to coronary revascularization. *Am Heart J.* 1991;122:1522–1531.
- Smart SC, Sawada S, Ryan T, et al. Low-dose dobutamine echocardiography detects reversible dysfunction after thrombolytic therapy of acute myocardial infarction. *Circulation.* 1993;88:405–415.
- Ehlendy A, Trocino G, Salustri A, et al. Low-dose dobutamine echocardiography and rest-redistribution thallium-201 tomography in the assessment of spontaneous recovery of left ventricular function after recent myocardial infarction. *Am Heart J.* 1996;131:1088–1096.
- Bolognese L, Antoniucci D, Rovai D, et al. Myocardial contrast echocardiography versus dobutamine echocardiography for predicting functional recovery after acute myocardial infarction treated with primary coronary angioplasty. *J Am Coll Cardiol.* 1996;28:1677–1683.
- Bolognese L, Buonamici P, Cerisano G, et al. Early dobutamine echocardiography predicts improvement in regional and global left ventricular function after reperfused acute myocardial infarction without residual stenosis of the infarct-related artery. *Am Heart J.* 2000;139:153–163.
- Sciagrà R, Bolognese L, Rovai D, et al. Detecting myocardial salvage after primary PTCA: early myocardial contrast echocardiography versus delayed sestamibi perfusion imaging. *J Nucl Med.* 1999;40:363–370.
- The TIMI Study Group. The Thrombolysis in Myocardial Infarction (TIMI) trial: phase I findings. *N Engl J Med.* 1985;312:932–936.
- Bolognese L, Cerisano G, Buonamici P, et al. Influence of infarct-zone viability on left ventricular remodeling after acute myocardial infarction. *Circulation.* 1997;96:3353–3359.
- Schiller NB, Shah PM, Crawford M, et al. for the American Society of Echocardiography Committee of Standards, Subcommittee on Quantification of Two-Dimensional Echocardiography. Recommendation for quantification of the left ventricle by two-dimensional echocardiography. *J Am Soc Echocardiogr.* 1989;5:358–367.

25. Bax JJ, Poldermans S, Ehlerdy A, et al. Improvement of left ventricular ejection fraction, heart failure symptoms and prognosis after revascularization in patients with chronic coronary artery disease and viable myocardium detected by dobutamine stress echocardiography. *J Am Coll Cardiol.* 1999;34:163–169.
26. Sciagrà R, Bisi G, Santoro GM, et al. Comparison of baseline-nitrate technetium-99m-sestamibi with rest-redistribution thallium-201 tomography in detecting viable hibernating myocardium and predicting postrevascularization recovery. *J Am Coll Cardiol.* 1997;30:384–391.
27. Ryan TJ, Antman EM, Brooks NH, et al. 1999 update: ACC/AHA guidelines for the management of patients with acute myocardial infarction—Executive summary and recommendations: a report of the American College of Cardiology/American Heart Association Task Force on Practice Guidelines (Committee on Management of Acute Myocardial Infarction). *Circulation.* 1999; 100:1016–1030.
28. The Global Use of Strategies to Open Occluded Coronary Arteries in Acute Coronary Syndromes (GUSTO IIb) angioplasty substudy investigators: a clinical trial comparing primary coronary angioplasty with tissue plasminogen activator for acute myocardial infarction. *N Engl J Med.* 1997;336:1621–1628.
29. Lim YJ, Nanto S, Masuyama T, Kohama A, Hori M, Kamada T. Myocardial salvage: its assessment and prediction by the analysis of serial myocardial contrast echocardiograms in patients with acute myocardial infarction. *Am Heart J.* 1994;128:649–656.
30. Hambÿe A-S, Vervaeet A, Dobbeleir A, Dendale P, Franken P. Prediction of functional outcome by quantification of sestamibi and BMIPP after acute myocardial infarction. *Eur J Nucl Med.* 2000;27:1494–1500.
31. Udelson JE, Coleman PS, Metherall J, et al. Predicting recovery of severe regional ventricular dysfunction: comparison of resting scintigraphy with <sup>201</sup>Tl and <sup>99m</sup>Tc-sestamibi. *Circulation.* 1994;89:2552–2561.
32. Bisi G, Sciagrà R, Santoro GM, Fazzini PF. Rest technetium-99m sestamibi tomography in combination with short-term administration of nitrates: feasibility and reliability for prediction of postrevascularization outcome of asynergic territories. *J Am Coll Cardiol.* 1994;24:1282–1289.

