UNIVERSITÀ DEGLI STUDI FIRENZE

FLORE
Repository istituzionale dell'Università degli Studi di Firenze

Dendritic cells in the skin after allogeneic bone marrow transplantation: immunohistochemical and electron microscopic

Questa è la Versione finale referata (Post print/Accepted manuscript) della seguente pubblicazione:

Original Citation:

Dendritic cells in the skin after allogeneic bone marrow transplantation: immunohistochemical and electron microscopic monitoring / N. PIMPINELLI; P. ROMAGNOLI; A. BOSI; M. SANTUCCI; M. MORI; S. GUIDI; B. GIANNOTTI. - In: EUROPEAN JOURNAL OF DERMATOLOGY. - ISSN 1167-1122. - STAMPA. - 3:(1993), pp. 310-317.

Availability:

This version is available at: 2158/320388 since:

Terms of use:

Open Access

La pubblicazione è resa disponibile sotto le norme e i termini della licenza di deposito, secondo quanto stabilito dalla Policy per l'accesso aperto dell'Università degli Studi di Firenze (https://www.sba.unifi.it/upload/policy-oa-2016-1.pdf)

Publisher copyright claim:

(Article begins on next page)

28 May 2024

EJD

EUROPEAN JOURNAL OF DERMATOLOGY

Volume 3 • Number 4 • May 1993

REVIEW ARTICLE

Topical 1α, 24 (R)-dihydroxivitamin D_3 for the treatment of psoriasis
M. Nishimura Y. Hori S. Nishiyama Y. Nakamizo

CLINICAL REPORTS

Revised classification of systemic sclerosis
H. Holzmann A. Schlieter A. Ramirez-Bosca

The mouth : a non casual localization of self-inflicted injuries in children
S. Menni R. Piccinno G.R. Brera

Non-recreational *Pseudomonas aeruginosa* folliculitis
R.M. Trüeb R.G. Panizzon G. Burg

Treatment of severe, chronic urticaria with cyclosporin A
R.J. Barlow A. Kobza Black M.W. Greaves

CASE REPORTS

Treatment of urticaria pigmentosa by corticosteroids
G. Taylor F. Wojnarowska Y. Chia C. Kennedy

Malignant proliferating trichilemmal tumor
M.J. Waligora P.J. Chor T.A. Schneider G.S. Schaefer

Nodular prurigo associated with lymph node non-Hodgkins lymphoma
C.A. Morton C.M. Green K.J.A. Kenicer

INVESTIGATIVE REPORTS

In short

Immunological studies of cutaneous vasculitis
E.A. Stephansson A. Scheynius

Eosinophil cationic protein in bullous pemphigoid, dermatitis herpetiformis and other blistering disorders
N.H. Cox P. Nigel Cooper P. Venge P.S. Friedman

Comparison of classification rates for conventional and dermatoscopic images of malignant and benign melanocytic lesions
T. Schindewolf W. Stolz R. Albert W. Abmayr H. Harms

Silica-induced cytokine release in human monocyte cultures
R. Franck T. Giese R. Dummer T. Walther M. Rytter V. Ziegler U.F. Haustein

Dendritic cells in the skin after allogeneic bone marrow transplantation
N. Pimpinelli P. Romagnoli A. Bosi M. Santucci M. Mori S. Guidi B. Giannotti

GUESS WHAT ?

G. Trevisan P. Pauluzzi G. Grandi

LETTERS TO THE EDITOR

Systemic scleroderma and L-tryptophan
S. Jablonska

Paradoxical hair regrowth during treatment of severe alopecia areata
R. Licastro Cicero G. Micali A. Sapuppo

5-methoxypsoralen binding to proteins
P. Muret S. Makki S. Urien P. Humbert P. Bechtel J.P. Tillement P. Agache

John Libbey EUROTEXT

EJD

Investigative report
Eur J Dermatol 1993; 3: 310-7

Dendritic cells in the skin after allogeneic bone marrow transplantation: immunohistochemical and electron microscopic monitoring

NICOLA PIMPINELLI, PAOLO ROMAGNOLI, ALBERTO BOSI, MARCO SANTUCCI, MOIRA MORI, STEFANO GUIDI, BENVENUTO GIANNOTTI

The possible role of skin dendritic cells (DCs) in acute graft-versus-host disease (aGVHD) is still obscure. As a contribution to clarify this issue, we have investigated the sensitivity of different DC subsets to the conditioning regimen to bone marrow transplantation (BMT) and the kinetics of DCs in the skin during aGVHD. The skin of 29 patients undergoing allogeneic bone marrow transplantation (BMT), including 7 patients who developed aGVHD, has been analyzed by a sequential immunohistochemical and electron microscopic (EM) study. CD1a+/HLA-DR+ DCs were virtually eliminated from the skin by the conditioning treatment to BMT. On the contrary, dermal perivascular, CD36+/factor XIIIa+ dendritic macrophages ("dermal dendrocytes") were virtually the only DCs labelled in the skin at days − 1 and + 14, apparently unaffected in number by the conditioning regimen. In the lesional skin from patients with early aGVHD, CD1a+/HLA-DR+ DCs — which seemed to overexpress CD54 and CD11a/CD18 antigens — were observed in the basal layer of the epidermis and immediately beneath, a location strictly corresponding to that of the putative Langerhans cells (lacking identifiable Birbeck granules) observed on EM. The number of CD1a+ DCs was lower than that found in biopsies taken before starting the conditioning treatment, but was clearly higher than that found in biopsies from patients without aGVHD at the same — or comparable — time point after BMT. Neither dividing cells nor transitional forms between putative Langerhans cells and dendritic macrophages were found. On recovery after aGVHD, the immunohistologic and ultrastructural features of the skin were virtually identical to those observed in patients who did not develop aGVHD. The results of this study indicate that: (1) Langerhans cells are highly sensitive to the conditioning regimen to BMT, while dermal dendrocytes are resistant to this treatment; (2) aGVHD is characterized by rapid and transient "colonization" of the skin by CD1a + DCs, with no correlation with the long-term repopulation of the epidermis by Langerhans cells.

Graft-versus-host disease (GVHD) is a serious complication for patients treated with allogeneic bone marrow transplantation (BMT) [1, 2]. Acute GVHD (aGVHD) usually occurs during the first month after BMT, and is associated with rapid onset of skin rash [2, 3]. Skin lesions during aGVHD [4-7] are characterized by mononuclear cell infiltration of the upper dermis and dermo-epidermal junction, vacuolar degeneration of basal epidermal cells, and occasional gathering of mononuclear cells around individual necrotic epidermal cells ("satellite cell necrosis"). HLA-DR [8-18] and CD54 (ICAM-1) [19] staining of keratinocytes occurs in cutaneous aGVHD, even in the very initial phases [16]. HLA-DR ker-

atinocyte staining has been indicated by some authors [12, 16, 18] as the most reliable and early marker for the differential diagnosis between aGVHD and drug- or virus-induced skin rashes, although such a finding is common in several skin disorders [20] and cannot be considered — generally speaking — as specific.

The involvement and possible role of lymphoid dendritic cells (DCs) [21] in cutaneous aGVHD are still to be ascertained. A dramatic decrease in the numbers of epidermal Langerhans cells (LC) during aGVHD has been reported by some authors [8, 9, 15, 17, 22-25], and interpreted as the possible result of an immunologic damage of LC [9]. Other authors, on the contrary, have stressed the role of the conditioning regim to BMT as the immediate cause of epidermal LC depletion [12, 26-29].

We report here on a sequential immunohistochemical and ultrastructural study of the skin in 29 patients undergoing allogeneic BMT, including 7 with aGVHD. This study was designed to highlight the modifications in the number, distribution, morphology, and immunophenotype of DCs after allogeneic BMT and during aGVHD. The final aim was to ascertain the sensitivity of different DC subsets to the conditioning regimen to BMT and the kinetics of these cells in the skin during aGVHD, as a step to understand their possible role in this disease.

Patients and methods

Patient selection and care *(Table I)*

Twenty-nine patients receiving allogeneic BMT from an HLA-matched sibling donor were studied (16 males, 13 females; age 14-51 years, mean 31.8, median 30). All patients were transplanted in the BMT Unit of the Division of Haematology, Careggi General Hospital, Florence, Italy. Patients' data, including diagnosis and conditioning regimen, are reported in *Table I*. The conditioning regimens to BMT were as follows [30]: BU/CY, busulphan 4 mg/kg/day p.o. on days − 9 to − 6, and cyclophosphamide 50 mg/kg/day i.v. on days − 5 to − 2; BU/VP/CY, busulphan 4 mg/kg/day p.o. on days − 9 to − 6, etoposide 12.5 mg/kg twice a day i.v. on days − 5 and − 4, and cyclophosphamide 60 mg/kg/day i.v. on days − 3 and − 2; CVB III, BCNU 150 mg/m²/day i.v., etoposide 400 mg/m²/day i.v., and cyclophosphamide 1.5 gr/m²/day i.v. on days − 6 to − 3; TBI/CY, hyperfractioned total body irradiation on days − 7 to − 4, and cyclophosphamide 60 mg/kg/day i.v. on days − 3 and − 2. TBI was performed by delivering eleven 120 cGy fractions in 4 days, with a 300 cGy anterior and posterior boost; total dose was 1320 cGy, dose rate 18-19 cGy/minute.

All patients had a central venous catheter implanted, and were

Table I. ***Relevant clinical data of all patients under study***

#	Age/sex	Diagnosis/status at BMT*	Conditioning regimen	aGVHD** (time of onset)	cGVHD (time of onset)	Current status°
1	38/F	AML/CR1	BU/CY	-	-	NED
2	31/M	AML/CR1	BU/CY	-	-	NED
3	32/M	ALL/CR2	TBI/CY	+ 35***	-	NED
4	45/M	CML/CP1	BU/CY	-	-	NED
5	15/M	ALL/CR2	TBI/CY	-	+ 130	NED
6	39/F	AML/REF	BU/VP/CY	-	-	REL
7	15/M	AML/REF	BU/VP/CY	-	-	REL (DOD)
8	21/F	AML/CR1	BU/CY	+ 8	-	NED
9	30/M	ALL/CR3	TBI/CY	-	-	REL (DOOC)
10	28/F	HD/RES	CVB III	-	-	DOOC
11	51/M	MM/REF	BU/CY	-	-	NED
12	16/M	ALL/CR2	TBI/CY	-	-	DOOC
13	21/M	AML/CR1	BU/CY	+ 32	-	REL
14	21/F	Hist/REF	CVB III	+ 18§	-	NED
15	42/M	AML/REF	BU/VP/CY	-	-	DOOC
16	51/F	MM/REF	BU/CY	-	-	DOOC
17	24/M	ALL/REL	TBI/CY	-	-	REL
18	30/F	AML/CR1	BU/CY	-	+ 407	NED
19	42/M	CML/CP2	BU/VP/CY	-	-	NED
20	21/M	MB	CVB III	-	-	NED
21	26/F	CML/CP1	BU/CY	+ 11	-	REL
22	31/F	CML/AP	BU/VP/CY	+ 40	-	NED
23	30/M	AML/BMT2	BU/VP/CY	-	-	REL
24	18/F	ALL/CR1	TBI/CY	+ 34	+ 128	NED
25	42/F	AML/CR2	BU/CY	-	-	NED
26	14/F	ALL/CR1	TBI/CY	-	-	REL
27	32/F	CML/CP1	BU/CY	-	-	NED
28	15/F	ALL/CR2	TBI/CY	-	-	REL
29	46/F	AML/REF	BU/VP/CY	-	-	NED

* AML = Acute Myeloid Leukemia; ALL = Acute Lymphoid Leukemia; CML = Chronic Myeloid Leukemia; MM = Multiple Myeloma; HD = Hodgkin's Disease; MB = Medulloblastoma; Hist = Histiocytosis.
CR1, 2, 3 = Complete Remission 1, 2, 3; AP = Acute Phase; CP1 = Chronic Phase 1; BMT2 = Bone Marrow Transplantation 2; RES = resistant to treatment; REF = refractory to treatment; REL = relapse.
** clinical grade 1 or 2 °see ref. 16.
*** histologically evident at + 28d.
§ histologically evident at + 14d.
° NED = no evidence of disease; REL = relapse; DOD = dead of basic disease; DOOC = dead of other cause.

treated until discharge in single, positive-pressure rooms, with Hepa-filtered air. All patients received oral antibiotics and amphotericin B for selective decontamination of the gut, and prophylactic acyclovir. All patients were routinely screened for cytomegalovirus (CMV) infection by conventional serological assays, virus cultures, and viral DNA probes. Seronegative CMV patients received seronegative blood products [30]. As a prophylaxis against GVHD, cyclosporine A (2 mg/kg) was given from day − 1, while methotrexate was given on days + 1, + 3, + 6, and + 11, according to Storb *et al.* [31].

Biopsies

In all patients, one skin biopsy (4 or 5 mm punch) was taken after informed consent at each one of the following time points: (a) from clinically normal skin of the inner surface of upper arms before (− 10d from BMT) and after the conditioning treatment (− 1d), at + 14d, + 28d, and + 60d after BMT; (b) from lesional skin, whenever skin rashes occurred (from inner arms in all patients but one, # 8, in which the rash was confined to palms and soles); and *(c)* upon pharmacological resolution of aGVHD — between + 60 and + 70d — from previously involved, presently normal skin.

In detail, the immunohistochemical and electron microscopic (EM) analysis of clinically normal skin was based upon one biopsy per patient and per time point, as follows: 29 biopsies (5 for EM) at − 10d and − 1d; 27 biopsies (5 for EM) at + 14d (not done in patients # 8 and 21, who developed aGVHD at + 8d and + 11d, respectively; see *Table I*); 26 biopsies (5 for EM) at + 28d (not done in patients # 8, 21 and 14; the latter developed clinically evident aGVHD at + 18d; see *Table I*); 11 biopsies (1 for EM) at + 60d. The immunohistochemical and EM analysis of lesional skin concerned 12 biopsies. Three biopsies (none for EM) were obtained from patients # 1, 4 and 6, who had skin macular rashes not accompanied by extracutaneous signs of aGVHD and characterized by non-diagnostic histologic findings (see below). Nine biopsies (2 for EM) were obtained from the 7 patients who developed clinically and histologically clear-cut aGVHD (# 3, 8, 13, 14, 21, 22, and 24). In two of these patients (# 3 and 14), histological evidence of aGVHD had been already found on the occasion of the systematic biopsy from clinically normal skin, at + 28d and + 14d respectively; shortly after, they developed clinically evident cutaneous and extracutaneous aGVHD, at + 35d and + 18d respectively, and were biopsied again. The immunohistochemical and EM analysis of the skin upon pharmacological resolution of aGVHD concerned 7 biopsies (1 for EM), taken between + 60d and + 70d from previously involved, presently normal skin of the 7 patients who had developed aGVHD.

Biopsy specimens were processed with routine methods for immunohistochemistry and EM. For immunohistochemistry, a large panel of monoclonal antibodies *(Table II)*, whose specificities have been indicated elsewhere [32], was tested using the alkaline phosphatase anti-alkaline phosphatase (APAAP) method [33]. The step section method was used to evaluate the results; serial sections of each tissue specimens were carefully evaluated by two of us (NP and MM). For a quantitative analysis, the stained cells were counted in five consecutive microscopic fields (× 250), both in the dermis and in the epidermis. The results in the dermis are expressed as the number of stained cells on a total of 100 cells; those in the epidermis are expressed as the number of stained cells overlying 100 basal cells. Only cells whose nuclei were contained in the plane of the section were considered.

Diagnosis and evolution of aGVHD *(Table I)*

Acute GVHD was diagnosed on the basis of clinical features [1, 2] and histology (Lerner's grading II-IV [4]). Lerner's grade I (vacuolar degeneration of basal epidermal cells) was not considered conclusive for aGVHD, in agreement with previous reports [6, 7]. Once aGVHD had developed, patients were treated with high dose steroids according to Kenojia *et al.* [34].

Seven patients (# 3, 8, 13, 14, 21, 22, 24) developed clinically evident cutaneous aGVHD (clinical grade 1 or 2 [1]), accompanied by diarrhea and hyperbilirubinemia, at days + 35, + 8, + 32, + 18, + 11, + 40, and + 34 respectively. In all these patients, aGVHD healed after proper treatment [34] in 8 to 19 days. One patient (# 24) developed a clinically and histologically evident chronic GVHD (lichenoid oral lesions) three months after complete clinical and histologic recovery from aGVHD.

Three patients (# 1, 4, and 6) developed skin macular rashes clinically suspicious for aGVHD between + 10d and + 17d. These rashes were not accompanied by gastrointestinal or hepatic signs of the disease and were characterized by non-diagnostic histologic findings (mild perivascular infiltration of mononuclear cells, with endothelial swelling and focal presence of nuclear dust). These patient were therefore not treated for aGVHD, and rashes rapidly cleared spontaneously.

Two patients (# 5 and 18) developed "de novo" chronic cutaneous (lichenoid) GVHD.

Table II. ***Monoclonal antibodies used in the study***

Antibody	Cluster Designation	Source
T11	CD2	CC
T3	CD3	CC
T4	CD4	CC
OKT8	CD8	OD
OKT6	CD1a	OD
HLA-DR	-	BD
CD16	CD16	DP
NK	CD56	DP
α/β TCR*	-	*
gamma/delta TCR*	-	*
anti-f.XIIIa**	-	**
OKM5	CD36	OD
CL-203.4	CD54	***
MHM24	CD11a	DP
OKM1	CD11b	OD
LeuM5	CD11c	BD
MHM23	CD18	DP
LeuM3	CD14	BD

CC = Coulter Clone, UK.
BD = Becton and Dickinson, Montain View, CA, USA.
OD = Ortho Diagnostic Systems, Raritan, NJ, USA.
DP = Dakopatts, Denmark.
* anti-α/β and gamma/delta T-cell receptor; generous gift of Prof. E. Berti, Milan, Italy.
** anti-factor XIIIa (embedded tissue); generous gift of Prof. E. Berti, Milan, Italy.
*** generous gift of Dr. S. Ferrone, New York, USA.

Results

Clinically normal skin

Before the conditioning treatment (− 10d), the histologic, immunohistochemical [35] and EM features of the skin were indistinguishable from those of normal skin.

After the conditioning treatment (− 1d), the epidermis showed atrophy and vacuolar degeneration of basal cells; no remarkable findings were observable in the dermis. By immuno-

Figure 1. ***Clinically and histologically normal skin, + 14d.*** *Dermal, perivascular CD36+ dendritic cells are shown (APAAP, x 200).*

Figure 2. ***Clinically and histologically normal skin, + 14d.*** *Factor XIIIa+ dendritic cells are clearly visible in perivascular location (APAAP, x 200).*

histochemistry, no HLA-DR staining was found in the epidermis. The only DCs labelled were located in the dermis, mostly around blood capillaries of the superficial vascular plexus, and were CD36+ *(Fig. 1)*, HLA-DR weakly+, and factor XIIIa+ *(Fig. 2)*. On EM, DCs could not be evidenced within the epidermis. Besides few fibroblasts, perivascular dendritic macrophages — with phagolysosomes often containing melanin — were constantly found *(Fig. 3)*.

At + 14d after BMT, the histologic, immunohistochemical, and EM findings were not significantly different from those observed at − 1d. In one patient (# 14, *Table I*), histologic and immunohistochemical evidence of aGVHD was found at this time point, whereas the clinical rash occurred at + 18d.

At + 28d, epidermal atrophy and vacuolar degeneration of basal cells — still present — were less pronounced than at − 1d and + 14d. By immunohistochemistry, occasional CD1a+ DCs and HLA-DR+ DCs were observed in the epidermis, at variance with + 14d. On EM, no significant differences were noted in comparison with − 1d and + 14d. In one patient (# 3, *Table I*), histologic and immunohistochemical evidence of aGVHD was found at this time point, whereas the clinical rash occurred at + 35d.

Figure 3. ***Clinically and histologically normal skin, + 14d.*** *A perivascular dendritic macrophage (DM) is shown. Well-recognizable melanin granules are contained within lysosomes (*) (EM, x 12,500).*

aGVHD

In the 7 patients who developed aGVHD, the latter was staged as histological grade II according to Lerner [4], i.e. with vacuolar degeneration of basal epidermal cells, spongiosis, and dys-

Figure 4. ***aGVHD, + 11d.*** *Numerous CD1a+ DCs are visible within the basal layers of the epidermis and in the papillary dermis close to the dermo-epidermal junction (APAAP, x 200).*

Figure 5. ***aGVHD, + 11d.*** *Numerous CD36+ DCs, both in perivascular location and dispersed among collagen bundles, are seen in the upper reticular dermis. Virtually no cell is identifiable close to the dermo-epidermal junction. Evident staining of suprabasal keratinocytes is also clearly visible (APAAP, × 200).*

Figure 6. ***aGVHD, + 11d.*** *Numerous CD18+ DCs are clearly visible in the papillary dermis and in the basal layers of the epidermis (APAAP, × 200).*

keratosis. The epidermis appeared thicker than that of clinically normal skin from the same site of patients without aGVHD at roughly corresponding time points after BMT; the significance of this finding, however, was not subjected to statistical analysis. A sparse perivascular lymphohistiocytic infiltrate was found in the upper dermis, close to the dermo-epidermal junction.

By immunohistochemistry, sparse CD3+, α/β TCR+ T-cells (CD4/CD8 ratio 1:1 to 3:1) infiltrated the upper dermis and the dermo-epidermal junction. Numerous CD1a+ DCs were found within the basal layers of the epidermis and in the papillary dermis close to the dermo-epidermal junction *(Fig. 4)*. The number of CD1a+ DCs was always lower than that found in the normal skin of patients under study before the conditioning regimen (− 10d), but was clearly higher than that found after the completion of the conditioning regim (− 1d) and in biopsies from patients without aGVHD at the same — or comparable — time point after BMT. Numerous CD36+ DCs *(Fig. 5)* and factor XIIIa+ DCs, most in perivascular location and a few dispersed among collagen bundles, were also seen in the upper dermis. HLA-DR antigen and the adhesion molecules CD54 (ICAM-1) and β1-containing integrins (CD11/CD18) *(Fig. 6)* were widely expressed by both round and dendritic cells close to the dermo-epidermal junction. HLA-DR, CD36 *(Fig. 5)*, and CD54 staining of keratinocytes (clustered to diffuse) were constantly seen. Semiquantitative data are given in *Table III*.

None of the above described immunohistochemical findings was observed in the absence of histologic evidence of aGVHD. In particular, no HLA-DR, CD54 and/or CD36 staining of keratinocytes was found in the 3 biopsies from patients with non-aGVHD-related clinical rash.

Table III. ***Semiquantitative assessment of dendritic cells***

MoAb	−10d	1d	+14d	+28d	aGVH(*)	+60−70d
CD1a/e (°)	***	−	−	+	++	+++
CD1a/d (•)	−	−	−	+	+++	−
HLA-DR/e (°)	++	−	−	+	++	++
HLA-DR/d (•)	+	−	−	++	+++	+
CD36	+	+	+	+	++(**)	+
f.XIIIa	+	+	+	+	++(**)	+
CD54	−	−	−	−	++(***)	−
CD11a	−	−	−	−	++(***)	−
CD11b	+	−	−	−	+(°°)	+
CD11c	+	−	−	−	+(***)	+
CD18	−	−	−	−	++(***)	−
CD14	+	−	−	−	−	+

(°) # stained cells overlying 100 basal epidermal cells (− = 0-2; + = 3-5; ++ = 6-10; +++ = > 10).
(•) # stained cells on a total of 100 observed cells (− = 0-5; + = 6-25; ++ = 26-40; +++ = > 40).
(*) histologically clearcut (Lerner's grade II).
(**) both perivascular (numerous) and dispersed free in the dermis (scattered).
(***) epidermal basal layers and superficial dermis.
(°°) dermis only.

On EM, DCs showing a nucleus with a thin peripheral rim of condensed chromatin, well-developed smooth endoplasmic reticulum and Golgi apparatus, but few primary lysosomes — thus resembling LC, even though without identifiable Birbeck granules — were found near subepithelial blood vessels and between these vessels and the dermo-epidermal junction. These cells, according to recent reports [36], should be interpreted as LC despite the lack of identifiable Birbeck granules. They were usually polarized, with most cytoplasm and organelles towards the epidermis and the nucleus towards dermal capillaries *(Fig. 7)*. Their location corresponded to that of CD1a+ DCs shown by immunohistochemistry. Numerous dendritic macrophages (most perivascular and a few interspersed among collagen bundles), similar in fine structure to those observed in biopsies without aGVHD, were also seen *(Fig. 8)*. A few dermal cells, dendritic in shape, had poorly developed smooth and rough endoplasmic reticulum and Golgi apparatus and few lysosomes, and were sometimes in contact with either the above described putative LC or the dendritic macrophages *(Fig. 8)*.

Upon pharmacological resolution of aGVHD

Upon resolution of aGVHD (between + 60 and + 70d), the histologic, immunohistochemical and EM findings were very similar to those observed at corresponding time points in the clinically normal skin of patients who did not develop aGVHD. This was true also for case # 24, although this patient developed chronic GVHD 3 months after resolution of aGVHD *(Table I)*.

Discussion

The results of this investigation indicate that the systematic and sequential histologic and immunohistochemical analysis of the skin in patients treated by allogeneic BMT may lead to the diagnosis of aGVHD earlier than clinical examination. It remains to be stated whether this gain in time may improve the prognosis upon treatment. According to our results, the finding of a CD36 staining of keratinocytes — previously unreported — may be of possible use for the differential diagnosis between aGVHD and drug- or virus-induced rashes, in addition to HLA-DR [12, 16, 18] and CD54 [19] staining. This finding, however, needs to be evaluated in a larger series of patients. The CD36 staining of keratinocytes observed in aGVHD is presumably due to cytokines released by infiltrating CD4+ T-cells, in analogy with what happens in the skin in other conditions [37, 38] and in the inflamed liver [39].

Concerning the behavior of DCs in the skin after allogeneic BMT, our findings indicate a different sensitivity of DC subpopulations to the conditioning regimen to BMT. In fact, CD1a+, HLA-DR+ DCs are virtually eliminated from the epidermis by the conditioning treatment, thus confirming the conclusions of some recent studies [12, 26-29]. In particular, our results confirm that the chemotherapy regimen alone induces a large depletion of epidermal Langerhans cells [29], therefore, such a depletion in patients with aGVHD cannot be considered as a consequence of the immunologic injury of this disease, as previously claimed [8, 9, 15, 22-25]. On the contrary, a subset of dermal DCs seems to be resistant to the conditioning treatment to BMT; in fact, these cells were virtually the only DCs labelled in the skin at − 1d and + 14d. These cells were mostly perivascular and, according to a careful analysis of serial sections, expressed both CD36 and factor XIIIa antigens. According to their preferential location, they presumably correspond to the dendritic macrophages observed on EM. On account of their antigenic and ultrastructural features, these cells are identifiable with the so-called dermal dendrocytes [40], even though the negative staining for CD14 — normally expressed by dermal dendrocytes [40] — hampers their unequivocal interpretation. The negative CD14 staining could be interpreted as the consequence of a downregulation in the expression of this monocytic antigen by this peculiar subset of dermal DCs upon conditioning regimen.

Concerning the behavior of DCs in the skin during aGVHD, in our patients with aGVHD the number of CD1a+ DCs was clearly higher than that found in the skin from patients without aGVHD, at the same — or comparable — time point after BMT. This finding is in line with that of a recent report [12], and is only apparently discrepant with the results of some

Figure 7. ***aGVHD, + 18d.*** *Dendritic cells showing a nucleus with a thin peripheral rim of condensed chromatin, well-developed smooth (besides rough) endoplasmic reticulum and Golgi apparatus, and very few lysosomes (putative Langerhans cells, although lacking identifiable Birbeck granules) in the papillary dermis close to the dermo-epidermal junction. The cells are polarized, with most cytoplasm towards epidermis (EM, × 7,500).*

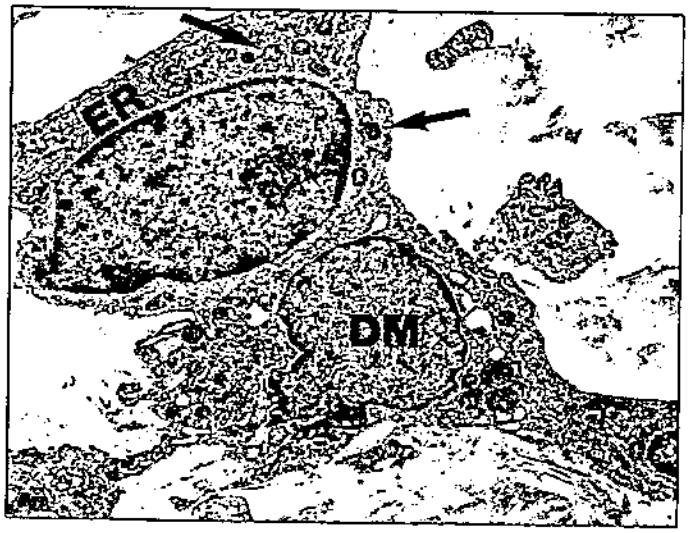

Figure 8. ***aGVHD, + 11d.*** *A dendritic macrophage (DM) in the upper dermis is in contact with another cell — dendritic in shape — with some cysternae of endoplasmic reticulum (ER) and very few lysosomes (arrows), and virtually no smooth vesicle or tubule (EM, × 10,500).*

previous studies [8, 9, 15, 22-25], where a reduction of epidermal CD1a+ LC had been claimed to occur during aGVHD. Indeed, if the comparison is made between the epidermis of aGVHD lesional skin and that of normal skin of the same patient before the conditioning treatment (baseline biopsy, at − 10d), CD1a+ DCs were much fewer in the former, and almost exclusively restricted to the basal epidermal layer and immediately beneath.

Concerning the possible role of DCs in cutaneous aGVHD, the methods used in this study do not allow to draw conclusions. However, some of our findings may be interpreted as hints of an involvement of CD1a+ DCs in the pathogenesis of cutaneous aGVHD. First, these T-lymphocyte accessory DCs are markedly increased in number at early stages of the disease, much more than lymphocytes. Second, the DCs found in the basal epidermal layer and immediately beneath during aGVHD express — besides CD1a and HLA-DR antigens — functionally relevant adhesion molecules, such as CD54 and CD11/CD18. The staining for these latter antigens was detected by light microscopic immunohistochemistry, while in normal human skin both CD54 and CD11/CD18 antigens may be detected on the plasma membrane of LC only by immunoelectron microscopy [41, 42]. Therefore, we believe that our findings indicate an overexpression of such antigens during aGVHD. Third, these CD1a+ DCs have a location strictly corresponding to that of the putative LC observed on EM. These latter cells showed ultrastructural signs of activation, such as well-developed endoplasmic reticulum and Golgi apparatus. On the basis of these findings and of the pivotal role of T-zone DCs in the colonization of lymphoid organs [21, 43], we suggest the hypothesis that these cells contribute to recruit T lymphocytes in the skin in the early phase of aGVHD.

Concerning the origin of the CD1a+ DCs observed in the skin during aGVHD, the hypothesis of their derivation from host LC, possibly surviving the conditioning treatement [44], is contradicted by the absence of CD1a+ cells in the skin of patients without aGVHD at the same time point after BMT, as demonstrated in this and previous studies. On the other hand, the hypothesis of a neo-differentiation of LC from residual dermal macrophages of the host surviving the conditioning treatment [24, 25] is contradicted by the absence of cells with intermediate features between dermal dendritic macrophages and LC in the dermis during aGVHD. The recent report of a high number of CD1a+ cells, with monocytoid ultrastructural features, in the peripheral blood of patients early after BMT [45] may represent an alternative hypothesis. These putative precursors of LC, mobilized from the graft marrow, may "colonize" the skin during aGVHD. However, this colonization would be transient (see the results concerning the biopsies after healing of aGVHD), and followed by slow — but long-lasting — reconstitution of LC population in the epidermis by cells of graft origin, as known by previous studies [46]. In fact, our findings seem to indicate that the presence of putative LC in the skin during aGVHD has no correlation with the long-term repopulation of the epidermis by LC. The histoimmunologic and ultrastructural pattern of the skin 60-70 days after BMT is similar between patients who did not develop aGVHD and those who had aGVHD and healed after treatment. ■

Riassunto

Abbiamo effettuato uno studio sistematico e sequenziale della cute in 29 pazienti sottoposti a trapianto di midollo osseo (TMO) allogenico, con lo scopo di valutare possibili differenze nella sensibilità di specifiche sottopopolazioni di cellule dendritiche (c.d.) alla terapia di condizionamento ed indagare la cinetica delle c.d. in corso di malattia trapianto-contro-ospite acuta (acute graft-versus-host disease, aGVHD). I risultati del nostro studio indicano che c.d. macrofagiche dermiche, perivascolari ed a fenotipo CD36+/fattore XIIIa+ (cosiddetti "dendrociti dermici"), sono resistenti alla terapia di condizionamento, mentre quest'ultimo ha — come noto — un profondo effetto negativo sulle cellule di Langerhans epidermiche. In corso di aGVHD, c.d. CD1a+ — cellule di Langerhans putative con segni antigenici e morfologici di attivazione — "colonizzano" in modo transitorio la cute, senza alcun rapporto dimostrabile con il normale recupero successivo al TMO.

The results of this work have been presented in part at the 18th Annual Meeting of the Society for Cutaneous Ultrastructural Research (Wien, May 23-25, 1991) and at the 3rd Langerhans Cell International Workshop (Dallas, Dec. 5-6, 1991).

Acknowledgements

The authors are grateful to Prof. E. Berti (Clinica Dermatologica I, University of Milan, Italy) for the generous gift of anti-*α/β* and -*gamma/delta* T-cell receptor and anti-factor XIIIa antibodies, Dr. S. Ferrone (Dept. of Microbiology and Immunology, University of New York, USA) for the generous gift of CL-203.4 (anti-CD54) antibody, and the following people of the Dipartimento di Anatomia Umana e Istologia of the University of Florence, Italy: Dr. F.M. Colonna (for ultrathin sectioning), Mr. P. Guasti (for set up and maintainance of electron microscopes), Mrs. L. Calosi and C. Righini (for printing microphotographs), and Mrs. R. Scantimburgo (for secretarial assistance).

This work was supported by the Ministry of University, Science, and Technology ("40%" and "60%" University funds), the Italian National Research Council (grant # 92.01087.04), and the Italian Association against Leukemia.

N. Pimpinelli, M. Mori, B. Giannotti: Clinica Dermatologica II, Università di Firenze, Via della Pergola, 58, I-50121 Firenze, Italy. P. Romagnoli: Dipartimento di Anatomia Umana e Istologia-Sez. "E. Allara", Italy. M. Santucci: Istituto di Anatomia e Istologia Patologica, Università di Firenze, Italy. A. Bosi, S. Guidi: Divisione di Ematologia, Unità Trapianto di Midollo Osseo, Policlinico di Careggi, Firenze, Italy.

Reprints: N. Pimpinelli.

References

1. Thomas ED, Storb R, Clift RA, *et al.* Bone marrow transplantation. *N Engl J Med* 1975; 95: 832-43.
2. Ferrara JLM, Deeg HJ. Graft-versus-host disease. *N Eng J Med* 1991; 10: 667-74.
3. Saurat JH. Graft-versus-host reaction: why is it important for the dermatologist? *Dermatologica* 1988; 176: 1-5.
4. Lerner KG, Kao GF, Storb R, *et al.* Histopathology of graft-vs-host reaction in human recipients of marrow from HLA matched sibling donors. *Transplant Proc* 1974; 6: 367-71.
5. Sale GE, Lerner KG, Barker EA, *et al.* The skin biopsy in the diagnosis of acute graft-versus-host disease in man. *Am J Pathol* 1977; 89: 621-36.
6. Elliot CJ, Sloane JP, Sanderson KV, *et al.* The histological diagnosis of cutaneous graft-versus-host disease: relationship of skin changes to marrow purging and other clinical variables. *Histopathology* 1987; 11: 145-55.
7. Sviland L, Pearson ADJ, Eastham E, *et al.* Histological features of skin and rectal biopsy specimens after autologous and allogeneic bone marrow transplantation. *J Clin Pathol* 1988; 41: 148-54.
8. Lampert IA, Janossy G, Suitters AJ, *et al.* Immunological analysis of the skin in graft-versus-host disease. *Clin Exp Immunol* 1982; 50: 123-31.
9. Breathnach SM, Shimada S, Kovac Z, Katz SI. Immunologic aspects of acute cutaneous graft-versus-host disease: decreased density and antigen-presenting function of Ia+ Langerhans cells and absent antigen-presenting capacity of Ia+ keratinocytes. *J Invest Dermatol* 1986; 86: 226-34.
10. Volc-Platzer B, Majdic O, Knapp W, *et al.* Evidence of HLA-DR antigen biosynthesis by human keratinocytes in disease. *J Exp Med* 1984; 159: 1784-9.
11. Beschorner WE, Farmer ER, Saral R, Stirling WL, Santos GW. Epithelial class II antigen expression in cutaneous graft-versus-host disease. *Transplantation* 1987; 44: 237-43.
12. Volc-Platzer B, Rappersberger K, Mosberger I, *et al.* Sequential immunohistologic analysis of the skin following allogeneic bone marrow transplantation. *J Invest Dermatol* 1988; 91: 162-8.
13. Sloane JP, Elliot CJ, Powles R. HLA-DR expression in epidermal keratinocytes after allogeneic bone marrow transplantation. *Transplantation* 1988; 46: 840-5.
14. Dreno B, Milpied N, Harrousseau JL, *et al.* Cutaneous immunological studies in diagnosis of acute graft-versus-host disease. *Br J Dermatol* 1986; 114: 7-15.
15. Guyotat D, Mauduit G, Chouvet B, *et al.* A sequential study of histological and immunological changes in the skin after allogeneic bone marrow transplantation. *Transplantation* 1986; 41: 340-2.
16. Sviland L, Pearson ADJ, Eastham EJ, *et al.* Class II antigen expression by keratinocytes and enterocytes — an early feature of graft-versus-host disease. *Transplantation* 1988; 46: 402-5.
17. Girolomoni G, Pincelli C, Zambruno G, *et al.* Immunohistochemistry of cutaneous graft-versus-host disease after allogeneic bone marrow transplantation. *J Dermatol (Tokyo)* 1991; 18: 314-23.
18. Norton J, Sloane JP. Epidermal damage in skin of allogeneic marrow recipients: relative importance of chemotherapy, conditioning and graft v. host disease. *Histopathology* 1992; 21: 529-34.
19. Norton J, Sloane JP. ICAM-1 expression on epidermal keratinocytes in cutaneous graft-versus-host disease. *Transplantation* 1991; 51: 1203-1206.
20. Smolle J. HLA-DR bearing keratinocytes in various dermatologic disorders. *Acta Derm Venereol* 1985; 65: 9-13.
21. Austyn JM. Lymphoid dendritic cells. *J Immunol* 1987; 62: 161-70.
22. Favrot M, Janossy G, Tidman N, *et al.* T cell regeneration after allogeneic bone marrow transplantation. *Clin Exp Immunol* 1983; 54: 59-72.
23. Perreault C, Pelletier M, Landry D, *et al.* Study to Langerhans cells after allogeneic bone marrow transplantation. *Blood* 1984; 63: 807-11.
24. Murphy GF, Merot Y, Tong ALF, *et al.* Depletion and repopulation of epidermal dendritic cells after allogeneic bone marrow transplantation in humans. *J Invest Dermatol* 1985; 84: 210-4.
25. Murphy GF, Messadi D, Fonferko E, Hancock W. Phenotypic transformation of macrophages of Langerhans cells in the skin. *Am J Pathol* 1986; 123: 401-6.
26. Sloane JP, Thomas JA, Imrie SF, *et al.* Morphological and immunological changes in the skin in allogeneic bone marrow recipients. *J Clin Pathol* 1984; 37: 919-30.
27. Elliot CJ, Sloane JP, Pollett CD, *et al.* Cutaneous leucocyte composition after human allogeneic bone marrow transplantation: relationship to marrow purging, histology and clinical rash. *Histopathology* 1988; 12: 1-16.
28. Sviland L, Pearson ADJ, Green MA, *et al.* Immunopathology of early graft-versus-host disease — A prospective study of skin, rectum, and peripheral blood in allogeneic and autologous bone marrow transplant recipients. *Transplantation* 1991; 52: 1029-36.
29. Zambruno G, Girolomoni G, Manca V, *et al.* Epidermal Langerhans cells after allogeneic bone marrow transplantation: depletion by chemotherapy conditioning regimen alone. *J Cutan Pathol* 1991; 18: 533-6.
30. Bosi A, Vannucchi AM, Grossi A, *et al.* Inadequate erythropoietin production in allogeneic bone marrow transplant patients. *Haematologica* 1991; 76: 280-4.
31. Storb R, Deeg HG, Whitehead J, *et al.* Methotrexate and cyclosporine compared with cyclosporine alone for prophylaxis of acute graft-versus-host disease after marrow transplantation for leukemia. *N Engl J Med* 1986; 314: 729-35.
32. Knapp W, Dorken B, Rieber P, *et al.* CD antigens 1989. *Am J Pathol* 1989; 135: 420-1.
33. Cordell JL, Falini B, Erber WN, *et al.* Immunoenzymatic labelling of monoclonal antibodies using immune complexes of alkaline phosphatase and monoclonal anti-alkaline phosphatase (APAAP complexes). *J Histochem Cytochem* 1984; 32: 219-26.
34. Kanojia MD, Anagnostou AA, Zandu AR, *et al.* High dose methylprednisolone treatment for acute graft-versus-host disease after bone marrow transplantation in adults. *Transplantation* 1984; 37: 246-9.
35. Bos JD, Kapsenberg ML. The skin immune system (SIS). Its cellular costituents and their interaction. *Immunol Today* 1986; 7: 235-40.
36. Bartosik J. The non-keratinocytes in normal epidermis. *Eur J Dermatol* 1991; 1: 131-4.
37. Soyer HP, Smolle J, Kerl H. Distribution patterns of the OKM5 antigen in normal and diseased human epidermis. *J Cutan Pathol* 1989; 16: 60-5.
38. Lisby S, Baadsgaard O, Cooper KD, *et al.* Expression of OKM5 antigen on epidermal cells in mycosis fungoides plaque stage. *J Invest Dermatol* 1988; 90: 716-9.
39. Volpes R, Van den Oord JJ, Desmet VJ. Adhesive molecules in liver disease. Immunohistochemical distribution of thrombospondin receptor in chronic HBV infection. *J Hepatol* 1990; 10: 297-304.
40. Headington JT, Cerio R. Dendritic cells and the dermis: 1990. *Am J Dermatopathol* 1990; 12: 217-20.
41. De Panfilis G, Soligo D, Manara GC, Ferrari C, Torresani C. Adhesion molecules on the plasma membrane of epidermal cells. I. Human resting Langerhans cells express two members of the adherence-promoting CD11/CD18 family, namely, H-Mac-1 (CD11b/CD18) and gp 150,95 (CD11c/CD18). *J Invest Dermatol* 1989; 93: 60-5.
42. De Panfilis G, Manara GC, Ferrari C, Torresani C. Adhesion molecules on the plasma membrane of epidermal cells. II. The intercellular adhesion molecule-1 is constitutively present on the cell surface of human resting Langerhans cells. *J Invest Dermatol* 1990; 94: 317-21.
43. Van Rees EP, Dopp EA, Dijkstra CD. The postnatal development of cell populations in the rat popliteal lymph node. *Cell Tissue Res* 1985; 342: 391-8.
44. Perreault C, Pelletier M, Belanger R, *et al.* Persistence of host Langerhans cells following allogeneic bone marrow transplantation possible relationship with graft-versus-host disease. *Br J Haematol* 1985; 60: 253-60.
45. De Fraissinette A, Dezutter-Dambuyant C, Guyotat D, Schmitt D. High level of CD1a putative peripheral blood precursors of epidermal Langerhans cells after bone marrow transplantation. *Thymus* 1991; 18: 129-32.
46. Volc-Platzer B, Stingl G, Wolff K, Hinterberg W, Schnedl W. Cytogenetic identification of allogeneic epidermal Langerhans cells in a bone marrow recipient. *N Engl J Med* 1984; 310: 1123-4.