



UNIVERSITÀ  
DEGLI STUDI  
FIRENZE

FLORE

## Repository istituzionale dell'Università degli Studi di Firenze

### **The treatment of isolated iliac artery aneurysm in patients with non-aneurysmal aorta**

Questa è la Versione finale referata (Post print/Accepted manuscript) della seguente pubblicazione:

*Original Citation:*

The treatment of isolated iliac artery aneurysm in patients with non-aneurysmal aorta / W. DORIGO; R. PULLI; N. TROISI; A. ALESSI INNOCENTI; G. PRATESI; L. AZAS; C. PRATESI. - In: EUROPEAN JOURNAL OF VASCULAR AND ENDOVASCULAR SURGERY. - ISSN 1078-5884. - STAMPA. - 35:(2008), pp. 585-589.

*Availability:*

This version is available at: 2158/316554 since: 2020-05-15T13:51:30Z

*Terms of use:*

Open Access

La pubblicazione è resa disponibile sotto le norme e i termini della licenza di deposito, secondo quanto stabilito dalla Policy per l'accesso aperto dell'Università degli Studi di Firenze (<https://www.sba.unifi.it/upload/policy-oa-2016-1.pdf>)

*Publisher copyright claim:*

(Article begins on next page)

## The Treatment of Isolated Iliac Artery Aneurysm in Patients with Non-aneurysmal Aorta

W. Dorigo,<sup>\*</sup> R. Pulli, N. Troisi, A. Alessi Innocenti, G. Pratesi, L. Azas and C. Pratesi

*Department of Vascular Surgery, University of Florence, Florence, Italy*

**Objectives.** The aim of the study was to evaluate early and mid-term results of surgical repair of isolated iliac artery aneurysm (IAA) in patients with non aneurysmal abdominal aorta.

**Methods.** From January 1996 to December 2006, 34 patients with IAA had elective surgery. In 32 cases open repair was performed. Two patients had endovascular repair using a tube endoprosthesis and internal iliac artery coil embolization. The diameters of the abdominal aorta and iliac arteries were measured preoperatively and during follow-up. Early and late results in terms of mortality, major morbidity, reinterventions and graft-related complications were recorded. Mean pre and postoperative diameters of abdominal aorta were compared.

**Results.** The site of the IAA was the common iliac artery in 29 cases (10 bilateral), internal iliac artery in 4 cases and external iliac artery in 1 case. Preoperative mean abdominal aortic diameter was 22.2 mm (SD 7.6). There were no perioperative deaths and two major complications (retroperitoneal bleeding and limb ischemia) occurred. At the median follow-up time of 24 months survival was estimated as 91%. No reinterventions, graft thrombosis and graft related complications occurred. There were no cases of abdominal aorta aneurysm development. Mean aortic diameter at the most recent imaging was 23.1 mm, which was not significantly different from preoperative values ( $p = 0.2$ ).

**Conclusions.** Surgical treatment of IAAs provides good early and mid-term results. During mid-term follow-up the diameter of abdominal aorta remains stable, suggesting IAA may be a localized aneurysmal disease.

© 2007 European Society for Vascular Surgery. Published by Elsevier Ltd. All rights reserved.

**Keywords:** Isolated iliac artery aneurysm; Abdominal aorta; Follow-up.

### Introduction

Isolated iliac artery aneurysm (IAA) is a relatively uncommon disease, accounting for approximately 0.4% to 1.9% of all arterial aneurysms.<sup>1</sup> Mainly because of their rarity, the natural history and strategies of management of IAA are much less studied than corresponding features concerning abdominal aortic aneurysms (AAAs).<sup>2</sup>

Surgical treatment of isolated IAAs includes open and endovascular repair, however, there is no firm consensus regarding the optimal surgical approach. When open repair is performed, it is unclear whether to limit the intervention to the affected iliac artery or to simultaneously replace the infrarenal aortic segment.<sup>3</sup> Some recent studies<sup>4,5</sup> have demonstrated that, in patients undergoing tube graft repair for AAA, the risk of developing an iliac aneurysm

during follow-up is substantial and related to the initial diameter of iliac vessels. There are very few data<sup>3</sup> concerning the behaviour of abdominal aorta in patients who had surgical treatment limited to the affected iliac artery.

The aim of this study was to evaluate early and mid-term results of surgical treatment of isolated IAA in our 11-year experience and to evaluate the change in diameter of unrepaired abdominal aorta during follow-up.

### Materials and Methods

#### *Selection of patients*

From January 1996 to December 2006, 1609 open and endovascular interventions for aorto-iliac aneurysms were performed at our Institution. Data concerning all these interventions were prospectively collected in a specific database. A post-hoc analysis of this database was performed in order to identify all the patients operated on for isolated IAAs and 103 patients

<sup>\*</sup>Corresponding author. W. Dorigo, MD, Department of Vascular Surgery, University of Florence, Viale Morgagni 85, 50134 Florence, Italy.

E-mail address: [dorigow@email.com](mailto:dorigow@email.com)

were selected. From this group we excluded patients with iliac pseudoaneurysms following AAA repair with bifurcated grafts (20 patients), patients who developed a true iliac aneurysm following AAA repair with tube and bifurcated grafts (14 patients) and patients with IAA and ectatic (>35 mm) abdominal aorta who underwent bifurcated graft placement (30 patients). As a consequence, 39 patients with true isolated IAA and untreated abdominal aorta were identified. In 32 patients open surgical repair was performed and the remaining 7 patients were treated with endovascular repair. In two cases endovascular repair was with a tube endograft and in 5 cases with bifurcated endografting. The later five cases were excluded from our study, which finally included 34 patients.

All the hospital charts of these patients were revised and from our database pre-, intra- and postoperative features were analysed. Preoperative variables included demographic data, risk factors, comorbidities, clinical and anatomical features. Among risk factors and comorbidities, arterial hypertension (defined as pressure values higher than 130/80 mmHg or the need for anti-hypertensive drugs), diabetes mellitus (defined as the need for specific drugs), hyperlipidemia (defined as triglycerides and cholesterol values > 200 mg/dl), coronary artery disease (history of acute myocardial infarction, angina, previous coronary revascularization), chronic renal failure (defined as serum creatinine > 2 mg/dl), carotid artery disease (previous carotid revascularization, carotid stenosis > 30%) and peripheral arterial disease (ankle/brachial index < 0.9) were considered. Intraoperative data collected included surgical approach, kind of reconstruction, materials and associated procedures. Postoperative data included clinical events and anatomical assessment in the perioperative period and during follow-up.

No medical ethics approval was necessary for this study because all the patients underwent only the routine pre and postoperative assessment of surgical intervention for aorto-iliac aneurysmal disease.

#### *Preoperative assessment*

Duplex ultrasound examination (DUS) and computed tomography angiography (CT) were performed in all the patients. Indication for surgical treatment was the presence of an asymptomatic IAA with a maximum diameter larger than 3 cm or the presence of a symptomatic aneurysm regardless of the diameter. All the diagnostic images collected were reviewed by a single physician, who was validated and accredited by the

Italian Society for Vascular Investigations. The physician measured maximum diameters of abdominal aorta and iliac arteries. Maximum diameters of abdominal aorta and iliac arteries were defined as the largest A-P diameter obtained after the analysis of every slice at CT examination. For DUS measurements, the protocol suggested by the Tromso Study was used.<sup>6</sup>

#### *Surgical technique*

Open surgical repair consisted of aneurysm resection in patients with unilateral lesions via a retroperitoneal approach; patients with bilateral aneurysms had a transperitoneal approach and were treated with bilateral tube grafting. A routine policy of preservation of internal iliac artery flow was adopted in patients with contralateral internal iliac artery occlusion and in patients with bilateral lesions. In patients with bilateral interventions, a sequential cross-clamping of both common iliac arteries was performed whenever possible.

The feasibility of endovascular repair was assessed in all our patients starting from 2000. Selection criteria included the presence of a proximal neck longer than 1.5 cm.<sup>7</sup> In patients with short distal common iliac artery necks the external iliac artery was used as the landing vessel and internal iliac artery coil embolization was performed.

Perioperative results (<30 days) were analysed in terms of mortality, major complications and graft related complications. Major complications were defined as surgery-related complications requiring reintervention or a longer hospital stay. Graft related complications included thrombosis and bleeding at the anastomotic site. All the patients were postoperatively treated with antiplatelets drugs. Anti-hypertensive drugs, statins and other cardiovascular medications were prescribed on the basis of patients' comorbidities.

#### *Follow-up*

The follow-up program consisted of DUS at 1 month and yearly thereafter in patients who underwent open repair. Patients treated with endovascular repair underwent DUS and CT at 1 month, DUS every six months and CT yearly thereafter. DUS were performed by the same operator at our validated vascular laboratory, following the Guidelines of the Italian Society for Vascular Investigations. The diameter of abdominal aorta, contralateral iliac artery and external iliac arteries was assessed.

### Statistics

Late results in terms of survival, graft thrombosis, graft-related complications (infection, dilatation, anastomotic pseudo-aneurysm) and reinterventions rate were estimated by the Kaplan–Meyer method. The diameter of the untreated abdominal aorta and contralateral iliac arteries in unilateral lesions were measured at each follow-up and the values obtained in the most recent postoperative scan were compared with DUS preoperative values (T test for coupled values, 95% CI).

## Results

### Clinical and anatomical features

Patients were predominantly males (32 cases, 94%), with a mean age of 72 years (range 61–85). Demographic data and comorbidities are listed in Table 1. In 6 patients another aneurysm was present (femoro-popliteal in three cases, renal artery, superior mesenteric artery and middle cerebral artery in one case, respectively). All but two patients were asymptomatic and aneurysms were discovered during diagnostic examination performed for unrelated causes. In two cases lumbar pain due to compression of the ureter from a large aneurysm was present. The site of IAA was the common iliac artery in 29 cases (10 bilateral), internal iliac artery in 4 cases and external iliac artery in 1 case. Three patients with common IAA had also associated internal iliac artery aneurysms.

The mean preoperative diameters of involved vessels are reported in Table 2. In patients operated on for unilateral common IAA, mean preoperative diameter of the contralateral common iliac artery was  $15.3 \text{ mm} \pm 4.3$ . In the 5 patients operated on for isolated internal and external iliac artery lesions, the mean diameters of common iliac arteries were 11.2 and 10.8 mm, respectively.

Mean preoperative diameter of the abdominal aorta was  $22.2 \text{ mm} \pm 7.5$  (range 12–34 mm), with

**Table 1. Demographic data and comorbidities**

	N
Male sex	32 (94%)
Mean age	72.02 (range 61–85)
Arterial hypertension	21 (62%)
Diabetes mellitus	3 (9%)
Coronary artery disease	12 (35%)
Chronic obstructive pulmonary disease	16 (47%)
Hyperlipemia	11 (32%)
Carotid artery disease	5 (14%)
Peripheral arterial disease	9 (26%)
Chronic renal failure	2 (6%)

**Table 2. Mean preoperative measures of IAAs**

	Mean diameter (mm)/SD
Unilateral common IAA	$42.0 \pm 13.4$
Bilateral common IAA	
Right side	$51.01 \pm 15.02$
Left side	$41.4 \pm 18.4$
Internal IAA (3 isolated and 4 associated with common IAA)	$50.2 \pm 26.5$
External IAA (1 case)	30

a normal distribution of the values. All the interventions were electively performed.

### Surgical techniques

Open surgical repair consisted of aneurysm resection with inlay tube grafting in 27 cases. In 10 of these patients bilateral intervention was performed. In two cases of unilateral intervention a common iliac artery to internal iliac artery tube grafting with reimplantation of external iliac artery on the graft was performed. One patient had the reimplantation of the internal iliac artery on the common iliac artery tube graft. Three patients with isolated internal IAA had an internal iliac artery tube graft. Among patients with bilateral intervention, one patient underwent common iliac artery to internal iliac artery tube grafting with reimplantation of external iliac artery on the graft at one of the affected sides. In two cases a unilateral bypass between the tube graft and internal iliac artery was performed. Four patients (three common iliac and one external iliac artery aneurysms) had aneurysm resection with end-to-end anastomosis. In one case endarterectomy of the iliac bifurcation was required. One patient with a giant aneurysm (11 cm diameter) of the left internal iliac artery underwent obliterative endoaneurysmorrhaphy<sup>8</sup> with proximal and distal ligation of the internal iliac artery. In the open surgery group four associated interventions were performed. In the two patients with ureter compression, ureterolysis was performed and in one case a ureter pig-tail catheter was placed. In the patient with a superior mesenteric artery aneurysm, the lesion was resected and an inlay tube graft was placed. One patient underwent cholecystectomy.

In two patients endovascular treatment was performed with a tube endograft. In both cases the external iliac artery was used as a landing vessel and coil embolization of the internal iliac artery was performed.

In our series there were no perioperative deaths and two major complications occurred. In one patient with bilateral IAA which were treated with tube grafts, reoperation was required on the 2nd

postoperative day because of a subacute retroperitoneal bleed. A further patient, who had undergone a right common IAA resection, developed an acute right leg ischemia on the 1st postoperative day. This problem was successfully treated with femoropopliteal thrombectomy. In three cases postoperative pneumonia occurred.

### Follow-up

Follow-up data were obtained in 30 out of 34 patients (89%); median duration of follow-up was 24 months (mean 36.4 months, range 0–120, SD 31.3). During follow-up four deaths occurred, in all the cases unrelated to surgical intervention. Estimated 24- and 60-month survival rates were 91% and 82.7%, respectively (Fig. 1). No reinterventions, graft thrombosis and graft related complications occurred. One patient developed critical limb ischemia 12 months after IAA repair and underwent successful below-knee femoropopliteal bypass.

In patients operated on for unilateral IAA, no late contralateral iliac artery aneurysm developed.

There were no cases of abdominal aorta aneurysm development. Pre- and postoperative abdominal aorta diameters in these thirty patients demonstrated a slight increase in aortic size, which was not statistically significant (21.8 mm vs. 23.1 mm, range of

postoperative aortic diameter 15–34 mm;  $p = 0.187$ , 95% CI  $-3.2/0.6$ ). The mean increasing in postoperative diameter of the abdominal aorta was  $2.7 \text{ mm} \pm 2.5$ . In five patients a  $>5 \text{ mm}$  aortic diameter increasing was recorded and aortic diameter never became  $>35 \text{ mm}$ . The time intervals during which measurements were recorded in the five patients with a  $>5 \text{ mm}$  increase in aortic diameter were 30, 60 (2 patients), 72 and 120 months, respectively.

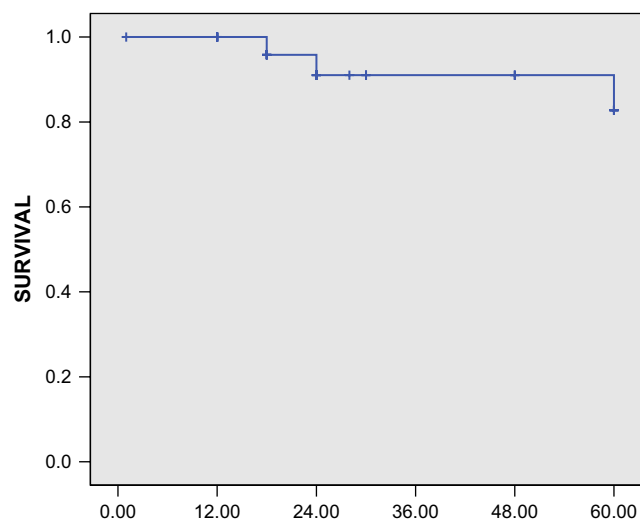
### Discussion

Isolated IAA is a rare disease, with an estimated incidence in the general population of about 0.03%.<sup>9</sup> In part because of its rarity, little information is available concerning natural history and indications for treatment of isolated IAA. Rupture of isolated IAA is reported,<sup>10,11</sup> particularly when maximum diameter exceeds 3–3.5 cm, which, at the moment, is generally accepted as the threshold value for suggesting treatment.<sup>12</sup> Open surgical repair remains the standard treatment option, providing excellent results particularly in elective interventions.<sup>1</sup> Recently endovascular techniques have been used to treat these lesions and have been described to be safe and effective in the short- and mid-term period<sup>6</sup> and to provide satisfactory rates of aneurysm exclusion.<sup>13,14</sup>

There are few reports of the fate of the untreated abdominal aorta in patients operated on for isolated IAA. Kasirajan and colleagues<sup>3</sup> reported seven cases of patients operated on for isolated IAA who did not undergo aortic replacement at the time of their original operation. Two of these patients subsequently developed infrarenal aortic aneurysms for which reoperation was necessary during follow-up. However, the initial diameters of abdominal aorta and their modifications during follow-up were not accurately reported.

Data from our study suggests that a surgical approach limited to the isolated IAA in the presence of a non-aneurysmal abdominal aorta can be supported. We had no cases of significant increase of the diameter of abdominal aorta at mid-term follow-up and an increase of aortic diameter of more than 5 mm occurred in less than 15% of the patients, which probably represents a subgroup needing further and longer follow-up.

In our opinion, the avoidance of an adjunctive aortic replacement offers some advantages. In the presence of unilateral aneurysm it is possible to perform a retroperitoneal approach, limiting the size of surgical exposure, reducing the risk of cardiac and pulmonary complications and making postoperative



Interval (months)	12	24	36	48	60
Pts. at risk	29	19	13	12	10
S.E.	0.041	0.061	0.061	0.061	0.096

**Fig. 1.** Long-term survival (Kaplan–Meyer curve with number of patients at risk and standard error values).



recovery faster and safer.<sup>15</sup> In the case of bilateral aneurysms, transperitoneal bilateral iliac tube grafting can be safely performed without the need for an infrarenal aortic cross clamp. This approach also avoids a proximal aortic anastomosis. Aortic anastomosis complications (proximal pseudoaneurysm, infrarenal aortic graft thrombosis) are reported to be approximately 7% in some series.<sup>16</sup> Moreover, this surgical strategy allows preservation of lumbar arteries and inferior mesenteric artery, reducing the risk of postoperative colonic ischemic. Finally, this technique makes it possible to avoid bilateral lower limb ischemia during aortic cross clamp.

This study has some limitations. It is a post-hoc analysis with an heterogeneous study population and a mid term-follow-up. Moreover, we had no control group, which should include patients with initial ectatic aorta with a diameter ranging between 35 and 45 mm. These patients would be expected to have a faster and higher rate of aortic diameter increasing. Another possible bias of this study derives from having used DUS during follow-up in all but two patients. DUS underestimate aortic diameters in comparison with CT.<sup>6</sup> In a recent study<sup>17</sup> DUS in a validated diagnostic laboratory provided similar results for aortic measurement to those obtained with CT.

## Conclusions

Data from this study suggests that limiting treatment to the affected iliac artery in patients with isolated IAA provides satisfactory early and mid-term results.

## References

- SANDHU RS, PIPINOS II. Isolated iliac artery aneurysm. *Semin Vasc Surg* 2005;**18**:209–215.
- MATSUMOTO K, MATSUBARA K, WATADA S, AKIYOSHI T, INOUE F, KANEDA M *et al*. Surgical and endovascular procedures for treating isolated iliac artery aneurysms: ten-year experience. *World J Surg* 2004;**28**:797–800.
- KASIRAJAN V, HERTZER NR, BEVEN EG, O'HARA PJ, KRAJEWSKI LP, SULLIVAN TM. Management of isolated common iliac artery aneurysms. *Cardiovasc Surg* 1998;**6**:171–177.
- DUSLUOGLU HH, DYISKI ML, HARRIS LM. Isolated iliac artery aneurysms in patients with or without previous abdominal aortic aneurysm repair. *Am J Surg* 1999;**178**:129–132.
- HASSEN-KHODJA R, FEUGIER P, FAVRE JP, NEVELSTEEN A, FERREIRA J, for the University Association for Research in Vascular Surgery. Outcome of common iliac arteries after straight aortic tube-graft placement during elective repair of abdominal aortic aneurysms. *J Vasc Surg* 2006;**44**:943–948.
- SINGH K, JACOBSEN BK, SOLBERG S, KUMAR S, ARNESEN E. The difference between ultrasound and computed tomography (CT) measurements of aortic diameter increases with aortic diameter: analysis of axial images of abdominal aortic and common iliac artery diameter in normal and aneurysmal aortas. The Tromsø Study, 1994–1995. *Eur J Vasc Endovasc Surg* 2004;**28**:158–167.
- BOULES TN, SELZER F, STANZIALE SF, CHOMIC A, MARONE LK, DILLAVOU ED *et al*. Endovascular management of isolated iliac artery aneurysms. *J Vasc Surg* 2006;**44**:29–37.
- DIX FP, TITI M, AL-KHAFFAF H. The isolated internal iliac artery aneurysm – a review. *Eur J Vasc Endovasc Surg* 2005;**30**:119–129.
- BRUNKWALL J, HAUSSON H, BENGTSSON H, BERQVIST D, TAKOLANDER R, BERGENTZ SE. Solitary aneurysms of the iliac arterial system: an estimate of their frequency of occurrence. *J Vasc Surg* 1989;**10**:381–384.
- KRUPSKI WC, SEZMAN CH, FLORIDIA R, STRECKER PK, NEHLER MR, WHITEHILL TA. Contemporary management of isolated iliac aneurysms. *J Vasc Surg* 1998;**28**:1–13.
- VAMMEN S, LINDHOLT J, HENNEBERG EV, FASTING H. A comparative study of iliac and abdominal aortic aneurysms. *Int Angiol* 2000;**19**:152–157.
- SANTILLI SM, WERNING LE, LEE ES. Expansion rates and outcomes for iliac artery aneurysms. *J Vasc Surg* 2000;**31**:114–121.
- SAHGAL A, VEITH FJ, LIPSITZ E, OHKI T, SUGGS WD, ROZENBLIT AM *et al*. Diameter changes in isolated iliac artery aneurysm 1 to 6 years after endovascular repair. *J Vasc Surg* 2001;**33**:289–295.
- PITOUILLAS GA, DONAS KP, SCHULTE S, HORSCH S, PAPADIMITRIOU DK. Isolated iliac artery aneurysms: endovascular versus open elective repair. *J Vasc Surg* 2007;**46**:648–654.
- SACKS M, HUDDY SPJ, WEGNER T, GIDDINGS AEB. Management of solitary iliac aneurysms. *J Cardiovasc Surg* 1992;**33**:679–683.
- KALMAN PG, RAPPAPORT DC, MERCHANT N, CLARKE K, JOHNSTON KW. The value of late computed tomographic scanning in the identification of vascular abnormalities after abdominal aortic aneurysm repair. *J Vasc Surg* 1999;**29**:442–450.
- KNAUT AL, KENDALL JL, PATTEN R, RAY C. Ultrasonographic measurement of aortic diameter by emergency physicians approximates results obtained by computed tomography. *J Emerg Med* 2005;**28**:119–126.

Accepted 19 November 2007

Available online 15 January 2008