



UNIVERSITÀ  
DEGLI STUDI  
FIRENZE

FLORE

## Repository istituzionale dell'Università degli Studi di Firenze

### **The expanding role of left ventricular functional assessment using gated myocardial perfusion SPECT: the supporting actor is stealing**

Questa è la Versione finale referata (Post print/Accepted manuscript) della seguente pubblicazione:

*Original Citation:*

The expanding role of left ventricular functional assessment using gated myocardial perfusion SPECT: the supporting actor is stealing the scene / R. SCIAGRA'. - In: EUROPEAN JOURNAL OF NUCLEAR MEDICINE AND MOLECULAR IMAGING. - ISSN 1619-7070. - STAMPA. - 34:(2007), pp. 1107-1122. [10.1007/s00259-007-0405-6]

*Availability:*

This version is available at: 2158/255997 since: 2019-10-09T14:08:47Z

*Published version:*

DOI: 10.1007/s00259-007-0405-6

*Terms of use:*

Open Access

La pubblicazione è resa disponibile sotto le norme e i termini della licenza di deposito, secondo quanto stabilito dalla Policy per l'accesso aperto dell'Università degli Studi di Firenze (<https://www.sba.unifi.it/upload/policy-oa-2016-1.pdf>)

*Publisher copyright claim:*

(Article begins on next page)

# The expanding role of left ventricular functional assessment using gated myocardial perfusion SPECT: the supporting actor is stealing the scene

Roberto Sciagrà

Published online: 24 March 2007  
© Springer-Verlag 2007

## Abstract

**Background** Gating of single-photon emission computed tomography (SPECT) has significantly improved the reliability and diagnostic accuracy of myocardial perfusion imaging. The functional parameters derived from this technique, mainly left ventricular volumes and ejection fraction, have been demonstrated to be accurate and reproducible. They are able to increase the detection of severe and extensive coronary artery disease and show a significant incremental prognostic power over perfusion abnormalities. Therefore, the importance given to gated SPECT functional data has progressively grown.

**Discussion** This circumstance has further expanded the indications for myocardial perfusion imaging and strengthened its position among the different imaging modalities. Moreover, several studies show that the evaluation of ventricular function may have a leading part in justifying the execution of perfusion scintigraphy in various clinical conditions.

**Aim** Aim of this review is to describe this evolution of gated SPECT functional assessment from a supporting rank with respect to perfusion, to a main actor position in the field of cardiac imaging.

**Keywords** Gated single-photon emission computed tomography · Left ventricular function · Myocardial perfusion imaging

## Introduction

The use of electrocardiographic gating has deeply modified the scenario of myocardial perfusion single-photon emission computed tomography (SPECT). The simple visualisation of wall motion and thickening has greatly improved the identification of attenuation artefacts, with a resultant significant rise in specificity and diagnostic accuracy [1–3]. A number of studies have demonstrated that gated SPECT evaluation of regional wall motion and wall thickening is accurate both in baseline conditions and under stimulation, and that it allows the recognition of stress-induced abnormalities, as, for instance, in the case of post-ischaemic stunning [4–7]. Furthermore, the available gated SPECT processing software can measure the left ventricular volumes and ejection fraction with good accuracy and high reproducibility [8–36]. With time, the importance of the functional data derived from gated images has steadily increased. It has become clear that global and regional functional parameters derived from gated SPECT can improve the diagnostic capability of myocardial perfusion imaging. Other studies have shown that assessment of the left ventricular function by gated SPECT provides prognostic information that is incremental to perfusion data. The evaluation of regional wall motion has improved the interpretation of segmental perfusion in various clinical settings. The use of gated SPECT as a reliable modality for examining the left ventricular contractile reserve on both a regional and a global basis has become a reality, with different possible applications. Finally, various recent research papers have used gated SPECT to obtain functional information, consigning the perfusion data to a secondary rank or even neglecting them altogether. These last reports suggest that, at least in the investigational setting or for particular clinical indications, gated myocar-

R. Sciagrà (✉)  
Nuclear Medicine Unit, Department of Clinical Physiopathology,  
University of Florence,  
Viale Morgagni 85,  
50134 Florence, Italy  
e-mail: r.sciagra@dfc.unifi.it

dial perfusion SPECT could be considered as an effective substitute modality for the assessment of left ventricular function. Thus, from an ancillary position with respect to perfusion assessment, gated SPECT is progressively achieving a major role in various clinical settings based on its ability to evaluate left ventricular function. The purpose of this review is to illustrate this expansion in gated SPECT usage and to help to define its importance in the present context of cardiac imaging.

### Gated SPECT technique

A comprehensive exposition of the technical issues concerning myocardial perfusion gated SPECT is beyond the scope of the present article. Various excellent reviews have covered this topic [37–40]. The almost universal use of gated SPECT for myocardial perfusion imaging has been made possible by the availability of the technetium-labelled perfusion agents, the propagation of multihead gamma cameras, the increased power of computer systems and the development of dedicated software for processing of perfusion and functional data. The presence of very important arrhythmic problems remains the only reason for avoiding acquisition of a perfusion study using electrocardiographic gating [37, 41, 42]. It must be considered that some major gating artefacts may propagate even to the summed perfusion images and thus affect their reliability [37]. The American Society of Nuclear Cardiology proposed the limit of >20% of premature beats to classify a patient as unsuitable for gated SPECT [43]. However, the possibility of conveying the counts of the heart cycles falling outside the selected R-R acceptance window in an extra frame and the capability offered by manufacturers of simultaneously acquiring a gated and a non-gated study allow the use of electrocardiographic gating in most patients with arrhythmias. In these subjects, the summed frames will be usable for perfusion assessment, whilst the gated data may remain valuable for a visual estimate of ventricular function. In the presence of heart rhythm disturbances, the assessment of wall thickening is the most sensitive parameter, while ejection fraction has been demonstrated to be a quite robust measurement [41, 42].

The detection of ventricular boundaries is a crucial issue for gated SPECT. Gamma camera resolution is still too low in comparison to left ventricular wall thickness. Therefore, because of the partial volume effect, myocardial wall thickening is perceived as an apparent increase in count density [44]. This brightening effect is used to estimate wall thickening in gated SPECT studies [45]. On the other hand, in patients with a relatively small left ventricular cavity, for instance in women or children, or with left ventricular

hypertrophy, the endocardial border may be inaccurately identified, leading to underestimation of the end-systolic volume [46, 47]. This causes significant overestimation of the left ventricular ejection fraction, although differences exist in the degree of overestimation using the various available processing algorithms [47, 48]. It has been suggested that proper filtering and zooming may reduce the inaccuracy of gated SPECT in these subjects [46, 47]. In spite of the finding of very small values in females, a recent article has demonstrated that preserved left ventricular ejection fraction and normal left ventricular volumes have an incremental prognostic value over perfusion abnormalities in women as well as in men [49]. This suggests that the possible volume underestimation does not impair the prognostic capability of gated SPECT [49].

The capability of the software program to correctly identify the left ventricular border may be impaired in regions with severely reduced tracer uptake. Many of the patients with severe uptake defects, together with those with left ventricular remodelling, have an altered left ventricular shape. Although most software programs used for gated SPECT functional measurements work on three-dimensional data, the possibility of inaccurate results, particularly underestimation of the ejection fraction, in left ventricles with an irregular shape and wide uptake defects must be considered [14, 16]. In general the published reports indicate that the edge detection programs are able to correctly define the ventricular borders even in patients with severe hypoperfusion [5, 26, 50]. Most recent data suggest that gated SPECT could be a valuable method to assess abnormalities in left ventricular shape by means of a ventricular shape index [51].

A debated point is whether gated SPECT should be corrected for attenuation. There is no doubt that gating has made a significant contribution to the identification of attenuation artefacts in myocardial perfusion imaging [1–3]. However, Links et al. demonstrated that attenuation correction of gated images improves both sensitivity (from 78% to 96%) and normalcy (from 62% to 85%) as compared with non-corrected data sets [52]. The diagnostic gain is particularly marked in patients with a high body mass index; thus Thompson et al. observed that in patients with a body mass index  $\geq 30$ , attenuation correction increased specificity from 41% to 76% and accuracy from 73% to 80%, with a limited loss in sensitivity (from 87% to 82%) [53]. The corresponding values obtained using attenuation-corrected versus non-attenuation-corrected gated SPECT in patients with a body mass index <30 were: specificity 82% versus 60%, accuracy 88% versus 85%, and sensitivity 90% versus 90%, respectively [53]. It appears reasonable to conclude that attenuation correction and gated SPECT act synergistically in improving the diagnostic reliability of myocardial perfusion imaging [54].

### Value of gated SPECT for estimating left ventricular function

Several studies have convincingly demonstrated that there is excellent agreement between gated SPECT and the other established techniques in the measurement of left ventricular function (volumes and ejection fraction), and a complete description of the literature would go beyond the aims of this review. Various algorithms have been proposed for data processing and many of them are either implemented on gamma camera systems or available as commercial software. Quantitative Gated SPECT (QGS, Cedars-Sinai Medical Center, Los Angeles, CA) is probably the most widely used method [9]. It was initially compared with first-pass radionuclide ventriculography, and the correlation of the gated SPECT ejection fraction with the reference standard was  $r=0.909$  [9]. Subsequent studies compared the QGS results with other reference techniques, such as equilibrium radionuclide angiocardigraphy (ERNA), echocardiography, contrast ventriculography and magnetic resonance imaging [16, 19–21, 23, 26–36, 55]. The Emory Cardiac Toolbox (ECTb, Emory University, Atlanta, GA) has also been extensively validated by comparison with first-pass radionuclide ventriculography, ERNA, echocardiography and magnetic resonance imaging [23, 25, 30, 34, 55]. Furthermore, comparative studies with ERNA and magnetic resonance imaging have confirmed the reliability of 4D-MSPECT (University of Michigan Medical Center, Ann Arbor, MI) [32, 34, 55, 56]. Other quantitative algorithms that have achieved commercial diffusion are the MultiDim (Stanford University, Palo Alto, CA), the W-L CQ (Yale University, New Haven, CT), the Left Ventricular Global Thickening Fraction (LVGTF) and the Perfusion and Functional Analysis for Gated SPECT (pFAST, Sapporo Medical University, Sapporo, Japan) [57–60].

The relative accuracy and reliability of these methods have been examined in various studies, comparing them either with each other or with a reference standard. Everaert et al. compared QGS and the Stanford University algorithm with ERNA and observed high and very close correlations ( $r=0.93$  and  $r=0.94$ , respectively) of the two methods with the reference standard [12]. In a similar study using  $^{201}\text{Tl}$  as a perfusion agent, Vera et al. registered a slightly lower degree of correlation between the above-mentioned two methods and ERNA ( $r=0.80$  for QGS and  $r=0.78$  for the Stanford University algorithm) and considerably lower correlation values when gated SPECT was compared with contrast left ventriculography ( $r=0.63$  and  $r=0.61$ , respectively, for the two algorithms) [24]. These data confirm substantial agreement between the two examined quantitative algorithms, but also emphasise the influence of the reference standard on the achievable results. Using ERNA as the reference, Nakajima et al. demonstrated good

correlation coefficients for the ejection fraction calculated using the examined algorithms (QGS, ECTb, 4D-MSPECT and pFAST) and even better correlation coefficients for the end-diastolic volume:  $r=0.88$  with QGS,  $r=0.89$  with ECTb,  $r=0.85$  with 4D-MSPECT,  $r=0.90$  with pFAST [55]. Nichols et al. compared QGS and ECTb with regard to ejection fraction and volumes, and demonstrated a very close correlation between the two algorithms, but with a systematic slight underestimation of end-diastolic volume and ejection fraction using QGS [61]. Lum et al. compared QGS, ECTb and 4D-MSPECT [62]. Although the correlation coefficients between the algorithms were again excellent, the Bland-Altman plot showed quite large standard deviations. Moreover, these differences, in agreement with the observations of Nakajima et al., were influenced by the heart dimensions and by the presence of perfusion defects [55, 61]. Therefore, although all methods give reasonable results, it appears clear that the various algorithms should not be used interchangeably.

To clarify the issue of the relative accuracy of various algorithms, most recently Khalil et al. proposed the use of a dedicated mathematical tool for the statistical analysis, the regression without truth technique [63]. They compared QGS, ECTb, LVGTF and the layer of maximum counts (LMC), a relatively new, still commercially unavailable method [64]. According to their analysis, QGS and ECTb outperformed the other two methods, with the ECTb showing a slight superiority over QGS, in part because the latter was influenced by the severity of perfusion defects [63]. Since magnetic resonance imaging is the true gold standard for left ventricular volumetric and functional assessment, in Table 1 we have summarised the studies comparing gated SPECT with this reference technique. It appears that the accuracy of gated SPECT quantitative functional data is good and that no major differences exist among the most widely available algorithms.

Independently of the accuracy of the measured data, a major strength of gated SPECT is its high reproducibility. Verberne et al. reported that in two repeated gated SPECT acquisitions in 22 patients, the left ventricular ejection fraction changed by just 0.9 units [65]. Comparable results have been observed in patients with left ventricular dysfunction due to ischaemic cardiomyopathy [66]. The tracer dosage influences the degree of ejection fraction reproducibility, which is greater in the case of high-dose studies than in the low-dose studies of single-day protocols [67]. Naturally, the above-mentioned differences among the various quantitative algorithms preclude comparison of values achieved using different procedures [34, 55]. On the other hand, a recent inter-institutional study using the same algorithm (QGS) showed a very good reproducibility of the functional measurements performed by the different centres and using different workstations [68].

**Table 1** Validation of gated SPECT left ventricular ejection fraction and volume measurements versus magnetic resonance imaging

Authors [ref. no.]	No. of patients	Method	LVEF	End-diastolic volume	End-systolic volume
Mochizuki et al. [13]	18	Ref. no. [13]	$r=0.89$	$r=0.94$	$r=0.90$
Stollfuss et al. [14]	26	Ref. no. [8]	$r=0.86$		
Vaduganathan et al. [17]	25	QGS	$r=0.93$	$r=0.81$	$r=0.92$
Tadamura et al. [20]	20	QGS	$r=0.94$	$r=0.92$	$r=0.97$
Tadamura et al. [21]	16	QGS	$r=0.89$	$r=0.89$	$r=0.93$
Stollfuss et al. [22]	19	Ref. no. [8]	$r=0.71$		
Faber et al. [23]	10	QGS	$r=0.88$	$r=0.97$	$r=0.99$
Bax et al. [27]	22	QGS	$r=0.90$	$r=0.84$	$r=0.87$
Bavelaar-Croon et al. [28]	21	QGS	$r=0.85$	$r=0.94$	$r=0.95$
Faber et al. [30]	35	QGS	$r=0.72$	$r=0.91$	$r=0.92$
		ECTb	$r=0.70$	$r=0.90$	$r=0.91$
Thorley et al. [31]	50	QGS	$r=0.82$	$r=0.90$	
Lipke et al. [32]	54	QGS	$r=0.90$	$r=0.92$	$r=0.96$
		4D-MSPECT	$r=0.89$	$r=0.89$	$r=0.90$
Persson et al. [33]	55	QGS	$r=0.83$	$r=0.96$	$r=0.95$
Schaefer et al. [34]	70	QGS	$r=0.89$	$r=0.92$	$r=0.96$
		4D-MSPECT	$r=0.87$	$r=0.88$	$r=0.96$
		ECTb	$r=0.85$	$r=0.90$	$r=0.94$
Marie et al. [35]	40	QGS	$r=0.93$	$r=0.93$	
Guterberlet et al. [36]	36	QGS	$r=0.79$	$r=0.91$	$r=0.94$
		ECTb	$r=0.72$	$r=0.91$	$r=0.93$

LVEF left ventricular ejection fraction, ECTb Emory Cardiac Toolbox; QGS Quantitative Gated SPECT; Ref. no. reference number

It has been shown that the lower limits of normalcy are slightly different, especially in the case of the ejection fraction, from those obtained using other imaging modalities. Recent studies have tried to identify the normal values in various groups of patients, demonstrating higher normal left ventricular ejection fraction values in women than in men. Particularly, the lower limit of normal ejection fraction in men has been fixed at 41–43% and in women at 49–51% [49, 69, 70]. Another important issue is the gating interval chosen. In theory, 16 frames are more accurate and reliable than the standard eight-interval gating, as shown by the repeatedly demonstrated underestimation of left ventricular ejection fraction using this latter technique in comparison with standard modalities [14, 16, 17, 70]. However, relatively few data are available on direct comparison between different framings in the same patients [9, 71, 72]. The promising reports about the possibility of analysing the diastolic function using gated SPECT would justify the choice of a higher number of frames per cycle [73]. Recent data suggest that improved reconstruction techniques enhance the reliability of 16-interval gated SPECT by reducing the image noise [35]. On the other hand, the dependability and widespread experience with eight-frame gating should be considered, and this approach is still recommended for clinical routine [74].

With regard to the evaluation of regional function, gated SPECT has been most extensively compared with echocardiography. The agreement in the classification of regional

wall motion abnormalities, taking into account wall thickening data as well, is good to excellent, ranging from 56% to 91% [4, 5]. Interestingly, even in patients with wide perfusion defects, such as those studied for the issue of myocardial viability in the setting of ischaemic cardiomyopathy, the accordance between gated SPECT and echocardiography appears satisfactory, with 68% agreement and a kappa statistics value of 0.54 [50]. Similar results have been reported by other authors [75]. Most importantly, the comparison with magnetic resonance imaging has confirmed the reliability of gated SPECT for regional dysfunction, with even higher exact agreement (83%) and a kappa value of 0.77 [27].

#### Incremental diagnostic value of function over perfusion

Several reports have demonstrated that functional parameters have an incremental value over perfusion alone for the diagnosis of coronary artery disease and the evaluation of its extent and severity [76–82]. It is well known that the possibility of visualising the motion and thickening of apparently hypoperfused segments significantly improves the diagnostic accuracy of perfusion SPECT, particularly in terms of increased specificity [2]. On the other hand, end-diastolic perfusion images have been demonstrated to be useful for improving the detection of mild perfusion defects, especially in women and in patients with small



hearts, with a consequent increase in sensitivity [83]. In some of these studies, however, the analysis of left ventricular function is not just incremental over perfusion, but also implies some specific piece of information which does not appear achievable using perfusion data alone. For the purpose of coronary artery disease detection and evaluation, Sharir et al. examined the value of regional wall motion abnormalities in the diagnosis of severe ( $\geq 90\%$  luminal diameter narrowing) and extensive ( $>1$  vessel with severe stenosis) coronary artery disease in patients with normal resting perfusion and demonstrated that the assessment of regional function had an incremental value over the evaluation of perfusion defects [76]. For this particular purpose the presence of regional wall motion abnormalities showed a significantly higher sensitivity (88% vs 52%,  $p < 0.001$ , and 65% vs. 38%,  $p < 0.03$ , respectively, in the left anterior descending and the left circumflex territories) than the finding of a severe perfusion defect, whereas the specificity was just slightly and not significantly diminished. Emmett et al. observed that the analysis of regional wall motion improved the specificity of myocardial perfusion imaging in the diagnosis of coronary stenosis  $>70\%$  of the vessel lumen [77]. The exclusive contribution of wall motion analysis was that the reversible wall motion abnormalities were able to stratify the patients according to the degree of angiographic coronary obstruction, with a high positive predictive value for the presence of a stenosis  $>80\%$ . Of all gated SPECT variables, the stress wall motion score and the difference wall motion score were the sole scintigraphic predictors of the angiographic jeopardy score in multivariate analysis [77]. Yamagishi et al. showed that worsening by  $>5$  ejection fraction units on post-exercise gated SPECT increased the sensitivity of perfusion data for the detection of multi-vessel coronary artery disease from 26.9% to 43.3%, with a decline in specificity from 100% to 90.4% [79]. Another paper by the same group demonstrated that taking into account the presence of stress-induced regional wall motion abnormalities significantly increased the sensitivity of  $^{201}\text{Tl}$  gated SPECT for the detection of right coronary artery lesions and for the recognition of multi-vessel disease as compared to perfusion defects alone, without affecting the specificity [80]. Similar results were obtained by Lima et al., who demonstrated that adding the functional abnormalities to clinical, stress and perfusion data significantly increased the predictive power of gated SPECT myocardial perfusion imaging for the identification of three-vessel coronary artery disease [81].

These examples indicate that the functional parameters derived from gated SPECT do not simply increase the diagnostic accuracy of perfusion analysis, but are chiefly valuable in characterising coronary artery disease in terms of severity and extent. It is clear that this is of foremost importance for orienting the patient management, allowing

not only better disease detection but also its timely stratification.

### Incremental prognostic value of function over perfusion

As just mentioned above, the current paradigm in coronary artery disease management is that of a risk-based approach [84]. Therefore, the main task of imaging procedures is to help in defining patient prognosis, identifying those subjects at risk for adverse events, mainly cardiac death or non-fatal myocardial infarction. As regards prognostication, several studies have examined the role of gated myocardial perfusion SPECT [85–94]. In general, the functional parameters improve the predictive models. Various reports, however, have shown that functional evaluation using gated SPECT is particularly important for the prediction of hard events, above all cardiac death.

In a patient population of more than 1,600 patients, Sharir et al. found that the ejection fraction and the end-systolic volume were the sole significant multivariate predictors of the two hard events (cardiac death or myocardial infarction), and that the perfusion variables became significant only if a soft event, such as late revascularisation, was included in the analysis [85]. In patients with any degree of significant perfusion abnormality, a post-stress ejection fraction  $<45\%$  or end-systolic volume  $>70$  ml dramatically increased the rate of cardiac death during follow-up. Interestingly, the end-systolic volume was able to further stratify risk of cardiac death in the patients with an abnormal ejection fraction. The same authors, in a larger patient population of approximately 2,700 patients, examined separately the predictors of cardiac death and non-fatal myocardial infarction [86]. They could demonstrate that the most powerful predictor of cardiac death was the post-stress ejection fraction, whereas the amount of ischaemia expressed as the summed difference score was the best predictor of myocardial infarction. Similarly, Kroll et al., studying patients with recent myocardial infarction, identified the post-stress left ventricular ejection fraction as the sole imaging predictor of cardiac death or infarct recurrence; in their cohort, the summed stress score was related to the occurrence of any cardiac event (including soft events such as unstable angina, congestive heart failure or late revascularisation), but not of hard events alone [87]. In a patient population of approximately 500 patients with a low ejection fraction who were followed up for about 2 years, Bestetti et al. demonstrated that the post-stress end-systolic volume was the best predictor of cardiac events in univariate analysis, followed by other functional parameters, such as resting end-systolic and end-diastolic volumes, post-stress end-diastolic volume and post-stress ejection fraction [88].

Moreover, in multivariate analysis, the post-stress end-systolic volume and ejection fraction were the two significant predictors of hard events [88]. In the setting of preoperative risk stratification, Hashimoto et al. observed that gated SPECT functional data had a significant predictive value in patients without perfusion abnormalities, both for all cardiac events and for hard events only [89]. De Winter et al. examined the role of gated SPECT in elderly patients and confirmed the significant incremental value of functional parameters over clinical and perfusion variables [93]. They found that the resting and post-stress left ventricular ejection fraction were the most significant predictors of all-cause mortality and that the left ventricular resting and post-stress end systolic volume were the best predictors of cardiac death. Most recently, Bigi et al. examined the prognostic power of gated SPECT in hypertensive patients. In the presence of a normal perfusion pattern, the event rate was low independently of the peak stress end-systolic volume, but in the case of moderate-to-severe perfusion defects, a peak end-systolic volume >74 ml identified the patients with an adverse outcome [94]. Furthermore, this parameter was significantly related to the occurrence of cardiac death. Finally, a most recent report by Sharir et al. has addressed the issue of the gender-related differences in the prognostic value of left ventricular volumes and ejection fraction [49]. According to these authors, there is no influence of sex on the capability of gated SPECT to effectively stratify the patient population. In particular, after considering separate ranges of normal ejection fraction, end-diastolic and end-systolic volume for men and women, even in this last group there is a significant incremental value of functional parameters for prediction of hard events [49].

Therefore, functional data do not merely have an additional prognostic value over the perfusion pattern; rather, they appear specifically involved in the prediction of cardiac death. In terms of risk-based patient management, the extent of inducible ischaemia detected by gated myocardial perfusion SPECT is the most effective predictor of the potential benefit of early revascularisation compared with medical therapy, but the left ventricular ejection fraction stratifies the absolute life gain in the individual patient [40].

### Regional function and perfusion

The accuracy of gated SPECT for the assessment of wall motion and thickening has been comprehensively demonstrated [4–6, 20, 27, 50, 75, 95, 96]. Moreover, this modality is perfectly suitable for exploring the relationship between perfusion and function on a segmental basis, because there are no realignment problems. A clinical

condition in which the interpretation of perfusion abnormalities without considering functional parameters can be tricky is the left bundle branch block. Several years ago, Sugihara et al. demonstrated that the decreased septal thickening in these patients can mimic the presence of hypoperfusion on non-gated images [97]. In a more recent study, Kasai et al. demonstrated using gated SPECT that in patients with left bundle branch block, septal wall thickening is reduced even in the presence of normal wall motion, and that it is further decreased in the case of dyssynchronous wall motion [98]. Therefore, gating appears mandatory to interpret the meaning of defects in myocardial perfusion imaging in patients with left bundle branch block. Similarly, Giubbini et al. demonstrated that the combination of functional (in particular wall thickening) and perfusion data obtained from gated SPECT is very effective in order to interpret the meaning of septal wall motion abnormalities in patients submitted to coronary artery bypass grafting and to differentiate between pseudo-paradoxical wall motion caused by heart surgery and paradoxical wall motion in patients with prior anterior myocardial infarction [99].

For the recognition of viable myocardium, gated SPECT allows the classification of dysfunctional segments according to their degree of baseline asynergy. It is therefore possible to select different and more accurate activity thresholds for each level of baseline dysfunction. Our group demonstrated that two different activity cut-offs ( $\geq 50\%$  for the a/dyskinetic and  $>68\%$  for the hypokinetic segments, as classified by baseline gated SPECT) allowed significantly more accurate (74% vs 64%,  $p < 0.02$ ) detection of segments with post-revascularisation recovery than the use of the same threshold for all dysfunctional segments [100]. The relation between segmental perfusion and wall motion abnormalities has been used by Kurihara et al. for the prediction of functional recovery after primary angioplasty for acute myocardial infarction [101]. The patients with a higher number of segments with a perfusion/function mismatch pattern had a greater increase in left ventricular ejection fraction 3 months after primary angioplasty. Moreover, the number of matched abnormal segments was related to the left ventricular ejection fraction value at 3 months. In a more investigational setting, Marini et al. used the combination of perfusion and functional data (segment wall motion and thickening) to evaluate the regional washout of metaiodobenzylguanidine in patients with ischaemic and idiopathic cardiomyopathy [102]. They could demonstrate that there are significant differences in the metaiodobenzylguanidine washout in normal versus hypoperfused dysfunctional segments and that these differences are influenced by the type of cardiomyopathy [102].

It is thus clear that the possibility of classifying segments in terms of both perfusion and function is useful in order to

accurately interpret the results of myocardial perfusion imaging as well as those of other scintigraphic studies.

### Gated SPECT for the assessment of contractile reserve

The reproducibility of gated SPECT regional wall motion assessment made it a reliable tool for evaluating the response to inotropic stimulation [6, 50, 103]. Low-dose dobutamine gated SPECT has become a reality with expanding fields of application. This approach has been evaluated by various authors, who have demonstrated its feasibility and appraised its merits. Yoshinaga et al. compared it with fluorodeoxyglucose positron emission tomography for the recognition of myocardial viability, and reported a significant gain in specificity over perfusion data (100% vs 52%,  $p < 0.05$ ) [104]. Considered alone, however, the inotropic response is affected by a low sensitivity for viable myocardium [105]. This was confirmed by our group using the post-revascularisation functional recovery as a reference criterion for myocardial viability: we registered higher specificity (88% vs 55%) but lower sensitivity (64% vs 85%) of inotropic response compared with perfusion activity threshold criteria [106]. However, we could demonstrate that a combined approach that defines viability of hypokinetic segments according to their contractile reserve (assessed using gated SPECT under dobutamine infusion) and of a/dyskinetic segments according to their tracer activity was significantly more specific (83%) and accurate (81%) than perfusion imaging alone [106]. Other groups have confirmed the value of combining perfusion threshold and inotropic and/or ischaemic response with low-dose dobutamine, even when using  $^{201}\text{Tl}$  as the perfusion tracer or with a dual-isotope imaging protocol [107–109]. Another most recent use of dobutamine gated SPECT is that reported by Kumita et al. [110], who demonstrated a relationship between the type of contractile response, the stress-rest perfusion pattern and the fatty acid metabolic status assessed by  $^{123}\text{I}$ -beta-methyl-iodophenyl-pentadecanoic acid. Although still investigational, this combined approach is certainly promising for the characterisation of different diseases.

Taking advantage of the demonstrated reproducibility of gated SPECT functional measurements, other authors have examined the changes in global left ventricular functional parameters under inotropic stimulation. The reaction to low-dose dobutamine can be predictive of the left ventricular functional response to revascularisation. Our group observed that an ejection fraction increase by  $\geq 5$  units during dobutamine predicted an increase of  $\geq 5$  units after revascularisation with an accuracy of 77%, a positive predictive value of 73% and a negative predictive value of 81% [111]. In patients with recent-onset idiopathic dilated

cardiomyopathy, Kasama et al. demonstrated that the ejection fraction changes induced by low-dose dobutamine and evaluated using gated SPECT were predictive of spontaneous improvement at 1-year follow-up [112]. The same authors demonstrated that dobutamine gated SPECT could be used to predict the response to beta-blocker therapy in these patients, whilst the perfusion pattern was useless for this purpose [113]. According to their data, the delta left ventricular ejection fraction under dobutamine stimulation was significantly larger in responders to carvedilol therapy than in non-responders [113]. Similarly, Weytjens et al. studied with dobutamine gated SPECT the contractile reserve of asymptomatic type 1 diabetics, showing that they responded with an increase in ejection fraction higher than that observed in the control subjects, but produced by a decrease in end-systolic volume rather than by an increase in end-diastolic volume [114]. The authors concluded that this behaviour could be related to subclinical abnormalities in diastolic function in diabetic patients [114].

On the basis of these reports, it is reasonable to include baseline low-dose dobutamine gated SPECT among the stress tests that a nuclear cardiology laboratory must be able to perform when appropriately indicated.

### Gated SPECT for the evaluation of left ventricular volumes and ejection fraction

Because of the reliability of gated SPECT measurements of global left ventricular functional parameters, several studies have employed gated SPECT to follow up the evolution of left ventricular function or its response to therapeutic interventions. In some of these studies, functional analysis has been used together with the assessment of myocardial perfusion, which remained the main indication for the radionuclide scan, in order to investigate the relationship between these parameters under different conditions. Zellweger et al. studied patients after percutaneous coronary interventions: they were able to document that the improvement in extent of ischaemia was accompanied by a beneficial effect on left ventricular volumes and function. In patients without prior infarction they observed the presence of reverse remodelling with a significant decrease in both the end-diastolic and the end-systolic volume and a significant increase in ejection fraction; conversely, patients with previous infarction showed only a significant decrease in end-systolic volume [115]. Ogard et al. used gated SPECT to explore perfusion abnormalities and their possible functional consequences in patients with primary hyperparathyroidism without a history of previous myocardial infarction, taking advantage of the use of  $^{99\text{m}}\text{Tc}$ -sestamibi for parathyroid imaging [116]. They identified

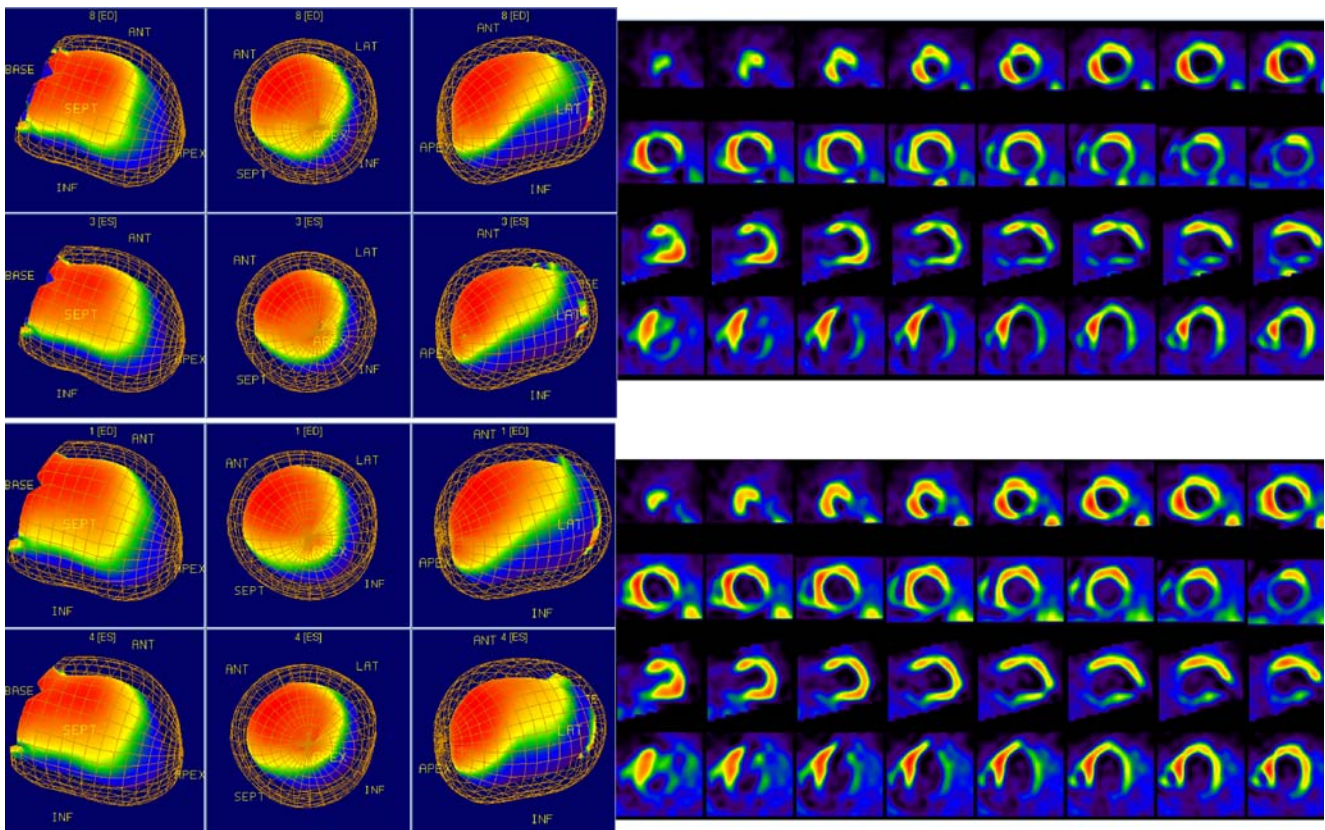


unexpected significant (>15% of the left ventricular wall) perfusion defects at rest in 5 out of 22 patients; the clinical importance of these defects was confirmed by the detection of lower ejection fraction values than in patients with normal perfusion [116]. The authors concluded that the acquisition of a gated SPECT study should be contemplated in patients submitted to  $^{99m}\text{Tc}$ -sestamibi parathyroid scintigraphy, because it could be helpful to recognise patients with unsuspected cardiac disease, in whom proper treatment and peri-operative precautions should be considered [116]. Most recently, Lima et al. employed gated SPECT to examine the factors that are related to an abnormal heart rate recovery after dynamic exercise, a well-known adverse prognostic marker in coronary artery disease [117]. In multivariate analysis, the extent and severity of the perfusion defect at rest were just borderline significant predictors of an abnormal heart rate recovery, whereas age, resting heart rate and left ventricular ejection fraction derived from gated SPECT were all highly significant predictors; interestingly, exercise-induced ischaemia was not a significant predictor [117]. This study emphasises the importance of combining perfusion and functional data to fully understand the physiopathology of dynamic exercise.

Other studies have used gated SPECT to assess the response to drug therapy and for this purpose, perfusion and functional data were equally important. Feola et al. studied the changes in myocardial perfusion and global left ventricular function induced by short-term treatment with trimetazidine in patients with ischaemic ventricular dysfunction [118]. They demonstrated a significant improvement in myocardial perfusion during treatment as compared with the images obtained under placebo, and this improvement was accompanied by a significant reduction in left ventricular end-systolic volume and a significant increase in the ejection fraction; however, in the subgroup of patients with the most severe left ventricular dysfunction, the perfusion recovery was not associated with a significant functional improvement [118]. Thus, the functional effect of treatment could be analysed taking into account also the interaction between drug action and perfusion pattern. Valgimigli et al. used gated SPECT to evaluate the response to granulocyte-colony stimulating factor in patients with acute myocardial infarction [119]. They compared the changes in perfusion, end-diastolic volume and ejection fraction in placebo versus treatment groups and demonstrated that in the presence of a similar reduction in the defect score, the treated group showed a trend towards an improvement in ejection fraction and a lower increase in end-diastolic volume [119]. This result implies that perfusion changes alone could be misleading as the sole basis for accurate evaluation of treatment outcome. This conclusion is partly contradicted by the study by Kueth et al., who used gated SPECT to assess the changes in wall perfusion

and wall motion score and radionuclide ventriculography to evaluate the evolution of ejection fraction in patients treated by granulocyte-colony stimulating factor compared with a placebo group. They registered a significant improvement in both wall motion and perfusion scores in the treated patients, together with a significant increase in ejection fraction, whilst the patients under placebo therapy showed neither perfusion nor functional improvements [120]. Most recently, Beeres et al. used gated SPECT to examine the effect of intramyocardial injection of autologous bone marrow-derived cells on perfusion and function in patients with severe, drug-refractory chronic ischaemia [121]. They demonstrated with a single imaging modality improvement in both stress-induced perfusion defects and left ventricular function [121]. Interestingly, the same group was able to verify that the improvement is not short-lived by identifying the persistence of the ejection fraction increase at a later 12-month control, which was again performed using perfusion gated SPECT [122]. The effectiveness of this modality for follow-up studies is therefore confirmed.

Another interesting field of application for gated SPECT is the treatment of severe heart failure. Fukuchi et al. used gated SPECT to examine patients with established idiopathic dilated cardiomyopathy and demonstrated that the perfusion defect extent and a sphericity index that they obtained from gated SPECT volumes were both significant predictors of the subsequent response to beta-blocker therapy [123]. In these patients, the possibility of improving both the clinical condition and the left ventricular function using cardiac resynchronisation therapy with biventricular pacing has recently opened up new therapeutic perspectives. However, because of its costs and its potential morbidity, this treatment should be reserved for those patients who may benefit from it. The aetiology of left ventricular dysfunction is one of the parameters that could influence the response to resynchronisation therapy. We used gated SPECT to evaluate the changes in left ventricular volumes and ejection fraction in a small group of patients submitted to cardiac resynchronisation therapy and were able to demonstrate that improvement in functional parameters was limited to patients with normal myocardial perfusion, and was negligible or absent in those with significant resting perfusion defects, independently of the type of cardiomyopathy [124]. Figures 1 and 2 show two typical gated SPECT studies in this kind of patient. These two studies emphasise the advantage of combining assessment of abnormalities in the myocardial perfusion pattern, which correspond to the extent of fibrotic and/or scarred areas, with a reproducible estimate of left ventricular shape and function. In the same clinical setting, other groups have used gated SPECT for the sole assessment of left ventricular function, without considering the perfusion pattern. Chen et al. used gated SPECT to evaluate the



**Fig. 1** Gated SPECT studies of a patient with severe heart failure [New York Heart Association (NYHA) class III] on the basis of ischaemic cardiomyopathy, scheduled for cardiac resynchronisation therapy because of left bundle branch block with a wide QRS complex (140 ms). In the left upper quadrant are the end-diastolic (ED) and end-systolic (ES) three-dimensional images of the left ventricle at baseline, and the right upper quadrant shows the corresponding short-axis and vertical and horizontal long-axis slices. The left ventricle is severely dilated (end-diastolic volume 375 ml), with a depressed

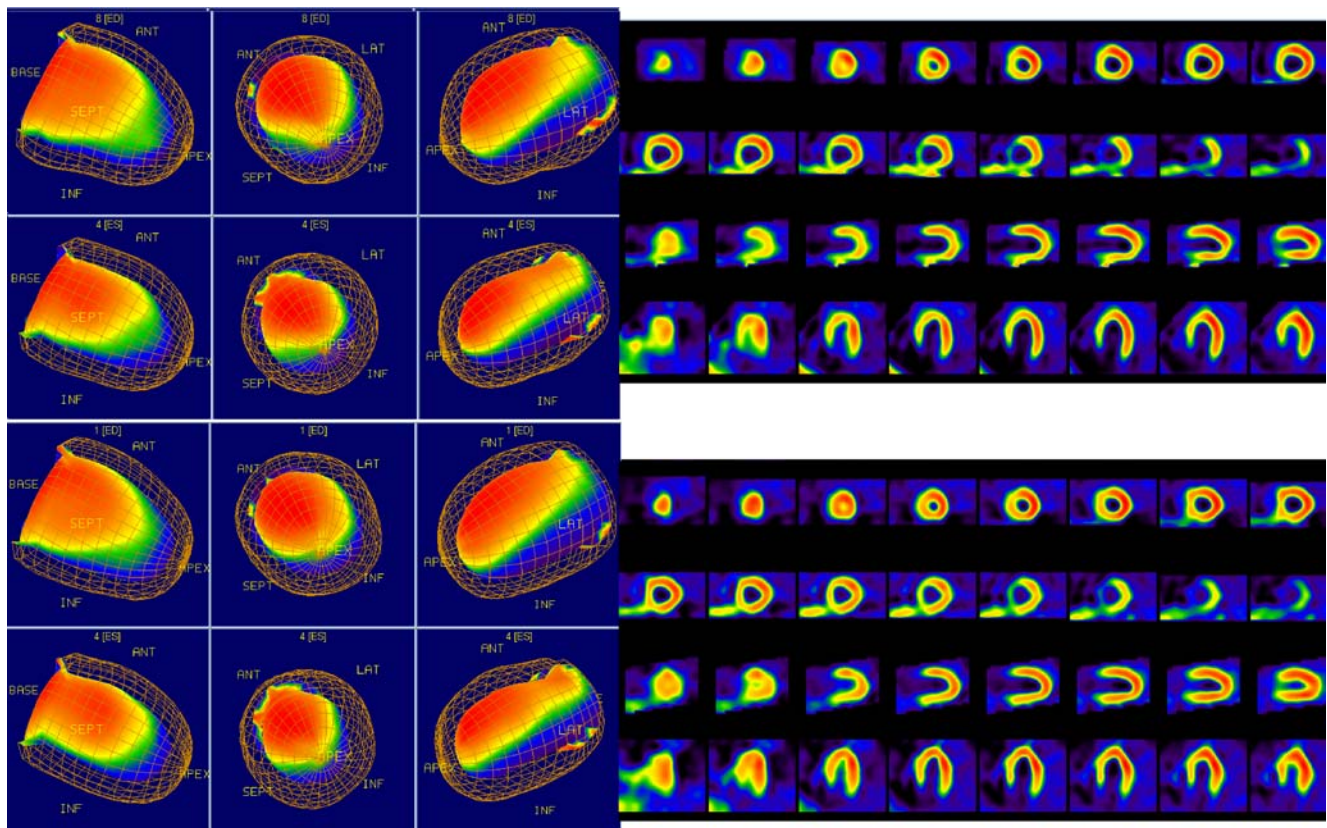
ejection fraction (19%). A wide and severe perfusion defect of the infero-lateral wall can be readily recognised. In the left lower quadrant are the three-dimensional images obtained 3 months after implantation of a biventricular pacemaker, and the lower right quadrant shows the related slices, demonstrating an unchanged perfusion pattern. Although the QRS width was reduced (130 ms) and a slight subjective improvement was reported by the patient (NYHA class II–III), the left ventricle is even larger than before treatment (end-diastolic volume 387 ml) and the ejection fraction is further decreased (15%)

mechanical dyssynchrony in these patients, with the aim of improving the detection of potential candidates for cardiac resynchronisation therapy [125]. They were able to create a normal database for the onset of mechanical contraction using phase analysis of  $^{99m}\text{Tc}$ -sestamibi gated SPECT [125]. Using a dynamic display of the onset of mechanical contraction, this method could be potentially helpful for selecting those patients in whom the degree of left ventricular dyssynchrony is predictive of a favourable response to resynchronisation therapy [125]. Tsurugaya et al. could classify patients into responders and non-responders to biventricular pacing on the basis of the improvement in left ventricular synchrony assessed by gated SPECT studies performed before and shortly after the onset of cardiac resynchronisation therapy [126]. To this end they used a simplified approach based on an asynchrony index calculated from the difference between the frame number showing the maximum systolic movement in the septum and that showing the maximum systolic movement in the lateral wall [126]. According to their results, the asynchro-

ny index significantly improved after resynchronisation therapy in the responders, but not in the non-responders [126]. These two reports indicate that perfusion gated SPECT can be used in these patients with the same effectiveness as ERNA, and is therefore a reasonable alternative to gated blood pool SPECT.

There are other examples of gated SPECT studies that did not consider the myocardial perfusion data, but exclusively addressed the functional parameters. Also in these reports, perfusion gated SPECT took the role that in the past was often occupied by ERNA, with the advantage over this latter modality that it is a three-dimensional technique and allows the measurement of left ventricular volumes. Schafers et al. employed gated SPECT to study the functional changes after partial left ventriculectomy in patients with dilated cardiomyopathy; they observed an early reduction in left ventricular volumes with improvement in ejection fraction, without further significant changes at late follow-up, but with a trend to reverse remodelling in good agreement with the clinical improve-





**Fig. 2** Gated SPECT of another patient with ischaemic cardiomyopathy, severe heart failure (NYHA class III) and left bundle branch block with wide QRS (140 ms). Same image arrangement as in Fig. 1. The baseline end-diastolic volume is 173 ml, and the ejection fraction, 28%; the myocardial perfusion is normal. At follow-up, there was the

same QRS width reduction as in the other subject, but this patient was in NYHA class I, and a clear decrease in end-diastolic volume (156 ml) and an improvement in the ejection fraction (33%) can be observed

ment [127]. In patients with severe left ventricular dysfunction due to prior infarction who were submitted to endoventricular circular patch plasty performed in addition to coronary artery bypass grafting, Fujii et al. could demonstrate a very good correlation between the parameters derived from gated SPECT and those obtained using left ventriculography [128]. Moreover, using gated SPECT for prolonged follow-up, they observed a significant reduction in left ventricular volumes and an increase in ejection fraction, indicating the presence of both short- and long-term reverse remodelling [129]. Akincioglu et al. demonstrated the feasibility and reliability of the assessment of diastolic function of the left ventricle by means of 16-frame gated SPECT, with results comparable to those of gated blood pool studies [73]. In particular, they observed that the gated SPECT time to peak filling was a stable parameter and was not influenced by systolic function, heart rate or age.

Finally, Htay et al. compared the functional parameters derived from gated SPECT in diabetic patients with those obtained in patients with a low-to-intermediate probability of coronary artery disease, who had been submitted to rest-stress myocardial perfusion imaging in the emergency

department because of non-specific symptoms [130]. They demonstrated that in patients with type 2 diabetes there are no differences in ejection fraction and left ventricular volumes as compared to gender-matched controls without diabetes [130]. However, in diabetic men the rate of subjects with an abnormally low ejection fraction was fourfold that among non-diabetic controls; this difference was not registered in women [130]. In this study, gated SPECT was performed with the clinical aim of examining myocardial perfusion, but the authors' research interest was focussed on the functional data alone, and the perfusion pattern was considered just to exclude the presence of myocardial infarction or stress-induced ischaemia.

### Gated SPECT versus other imaging modalities

There is no doubt that magnetic resonance imaging is the reference method for assessment of left ventricular function, with the additional most important advantage that it does not require the use of ionising radiation [131, 132]. However, in many circumstances its availability and feasibility are probably inferior to those of gated SPECT.

The time required to acquire a magnetic resonance study remains quite long, and this may be unbearable for claustrophobic patients; furthermore, the use of magnetic resonance is contraindicated in patients with pacemakers and implantable cardioverter defibrillators [133].

Echocardiography is widely available, has limited costs and does not require ionising radiation. Therefore, it is certainly the technique with the greatest accessibility and user-friendliness, and the only one that can be employed directly at the patient's bedside or in other crucial settings, such as the cath lab. However, it is affected by acoustic window limitations, particularly if high-quality definition of endocardial borders is needed, is operator dependent, and has suboptimal accuracy and reproducibility for quantitative measurements. This last limitation is especially evident in patients with abnormal ventricles, also because geometric assumptions are needed with the standard two-dimensional technique [131, 133–136]. It can be overcome by the use of three-dimensional echocardiography, but this technique still suffers from the problems of acoustic window and imaging artefacts [133, 137].

Recent studies indicate that multi-slice computed tomography can effectively assess the left ventricular function [138, 139]. However, the use of this technique for this particular aim is still under evaluation, and various limitations must be considered, such as the use of contrast media, the need for low heart rates during acquisition and the relatively prolonged post-processing [133]. Moreover, there are no advantages in terms of radiation exposure compared with gated SPECT [140]. In a most recent article, exactly gated SPECT was used as a reference method to validate the functional parameters derived from multi-slice computed tomography [141].

In the research setting, the available data on the reliability and reproducibility of gated SPECT functional parameters are sufficient to justify the use of gated SPECT for the evaluation of left ventricular function and not just as a method for studying the perfusion pattern. For investigational purposes, gated SPECT offers various advantages over competing modalities, and can probably be regarded as the true successor of ERNA instead of gated blood pool SPECT. Therefore, its use could be considered as a reasonable standard for the assessment of ventricular function even in multicentre studies, as recently suggested [68].

In everyday routine, however, it is much more difficult to imagine widespread use of gated myocardial perfusion SPECT exclusively for the evaluation of left ventricular function. For almost all clinical purposes, the wide availability and the lack of ionising radiation hazards will certainly encourage practitioners to overlook the limitations of echocardiography in terms of quantitation and reproducibility. Like ERNA formerly, gated myocardial perfusion SPECT could be considered as an alternative just in the few

patients with a suboptimal acoustic window. However, even in these subjects and more generally in all patients in whom accurate quantification of left ventricular function is required, magnetic resonance imaging remains the ideal approach to functional evaluation.

On the other hand, if perfusion data are of some interest, and this is often the case, there is nowadays no other technique that allows the simultaneous assessment of perfusion abnormalities and functional parameters with the same ease and reliability as gated myocardial perfusion SPECT [142]. Although both contrast echocardiography and stress magnetic resonance first-pass perfusion have great potential for myocardial perfusion imaging, these two techniques have so far been studied in relatively small populations, are quite demanding and have thus far achieved only limited implementation in clinical practice [142, 143]. Conversely, stress perfusion nuclear imaging has been used for approximately 30 years, and its value in heart disease has been extensively evaluated and demonstrated in very large patient groups [144]. Furthermore, nuclear perfusion imaging is the only technique that allows reliable evaluation of myocardial perfusion during dynamic exercise. Although the value of pharmacological stress testing is undeniable, the importance of exercise-related parameters for risk stratification cannot be exaggerated [144, 145]. Multi-slice computed tomography is also emerging as an alternative non-invasive approach for coronary artery disease diagnosis [146]. However, this method focusses on the anatomical abnormalities of the epicardial coronary vessels instead of on the myocardial perfusion pattern [147]. Therefore, its value for risk stratification is still to be demonstrated [148].

## Conclusion

Despite its reliability, gated SPECT will seldom be preferred to other techniques only for the estimation of left ventricular function. However, the functional parameters achievable using gated myocardial perfusion SPECT are so valuable that the possibility of obtaining them does not merely encourage the use of perfusion gated SPECT for the assessment of suspected or known coronary artery disease; rather, it could even reasonably lead to the expansion of its indications to various other clinical settings in which perfusion imaging has not previously been considered.

## References

1. DePuey EG, Rozanski A. Using gated technetium-99m-sestamibi SPECT to characterize fixed myocardial defects as infarct or artifact. *J Nucl Med* 1995;36:952–5.

2. Smanio PE, Watson DD, Segalla DL, Vinson EL, Smith WH, Beller GA. Value of gating of technetium-99m sestamibi single-photon emission computed tomographic imaging. *J Am Coll Cardiol* 1997;30:1687–92.
3. Fleischmann S, Koepfli P, Namdar M, Wyss CA, Jenni R, Kaufmann PA. Gated <sup>99m</sup>Tc-tetrofosmin SPECT for discriminating infarct from artifact in fixed myocardial perfusion defects. *J Nucl Med* 2004;45:754–75.
4. Chua T, Kiat H, Germano G, Maurer G, van Train K, Friedman J, et al. Gated technetium-99m sestamibi for simultaneous assessment of stress myocardial perfusion, postexercise regional ventricular function and myocardial viability. Correlation with echocardiography and rest thallium-201 scintigraphy. *J Am Coll Cardiol* 1994;23:1107–14.
5. Nichols K, DePuey EG, Krasnow N, Lefkowitz D, Rozanski A. Reliability of enhanced gated SPECT in assessing wall motion of severely hypoperfused myocardium: echocardiographic validation. *J Nucl Cardiol* 1998;5:387–94.
6. Everaert H, Vanhove C, Franken PR. Effects of low-dose dobutamine on left ventricular function in normal subjects as assessed by gated single-photon emission tomography myocardial perfusion studies. *Eur J Nucl Med* 1999;26:1298–303.
7. Johnson LL, Verdesca SA, Aude WY, Xavier RC, Nott LT, Campanella MW, et al. Postischemic stunning can affect left ventricular ejection fraction and regional wall motion on post-stress gated sestamibi tomograms. *J Am Coll Cardiol* 1997;30:1641–8.
8. DePuey EG, Nichols K, Dobrinsky C. Left ventricular ejection fraction assessed from gated technetium-99m-sestamibi SPECT. *J Nucl Med* 1993;34:1871–6.
9. Germano G, Kiat H, Kavanagh PB, Moriel M, Mazzanti M, Su HT, et al. Automatic quantification of ejection fraction from gated myocardial perfusion SPECT. *J Nucl Med* 1995;36:2138–47.
10. Williams KA, Taillon LA. Left ventricular function in patients with coronary artery disease assessed by gated tomographic myocardial perfusion images. Comparison with assessment by contrast ventriculography and first-pass radionuclide angiography. *J Am Coll Cardiol* 1996;27:173–81.
11. Gunning MG, Anagnostopoulos C, Davies G, Format SM, Ell PJ, Underwood SR. Gated technetium-99m-tetrofosmin SPECT and cine MRI to assess left ventricular contraction. *J Nucl Med* 1997;38:438–42.
12. Everaert H, Bossuyt A, Franken PR. Left ventricular ejection fraction and volumes from gated single photon emission tomographic myocardial perfusion images: comparison between two algorithms working in three-dimensional space. *J Nucl Cardiol* 1997;4:472–6.
13. Mochizuki T, Murase K, Tanaka H, Kondoh T, Hamamoto K, Tauxe WN. Assessment of left ventricular volume using ECG-gated SPECT with technetium-99m-MIBI and technetium-99m-tetrofosmin. *J Nucl Med* 1997;38:53–7.
14. Stollfuss JC, Haas F, Matsunari I, Neverve J, Nekolla S, Schneider-Eicke J, et al. Regional myocardial wall thickening and global ejection fraction in patients with low angiographic left ventricular ejection fraction assessed by visual and quantitative resting ECG-gated <sup>99m</sup>Tc-tetrofosmin single-photon emission tomography and magnetic resonance imaging. *Eur J Nucl Med* 1998;25:522–30.
15. Nichols K, Amis J, dePuey G, Mieres J, Malhotra S, Rozanski A. Relationship of gated SPECT ventricular function parameters to angiographic measurements. *J Nucl Cardiol* 1998;5:295–303.
16. Manrique A, Faraggi M, Vera P, Vilain D, Lebtahi R, Cribier A, et al. 201-Tl and <sup>99m</sup>Tc-MIBI gated SPECT in patients with large perfusion defects and left ventricular dysfunction: comparison with equilibrium radionuclide angiography. *J Nucl Med* 1999;40:805–9.
17. Vaduganathan P, He ZX, Vick W, Mahmarian JJ, Verani MS. Evaluation of left ventricular wall motion, volumes and ejection fraction by gated myocardial tomography with technetium <sup>99m</sup>-labeled tetrofosmin: a comparison with cine magnetic resonance imaging. *J Nucl Cardiol* 1999;6:3–10.
18. Yoshika J, Hasegawa S, Yamaguchi H, Tokita N, Paul AK, Xiuli M, et al. Left ventricular volumes and ejection fraction calculated from quantitative electrocardiogram-gated <sup>99m</sup>Tc-tetrofosmin myocardial SPECT. *J Nucl Med* 1999;40:1693–8.
19. Cwajg E, Cwajg J, He ZX, Hwang WS, Keng F, Nagueh SF, et al. Gated myocardial perfusion tomography for the assessment of left ventricular function and volumes: comparison with echocardiography. *J Nucl Med* 1999;40:1857–65.
20. Tadamura E, Kudoh T, Motooka M, Inubushi M, Shirakawa S, Hattori N, et al. Assessment of regional and global left ventricular function by reinjection Tl-201 and rest Tc-99m sestamibi ECG-gated SPECT. Comparison with three-dimensional magnetic resonance imaging. *J Am Coll Cardiol* 1999;33:991–7.
21. Tadamura E, Kudoh T, Motooka M, Inubushi M, Okada T, Kubo S, et al. Use of technetium-99m sestamibi ECG-gated single-photon emission tomography for the evaluation of left ventricular function following coronary artery bypass graft: comparison with three-dimensional magnetic resonance imaging. *Eur J Nucl Med* 1999;26:705–12.
22. Stollfuss JC, Haas F, Matsunari I, Neverve J, Nekolla S, Ziegler S, et al. <sup>99m</sup>Tc-tetrofosmin SPECT for prediction of functional recovery defined by MRI in patients with severe left ventricular dysfunction: additional value of gated SPECT. *J Nucl Med* 1999;40:1824–31.
23. Faber TL, Cooke CD, Folks RD, Vansant JP, Nichols KJ, DePuey EG, et al. Left ventricular function and perfusion from gated SPECT perfusion images: an integrated method. *J Nucl Med* 1999;40:650–9.
24. Vera P, Koning R, Cribier A, Manrique A. Comparison of two three-dimensional gated SPECT methods with thallium in patients with large myocardial infarction. *J Nucl Cardiol* 2000;7:312–9.
25. Nichols K, Lefkowitz D, Faber T, Folks R, Cooke D, Garcia EV, et al. Echocardiographic validation of gated SPECT ventricular function measurements. *J Nucl Med* 2000;41:1308–14.
26. Chua T, Yin LC, Thiang TH, Choo TB, Ping DZ, Leng LY. Accuracy of the automated assessment of left ventricular function with gated perfusion SPECT in the presence of perfusion defects and left ventricular dysfunction: correlation with equilibrium radionuclide ventriculography and echocardiography. *J Nucl Cardiol* 2000;7:301–11.
27. Bax JJ, Lamb H, Dibbets P, Pelikan H, Boersma E, Viergever EP, et al. Comparison of gated single-photon emission computed tomography with magnetic resonance imaging for evaluation of left ventricular function in ischemic cardiomyopathy. *Am J Cardiol* 2000;86:1299–305.
28. Bavelaar-Croon CD, Kayser HW, van der Wall EE, de Roos A, Dibbets-Schneider P, Pauwels EK, et al. Left ventricular function: correlation of quantitative gated SPECT and MR imaging over a wide range of values. *Radiology* 2000;217:572–5.
29. Atsma DE, Bavelaar-Croon CD, Germano G, Dibbets-Schneider P, van Eck-Smit BL, Pauwels EK, et al. Good correlation between gated single photon emission computed myocardial tomography and contrast ventriculography in the assessment of global and regional left ventricular function. *Int J Card Imaging* 2000;16:447–53.
30. Faber TL, Vansant JP, Pettigrew RI, Galt JR, Blais M, Chatzimavroudis G, et al. Evaluation of left ventricular endocardial volumes and ejection fractions computed from gated



- perfusion SPECT with magnetic resonance imaging: comparison of two methods. *J Nucl Cardiol* 2001;8:645–51.
31. Thorley PJ, Plein S, Bloomer TN, Ridgway JP, Sivananthan UM. Comparison of  $^{99m}\text{Tc}$  tetrofosmin gated SPECT measurements of left ventricular volumes and ejection fraction with MRI over a wide range of values. *Nucl Med Commun* 2003;24:763–9.
  32. Lipke CS, Kuhl HP, Nowak B, Kaiser HJ, Reinartz P, Koch KC, et al. Validation of 4D-MSPECT and QGS for quantification of left ventricular volumes and ejection fraction from gated  $^{99m}\text{Tc}$ -MIBI SPET: comparison with cardiac magnetic resonance imaging. *Eur J Nucl Med Mol Imaging* 2004;31:482–90.
  33. Persson E, Carlsson M, Palmer J, Pahlm O, Arheden H. Evaluation of left ventricular volumes and ejection fraction by automated gated myocardial SPECT versus cardiovascular magnetic resonance. *Clin Physiol Funct Imaging* 2005;25:135–41.
  34. Schaefer WM, Lipke CS, Standke D, Kuhl HP, Nowak B, Kaiser HJ, et al. Quantification of left ventricular volumes and ejection fraction from gated  $^{99m}\text{Tc}$ -MIBI SPECT: MRI validation and comparison of the Emory Cardiac Tool Box with QGS and 4D-MSPECT. *J Nucl Med* 2005;46:1256–63.
  35. Marie PY, Djaballah W, Franken PR, Vanhove C, Muller MA, Boutley H, et al. OSEM reconstruction, associated with temporal Fourier and depth-dependant resolution recovery filtering, enhances results from sestamibi and  $^{201}\text{Tl}$  16-interval gated SPECT. *J Nucl Med* 2005;46:1789–95.
  36. Guterberlet M, Mehl S, Froelich M, Hausmann H, Plotkin M, Ruf J, et al. Determination of ventricular volumes in coronary artery disease. Comparison of two gated SPECT analysis tools with MRI. *Nuklearmedizin* 2006;45:63–73.
  37. Cullom SJ, Case JA, Bateman TM. Electrocardiographically gated myocardial perfusion SPECT: technical principles and quality control considerations. *J Nucl Cardiol* 1998;5:418–25.
  38. Paul AK, Nabi HA. Gated myocardial perfusion SPECT: basic principles, technical aspects, and clinical applications. *J Nucl Med Technol* 2004;32:179–87.
  39. Sciagrà R, Leoncini M. Gated single-photon emission computed tomography. The present-day “one-stop-shop” for cardiac imaging. *Q J Nucl Med Mol Imaging* 2005;49:19–29.
  40. Abidov A, Germano G, Hachamovitch R, Berman DS. Gated SPECT in assessment of regional and global left ventricular function: major tool of modern nuclear imaging. *J Nucl Cardiol* 2006;13:261–79.
  41. Nichols K, Dorbala S, DePuey EG, Yao SS, Sharma A, Rozanski A. Influence of arrhythmias on gated SPECT myocardial perfusion and function quantification. *J Nucl Med* 1999;40:924–34.
  42. Nichols K, Yao SS, Kamran M, Faber TL, Cooke CD, DePuey EG. Clinical impact of arrhythmias on gated SPECT cardiac myocardial perfusion and function assessment. *J Nucl Cardiol* 2001;8:19–30.
  43. ASNC Executive Council. American Society of Nuclear Cardiology position statement on electrocardiographic gating of myocardial perfusion SPECT scintigrams. *J Nucl Cardiol* 1999;6:470–1.
  44. Gait JR, Garcia EV, Robbins WL. Effects of myocardial wall thickness of SPECT quantification. *IEEE Trans Med Imaging* 1990;9:144–50.
  45. Nichols K, DePuey EG, Friedman MI, Rozanski A. Do patient data ever exceed the partial volume limit in gated SPECT studies? *J Nucl Cardiol* 1998;5:484–90.
  46. Nakajima K, Taki J, Higuchi T, Kawano M, Taniguchi M, Maruhashi K, et al. Gated SPET quantification of small hearts: mathematical simulation and clinical application. *Eur J Nucl Med* 2000;27:1372–9.
  47. Hambye AS, Vervaet A, Dobbeleir A. Variability of left ventricular ejection fraction and volumes with quantitative gated SPECT: influence of algorithm, pixel size and reconstruction parameters in small and normal-sized hearts. *Eur J Nucl Med Mol Imaging* 2004;31:1606–13.
  48. Khalil MM, Elgazzar A, Khalil W, Omar A, Ziada G. Assessment of left ventricular ejection fraction by four different methods using  $^{99m}\text{Tc}$  tetrofosmin gated SPECT in patients with small hearts: correlation with gated blood pool. *Nucl Med Commun* 2005;26:885–93.
  49. Sharir T, Kang X, Germano G, Bax JJ, Shaw LJ, Gransar H, et al. Prognostic value of poststress left ventricular volume and ejection fraction by gated myocardial perfusion SPECT in women and men: gender-related differences in normal limits and outcomes. *J Nucl Cardiol* 2006;13:495–506.
  50. Leoncini M, Marcucci G, Sciagrà R, Frascarelli F, Traini AM, Mondanelli D, et al. Nitrate-enhanced gated Tc-99m sestamibi SPECT for evaluating regional wall motion at baseline and during low dose dobutamine infusion in patients with chronic coronary artery disease and left ventricular dysfunction. Comparison with two-dimensional echocardiography. *J Nucl Cardiol* 2000;7:426–31.
  51. Abidov A, Slomka PJ, Nishina H, Hayes SW, Kang X, Yoda S, et al. Left ventricular shape index assessed by gated stress myocardial perfusion SPECT: initial description of a new variable. *J Nucl Cardiol* 2006;13:652–9.
  52. Links JM, DePuey EG, Taillefer R, Becker LC. Attenuation correction and gating synergistically improve the diagnostic accuracy of myocardial perfusion SPECT. *J Nucl Cardiol* 2002;9:183–7.
  53. Thompson RC, Heller GV, Johnson LL, Case JA, Cullom J, Garcia EV, et al. Value of attenuation correction on ECG-gated SPECT myocardial perfusion imaging related to body mass index. *J Nucl Cardiol* 2005;12:195–202.
  54. Bateman TM, Cullom SJ. Attenuation correction single-photon emission computed tomography myocardial perfusion imaging. *Semin Nucl Med* 2005;35:37–51.
  55. Nakajima K, Higuchi T, Taki J, Kawano M, Tonami N. Accuracy of ventricular volume and ejection fraction measured by gated myocardial SPECT: comparison of 4 software programs. *J Nucl Med* 2001;42:1571–8.
  56. Kritzman JN, Ficaro EP, Corbett JR. Reproducibility of 3-D MSPECT for quantitative gated SPECT sestamibi perfusion analysis [abstract]. *J Nucl Med* 2000;41(suppl):166P.
  57. Goris ML, Thompson C, Malone LJ, Franken PR. Modelling the integration of myocardial regional perfusion and function. *Nucl Med Commun* 1994;15:9–20.
  58. Liu YH, Sinusas AJ, Khalmov D, Gebuza BJ, Wackers FJT. New hybrid count-and geometry-based method for quantification of left ventricular volumes and ejection fraction from ECG-gated SPECT: methodology and validation. *J Nucl Cardiol* 2005;12:55–65.
  59. Smith WH, Kastner RJ, Calnon DA, Segalla D, Beller GA, Watson DD. Quantitative gated single photon emission computed tomography imaging: a count-based method for display and measurement of regional and global ventricular systolic function. *J Nucl Cardiol* 1997;4:451–63.
  60. Nakata T, Katagiri Y, Odawara Y, Eguchi M, Koruda M, Tsuchihashi K, et al. Two- and three-dimensional assessments of myocardial perfusion and function by using technetium-99m sestamibi gated SPECT with a combination of count-and image-based techniques. *J Nucl Cardiol* 2000;7:623–32.
  61. Nichols K, Santana CA, Folks R, Krawczynska E, Cooke CD, Faber TL, et al. Comparison between ECTb and QGS for assessment of left ventricular function from gated myocardial perfusion SPECT. *J Nucl Cardiol* 2002;9:285–93.
  62. Lum DP, Coel MN. Comparison of automatic quantification software for the measurement of ventricular volume and ejection

- fraction in gated myocardial perfusion SPECT. *Nucl Med Commun* 2003;24:259–66.
63. Khalil MM, Elgazzar A, Khalil W. Evaluation of left ventricular ejection fraction by the quantitative algorithms QGS, ECTb, LMC and LVGTF using gated myocardial perfusion SPECT: investigation of relative accuracy. *Nucl Med Commun* 2006; 27:321–32.
  64. Feng B, Sitek A, Gullberg GT. Calculation of left ventricular ejection fraction without edge detection: application to small hearts. *J Nucl Med* 2002;43:786–94.
  65. Verberne HJ, Dijkgraaf MG, Somsen GA, van Eck-Smit BL. Stress-related variations in left ventricular function as assessed with gated myocardial perfusion SPECT. *J Nucl Cardiol* 2003;10:456–63.
  66. De Winter O, De Bondt P, Van De Wiele C, De Backer G, Dierckx RA, De Sutter J. Day-to-day variability of global left ventricular functional and perfusional measurements by quantitative gated SPECT using Tc-99m tetrofosmin in patients with heart failure due to coronary artery disease. *J Nucl Cardiol* 2004;11:47–52.
  67. Vallejo E, Chaya H, Plancarte G, Victoria D, Bialostozky D. Variability of serial same-day left ventricular ejection fraction using quantitative gated SPECT. *J Nucl Cardiol* 2002;9:377–84.
  68. Nakajima K, Nishimura T. Inter-institution preference-based variability of ejection fraction and volumes using quantitative gated SPECT with <sup>99m</sup>Tc-tetrofosmin: a multicentre study involving 106 hospitals. *Eur J Nucl Med Mol Imaging* 2006; 33:127–33.
  69. Rozanski A, Nichols K, Yao SS, Malholtra S, Cohen R, DePuey EG. Development and application of normal limits for left ventricular ejection fraction and volume measurements from <sup>99m</sup>Tc-sestamibi myocardial perfusion gated SPECT. *J Nucl Med* 2000;41:1445–50.
  70. Ababneh AA, Sciacca RR, Kim B, Bergmann SR. Normal limits for left ventricular ejection fraction and volumes estimated with gated myocardial perfusion imaging in patients with normal exercise test results: influence of tracer, gender, and acquisition camera. *J Nucl Cardiol* 2000;7:661–8.
  71. Kumita S, Cho K, Nakajo H, Toba M, Uwamori M, Mizumura S, et al. Assessment of left ventricular diastolic function with electrocardiography-gated myocardial perfusion SPECT: comparison with multigated equilibrium radionuclide angiography. *J Nucl Cardiol* 2001;8:568–74.
  72. Navare SM, Wackers FJ, Liu YH. Comparison of 16-frame and 8-frame gated SPET imaging for determination of left ventricular volumes and ejection fraction. *Eur J Nucl Med Mol Imaging* 2003;30:1330–7.
  73. Akincioglu C, Berman DS, Nishina H, Kavanagh PB, Slomka PJ, Abidov A, et al. Assessment of diastolic function using 16-frame <sup>99m</sup>Tc-sestamibi gated myocardial perfusion SPECT: normal values. *J Nucl Med* 2005;46:1102–8.
  74. Hesse B, Tagil K, Cuocolo A, Anagnostopoulos C, Bardies M, Bax J, et al. EANM/ESC procedural guidelines for myocardial perfusion imaging in nuclear cardiology. *Eur J Nucl Med Mol Imaging* 2005;32:855–97.
  75. Vourvouri EC, Poldermans D, Bax JJ, Sianos G, Sozzi FB, Schinkel AF, et al. Evaluation of left ventricular function and volumes in patients with ischaemic cardiomyopathy: gated single-photon emission computed tomography versus two-dimensional echocardiography. *Eur J Nucl Med* 2001;28:1610–5.
  76. Sharir T, Bacher-Stier C, Dhar S, Lewin HC, Miranda R, Friedman JD, et al. Identification of severe and extensive coronary artery disease by postexercise regional wall motion abnormalities in Tc-99m sestamibi gated single-photon emission computed tomography. *Am J Cardiol* 2000;86:1171–5.
  77. Emmett L, Iwanochko RM, Freeman MR, Barolet A, Lee DS, Husain M. Reversible regional wall motion abnormalities on exercise technetium-99m-gated cardiac single photon emission computed tomography predict high-grade angiographic stenoses. *J Am Coll Cardiol* 2002;39:991–8.
  78. Mazzanti M, Germano G, Kiat H, Kavanagh PB, Alexanderson E, Friedman JD, et al. Identification of severe and extensive coronary artery disease by automatic measurement of transient ischemic dilatation of the left ventricle in dual-isotope myocardial perfusion SPECT. *J Am Coll Cardiol* 1996;27:1612–20.
  79. Yamagishi H, Shirai N, Yoshiyama M, Teragaki M, Akioka K, Takeuchi K, et al. Incremental value of left ventricular ejection fraction for detection of multivessel coronary artery disease in exercise <sup>201</sup>Tl gated myocardial perfusion imaging. *J Nucl Med* 2002;43:131–9.
  80. Shirai N, Yamagishi H, Yoshiyama M, Teragaki M, Akioka K, Takeuchi K, et al. Incremental value of assessment of regional wall motion for detection of multivessel coronary artery disease in exercise <sup>201</sup>Tl gated myocardial perfusion imaging. *J Nucl Med* 2002;43:443–50.
  81. Lima RS, Watson DD, Goode AR, Siadaty MS, Ragosta M, Beller GA, et al. Incremental value of combined perfusion and function over perfusion alone by gated SPECT myocardial perfusion imaging for detection of severe three-vessel coronary artery disease. *J Am Coll Cardiol* 2003;42:64–70.
  82. Kaul S, Senior R, Firsche C, Wang XQ, Lindner J, Villanueva FS, et al. Incremental value of cardiac imaging in patients presenting to the emergency department with chest pain and without ST-segment elevation: a multicenter study. *Am Heart J* 2004;148:129–36.
  83. Taillefer R, DePuey EG, Udelson JE, Beller GA, Benjamin C, Gagnon A. Comparison between the end-diastolic images and the summed images of gated <sup>99m</sup>Tc-sestamibi SPECT perfusion study in detection of coronary artery disease in women. *J Nucl Cardiol* 1999;6:169–76.
  84. Hachamovitch R, Berman DS. The use of nuclear cardiology in clinical decision making. *Semin Nucl Med* 2005;35:62–72.
  85. Sharir T, Germano G, Kavanagh PB, Lai S, Cohen I, Lewin HC, et al. Incremental prognostic value of pots-stress left ventricular ejection fraction and volume by gated myocardial perfusion single photon emission computed tomography. *Circulation* 1999;100:1035–42.
  86. Sharir T, Germano G, Kang X, Lewin HC, Miranda R, Cohen I, et al. Prediction of myocardial infarction versus cardiac death by gated myocardial perfusion SPECT: risk stratification by the amount of stress-induced ischemia and the poststress ejection fraction. *J Nucl Med* 2001;42:831–7.
  87. Kroll D, Farah W, McKendall GR, Reinert SE, Johnson LL. Prognostic value of stress-gated Tc-99m sestamibi SPECT after acute myocardial infarction. *Am J Cardiol* 2001;87:381–6.
  88. Bestetti A, Triulzi A, Di Leo C, Tagliabue L, Strinchini A, Bax JJ. Enhanced prognostic stratification of CAD patients with low ejection fraction by stress-rest Tc99m tetrofosmin gated-SPECT. *Acta Cardiol* 2004;59:17–23.
  89. Hashimoto J, Suzuki T, Nakahara T, Kosuda S, Kubo A. Preoperative risk stratification using stress myocardial perfusion scintigraphy with electrocardiographic gating. *J Nucl Med* 2003;44:385–90.
  90. Spinelli L, Petretta M, Acampa W, He W, Petretta A, Bonaduce D, et al. Prognostic value of combined assessment of regional left ventricular function and myocardial perfusion by dobutamine and rest gated SPECT in patients with uncomplicated acute myocardial infarction. *J Nucl Med* 2003;44: 1023–9.
  91. Travin MI, Heller GV, Johnson LL, Katten D, Ahlberg AW, Isasi CR, et al. The prognostic value of ECG-gated SPECT imaging in patients undergoing stress Tc-99m sestamibi myocardial perfusion imaging. *J Nucl Cardiol* 2004;11:253–62.

92. Thomas GS, Miyamoto MI, Morello AP 3rd, Majmundar H, Thomas JJ, Sampson CH, et al. Technetium 99m sestamibi myocardial perfusion imaging predicts clinical outcome in the community outpatient setting. The Nuclear Utility in the Community (NUC) study. *J Am Coll Cardiol* 2004;43:213–23.
93. De Winter O, Velghe A, Van de Veire N, De Bondt P, De Buyzere M, Van De Wiele C, et al. Incremental prognostic value of combined perfusion and function assessment during myocardial gated SPECT in patients aged 75 years or older. *J Nucl Cardiol* 2005;12:662–70.
94. Bigi R, Bestetti A, Strinchini A, Conte A, Gregori D, Brusoni B, et al. Combined assessment of left ventricular perfusion and function by gated single-photon emission computed tomography for the risk stratification of high-risk hypertensive patients. *J Hypertens* 2006;24:767–73.
95. Germano G, Erel J, Lewin H, Kavanagh PB, Berman DS. Automatic quantification of regional myocardial wall motion and thickening from gated technetium-99m sestamibi myocardial perfusion single-photon emission computed tomography. *J Am Coll Cardiol* 1997;30:1360–7.
96. Yang KTA, Chen HD. Evaluation of global and regional left ventricular function using technetium-99m sestamibi ECG-gated single-photon emission tomography. *Eur J Nucl Med* 1998;25:515–21.
97. Sugihara H, Tamaki N, Nozawa M, Ohmura T, Inamoto Y, Taniguchi Y, et al. Septal perfusion and wall thickening in patients with left bundle branch block assessed by technetium-99m-sestamibi gated tomography. *J Nucl Med* 1997;38:545–7.
98. Kasai T, Depuey EG, Shah AA. Decreased septal wall thickening in patients with left bundle branch block. *J Nucl Cardiol* 2004;11:32–7.
99. Giubbini R, Rossini P, Bertagna F, Bosio G, Paghera B, Pizzocaro C, et al. Value of gated SPECT in the analysis of regional wall motion of the interventricular septum after coronary artery bypass grafting. *Eur J Nucl Med Mol Imaging* 2004;31:1371–7.
100. Leoncini M, Marcucci G, Sciagrà R, Frascarelli F, Bellandi F, Gallopin M, et al. Usefulness of distinct activity thresholds according to baseline regional asynergy for predicting functional recovery in patients with chronic coronary artery disease and left ventricular dysfunction. A study with nitrate-enhanced sestamibi gated SPECT. *J Nucl Cardiol* 2001;8:555–60.
101. Kurihara H, Nakamura S, Takehana K, Fukui M, Sawanishi T, Maeba H, et al. Scintigraphic prediction of left ventricular functional recovery early after primary coronary angioplasty using single-injection quantitative electrocardiographic gated SPECT. *Nucl Med Commun* 2005;26:505–11.
102. Marini C, Giorgetti A, Gimelli A, Kusch A, Sereni N, L'abbate A, et al. Extension of myocardial necrosis differently affects MIBG retention in heart failure caused by ischaemic heart disease or by dilated cardiomyopathy. *Eur J Nucl Med Mol Imaging* 2005;32:682–8.
103. Everaert H, Vanhove C, Franken PR. Low-dose dobutamine gated single-photon emission tomography: comparison with stress echocardiography. *Eur J Nucl Med* 2000;27:413–8.
104. Yoshinaga K, Morita K, Yamada S, Komuro K, Katoh C, Ito Y, et al. Low-dose dobutamine electrocardiography-gated myocardial SPECT for identifying viable myocardium: comparison with dobutamine stress echocardiography and PET. *J Nucl Med* 2001;42:838–44.
105. Yamagishi H, Akioka K, Hirata K, Sakanoue Y, Toda I, Yoshiyama M, et al. Dobutamine stress electrocardiography-gated Tc 99m tetrofosmin SPECT for detection of viable but dysfunctional myocardium. *J Nucl Cardiol* 2001;8:58–67.
106. Leoncini M, Marcucci G, Sciagrà R, Frascarelli F, Simonetti I, Bini L, et al. Prediction of functional recovery in patients with chronic coronary artery disease and left ventricular dysfunction combining the evaluation of myocardial perfusion and contractile reserve using nitrate-enhanced technetium-99m sestamibi gated single-photon emission computed tomography and dobutamine stress. *Am J Cardiol* 2001;87:1346–50.
107. Zafir N, Arditi A, Ben-Gal T, Solodky A, Hassid Y, Sulkes J, et al. Additive value of low-dose dobutamine to technetium-99m sestamibi-gated single-photon emission computed tomography for prediction of wall motion improvement in patients undergoing coronary artery bypass graft. *Clin Cardiol* 2003;26:530–5.
108. Simoes MV, de Almeida-Filho OC, Pintya AO, de Figueiredo AB, Antloga CM, Salis FV, et al. Prediction of left ventricular wall motion recovery after acute myocardial infarction by Tl-201 gated SPECT: incremental value of integrated contractile reserve assessment. *J Nucl Cardiol* 2002;9:294–303.
109. Heiba SI, Abdel-Dayem HM, Gould R, Bernaski E, Morlote M, El-Zeftawy H, et al. Value of low-dose dobutamine addition to routine dual isotope gated SPECT myocardial imaging in patients with healed myocardial infarction or abnormal wall thickening by echocardiogram. *Am J Cardiol* 2004;93:300–6.
110. Kumita S, Cho K, Nakajo H, Toba M, Fukushima Y, Mizumura S, et al. Assessment of contractile response to dobutamine stress by means of ECG-gated myocardial SPECT: comparison with myocardial perfusion and fatty acid metabolism. *Ann Nucl Med* 2005;19:379–86.
111. Leoncini M, Sciagrà R, Maioli M, Bellandi F, Marcucci G, Sestini S, et al. Usefulness of dobutamine Tc-99m sestamibi-gated single-photon emission computed tomography for prediction of left ventricular ejection fraction outcome after coronary revascularization for ischemic cardiomyopathy. *Am J Cardiol* 2002;89:817–21.
112. Kasama S, Toyama T, Kumakura H, Takayama Y, Ichikawa S, Suzuki T, et al. Myocardial contractile reserve determined by dobutamine stress Tc-99m tetrofosmin quantitative gated SPECT predicts late spontaneous improvement in cardiac function in patients with recent-onset dilated cardiomyopathy. *J Nucl Cardiol* 2003;10:607–14.
113. Kasama S, Toyama T, Kumakura H, Takayama Y, Ichikawa S, Tange S, et al. Dobutamine stress <sup>99m</sup>Tc-tetrofosmin quantitative gated SPECT predicts improvement of cardiac function after carvedilol treatment in patients with dilated cardiomyopathy. *J Nucl Med* 2004;45:1878–84.
114. Weytjens C, Cosyns B, Van Camp G, Daniels C, Spincemaille K, Dupont A, et al. Abnormal response to inotropic stimulation in young asymptomatic type I diabetic patients demonstrated by serial gated myocardial perfusion SPECT imaging. *Eur J Nucl Med Mol Imaging* 2005;32:1317–23.
115. Zellweger MJ, Tabacek G, Zutter AW, Weinbacher M, Cron TA, Muller-Brand J, et al. Evidence for left ventricular remodeling after percutaneous coronary intervention: effect of percutaneous coronary intervention on left ventricular ejection fraction and volumes. *Int J Cardiol* 2004;96:197–201.
116. Ogard CG, Sondergaard SB, Vestergaard H, Jakobsen H, Nielsen SL. Myocardial perfusion defects and the left ventricular ejection fraction disclosed by scintigraphy in patients with primary hyperparathyroidism. *World J Surg* 2005;29:914–6.
117. Lima RSL, De Lorenzo A, Soares AJ. Relation between postexercise abnormal heart rate recovery and myocardial damage evidenced by gated single-photon emission computed tomography. *Am J Cardiol* 2006;97:1452–4.
118. Feola M, Biggi A, Francini A, Leonardi G, Ribichini F, Ferrero V, et al. The acute administration of trimetazidine modified myocardial perfusion and left ventricular function in 31 patients with ischaemic ventricular dysfunction. *Int J Cardiovasc Imaging* 2004;20:315–20.



119. Valgimigli M, Rigolin GM, Cittanti C, Malagutti P, Curello S, Percoco G, et al. Use of granulocyte-colony stimulating factor during acute myocardial infarction to enhance bone marrow stem cell mobilization in humans: clinical and angiographic safety profile. *Eur Heart J* 2005;26:1838–45.
120. Kuethe F, Figulla HR, Herzau M, Voth M, Fritzenwanger M, Opfermann T, et al. Treatment with granulocyte colony-stimulating factor for mobilization of bone marrow cells in patients with acute myocardial infarction. *Am Heart J* 2005;150:115.
121. Beeres SL, Bax JJ, Dibbets P, Stokkel MP, Zeppenfeld K, Fibbe WE, et al. Effect of intramyocardial injection of autologous bone marrow-derived mononuclear cells on perfusion, function, and viability in patients with drug-refractory chronic ischemia. *J Nucl Med* 2006;47:574–80.
122. Beeres SL, Bax JJ, Dibbets-Schneider P, Stokkel MP, Fibbe WE, van der Waal EE, et al. Sustained effect of autologous bone marrow mononuclear cell injection in patients with refractory angina pectoris and chronic myocardial ischemia: twelve-month follow-up results. *Am Heart J* 2006;152:684.e11–16.
123. Fukuchi K, Yasumura Y, Kiso K, Hayashida K, Miyatake K, Ishida Y. Gated myocardial SPECT to predict response to beta-blocker therapy in patients with idiopathic dilated cardiomyopathy. *J Nucl Med* 2004;45:527–31.
124. Sciarà R, Giaccardi M, Porciani MC, Colella A, Michelucci A, Pieragnoli P, et al. Myocardial perfusion imaging using gated SPECT in heart failure patients undergoing cardiac resynchronization therapy. *J Nucl Med* 2004;45:164–8.
125. Chen J, Garcia EV, Folks RD, Cooke CD, Faber TL, Tauxe EL, et al. Onset of left ventricular mechanical contraction as determined by phase analysis of ECG-gated myocardial perfusion SPECT imaging: development of a diagnostic tool for assessment of cardiac mechanical dyssynchrony. *J Nucl Cardiol* 2005;12:687–95.
126. Tsurugaya H, Tada H, Toyama T, Naito S, Adachi H, Seki RT, et al. Usefulness of quantitative gated single-photon emission computed tomography to evaluate ventricular synchrony in patients receiving biventricular pacing. *Am J Cardiol* 2004;94:127–30.
127. Schafers M, Stypmann J, Wilhelm MJ, Stegger L, Kies P, Hermann S, et al. Functional changes after partial left ventriculectomy and mitral valve repair assessed by gated perfusion SPECT. *J Nucl Med* 2004;45:1605–10.
128. Fujii H, Ohashi H, Tsutsumi Y, Kawai T, Iino K, Onaka M. Comparison of volume study by left ventriculography and gated SPECT in endoventricular circular patch plasty. *J Card Surg* 2005;20:322–5.
129. Fujii H, Ohashi H, Tsutsumi Y, Kawai T, Iino K, Onaka M. Radionuclide study of mid-term left ventricular function after endoventricular circular patch plasty. *Eur J Cardiothorac Surg* 2004;26:125–8.
130. Htay T, Mehta D, Heo J, Iskandrian AE. Left ventricular function in patients with type 2 diabetes mellitus. *Am J Cardiol* 2005;95:798–801.
131. Van der Wall EE, Bax JJ. Different imaging approaches in the assessment of left ventricular dysfunction: all things equal? *Eur Heart J* 2000;21:1295–7.
132. Alfakih K, Reid S, Jones T, Sivananthan M. Assessment of ventricular function and mass by cardiac magnetic resonance imaging. *Eur Radiol* 2004;14:1813–22.
133. Lim TK, Senior R. Noninvasive modalities for the assessment of left ventricular function: all are equal but some are more equal than others. *J Nucl Cardiol* 2006;13:445–9.
134. van Royen N, Jaffe CC, Krumholz HM, Johnson KM, Lynch PJ, Natale D, et al. Comparison and reproducibility of visual echocardiographic and quantitative radionuclide left ventricular ejection fractions. *Am J Cardiol* 1996;77:843–50.
135. Bellenger NG, Burgess MI, Ray SG, Lahiri A, Coats AJ, Cleland JG, et al. Comparison of left ventricular ejection fraction and volumes in heart failure by echocardiography, radionuclide ventriculography and cardiovascular magnetic resonance; are they interchangeable? *Eur Heart J* 2000;21:1387–96.
136. Senior R, Sridhara BS, Basu S, Henley M, Handler CE, Raftery EB, et al. Comparison of radionuclide ventriculography and 2D echocardiography for the measurement of left ventricular ejection fraction following acute myocardial infarction. *Eur Heart J* 1994;15:1235–9.
137. Jacobs LD, Salgo IS, Goonewardena S, Weinert L, Coon P, Bardo D, et al. Rapid online quantification of left ventricular volume from real-time three-dimensional echocardiography. *Eur Heart J* 2006;27:460–8.
138. Mahnken AH, Muhlenbruch G, Koos R, Stanzel S, Busch PS, Niethammer M, et al. Automated vs. manual assessment of left ventricular function in cardiac multidetector row computed tomography: comparison with magnetic resonance imaging. *Eur J Radiol* 2006;16:1416–23.
139. Henneman MM, Schuiff JD, Jukema JW, Holman ER, Lamb HJ, de Roos A, et al. Assessment of global and regional left ventricular function and volumes with 64-slice MSCT: a comparison with 2D echocardiography. *J Nucl Cardiol* 2006;13:480–7.
140. Thompson RC, Cullom SJ. Issues regarding radiation dosage of cardiac nuclear and radiography procedures. *J Nucl Cardiol* 2006;13:19–23.
141. Schepis T, Gaemperli O, Koepfli P, Valenta I, Strobel K, Brunner A, et al. Comparison of 64-slice CT with gated SPECT for evaluation of left ventricular function. *J Nucl Med* 2006;47:1288–94.
142. Cuocolo A, Acampa W, Imbriaco M, De Luca N, Iovino GL, Salvatore M. The many ways to myocardial perfusion imaging. *Q J Nucl Med Mol Imaging* 2005;49:4–18.
143. Isbell DC, Kramer CM. Cardiovascular magnetic resonance: structure, function, perfusion, and viability. *J Nucl Cardiol* 2005;12:324–36.
144. Clark AN, Beller GA. The present role of nuclear cardiology in clinical practice. *Q J Nucl Med Mol Imaging* 2005;49:43–58.
145. Poornima IG, Miller TD, Christian TF, Hodge DO, Bailey KR, Gibbons RJ. Utility of myocardial perfusion imaging in patients with low-risk treadmill scores. *J Am Coll Cardiol* 2004;43:194–9.
146. Raff GL, Gallagher MJ, O'Neill WW, Goldstein JA. Diagnostic accuracy of noninvasive coronary angiography using 64-slice spiral computed tomography. *J Am Coll Cardiol* 2005;46:552–7.
147. Hacker M, Jakobs T, Matthiesen F, Vollmar C, Nikolaou K, Becker C, et al. Comparison of spiral multidetector CT angiography and myocardial perfusion imaging in the noninvasive detection of functionally relevant coronary artery lesions: first clinical experiences. *J Nucl Med* 2005;46:1294–300.
148. Berman DS, Hachamovitch R, Shaw LJ, Friedman JD, Hayes SW, Thomson LE, et al. Roles of nuclear cardiology, cardiac computed tomography, and cardiac magnetic resonance: Non-invasive risk stratification and a conceptual framework for the selection of noninvasive imaging tests in patients with known or suspected coronary artery disease. *J Nucl Med* 2006;47:1107–18.