



UNIVERSITÀ  
DEGLI STUDI  
FIRENZE

FLORE

## Repository istituzionale dell'Università degli Studi di Firenze

### **Primary cutaneous B-cell lymphoma: A unique type of low grade lymphoma. Clinicopathologic and immunologic study of 83 cases**

Questa è la Versione finale referata (Post print/Accepted manuscript) della seguente pubblicazione:

*Original Citation:*

Primary cutaneous B-cell lymphoma: A unique type of low grade lymphoma. Clinicopathologic and immunologic study of 83 cases / M. SANTUCCI; N. PIMPINELLI; L. ARGANINI. - In: CANCER. - ISSN 0008-543X. - STAMPA. - 67:(1991), pp. 2311-2326.

*Availability:*

This version is available at: 2158/307678 since:

*Terms of use:*

Open Access

La pubblicazione è resa disponibile sotto le norme e i termini della licenza di deposito, secondo quanto stabilito dalla Policy per l'accesso aperto dell'Università degli Studi di Firenze (<https://www.sba.unifi.it/upload/policy-oa-2016-1.pdf>)

*Publisher copyright claim:*

(Article begins on next page)

***Primary Cutaneous B-Cell Lymphoma:  
A Unique Type of Low-Grade Lymphoma***  
***Clinicopathologic and Immunologic Study of 83 Cases***

Marco Santucci, MD, Nicola Pimpinelli, MD, PhD,  
and Luisa Arganini, BSc

Reprinted from *CANCER*, Vol. 67, No. 9, May 1, 1991.  
Copyright © 1991, by the American Cancer Society, Inc. J. B. Lippincott Company.  
Printed in U.S.A.

## **Primary Cutaneous B-Cell Lymphoma: A Unique Type of Low-Grade Lymphoma**

### *Clinicopathologic and Immunologic Study of 83 Cases*

Marco Santucci, MD,\* Nicola Pimpinelli, MD, PhD,†  
and Luisa Arganini, BSc\*

The clinical presentation and course, and the morphoimmunologic features of primary cutaneous B-cell lymphoma (CBCL) were investigated in a series of 83 patients. Fifty-one patients were male and 32 were female (male-to-female ratio of 1.6:1); CBCL primarily involved the elderly (median age, 58 years). A locoregional extension of the disease was quite frequent (86.7%). The neoplastic cells showed a range of appearances reminiscent of the whole spectrum of follicular/parafollicular cells. The antigenic phenotype of tumor cells (CD19+, CD20+, CD22+, CD28+, CD10-, CD5-, MB2+, CD74+/-, CDw75+/-, MT2+/-, surface immunoglobulin+ monoclonal/-) plus the presence of admixed CD14- dendritic reticulum cells suggest a mantle-zone nature for CBCL. The nonaggressive clinical behavior with a substantial tendency to remain localized to a limited area of the skin, the quite good response to nonaggressive treatment, and the dichotomy existing between the enhancement of morphoimmunologic atypism—which parallels the increasing age and growth rate of lesions—and the constant benign overall prognosis on long-term follow-up make CBCL a unique type of lymphoma of low-grade malignancy. Proper recognition of CBCL is mandatory to avoid possible undertreatment or overtreatment of the patients affected. *Cancer* 67:2311-2326, 1991.

**T**HE CUTANEOUS INVOLVEMENT of a B-cell lymphoma has long been considered as a doubtless sign of progression and dissemination of lymph node disease, and thus associated with a poor prognosis, the very existence of primary cutaneous B-cell lymphomas being disputed. Conversely, B-cell lymphoproliferative disorders that respond favorably to local treatment and present a benign prognosis are well known in the skin. Good response to local therapy with the absence of subsequent dissemination and their often cytologically bland appearance have led dermatologists and pathologists to doubt that a di-

agnosis of lymphoma may be applied to such cases, hence, the term pseudolymphoma originated.<sup>1-7</sup> With the advent of immunohistochemical study<sup>8,9</sup> and, quite recently, of DNA analysis,<sup>10</sup> it is now clear that a light chain monoclonal restriction is present in a consistent part of these cases, and that they are monoclonal proliferations, and thus true lymphomas.<sup>11-16</sup>

We report the clinical presentation and course of quite a large series of patients with primary cutaneous B-cell lymphoma (CBCL), and investigate in depth the cytoarchitectural and immunologic profile of the disease. This report delineates the clinicopathologic entity and supports the conjecture of its single nature and actual cutaneous origin.

#### **Materials and Methods**

The files of the Institute of Morbid Anatomy and Histopathology of the University of Florence (Florence, Italy) concerning cutaneous lymphoproliferative disorders were reviewed and 127 cases of CBCL were extracted. The following were crucial criteria for the selection of cases: ab-

From the \*Istituto di Anatomia e Istologia Patologica and the †Clinica Dermosifilopatica II, Università degli Studi di Firenze, Firenze, Italia.

Supported by grants from the Italian Ministries of Public Education, and of University and Scientific and Technologic Research.

The authors thank Dr. Milena Paglierani of the Laboratory of Histochemistry and Mr. Daniele Danielli of the Laboratory of Ultrastructures and the Diagnostic Electron Microscopy Unit of the Institute of Morbid Anatomy and Histopathology of the University of Florence, Italy, for excellent assistance and collaboration in performing the investigation.

Address for reprints: Marco Santucci, MD, Istituto di Anatomia e Istologia Patologica, Policlinico di Careggi, Viale G.B. Morgagni 85, 50134 Firenze, Italia.

Accepted for publication October 18, 1990.

sence of any detectable extracutaneous lesion; expression of B-cell restricted antigens by neoplastic cells; light chain monoclonal restriction or surface immunoglobulin (SIg)-negative staining by neoplastic cells. Due to the lack of available detailed clinical information and/or material useful for immunohistochemical phenotyping, 44 cases were discarded, and the current investigation was thus performed on 83 cases, including the 11 patients on whom we reported previously as examples of CBCL.<sup>14</sup>

Extensive and careful staging procedures<sup>14,16</sup> had been performed at presentation to exclude any extracutaneous spread of the disease in all patients who entered the study.

Several skin biopsies were performed in all patients, either at presentation or on relapse after treatment. Skin samples were obtained from lesions with different dimensions, ages, and growth rates. Biopsies of clinically enlarged lymph nodes were performed in four patients.

Each specimen was divided into three parts and processed for light and electron microscopic and immunohistochemical study. The immunohistologic study was performed either on paraffin or cryostat sections. The monoclonal antibodies used are listed in Table 1.

## Results

### Clinical Data

There were 51 male and 32 female patients with a male-to-female ratio of 1.6:1; the age at the first examination ranged from 22 to 88 years (mean, 55 years; median, 58 years) (Table 2).

All patients presented with plaques, nodules, or tumors of variable age and size. The lesions, red to violet in color, generally had a mammillated smooth shiny surface; ulceration and scaling were uncommon (Fig. 1).

At presentation, in 72 patients (86.7%) the lesions were confined to a rather circumscribed area of the skin, with a noticeable predilection for the back (44.6%) and the head (25.3%), whereas in the remaining 11 patients (13.3%), nodular cutaneous and subcutaneous lesions involved noncontiguous anatomic regions.

Blood cell count, morphologic study, and immunologic phenotyping of circulating mononuclear cells and immunoglobulin (Ig) quantification were unremarkable in all patients but one, who presented a mild hypogammaglobulinemia. This patient had chronic renal failure, treated with hemodialysis for 3 years before the onset of cutaneous lesions.

The data concerning therapy are synoptically reported in Table 2. Twenty-two patients had single or multiple cutaneous relapses. The median disease-free interval was 16 months (mean, 26.6 months; range, 2 to 100 months). No statistically significant differences in disease-free period and/or recurrence rate were found in relation to therapeutic modalities, site of onset, sex, or age at presentation.

TABLE 1. Antibody Panel

Antibody	Cluster designation	Source
Leu-12	CD19	BD
B1	CD20	CC
B2	CD21	CC
Leu-14	CD22	BD
T11	CD22	CC
T3	CD3	CC
OKT4	CD4	OD
OKT8	CD8	OD
Leu-1	CD5	BD
OKT6	CD1a	OD
Leu-8	NA	BD
IL-2 r.	CD25	BD
HLA-DR	NA	BD
C3b r.*	CD35	DP
Ki-1	CD30	DP
Ber-H2†	CD30	DP
DRC-1	NA	DP
J5	CD10	BD
Leu-M3	CD14	BD
Leu-M5	CD11c	BD
OKM1	CD11b	OD
OKT9	CD71	OD
Ki-67	NA	DP
MB2†	NA	BI
LN1†	CDw75	BI
LN2†	CD74	BI
MT1†	CD43	BI
MT2†	NA	BI
LN3†	NA	BI
Anti-kappa*	NA	BD
Anti-lambda*	NA	BD
Anti-gamma	NA	BD
Anti-mu	NA	DP
Anti-delta	NA	DP

NA: not assigned; BD: Becton & Dickinson, Mountain View, CA; CC: Coulter Clone, Sheffield, UK; OD: Ortho Diagnostic Systems, Raritan, NJ; DP: Dakopatts, Copenhagen, Denmark; BI: Biotest AG, Dreieich, Germany.

For predominant immunoreactivity see reference 17.

\* Tested on both frozen and paraffin sections.

† Tested on paraffin sections only.

Nonetheless, local orthovolt radiation therapy proved to be the most subjectively well-accepted therapeutic procedure, and presented the most prolonged disease-free period (median, 20 months; mean, 30.5 months). Further cutaneous relapses occurred in ten of these patients—therapy always resulting in further complete remissions—irrespective of the type of treatment used.

Data on follow-up were available for 65 patients. Despite prolonged follow-up (median, 26 months; mean, 36 months; range, 6 to 100 months), extracutaneous spread of the disease was observed only in two cases. In one case, it was limited to a single lymph node of a draining station, whereas in the other case, a left inguinoaxillary lymph node involvement occurred simultaneously to a cutaneous widespread diffusion, bone marrow involvement, and leukemic spread ( $23.0 \times 10^9$  leukocytes/l) 10 months after complete remission. This patient, affected with chronic

TABLE 2. Clinical Information and Follow-up Data on the Series of 83 Patients

Patient	Age (yr)/ Sex	Past history (yr/mo)	Site at presentation	Initial therapy	Response to treatment	No. of relapses (biopsied)	Disease-free interval (yr/mo)	Treatment of relapses	Survival from diagnosis (yr/mo)
1	68/M	2/2	Back	RT	CR	1 (1)	0/11	RT	1/10
2	58/M	26/0	Back and right arm	RT	CR	5 (3)	1/5	RT	5/9*
3	69/F	2/3	Back	RT	CR	2 (2)	0/6	RT	6/5
4	61/F	0/8	Back	RT	CR	—	0/11	—	0/11
5	64/F	3/2	Back	RT	CR	—	1/2	—	1/2
6	38/M	0/9	Back	RT	CR	5 (4)	0/9	RT + CT	4/8
7	60/M	1/3	Head	RT	CR	2 (2)	0/7	RT	4/3
8	54/M	0/8	Head and neck	Oral corticosteroids	CR	1 (0)	0/6	RT	1/4
9	49/M	1/4	Back	Surgery	PR	—	—	—	3/1
10	45/M	1/8	Right shoulder	RT	CR	—	6/5	—	6/5
11	60/F	1/2	Back	RT	CR	—	1/4	—	1/4
12	84/M	0/6	Head and trunk	CT	CR	2 (1)	0/2	CT	0/9*
13	54/M	2/7	Back	RT	CR	1 (1)	3/2	RT	4/1
14	34/M	0/6	Left arm	Oral corticosteroids	CR	2 (2)	0/8	RT	1/6
15	56/F	1/0	Head	RT	CR	—	0/10	—	0/10
16	72/F	0/6	Back and right thigh	RT	CR	1 (1)†	0/5	CT	0/7‡
17	70/M	2/8	Back	RT	CR	—	3/3	—	3/3
18	67/M	1/5	Back	RT	CR	—	1/2	—	1/2
19	59/M	1/3	Left leg	CT	CR	3 (2)	2/2	RT	4/11
20	58/M	2/9	Back	RT	CR	—	6/9	—	6/9
21	66/F	8/9	Head, trunk, and limbs	Oral corticosteroids	PR	—	—	—	1/2
22	60/M	0/11	Trunk and limbs	IFN	CR	—	1/2	—	1/2
23	37/F	0/10	Back	RT	CR	—	0/8	—	0/8
24	59/M	1/2	Head	RT	CR	—	3/2	—	3/2
25	70/F	2/7	Left arm	RT	CR	—	1/7	—	1/7
26	35/M	0/7	Trunk	RT	CR	3 (2)	0/11	RT	3/11
27	77/F	1/6	Head	RT	CR	1 (1)	2/8	RT	6/10
28	51/M	2/9	Left flank	RT	CR	—	4/2	—	4/2
29	63/F	1/10	Back	RT	CR	1 (1)	0/6	RT	3/11
30	49/M	0/9	Back	Surgery	CR	—	1/8	—	1/8
31	30/F	2/2	Right buttock and left arm	Surgery + RT	CR	2 (2)	2/0	RT	2/6
32	66/M	2/9	Back	Surgery + RT	CR	—	3/7	—	3/7
33	58/M	1/6	Trunk	CT	CR	1 (1)†	0/9	Surgery + CT	3/11
34	62/M	1/4	Back	Surgery	PR	—	—	—	1/2
35	27/M	2/2	Upper limbs	RT	CR	—	6/5	—	6/5
36	65/M	0/9	Back	RT	CR	—	1/4	—	1/4
37	80/M	0/9	Trunk and limbs	CT	CR	—	1/2	—	1/2*
38	61/M	1/8	Head	RT	CR	—	1/4	—	1/4
39	74/F	0/8	Head	RT	CR	—	0/6	—	0/6
40	71/M	0/8	Trunk	RT	CR	—	6/3	—	6/3
41	58/F	1/1	Trunk	Surgery	CR	—	1/2	—	1/2
42	42/F	0/6	Back	RT	CR	1 (1)	0/8	CT	2/2
43	62/M	1/7	Head	RT	CR	—	1/8	—	1/8
44	57/M	0/9	Upper limbs	RT	CR	—	6/3	—	6/3
45	51/M	2/3	Right shoulder	RT	CR	—	1/2	—	1/2
46	39/M	0/8	Back	RT	CR	—	1/8	—	1/8
47	58/M	1/8	Back	RT	CR	—	2/3	—	2/3
48	28/F	2/4	Head and neck	RT	CR	—	2/3	—	2/3
49	88/F	1/8	Head	RT	CR	—	3/2	—	3/2
50	71/M	1/10	Left leg	Surgery	CR	5 (4)	0/6	RT	6/3
51	39/M	0/7	Head	RT	CR	1 (1)	4/8	RT	6/0
52	22/F	0/5	Right forearm	RT	CR	—	5/1	—	5/1
53	24/F	0/9	Trunk and limbs	IFN	PR	—	—	—	1/2
54	52/M	2/3	Head	RT	CR	—	1/8	—	1/8
55	75/F	1/7	Trunk	RT	CR	—	1/8	—	1/8
56	66/M	1/6	Head	RT	CR	1 (0)	0/11	RT	2/2
57	46/F	0/8	Trunk	RT	CR	—	7/8	—	7/8
58	29/M	0/11	Head, back, and lower limbs	CT	CR	—	6/4	—	6/4
59	44/F	1/2	Back	RT	CR	—	2/3	—	2/3
60	60/M	2/7	Back	CT	CR	1 (1)	0/10	RT	4/8

TABLE 2. (Continued)

Patient	Age (yr)/sex	Past history (yr/mo)	Site at presentation	Initial therapy	Response to treatment	No. of relapses (biopsied)	Disease-free interval (yr/mo)	Treatment of relapses	Survival from diagnosis (yr/mo)
61	48/M	1/6	Left flank	RT	CR	—	8/4	—	8/4
62	52/M	0/6	Trunk	RT	CR	—	0/9	—	0/9
63	78/F	0/9	Lower limbs	RT + CT	CR	1 (1)	0/5	RT + CT	0/8
64	48/M	1/1	Head	Surgery	CR	—	0/7	—	0/7
65	62/F	1/8	Back	Surgery	CR	—	0/6	—	0/6
66§	32/F	1/6	Left arm	Surgery	CR	—	—	—	—
67§	35/M	3/2	Back	RT	CR	—	—	—	—
68	32/M	0/9	Back	RT	CR	—	—	—	—
69	61/F	1/3	Head	RT	CR	—	—	—	—
70	57/M	2/1	Back	RT	CR	—	—	—	—
71	64/F	1/8	Back	RT	CR	—	—	—	—
72	70/F	0/8	Back	RT	CR	—	—	—	—
73	48/M	1/6	Back	RT	CR	—	—	—	—
74	58/F	0/7	Left arm	RT	CR	—	—	—	—
75	68/F	1/3	Back	RT	CR	—	—	—	—
76	31/M	0/7	Back	RT	CR	—	—	—	—
77	56/M	1/8	Head	RT	CR	—	—	—	—
78	44/M	1/3	Right arm	Surgery	PR	—	—	—	—
79	48/M	0/10	Head	RT	CR	—	—	—	—
80	52/F	1/3	Back	RT	CR	—	—	—	—
81	38/M	1/5	Back	RT	CR	—	—	—	—
82	41/F	1/2	Head and neck	CT	CR	—	—	—	—
83	67/M	0/9	Back	RT	CR	—	—	—	—

RT: local orthovolt irradiation, 6 to 8 Gy a week were given in two fractions, up to a total of 40 Gy, and irradiation fields were 20 × 20 cm, with at least 3-cm wide margins; CT: chemotherapy courses, cyclophosphamide, vincristine, prednisone (CVP)<sup>18</sup> or CVP-like + bleomycin<sup>19</sup>; IFN: recombinant interferon α-2b (Intron-A, Schering Co., Kenilworth, NJ); CR: complete remission; PR: partial remission.

\* Dead of unrelated causes.

† Nodal involvement.

‡ Dead of disease.

§ The patient had just finished initial treatment.

|| Lost to follow-up.

renal failure, was the only one of the current series who died of the disease. Three additional patients died of unrelated causes in the absence of any detectable sign of active disease.

### Histologic Features

The following parameters were investigated: histoarchitectural pattern of the infiltrate (this was referred to as nodular [patchy], diffuse, or mixed [nodular + diffuse] according to a simplified classification<sup>11,16</sup> that we derived from that of Evans *et al.*<sup>3</sup>); topography and depth of invasion of the infiltrate, and its amount; cellular composition of the neoplastic infiltrate and its histologic subtype (CBCL were classified according to the Working Formulation for Clinical Usage<sup>20</sup> following the criteria of Nathwani<sup>21</sup>); and amount and composition of the non-neoplastic cellular infiltrate.

These data were recorded for each specimen and then matched with age and growth rate of lesions and their immunologic profile (a synthesis of the clinicopathologic correlations is reported below). Lesions were categorized according to their age as follows: those younger than 3 months were recorded as young lesions; those older than 12 months as old lesions; and those aging between 3 and

12 months as intermediate-aged lesions. Conversely, we used the terms early and late to refer to the growth rate of lesions. Specifically, early lesions were represented by small, long-standing and slowly grown papules, plaques or nodules, being either young, intermediate-aged, or old; late lesions were represented by rapidly grown (*i.e.*, lesions that doubled their size in less than 1 month) nodules or tumors, irrespective of their age.

The nodular histoarchitectural pattern was characteristic of young lesions (39%) (Fig. 2), having been observed in specimens taken from intermediate-aged to old-aged lesions only very rarely (3%) (Fig. 3). The diffuse pattern was typical of old lesions (61%), having been observed in only a few specimens (9%) taken from lesions less than 12 months old. The mixed pattern was not characteristic of any specific age of lesion, having been almost the most frequently observed (Fig. 4).

Neoplastic follicles were never seen; conversely, in intermediate-aged to old-aged, slowly grown lesions, we often found variable numbers of reactive lymphoid follicles containing irregularly shaped and randomly situated germinal centers, lacking the typical zonal architecture. In some cases, features reminiscent of acquired immune deficiency syndrome (AIDS)-related changes in the lymph node were seen; namely, invaginations of mantle lym-

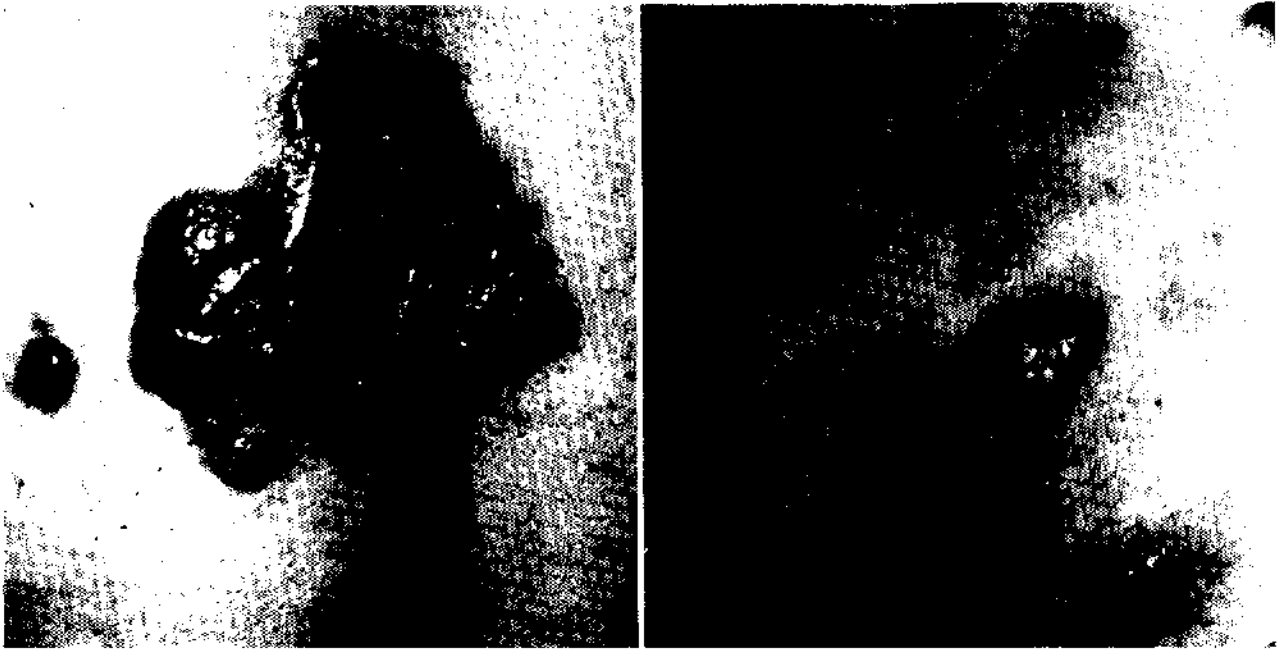


FIG. 1. Back of a male patient. Large tumors and plaques with a shiny mammillated surface are surrounded by figurate slightly infiltrated plaque-like or papular lesions and erythematous patches.



FIG. 2. Histoarchitectural nodular pattern of the infiltrate in a young (1-month-old) early lesion. Small roundish lymphoid aggregates mainly surround blood vessels, with a preferential involvement of the upper-mid reticular dermis (H & E, original magnification  $\times 30$ ).

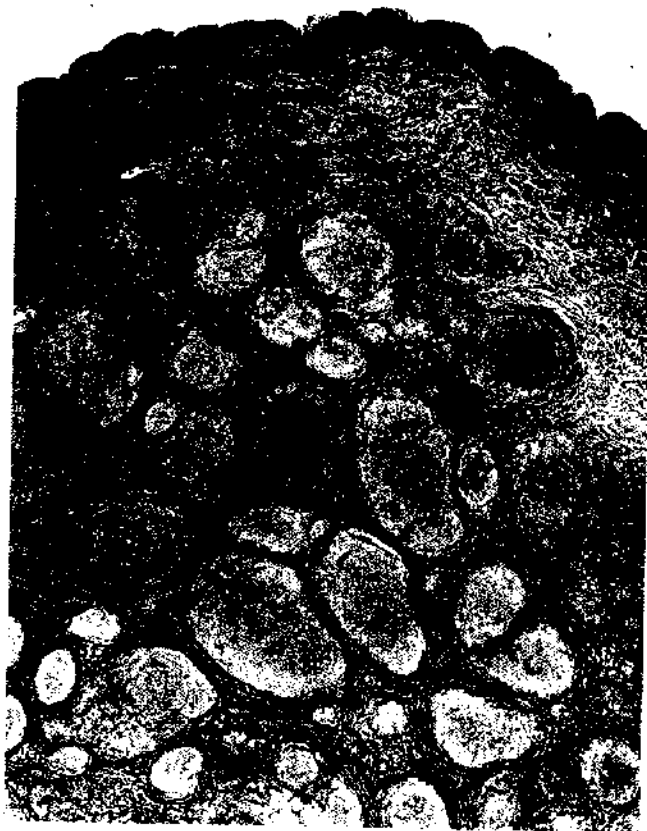

FIG. 3. Nodular pattern in a 2-year-old slowly grown lesion. Roundish cell aggregates are juxtaposed through the dermis and the subcutis, with a condensation of collagen bundles at the edges of lymphomatous nodules (H & E, original magnification  $\times 32$ )

phocytes into germinal centers with disruption of the architecture of these centers (follicle lysis) and distinctive clustering of large follicular center cells (Fig. 5).

Regarding the topography of the lymphoid infiltrate, the papillary dermis was always spared and a distinct Grenz-zone resulted (Figs. 2-4). A certain correlation was found among the amount of infiltrate, its deepest extension, and age and growth rate of lesions. In young early lesions, the infiltrate was inconspicuous and limited to the superficial portion of the reticular dermis (Fig. 2). Conversely, in intermediate-aged to old-aged and late lesions (Figs. 3 and 4), a deeper involvement was the rule, and in the majority of old and late lesions the dermis and subcutis were infiltrated by neoplastic cells.

The cellular composition of lymphoid infiltrates was highly variable, and neoplastic cells showed a range of appearances reminiscent of the whole spectrum of follicular/parafollicular cells.<sup>22-25</sup> Likewise, the relative quantity of each cell type was highly variable in different specimens from the same patient and different areas of the same specimen. This variability not only hampered an un-

equivocal categorization of the disease in the single patient, but often made a categorization of the single lesion quite difficult too; however, three prototypical patterns could be identified.

In small cleaved cell (SCC) lymphoma, the predominant cell population ( $\geq 75\%$ ) was intermediate-sized, and showed a relatively uniform appearance (Fig. 6). They had an oval or, more frequently, an indented nucleus with sometimes coarse, sometimes clear chromatin; nucleoli were inconspicuous. The cell cytoplasm was moderately abundant and pale-staining, and cell margins were quite often well defined. In large cell (LC) lymphoma (large cells  $\geq 50\%$ ), a conspicuous morphologic variability was found. The cell morphology was that of blast cells with abundant clear to eosinophilic cytoplasm, and a nucleus often having marked indentations and folds and slightly to moderately hypertrophic nucleoli (Fig. 7). Admixture with intermediate-sized cells was variable. In mixed small and large cell (MC) lymphoma, the entire range of morphologic aspects evidenced in SCC and LC lymphomas were present.

In SCC and MC lymphomas, variable numbers of cells with plasmacytic differentiation were often observed and, in some sections, there appeared to be a morphologic continuum between plasmacytic and neoplastic cells.

SCC lymphoma was by far the least frequently observed subtype (5%), and found exclusively in young early lesions, followed in frequency by MC (41%) and LC (54%) lymphoma. The cytomorphologic categories showed a certain correlation with age and growth rate of lesions. In young lesions, it was distinctive to find a SCC lymphoma (19%), even though a MC lymphoma represented the most frequent occurrence (79%). In intermediate-aged and old-aged lesions a predominance of LC lymphomas was observed (54% and 82%, respectively). Finally, in rapidly grown lesions, a LC lymphoma was almost always found (96%).

Neoplastic cells sometimes presented a skin appendage epidermotropism. The lymphocyte-appendage association was typically observed in the ductal portion of eccrine sweat glands and the pilosebaceous units (Fig. 8).

Reactive cellular infiltrate was variable; it was less conspicuous in old lesions in comparison with young ones, and in rapidly enlarged lesions in comparison to slowly grown ones.

All of the above-mentioned histomorphologic features failed to present any significant correlation with disease-free period and recurrence rate. Relapses presented histologic features indistinguishable from those of primary lesions.

The lymph node architecture of involved nodes was almost completely effaced. Cytologically, neoplastic cell proliferation was always constituted of large, blast-like



FIG. 4. The infiltrating cells show a composite (mixed) pattern of growth in this 1-year-old rapidly grown lesion. The collagen of upper-mid dermis is permeated by a cellular infiltrate which is rather uniformly dense, whereas discrete periadnexal and perivascular circular compartmentalizations of the infiltrating cells predominate in the lower dermis (H & E,  $\times 23$ ).



cells similar to those observed in cutaneous specimens of the same two patients.

The blood smear and bone marrow of the patient who died of the disease evidenced the presence of large, deeply cleaved cells similar to those observed in the skin and lymph nodes of the same patient.

#### *Submicroscopic Features*

Tumor cells (Fig. 9) had an irregular cell contour, sometimes with short processes, and more frequently with highly villous and intertwined cell membranes; due to this they were in contact with other neoplastic cells and dendritic reticulum cells (DRC). Nuclei were sometimes roundish, but more often grooved, convoluted or multilobated, with a moderate to slight quantity of marginated heterochromatin. Cytoplasm was always abundant, and organelles were often polarized toward the nuclear grooves and folds.

#### *Immunopathologic Findings*

CD19+, CD20+, CD22+, CD28+, HLA-DR+, CD10-, CD5-, MB2+, CD74+/-, CDw75+/-, MT2+/-, SIg+monoclonal/- neoplastic B-cells were

found admixed with variable numbers of DRC-1+, CD35+, CD21+/-, CD14- DRC. A kappa or lambda light chain monoclonal restriction was found in 63% and 18% of specimens, respectively. In 19% of specimens, infiltrating B-cells were SIg-. Variable numbers of reactive T-cells and CD1a+ dendritic cells were found, with a CD4/CD8 ratio varying from 1:1 to 1:3.

Three prototypical immunoarchitectural patterns were identified: (1) typical of young, early lesions; (2) characteristic of intermediate-aged to old-aged, slowly grown lesions; and (3) typical of late lesions. In specimens with a pattern typical of young, early lesions, an evident clustering of B-cells and DRC, with the virtual absence of admixed T-cells, was present, and mainly located in the upper-mid reticular dermis. In these clusters, DRC were loosely arranged in ill-defined meshwork with blurred and radiating contours, and they skipped the nodular centers in a centrifugal fashion. In the remaining areas of cell proliferation, B-cells and T-cells and their accessory cells were intermingled, with an overwhelming preponderance of T-cells (most of which expressed CD25 antigen). Thus, the overall immunoarchitecture of these lesions resulted

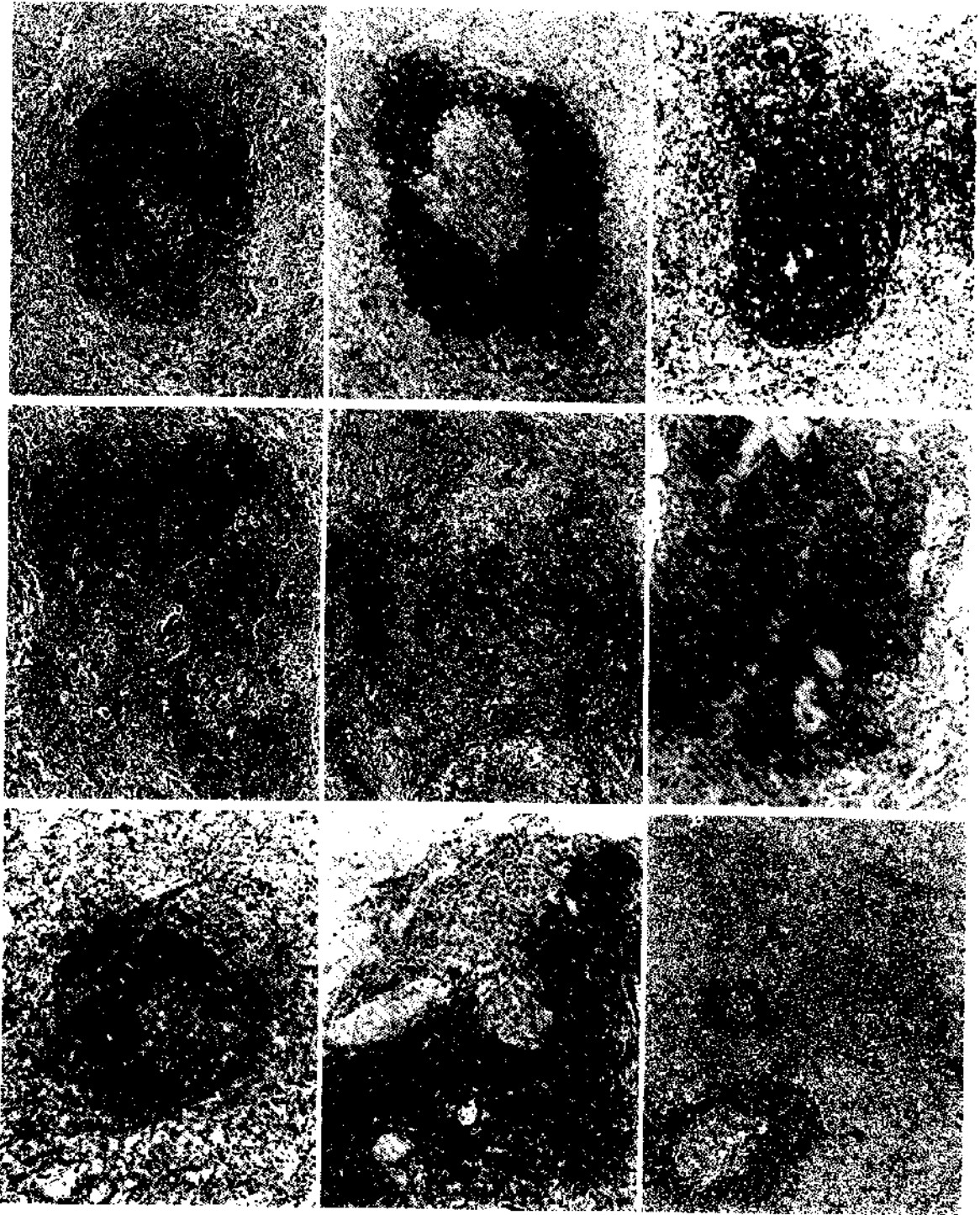


FIG. 5. Morphologic variability of reactive lymphoid follicles. Near rather well-formed follicles, with a central germinal center and a peripheral lymphocytic corona (top left; MT2 MoAb, top center), there are others without any histologically identifiable germinal center (MB2 MoAb, top right). Often there are present more than one germinal center cell-like collection per follicle (middle left) or aspects of dissociation of the germinal center by mantle-zone cells (follicle lysis) (middle center). Also seen are small collections of CDw75+ germinal center cells without well-defined mantle zones ("naked" follicular structures) (middle right). Frequently observed is the "bursting open" phenomenon, *i.e.*, follicular center cells melting with neoplastic cells due to the absence of interposed mantle zones (MB2 MoAb, bottom left); sometimes follicular center cells are partially surrounded by normal-looking collagen bundles (MT2 MoAb, bottom center). Neoplastic cells form broad confluent strands external to follicles in a fashion reminiscent of T-zone pattern (bottom right) (H & E, APAAP or immunoperoxidase stains on paraffin sections; original magnification  $\times 43$ ,  $\times 61$ ,  $\times 76$ ,  $\times 67$ ,  $\times 58$ ,  $\times 168$ ,  $\times 108$ ,  $\times 88$ ,  $\times 62$ , respectively, from top left to bottom right).




FIG. 6. SCC lymphoma. Medium-sized neoplastic cells resemble small centrocytes, intermediate lymphocytes, centrocyte-like or monocytoid cells, and have moderately abundant clear cytoplasm and a bland oval or indented nucleus (H & E, original magnification  $\times 156$ ,  $\times 717$ ).

in a rather distinct compartmentalization of B-cells and T-cells (Fig. 10). In most specimens (69%) showing this pattern, the clustered B-cells were SIgD+, in 7% were SIgM+, and in 14% coexpressed SIgM and SIgD, with heavy SIg- in the remaining cases (10%). Cells expressing CD71 and Ki-67 antigens were few and exclusively found in B-cell clusters.

In the second type of pattern, numerous reactive T-cells and CD1a+ dendritic cells were quite uniformly intermingled with B-cells and DRC, without a distinct compartmentalization. In 61% of specimens, a heavy SIg+ was found (D = 31%, G = 12%, M = 8%, D + M = 10%).

Cells expressing CD71 and Ki-67 antigens were few and sparse.

In the third pattern, typical of late lesions, B-cells were always the large majority of infiltrating cells and they were more often SIg- (57% of specimens). Dendritic reticulum cells were occasionally observed. Reactive T-cells were always few and sparse. The large majority of infiltrating cells expressed CD71 and Ki-67 antigens.

In intermediate-aged to old-aged, slowly grown lesions, the proliferation was dotted with polyclonal follicles, mainly located in the mid-lower dermis, showing a rather typical compartmentalization even though more or less evident signs of aberrancy were often found. In fact, follicular structures were incompletely surrounded by a thin rim of CD4+ and CD8+ T-cells; in the mantle-zone, DRC were more often missing. In some specimens, multiple follicle center-like clusters of SIgM+ or SIgG+ polyclonal B-cells and CD14+ DRC were found not only inside well-defined SIgD+ mantle zones, but even at their periphery, or without any evident outer SIgD+ polyclonal area or rim of MT2+ cells.

Concerning plasmacytic cells, a light chain monoclonal restriction was documented when a morphologic continuum between them and neoplastic cells was histologically evident.

No significant differences in immunopathologic profile, as documented in frozen and embedded tissue, were evidenced between primary and relapsing lesions. Concerning SIg, in three patients a dichotomy was evidenced between early and late lesions: although the former showed SIg monoclonality, the latter failed to show any immunostaining.

## Discussion

Cutaneous B-cell lymphoma represents, according to the current study, a peculiar and homogeneous entity concerning clinical behavior, response to treatment, and overall prognosis. Despite frequent relapses, the disorder tends to remain localized to a rather limited area of the skin. This tendency to relapse is not related to an increase of malignancy; in fact, relapsing skin lesions show clinical, histologic, and immunologic features indistinguishable from those of primary lesions. Extracutaneous spread is exceedingly rare. In fact, it took place in two patients of the current series, and only in one instance was it the expression of a progression and systemic spread of the disease with a consequent fatal outcome. We have to stress, however, that the immunologic impairment this latter patient presented, presumably due to chronic renal failure, may have greatly accounted for this severe evolution; in this light, the uncommon, rapidly fatal outcome

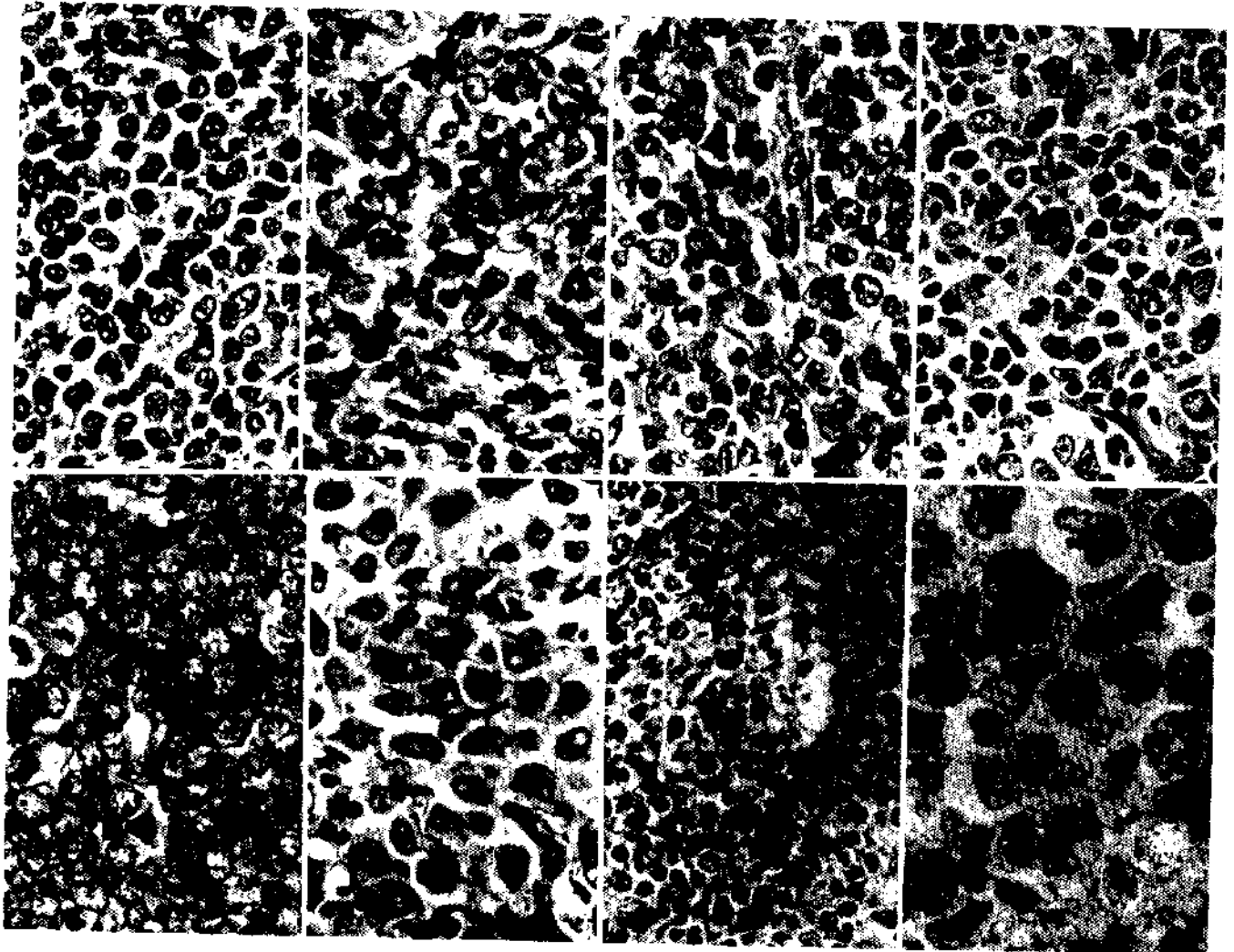


FIG. 7. LCC lymphoma. Range of appearances. Neoplastic cells resemble large anaplastic centrocytes, centrocytoid cells, multinucleated cells, centroblasts, and immunoblasts. The marked pleomorphism of tumor cells is evident, sometimes with the presence of bizarre multinucleated cells reminiscent of Reed-Sternberg cells (bottom right center) (H & E and semi-thin section, original magnification  $\times 498$ ).

might be due to an impaired immune response more than to an actual enhancement of malignancy of the tumor.

The data of the current investigation parallel those of previous reports.<sup>12-14,16,26,27</sup> Until now, only 11 of the 133 patients with adequate follow-up data reported here and in the more detailed and consistent articles dealing with CBCL<sup>13,16,26,27</sup> died; furthermore, seven of them died of unrelated causes without any evidence of extracutaneous spread of the disease.

The low malignant potential presented by CBCL is further supported by the strikingly good response to local orthovolt radiation therapy, which is the choice treatment either at presentation or upon relapse.<sup>13,14,16,26</sup> Only when an involvement of noncontiguous anatomic sites or an extracutaneous spread of the disease takes place is it advisable, in our opinion<sup>14,16</sup> and in that of others,<sup>13,26</sup> to

associate polychemotherapy courses or to perform chemotherapy alone.

Correct identification and proper differentiation of CBCL from inflammatory dermatoses and reactive lymphoid hyperplasia still represent one of the most serious and vexing problems. When the lymphoproliferative disorder shows a follicular-like (nodular) pattern or reactive lymphoid follicles are present, this becomes a formidable diagnostic challenge to surgical pathologists and dermatopathologists, particularly in light of some prior studies that have implied that virtually all cutaneous follicular lymphoid infiltrates represent reactive processes.<sup>1,3,7</sup>

Diagnostic features are linked to the type of lesion examined. Old and late lesions present very limited diagnostic problems. Hardly any other diagnosis is possible due to the frank atypism of cells, the diffusely infiltrating

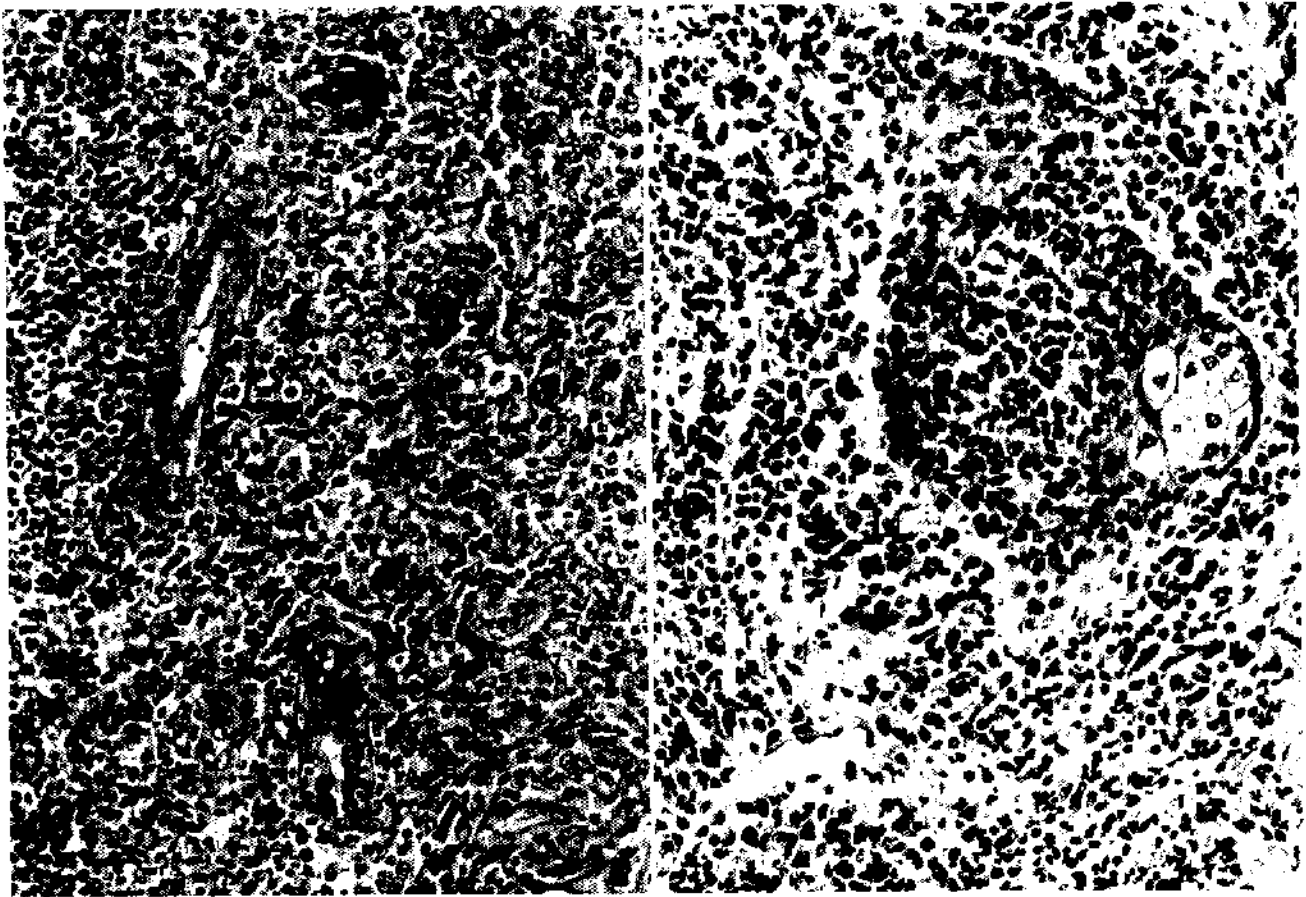


FIG. 8. Skin appendage epidermotropism. Neoplastic cells infiltrate and almost completely overrun the ductal portion of an eccrine sweat gland (left). The pilosebaceous units are involved at the sebaceous gland/hair follicle isthmus level (right) (H & E,  $\times 232$ ).

pattern with a substitutive fashion, and the constant finding of monoclonal light chain restriction or, more often, SIg- staining.

Conversely, early lesions often bring up major problems in differential diagnosis with respect to inflammatory dermatoses and pseudolymphomas. Among early lesions, young lesions at times closely resemble perivascular dermatitis or lymphocytic infiltration of the skin (Jessner-Kanof type). The rather large size and irregular contour of lymphoid nodules contemporaneously surrounding several channels of the superficial vascular plexus; the presence of a downward extension of infiltrating cells in the adventitial dermis around cutaneous appendages and nerves, especially when involvement of the deep plexus is lacking; the infiltration of arrectores pilorum muscles and/or of perineural spaces or nerves; and the presence of evident numbers of plasmacytic cells suggest an early lymphomatous lesion, which must be confirmed by immunophenotyping with the finding of a light chain monoclonal restriction. The constant prevalence of reactive CD8+ T-cells may be of some additional help in

differentiating these early neoplastic lesions from reactive lymphoproliferative disorders, in that in the latter a CD4+ T-cell prevalence has been more frequently documented.<sup>28-30</sup>

Intermediate-aged lesions are quite similar to the wide spectrum of B-cell pseudolymphomas *sensu strictu*.<sup>1,6,7,31,32</sup> The morphoarchitectural atypism presented by reactive follicles, along with the presence of "bursting open" follicular structures, naked germinal centers, and other remnants of lymphoid follicles, and the presence of an interfollicular lymphoid infiltrate with atypical cells blended with variable numbers of plasmacytic cells represent major clues in hypothesizing a neoplastic process. The documentation of monotypic Ig in a consistent number of B-cells, along with the immunarchitectural atypism of reactive follicular structures, make the diagnosis of lymphoma conclusive.

Pseudo-pseudolymphomas<sup>31</sup> (*i.e.*, those developing from insect bites, tattoos, *etc.*), conversely show more consistent differences, which can make a differential diagnosis possible even on morphologic grounds alone. Dif-

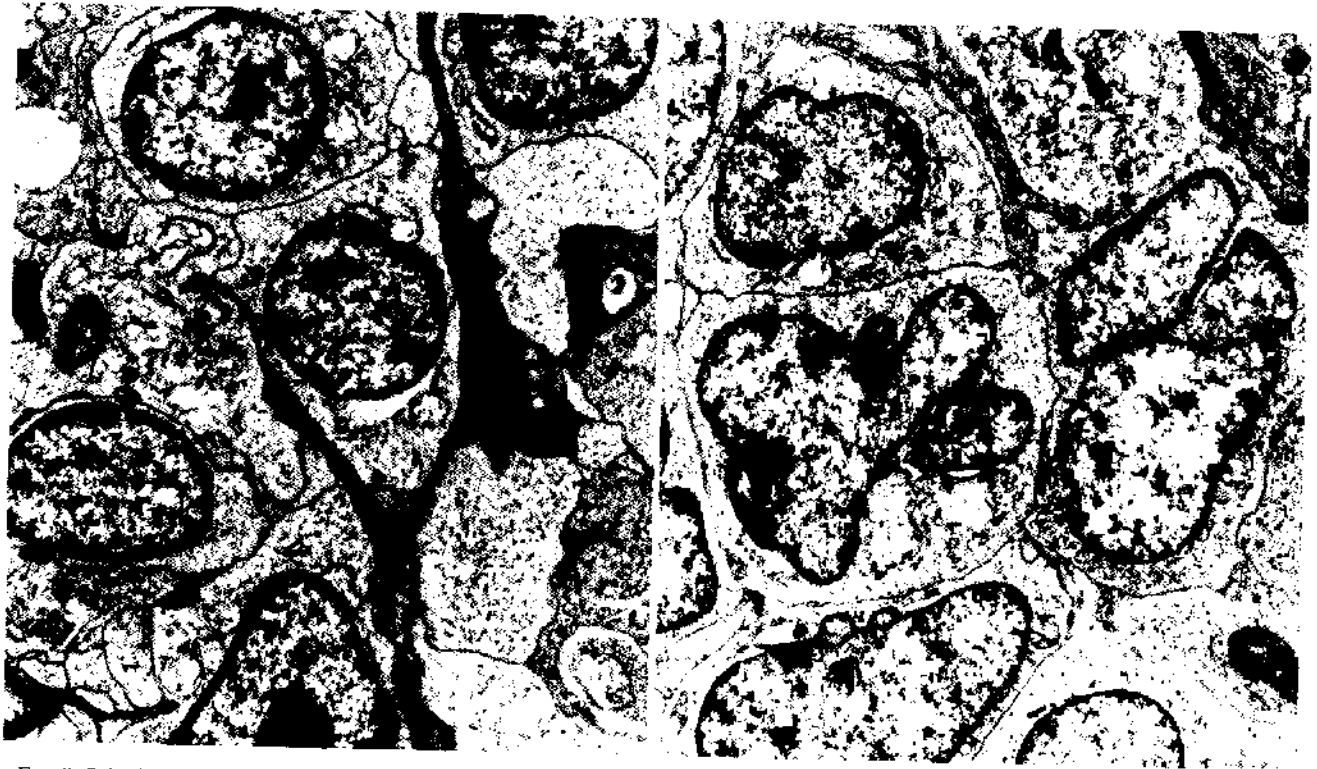

FIG. 9. Submicroscopically, neoplastic cells, despite the evident morphologic variability, show some common features, specifically, more or less irregular cell contour and abundant cytoplasm with large mitochondria, moderate to large amounts of ribosomes, some vesicles of smooth endoplasmic reticulum, and a few strands of rough endoplasmic reticulum. Less frequently, a few dense-core primary lysosomes, a pronounced Golgi body, and small lipid droplets are present ( $\times 5720$ ).

ferent from *sensu strictu* pseudolymphomas, in these instances reactive follicular structures show no signs of morphoarchitectural aberrancy; the epidermis is generally hyperplastic, with striking acanthosis and papillomatosis;

and the dermis shows a conspicuous neoangiogenesis involving its whole thickness, the presence of ectatic blood vessels, and a mild to moderate fibrosis. Eosinophils may often be prominent in pseudolymphomatous processes,



FIG. 10. Serial sections of a 2-month-old early lesion stained for CD22 (left), DRC-1 (middle), and CD3 (right). The distinct compartmentalization of B- and T-cells and the typical clustering of B-cells and DRC with the virtual absence of admixed T-cells are clearly evident. Notice that DRC are mainly located at the periphery of the B-cell nodule in a centrifugal fashion (APAAP stain on frozen sections, original magnification  $\times 136$ ).

similarly to giant cells, but sometimes they are present in lymphomatous lesions as well.

Using immunohistochemical study, a distinct compartmentalization of B-cells and T-cells and their accessory cells is always evident, and B-cells are polyclonal with the expected predominance of kappa-bearing over lambda-bearing cells. This true polyclonality has to be distinguished, however, from the pseudopolyclonality that is often found in lymphomatous lesions that have reactive lymphoid follicles and admixed polyclonal plasmacytic cells (Fig. 11).

Unfortunately, even immunophenotyping may fail to identify lymphomatous processes in initial phases. In fact, clonal rearrangements of immunoglobulin genes were documented in cell subsets of some cases of cutaneous lymphoid hyperplasia, presenting true polyclonality ac-

ording to the above-mentioned criteria, which subsequently developed clinically overt lymphomas showing the very same immunoglobulin gene rearrangements.<sup>10</sup> These data support the concept that pseudolymphomas evolving into frank lymphomas are actually lymphomas from the very beginning; in these instances, the polyclonality of lesions is actually the polyclonality of the overwhelming reactive B-cell component accompanying neoplastic B-cells. Therefore, pseudolymphomas *sensu stricto* have to be very cautiously considered reactive-hyperplastic processes unless clonal rearrangements of immunoglobulin genes are lacking.

Cutaneous B-cell lymphoma is currently classified heterogeneously as follicular center cell (FCC) lymphoma<sup>11-16,27</sup> and, to a lesser extent, as immunocytoma and immunoblastic lymphoma.<sup>4,33</sup> This interpretation is

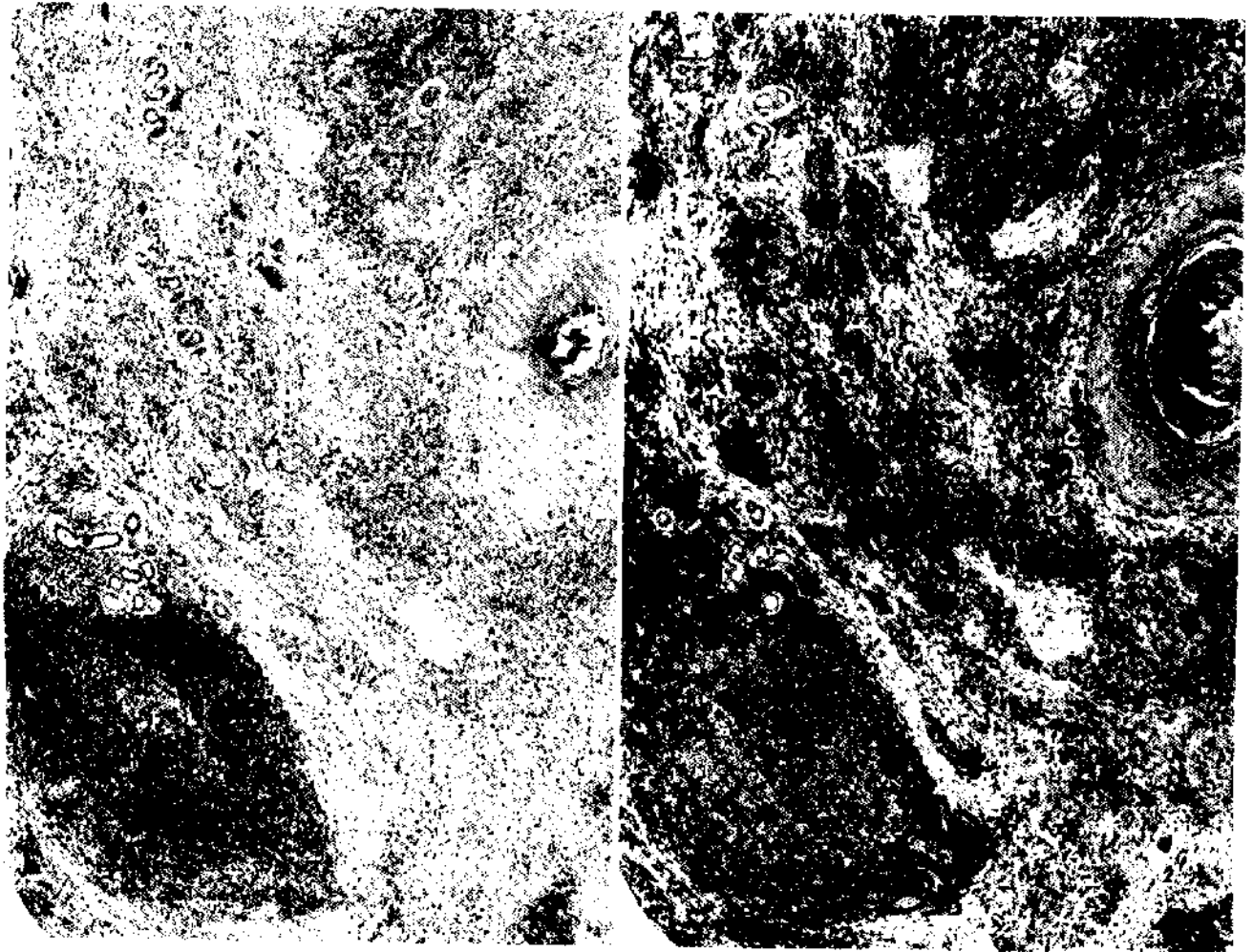


FIG. 11. Serial sections of an 11-month-old slowly grown lesion stained for kappa (left) and lambda light chain (right). The reactive lymphoid follicle (lower-left side of the picture) is polyclonal with the expected predominance of kappa-bearing over lambda-bearing cells; conversely, the neoplastic infiltrate shows a restricted expression of lambda light chain with a few admixed polyclonal (kappa-expressing) plasmacytic cells (APAAP stain on paraffin sections,  $\times 58$ ).

acceptable from a strictly histomorphologic point of view, even though the presence of composite aspects in a single lesion and the highly evident variability among different lesions of the same patient quite often hamper a reliable and effective subtyping according to current classifications of non-Hodgkin's lymphomas.<sup>20-24</sup> In addition, the lack of clinical relevance of morphologic categories—which do not correlate with recurrence rate, response to treatment, stage of disease, subsequent evidence of dissemination, or survival of patients—further proves such classifications and histologic subtypes to be unsuitable for CBCL, and favors a unitary concept and a single nature for CBCL.

Immunogenotypic features give support to this holistic view, and allow some speculations about the nature of CBCL. Concerning the immunophenotype of neoplastic B-cells, absent expression of CD5 and CD10 antigens associated with positive staining for anti-Leu-8 monoclonal antibody (MoAb) make an FCC origin questionable and militate in favor of the mantle-zone nature of the disease,<sup>17,34-36</sup> even though the recently reported absent expression of CD1c antigen in a few cases of CBCL<sup>15</sup> may raise some doubts about such an origin.

Additional support for this interpretation is given by the immunophenotype and architectural distribution of nonlymphoid accessory cells. In fact, the presence of DRC, long considered pathognomonic of FCC lymphomas, is not exclusive to them, different distribution patterns and subsets of DRC having been found in relation to follicular centers and mantle zones or their derived lymphomas.<sup>37,38</sup> In particular, the former is characterized by well-defined and sharply outlined nodular spherical meshwork of CD14+ DRC; whereas in the latter, CD14- DRC are loosely arranged with a distinctive centrifugal immunostaining pattern.<sup>37,39-41</sup> In our cases, both DRC patterns and subsets were identified; but, whereas the former (the FCC-related) was exclusively found in intermediate-aged to old-aged lesions in relation to polytypic lymphoid follicles, the latter (*i.e.*, the mantle-zone-related) was evidenced in young early lesions in association with clusters of monotypic, proliferating, SIgD+, Leu-8+, CD10-, CD5- intermediate-sized (mantle-zone type) neoplastic cells. Finally, genotypic studies<sup>10,15</sup> failed to show the bcl-2 (B-cell leukemia/lymphoma) gene rearrangements representing t(14:18) chromosomal translocation, recently documented in most FCC lymphomas.<sup>42,43</sup>

Further data support the speculation of the peculiar and single nature of CBCL. (1) Progressive reduction in amount of DRC with increasing age and growth rate of lesions is indicative of progressive dedifferentiation of neoplastic B-cells, with consequent acquisition of progressive autonomy that requires a less and less specialized microenvironment.<sup>41</sup> This neoplastic enhancement is well

known in B-cell and in T-cell node-based lymphomas as well as in cutaneous T-cell lymphomas, and parallels an increasing malignancy, namely widespread diffusion and rapidly fatal outcome.<sup>44-47</sup> The neoplastic enhancement of CBCL, conversely, is accompanied only by a limited increase in malignancy (quick development of large tumorous lesions, tumultuous proliferative rate). (2) A lack of immunostaining for SIg (a sign of increasing neoplastic malignancy in node large cell lymphomas<sup>48,49</sup>) was not found to be related to an impaired prognosis.<sup>12-14,16</sup> (3) The constant prevalence of CD8+ reactive T-cells in CBCL differs from that found in node lymphomas, in which an inversion of the CD4/CD8 ratio of reactive T-cells takes place when passing from follicular to diffuse B-cell lymphomas,<sup>44</sup> a CD8 prevalence being more frequently linked to a progressive disease.<sup>47</sup> A teleologic explanation, however, might be seen in the prevalence of CD8+ T-cells from the very beginning of the disease, especially considering the activated state (expression of CD25 antigen) of most of them, in that they may contribute to limiting the neoplastic growth of B-cells due to their suppressor/cytotoxic function.<sup>50,51</sup>

The existence of CBCL raises a major question, namely how its onset is explainable in light of the current knowledge on skin immune system (SIS).<sup>52,53</sup> Currently, no information is available regarding the very existence of a B-cell arm of SIS in physiologic conditions, and the only pertinent data concern the demonstration that sweat and sebaceous glands synthesize the secretory component of dimeric IgA in humans.<sup>54</sup> This very limited information does not allow any consistent hypothesis concerning B-cell homing in the skin. However, considering that CBCL and B-cell pseudolymphoma exist, the only speculation possible is that the skin and draining lymph nodes form an integrated system that allows the transduction of environmental stimuli directed toward the skin (the cutaneous appendages?) to a lymphoproliferative response in draining lymph nodes, with the subsequent specific homing back to the skin of the immunologically driven B-cells, a cutaneous equivalent of the lymph node B-cell compartment (the B-cell arm of SIS) becoming evident only when antigenic persistence and/or chronic antigenic stimulation take place. In this view, CBCL might represent the neoplastic amplification of such a process, and has been considered skin-associated lymphoid tissue (SALT)-derived lymphoma of the B-cell type.<sup>16</sup>

Currently, there is no definite explanation available for the morphoimmunologic signs of aberrance presented by reactive, polyclonal lymphoid follicles found in intermediate-aged to old-aged, slowly grown lesions. The only possible speculation derives from similarities with the changes observed in lymph nodes of AIDS patients. In this light, the morphoimmunologic aberrance of lymphoid



follicles might be linked to an impairment in immune response, which, due to the absence of any detectable sign of systemic immunodeficiency in CBCL patients, could possibly be limited to SIS.

The favorable clinical course of CBCL still begs for an explanation. A possible key to speculation may be furnished by the striking similarities to mucosa-associated lymphoid tissue (MALT) lymphomas.<sup>16</sup> Because the very good overall prognosis of these latter is considered to be linked to a specific cell type with peculiar homing features more than to an organ-related behavior,<sup>23,55-57</sup> the explanation for the peculiarities of CBCL may be due to the fact that constituting cells retain a specific cutaneous homing pattern and have a very low tendency to spread, even when neoplastic enhancement takes place.

## REFERENCES

- Mach KW, Wilgram GF. Characteristic histopathology of cutaneous lymphoplasia (lymphocytoma). *Arch Dermatol* 1966; 94:26-32.
- Clark WH, Mihm MC Jr, Reed RJ et al. The lymphocytic infiltrates of the skin. *Hum Pathol* 1974; 5:25-43.
- Evans HL, Winkelmann RK, Banks PM. Differential diagnosis of malignant and benign cutaneous lymphoid infiltrates. *Cancer* 1979; 44: 699-717.
- Holbert JM Jr, Chesney T McC. Malignant lymphoma of the skin: A review of recent advances in diagnosis and classification. *J Cutan Pathol* 1982; 9:133-168.
- Burke J. Malignant lymphomas of the skin: Their differentiation from lymphoid and non-lymphoid cutaneous infiltrates that simulate lymphoma. *Semin Diagn Pathol* 1985; 2:169-182.
- Geerts M-L, Kaiserling E. A morphologic study of lymphadenosis benigna cutis. *Dermatologica* 1985; 170:121-127.
- Winkelmann RK, Dabski K. Large cell lymphocytoma: Follow-up, immunopathology studies, and comparison to cutaneous follicular and Crosti lymphoma. *Arch Dermatol Res* 1987; 279:S81-S87.
- Knowles DM, Halper JP, Jakobiec FA. The immunologic characterization of 40 extranodal lymphoid infiltrates: Usefulness in distinguishing between benign pseudolymphoma and malignant lymphoma. *Cancer* 1982; 49:2321-2335.
- Wood GS, Burke JS, Horning S, Doggett RS, Levy R, Warnke RA. The immunologic and clinicopathologic heterogeneity of cutaneous lymphomas other than mycosis fungoides. *Blood* 1983; 62:464-472.
- Wood GS, Ngan B-Y, Tung R et al. Clonal rearrangements of immunoglobulin genes and progression to B cell lymphoma in cutaneous lymphoid hyperplasia. *Am J Pathol* 1989; 135:13-19.
- Santucci M, Pimpinelli N, Moretti S, Bondi R, Giannotti B. Primary cutaneous follicular center cell lymphoma of the back (Crosti's reticulohistiocytoma): Comparison between early and late lesions (Abstr 12). Presented at the 8th International Dermatopathology Colloquium, Barcelona, Spain, October 8-10, 1987.
- Willemze R, Meijer CJLM, Scheffer E et al. Diffuse large cell lymphomas of follicular center cell origin presenting in the skin. *Am J Pathol* 1987; 126:325-333.
- Berti E, Alessi E, Caputo R, Gianotti R, Delia D, Vezzani P. Reticulohistiocytoma of the dorsum. *J Am Acad Dermatol* 1988; 19: 259-272.
- Pimpinelli N, Santucci M, Bosi A et al. Primary cutaneous follicular center-cell lymphoma: A lymphoproliferative disease with favourable prognosis. *Clin Exp Dermatol* 1989; 14:12-19.
- Berti E, Gianotti R, Alessi E, Caputo R. Primary cutaneous follicular center cell lymphoma: Immunophenotypical and immunogenotypical aspects. In: van Vloten WA, Willemze R, Lange Vejlsgaard G, Thomsen K, volume eds. *Cutaneous Lymphoma: Current Problems in Dermatology*, vol. 19 (Hönigsmann H, series ed.). Basel: Karger, 1990; 196-202.
- Pimpinelli N, Santucci M, Carli P et al. Primary cutaneous follicular center cell lymphoma: Clinical and histological aspects. In: van Vloten WA, Willemze R, Lange Vejlsgaard G, Thomsen K, volume eds. *Cutaneous Lymphoma: Current Problems in Dermatology*, vol. 19 (Hönigsmann H, series ed.). Basel: Karger, 1990; 203-220.
- Knapp W, Dörken B, Rieber P, Schmidt RE, Stein H, Borne AEGK von dem. CD Antigens 1989. *Am J Pathol* 1989; 135:420-421.
- Norton L, Simon R. Tumor size, sensitivity to therapy and design of treatment schedules. *Cancer Treat Rep* 1977; 61:1307-1313.
- Rossi Ferrini P, Bellesi G, Bosi A. La chemioterapia dei linfomi non-Hodgkin. In: Cajozzo A, ed. *Le Malattie Linfoproliferative*. Palermo: Libreria Clemenza, 1978; 135-138.
- Non-Hodgkin's Lymphoma Pathologic Classification Project: National Cancer Institute sponsored study of classifications of non-Hodgkin's lymphomas. Summary and description of a Working Formulation for clinical usage. *Cancer* 1982; 49:2112-2135.
- Nathwani BN. Classifying non-Hodgkin's lymphoma. In: Berard CW, Dorfman RF, Kaufman N, eds. *Malignant Lymphomas*. Baltimore: Williams & Wilkins, 1987; 18-80.
- Lennert K. *Malignant Lymphomas Other Than Hodgkin's Disease: Histology, Cytology, Ultrastructure, Immunology*. Berlin: Springer-Verlag, 1978.
- Isaacson PG, Spencer J. Malignant lymphoma of mucosa-associated lymphoid tissue. *Histopathology* 1987; 11:445-462.
- Hui PK, Feller AC, Lennert K. High-grade non-Hodgkin's lymphoma of B-cell type: I. Histopathology. *Histopathology* 1988; 12:127-143.
- Sheibani K, Burke JS, Swartz WG, Nademanee A, Winberg CD. Monocytoid B-cell lymphoma: Clinicopathologic study of 21 cases of a unique type of low-grade lymphoma. *Cancer* 1988; 62:1531-1538.
- Willemze R, Meijer CJLM, Sentis HJ et al. Primary cutaneous large cell lymphomas of follicular center cell origin. *J Am Acad Dermatol* 1987; 16:518-526.
- Rijlaarsdam JU, Meijer CJLM, Willemze R. Lymphadenosis benigna cutis versus primary cutaneous B-cell lymphomas of follicular center cell origin. In: van Vloten WA, Willemze R, Lange Vejlsgaard G, Thomsen K, volume eds. *Cutaneous Lymphoma: Current Problems in Dermatology*, vol. 19 (Hönigsmann H, series ed.). Basel: Karger, 1990; 189-195.
- Ralfkiaer E, Lange Wanzin G, Mason DY, Stein H, Thomsen K. Characterization of benign cutaneous lymphocytic infiltrates by monoclonal antibodies. *Br J Dermatol* 1984; 111:635-645.
- Wirt DP, Grogan TM, Jolley CS et al. The immunoreactivity of cutaneous pseudolymphoma. *Hum Pathol* 1985; 6:492-510.
- Torné R, Roura M, Umbert P. Generalized cutaneous B-cell pseudolymphoma: Report of a case studied by immunohistochemistry. *Am J Dermatopathol* 1989; 11:544-548.
- Burg G, Braun-Falco O. *Cutaneous Lymphomas, Pseudolymphomas, and Related Disorders*. Berlin: Springer-Verlag, 1983; 415-463.
- Kerl H, Smolle J. Classification of cutaneous pseudolymphomas. In: van Vloten WA, Willemze R, Lange Vejlsgaard G, Thomsen K, volume eds. *Cutaneous Lymphoma: Current Problems in Dermatology*, vol. 19 (Hönigsmann H, series ed.). Basel: Karger, 1990; 167-175.
- Putte SCJ van der, Kreek EJ de, Go DMDS, Unnik JAM van. Primary cutaneous lymphoplasmacytoid lymphoma (immunocytoma). *Am J Dermatopathol* 1984; 6:15-24.
- Kansas GS, Wood GS, Engleman EG. Maturation and functional diversity of human B lymphocytes delineated with anti-Leu-8. *J Immunol* 1985; 134:3003-3006.
- Carbone A, Manconi R, Poletti A, Gloghini A, De Paoli P, Volpe R. Expression of Leu-8 surface antigen in B-cell lymphomas: Correlation with other B-cell markers. *J Pathol* 1988; 154:133-140.
- Poletti A, Manconi R, De Paoli P. Double labeling immunohistologic and flow cytometric analysis of human B cells with particular reference to Leu-8 expression. *Hum Pathol* 1988; 19:1001-1007.
- Carbone A, Poletti A, Manconi R, Gloghini A, Volpe R. Heterogeneous *in situ* immunophenotyping of follicular dendritic reticulum

- cells in malignant lymphomas of B-cell origin. *Cancer* 1987; 60:2919-2926.
38. Carbone A, Manconi R, Poletti A, Volpe R. Heterogeneous immunostaining patterns of follicular dendritic reticulum cells in human lymphoid tissue with selected antibodies reactive with different cell lineages. *Hum Pathol* 1988; 19:51-56.
39. Wood GS, Turner RR, Shiurba RA, Eng L, Warnke RA. Human dendritic cells and macrophages: *In situ* immunophenotypic definition of subsets that exhibit specific morphologic and microenvironmental characteristics. *Am J Pathol* 1985; 119:73-82.
40. Mori N, Kuniyuki O, Kojima M. DRC antigen expression in B-cell lymphomas. *Am J Clin Pathol* 1988; 89:488-492.
41. Scoazec J-Y, Berger F, Magaud J-P, Brochier J, Coiffier B, Bryon P-A. The dendritic reticulum cell pattern in B cell lymphomas of the small cleaved, mixed, and large cell types: An immunohistochemical study of 48 cases. *Hum Pathol* 1989; 20:124-131.
42. Weiss LM, Warnke RA, Sklar J, Cleary ML. Molecular analysis of the t(14;18) chromosomal translocation in malignant lymphomas. *N Engl J Med* 1987; 317:1185-1189.
43. Aisenberg AC, Wilkes BM, Jacobson. The bcl-2 gene is rearranged in many diffuse B-cell lymphomas. *Blood* 1988; 71:969-972.
44. Harris NL, Bhan AK. Distribution of T-cell subsets in follicular and diffuse lymphomas of B-cell type. *Am J Pathol* 1983; 113:172-180.
45. Gatringer C, Huber H, Radaszkiewicz T, Pfaller W, Braunsteiner H. Imbalance of helper and suppressor T lymphocytes in malignant non-Hodgkin's lymphomas: An *in situ* morphometric analysis. *Int J Cancer* 1984; 33:751-757.
46. Garcia CF, Lowder J, Meeker TC, Bindl J, Levy R, Warnke RA. Differences in "host infiltrates" among lymphoma patients treated with anti-idiotype antibodies: Correlation with treatment response. *J Immunol* 1985; 135:4252-4260.
47. Strickler JG, Copenhaver CM, Rojas VA, Horning SJ, Warnke RA. Comparison of "host cell infiltrates" in patients with follicular lymphoma with and without spontaneous regression. *Am J Clin Pathol* 1988; 90:257-261.
48. Picker LJ, Weiss LM, Medeiros LJ, Wood GS, Warnke RA. Immunophenotypic criteria for the diagnosis of non-Hodgkin's lymphoma. *Am J Pathol* 1987; 128:181-201.
49. Spier CM, Grogan TM, Lippman SM, Slymen DJ, Rybski JA, Miller TP. The aberrancy of immunophenotype and immunoglobulin status as indicators of prognosis in B cell diffuse large cell lymphoma. *Am J Pathol* 1988; 133:118-126.
50. Wortzel R, Urban J, Philipps C, Fitch F, Schreiber H. Independent immunological and immunorecessive tumor-specific antigens on a malignant tumor: Antigenic dissection with cytotoxic T-cell clones. *J Immunol* 1983; 130:2461-2466.
51. Wortzel R, Urban J, Schreiber H. Malignant growth in the normal host after variant selection *in vitro* with cytolytic T-cell lines. *Proc Natl Acad Sci USA* 1984; 81:2186-2190.
52. Strellein JW. Skin-associated lymphoid tissues (SALT): Origins and functions. *J Invest Dermatol* 1983; 80:12s-16s.
53. Bos JD, Kapsenberg ML. The skin immune system (SIS): Its cellular constituents and their interactions. *Immunol Today* 1986; 7:235-240.
54. Metzke D, Jurecka W, Gebhart W, Schmidt J, Mainitz M, Niebauer G. Immunohistochemical demonstration of immunoglobulin A in human sebaceous and sweat glands. *J Invest Dermatol* 1988; 91:13-17.
55. Addis BJ, Hyjek E, Isaacson PG. Primary pulmonary lymphoma: A reappraisal of its relationship to pseudolymphoma and lymphoid interstitial pneumonia. *Histopathology* 1988; 13:1-17.
56. Hyjek E, Smith WJ, Isaacson PG. Primary B-cell lymphoma of salivary glands and its relationship to myoepithelial sialadenitis. *Hum Pathol* 1988; 19:766-776.
57. Hyjek E, Isaacson PG. Primary B cell lymphoma of the thyroid and its relationship to Hashimoto's thyroiditis. *Hum Pathol* 1988; 19:1315-1326.