



UNIVERSITÀ  
DEGLI STUDI  
FIRENZE

FLORE

## Repository istituzionale dell'Università degli Studi di Firenze

### **Expression of vascular endothelial growth factor receptor types 1,2 and 3 in placenta from pregnancies complicated by hypertensive**

Questa è la Versione finale referata (Post print/Accepted manuscript) della seguente pubblicazione:

*Original Citation:*

Expression of vascular endothelial growth factor receptor types 1,2 and 3 in placenta from pregnancies complicated by hypertensive disorders / M. Marini; D. Vichi; A.Toscano; G.D Zappoli Thyron; E. Parretti; G. Mello; G. Gheri; A. Pacini; E. Sgambati. - In: REPRODUCTION FERTILITY AND DEVELOPMENT. - ISSN 1031-3613. - STAMPA. - 19:(2007), pp. 641-651. [10.1071/RD06131]

*Availability:*

This version is available at: 2158/255037 since: 2016-11-18T11:28:08Z

*Publisher:*

CSIRO Publishing:150 Oxford Street, Collingwood Victoria 3066 Australia:011 61 3 96627500, EMAIL:

*Published version:*

DOI: 10.1071/RD06131

*Terms of use:*

Open Access

La pubblicazione è resa disponibile sotto le norme e i termini della licenza di deposito, secondo quanto stabilito dalla Policy per l'accesso aperto dell'Università degli Studi di Firenze (<https://www.sba.unifi.it/upload/policy-oa-2016-1.pdf>)

*Publisher copyright claim:*

(Article begins on next page)

## Expression of vascular endothelial growth factor receptor types 1, 2 and 3 in placenta from pregnancies complicated by hypertensive disorders

M. Marini<sup>A</sup>, D. Vichi<sup>A</sup>, A. Toscano<sup>A</sup>, G. D. Zappoli Thyriou<sup>B</sup>, E. Parretti<sup>C</sup>, G. Mello<sup>C</sup>, G. Gheri<sup>A</sup>, A. Pacini<sup>A</sup> and E. Sgambati<sup>A,D</sup>

<sup>A</sup>Department of Anatomy, Histology and Forensic Medicine, University of Florence, Policlinic of Careggi, Viale Morgagni 85, 50134 Florence, Italy.

<sup>B</sup>Department of Medicine, University of Florence, Policlinic of Careggi, Viale Pieraccini 18, 50134 Florence, Italy.

<sup>C</sup>Department of Gynecology, Perinatology and Human Reproduction University of Florence, Policlinic of Careggi, Viale Morgagni 85, 50134 Florence, Italy.

<sup>D</sup>Corresponding author. Email: sgambati@unifi.it

**Abstract.** The aim of the present study was to determine the expression of vascular endothelial growth factor (VEGF) family receptors (VEGFR) in placentas from pregnancies complicated by hypertensive disorders of different clinical severity. Placental tissue from women with gestational hypertension, pre-eclampsia, pre-eclampsia with haemolysis, elevated liver enzymes and low platelets (HELLP syndrome) and normotensive women, as a control group, was examined. Immunohistochemical techniques, reverse transcription–polymerase chain reaction and western blot were used to evaluate receptor expression. In cases with gestational hypertension, as well as in control cases, VEGFR-1 and VEGFR-3 immunoreactivity was detected in all placental components, whereas in placentas from the pre-eclampsia and pre-eclampsia with HELLP syndrome groups, VEGFR-1 and VEGFR-3 immunoreactivity was detected only in some portions of trophoblast and/or some vessels and/or clusters of stromal cells. In the control group, VEGFR-2 immunoreactivity was observed only in the vessels, whereas the hypertensive groups showed VEGFR-2 immunoreactivity also in trophoblast and stromal cells. The mRNA levels of the three receptors in the group with gestational hypertension were higher with respect to those in the control group. Placentas from pregnancies with pre-eclampsia showed lowest mRNA expression levels, whereas placentas from women with pre-eclampsia plus HELLP syndrome showed higher mRNA expression levels with respect to the three other groups. Receptor protein levels were lower in pathological cases compared with levels in the control group. These findings demonstrate a dysregulation of placental expression of VEGF family receptors related to the degree of clinical severity of the hypertensive disorder.

### Introduction

In normal pregnancies, the invasion of the maternal decidua and transformation of the spiral arteries in low resistance vessels by fetal trophoblast are essential for successful development of the placenta (Pijnenborg 1994; Benirschke and Kaufmann 1995). In pregnancies complicated by pre-eclampsia, this trophoblast invasion is inadequate, resulting in poor placental perfusion and fetal hypoxia (Zhou *et al.* 1997; Damsky and Fisher 1998). This induces a release of factors in the maternal circulation that may cause vasoconstriction, hypertension, proteinuria and endothelial dysfunction (Roberts and Redman 1993; Zhou *et al.* 1997; Damsky and Fisher 1998).

Several vascular endothelial growth factors (VEGF), such as VEGF-A, VEGF-B, VEGF-C, VEGF-D and placental growth factor (PLGF), and their receptors have been shown to be expressed in the placenta (Table 1).

The VEGF family and its receptors are likely to be involved in the remodelling of uterine vessels, angiogenesis and the regulation of trophoblast invasion, proliferation and differentiation (Shore *et al.* 1997; Taylor *et al.* 1997; Torry and Torry 1997; Lash *et al.* 1999; Crocker *et al.* 2001; Gu *et al.* 2006).

Several studies have been undertaken investigating the expression of the VEGF family and its receptors in placental tissues of women with normal pregnancies (Cooper *et al.* 1995; Clark *et al.* 1996; Cheung 1997; Shore *et al.* 1997; Dunk and Ahmed 2001; Demir *et al.* 2004) and pregnancies complicated by hypertensive disorders (Cooper *et al.* 1996; Lyall *et al.* 1997; Cheng *et al.* 2001; El-Salahy *et al.* 2001; Helske *et al.* 2001; Ranheim *et al.* 2001; Kumazaki *et al.* 2002; Zhou *et al.* 2002; Tsatsaris *et al.* 2003). However, there are some discrepancies in the data reported. In particular, in some studies a decrease in the placental expression of VEGF-A and/or its receptors was

**Table 1.** The vascular endothelial growth factor family and its receptors expressed in the placenta

Growth factors	Molecular weight (kDa)	Receptors	References
VEGF-A	45	VEGFR-1/Flt-1 VEGFR-2/Flk-1	De Vries <i>et al.</i> 1992; Terman <i>et al.</i> 1992; Cheung 1997; Ni <i>et al.</i> 1997; Torry and Torry 1997; Vuorela <i>et al.</i> 1997; Kingdom <i>et al.</i> 2000; Favier and Corvol 2001
VEGF-B	48	VEGFR-1/Flt-1	De Vries <i>et al.</i> 1992; Klagsbrun and D'Amore 1996; Vuorela <i>et al.</i> 1997
VEGF-C	24	VEGFR-2/Flk-1 VEGFR-3/Flt-4	Joukov <i>et al.</i> 1996; Klagsbrun and D'Amore 1996; Vuorela <i>et al.</i> 1997; Enholm <i>et al.</i> 1998
VEGF-D	16	VEGFR-2/Flk-1 VEGFR-3/Flt-4	Gu <i>et al.</i> 2006
PLGF	50	VEGFR-1/Flt-1	Maglione <i>et al.</i> 1991; De Vries <i>et al.</i> 1992

VEGF, vascular endothelial growth factor; PLGF, placental growth factor.

observed in pregnancies complicated by more or less severe hypertensive disorders, such as pre-eclampsia and pre-eclampsia with HELLP syndrome, compared with control pregnancies (Cooper *et al.* 1996; Lyall *et al.* 1997; Zhou *et al.* 2002); other studies have demonstrated either an increase in or no evidence of abnormal placental VEGF and/or receptor expression in pregnancies complicated by hypertensive disorders (Cheng *et al.* 2001; Helske *et al.* 2001; Ranheim *et al.* 2001; Kumazaki *et al.* 2002; Tsatsaris *et al.* 2003).

In our previous study, VEGF-A expression was investigated in placentas derived from pregnancies complicated by hypertensive disorders with different clinical severity, such as gestational hypertension, pre-eclampsia and pre-eclampsia with haemolysis, elevated liver enzymes and low platelets (HELLP syndrome). We used immunohistochemical and reverse transcription-polymerase chain reaction (RT-PCR) techniques to show the location and mRNA expression of this factor, respectively (Sgambati *et al.* 2004). Moreover, we formed homogeneous groups of hypertensive disorders with a limited range of gestational ages and randomly sampled the placental tissue (to obtain material representative of the entire organ). This was done in order to obtain a better determination of the expression of VEGF-A in the various hypertensive disorders, to clarify the disagreement between the data reported in the literature and to understand the role of VEGF-A in these pathologies. The data showed different expression of placental VEGF-A according to the degree of clinical severity of the hypertensive disorder.

In the present study, we wanted to investigate the expression profile of VEGF family receptors in placentas from the same types of cases investigated in our previous study. In order to perform a complete study of the expression of the receptors, we used immunohistochemical and RT-PCR techniques, as well as the western blot technique for a quantitative analysis of the receptors.

## Materials and methods

### Group classification

Three groups of women were considered: (1) women with pregnancies complicated by gestational hypertension ( $n = 30$  cases);

(2) women with pregnancies complicated by pre-eclampsia ( $n = 25$  cases); (3) women with pregnancies complicated by pre-eclampsia with HELLP syndrome ( $n = 24$  cases). Women with uncomplicated pregnancies ( $n = 20$  cases) were examined as the control group. The gestational age ranged between 35 and 38 weeks.

No women with chronic hypertension, renal disease, diabetes or pregnancies complicated by intrauterine growth restriction (IUGR) were included in the study. In all study groups, women were delivered by Caesarean section. In the control group, the Caesarean section was performed because of one of the following indications: breech presentation, cephalopelvic disproportion or psychological reasons.

Gestational hypertension was defined as persistent diastolic blood pressure (DBP) above 90 mmHg and systolic blood pressure (SBP) above 140 mmHg, in patients normotensive before 20 weeks of gestation. The criteria for the diagnosis of pre-eclampsia were DBP above 90 mmHg and SBP above 140 mmHg, with oedema and proteinuria greater than 0.3 g per 24 h, in patients normotensive before 20 weeks of gestation. The criteria for the diagnosis of HELLP syndrome were: (1) haemolysis: abnormal peripheral blood smear, total bilirubin  $\geq 1.2$  mg dL<sup>-1</sup> and lactic dehydrogenase (LDH)  $\geq 600$  U L<sup>-1</sup>; (2) elevated liver enzymes: serum aspartate aminotransferase (AST)  $\geq 70$  U L<sup>-1</sup>; and (3) low platelets: platelets count  $\leq 100\,000$   $\mu$ L<sup>-1</sup>.

Informed written consent was obtained from each patient prior to their participation in the study.

### Placenta collection

At delivery, the placentas were weighed and full thickness blocks were obtained. A stratified random sampling procedure was used to obtain 12 full-thickness blocks per organ. Six specimens were immersed in neutral 4% buffered formalin solution for 12 h and processed in a standard manner for the preparation of paraffin blocks; sections (5  $\mu$ m) were then obtained. Other specimens were snap-frozen in liquid nitrogen and stored at  $-80^{\circ}$ C.

### Immunohistochemistry

Sections were treated according to the immunohistochemical technique for detection of VEG receptor (VEGFR)-1, VEGFR-2 and VEGFR-3. Briefly, endogenous peroxidase was blocked by incubation of sections in 0.3% hydrogen peroxide. Samples were incubated with blocking serum to reduce non-specific reactions and then incubated with the primary antibody. The following primary antibodies were used: polyclonal rabbit anti-VEGFR-1 and monoclonal mouse anti-VEGFR-2 diluted 1 : 80 in phosphate-buffered saline (PBS) and polyclonal rabbit anti-VEGFR-3 diluted 1 : 100 in PBS (Santa Cruz, Santa Cruz, CA, USA; Kumazaki *et al.* 2002; Zhou *et al.* 2002; Demir *et al.* 2004; Kaushal *et al.* 2005). The subsequent steps of the procedure were performed using the ABC Staining Systems kit (Santa Cruz) according to the manufacturer's instructions. Immunoreactive VEGFR-1, VEGFR-2 and VEGFR-3 were localised by incubating sections in 0.7 mg mL<sup>-1</sup> 3,3'-diaminobenzidine and 0.7 mg mL<sup>-1</sup> hydrogen peroxide in 0.06 M Tris-buffered saline (TBS). Controls samples were obtained by omitting the primary antibodies or by incubating the sections with non-specific IgG at the same concentrations as the primary antibodies.

For each section, 10 fields were examined by an investigator blinded to the group from which the tissue came and scored for staining location in trophoblast, stromal cells, Hofbauer cells and vessels.

All sections were treated with immunohistochemical techniques for each antibody in the same batch to eliminate inter-batch variations.

### Evaluation of immunostaining intensity

For each section, the staining intensity of the three VEGF receptors was evaluated in trophoblast, stromal cells, Hofbauer cells and vessels. For this purpose, optical density (OD) was measured on grey scale images using a computerised image analysis program (Image-Pro Plus version 4.5; Media Cybernetics, Silver Spring, MD, USA). The staining intensity was measured and expressed in arbitrary transmission units standardised from 0 to 250, with 0 being the maximum staining and 250 equivalent to no staining. Ten fields for each section, selected at random, were examined. In each field, for each placental component, two types of measurements were made: (1) a measurement of the intensity of the reactive components only; and (2) a measurement of the intensity of all the components (reactive and not reactive).

### Semiquantitative RT-PCR

For RT-PCR, total RNA was extracted from frozen specimens using TriReagent (Sigma, Milan, Italy) according to the manufacturer's instructions. The final total RNA pellet was suspended in 30 µL diethyl pyrocarbonate-treated water and 2 µL was used for the spectrophotometric determination of RNA concentrations at 260 nm and RNA quality (260 : 280 nm ratio). An equal amount of total RNA (1 µg) from each sample was reverse transcribed and amplified in a total volume of 50 µL using the SuperScript One Step RT-PCR System with Platinum Taq DNA (Invitrogen, Milan, Italy). Placental VEGFR-1, VEGFR-2 and VEGFR-3 primer sequences were designed on the basis of the published sequences (GeneBank accession numbers

**Table 2. Vascular endothelial growth factor receptor (VEGFR)-1, VEGFR-2, VEGFR-3 and  $\beta$ -actin sequence of primers and amplicons size for reverse transcription-polymerase chain reaction analysis**

	Primers	Amplicon size (bp)
VEGFR-1	5'-GGCTCTGTGGAAAGTTCAGC-3' 5'-GCTCACACTGCTCATCCAAA-3'	223
VEGFR-2	5'-GTGACCAACATGGAGTCGTG-3' 5'-TGCTTACAGAAGACCATGC-3'	218
VEGFR-3	5'-GAGACAAGGACAGCGAGGAC-3' 5'-TCACGAACACGTAGGAGCTG-3'	186
$\beta$ -Actin	5'-GGACTTCGAGCAAGAGATGG-3' 5'-AGCACTGTGTTGGCGTACCAG-3'	234

NM\_002019, NM\_002253 and NM\_182925, respectively). The forward and reverse primers and the expected product size for each receptor are given in Table 2.

All RT-PCR were normalised with  $\beta$ -actin (GenBank accession no. NM\_001101; Table 2) and the optimal PCR cycles within linear ranges were determined (data not shown).

Placental VEGFR-1, VEGFR-2, VEGFR-3 and  $\beta$ -actin were reverse transcribed by performing one cycle of 55°C for 30 min and 94°C for 2 min. The PCR was conducted immediately after cDNA synthesis, under the following conditions: 40 cycles for VEGFR receptors and 30 cycles for  $\beta$ -actin of 94°C for 15 s (denaturation), 54°C for 30 s (annealing) and 68°C for 1 min (extension), followed by a final extension at 68°C for 5 min. The size of the predicted products was visualised with 1.0% agarose gel electrophoresis and ethidium bromide staining. The amount of RT-PCR products was determined by densitometric analysis using Image J Analysis software, Scion Corporation, MD, USA. Data are expressed as the mean  $\pm$  s.e.m. of three values of VEGF receptor amplification products normalised to the starting total RNA volumes and in reference to the corresponding  $\beta$ -actin values.

### Western blot

Frozen placental tissues were thawed, minced with a razor blade and homogenised on ice three times (20 s each), in lysis buffer (50 mM TRIS-HCl (pH 7.0), 150 mM NaCl, 1.5 mM EDTA, 0.5 mM dithiothreitol, 0.25% (v/v) sodium dodecyl sulfate (SDS), 1% (v/v) Triton X-100) supplemented with a protease inhibitor cocktail (Roche, Milan, Italy) containing 10% phenylmethylsulfonyl fluoride (PMSF). Tissue homogenates were centrifuged at 20 000g for 15 min at 4°C and the supernatant assayed for total protein content (Bradford 1976) and stored at -80°C. Samples containing equal amounts of protein (30 µg) were separated on 4-12% gradient SDS-polyacrylamide gel electrophoresis (PAGE) and transferred to nitrocellulose membrane. Non-specific binding of antibodies was blocked by 1 h incubation in 5% powdered skim milk in PBS + 0.1% Tween-20 (PBST). After three washes with PBST, membranes were incubated for 1 h with the following primary antibodies: polyclonal rabbit anti-VEGFR-1, monoclonal mouse anti-VEGFR-2 and polyclonal rabbit anti-VEGFR-3 (Santa

Cruz) diluted 1 : 200 in PBST containing 5% milk. Subsequently, membranes were incubated for 1 h with horseradish peroxidase-conjugated secondary antibodies diluted 1 : 1000 (Santa Cruz). Immunoreactivity was detected using the Opti4CN kit (BioRad, Milan, Italy) according to the manufacturer's instructions. Densitometric analysis of the bands was performed using Image J Analysis software. Data are expressed as the mean  $\pm$  s.d. of triplicate determinations in a representative experiment of two independent experiments with similar results.

#### Statistical analysis

To compare clinical data among the study groups, analysis of variance (ANOVA) was applied.

Statistical analysis of immunostaining was performed using Student's *t*-test. Then, the following differences were tested: (1) differences between data obtained from a measurement of the intensity of the reactive components only of the control group and those of the other groups; (2) differences between data obtained from a measurement of the intensity of all the components (reactive and unreactive) in each study group. The reproducibility of measurements was assessed by comparing measurements made by one observer at different times and the measurements of two observers. Intra- and interobserver coefficients of variation were 1.5% and 5.2%, respectively.

Student's *t*-test was used to estimate the levels of significance of differences in VEGFR-1/ $\beta$ -actin, VEGFR-2/ $\beta$ -actin and VEGFR-3/ $\beta$ -actin mRNA ratios, as well as protein levels, between control placenta and placentas from women with gestational hypertension, pre-eclampsia and pre-eclampsia with HELLP syndrome.

Differences in mRNA expression and protein levels among the pathological study groups were compared using analysis of variance (ANOVA).

For each test,  $P < 0.05$  was considered statistically significant.

## Results

### Clinical details

The clinical details of the women whose placentas were used in the present study are given in Table 3. Mean weeks of gestation and mean birthweight at delivery were significantly lower in the cases with pre-eclampsia and pre-eclampsia with HELLP syndrome compared with the other groups. Mean placental weight was significantly lower in the pathological groups compared with the control group. Mean pressure (SBP and DBP) was statistically higher in pathological cases compared with the control cases. There were no significant differences between groups with respect to the other clinical data.

### Immunohistochemical analysis

The study was limited to the chorionic intermediate and terminal villi.

### Immunolocalization

Results of immunostaining for VEGFR-1, VEGFR-2 and VEGFR-3 in the placenta are given in Table 4.

#### VEGFR-1

In the control group, the trophoblast, endothelial cells of the vessels, stromal cells and Hofbauer cells showed immunoreactivity for VEGFR-1 (Fig. 1a).

In cases of hypertensive disorders, all placental components were immunoreactive for VEGFR-1 (Fig. 1b), although in the pre-eclampsia (Fig. 1c) and pre-eclampsia with HELLP syndrome (Fig. 1d) groups, some portions of the trophoblast, the endothelial cells of some vessels and clusters of stromal cells did not show reactivity.

#### VEGFR-2

In the control group, only the endothelial cells of the vessels showed immunoreactivity for VEGFR-2 (Fig. 2a).

In cases of gestational hypertension, the trophoblast, endothelial cells of the vessels and stromal cells showed

**Table 3. Clinical details of the study groups**

Values are the mean  $\pm$  s.e.m.

	Control <sup>a</sup> (n = 20)	Hypertension <sup>b</sup> (n = 30)	Pre-eclampsia <sup>c</sup> (n = 25)	Pre-eclampsia/HELLP syndrome <sup>d</sup> (n = 24)
Maternal age (years)	30.2 $\pm$ 7.4	31.0 $\pm$ 8.3	31.1 $\pm$ 5.7	30.3 $\pm$ 6.5
Gestation at delivery (weeks)	38.0 $\pm$ 1.3	37.8 $\pm$ 1.8	35.6 $\pm$ 4.3*	35.4 $\pm$ 3.8*
Birthweight (g)	3480.1 $\pm$ 610.1	3310.4 $\pm$ 712.2	2760.5 $\pm$ 516.2*	2638.1 $\pm$ 605.3*
Placental weight (g)	618.8 $\pm$ 80.1	524.4 $\pm$ 59.1*	451.3 $\pm$ 65.1*	440.2 $\pm$ 58.5*
Primigravida (n)	12	10	9	10
Smokers (n)	4	12	4	3
Pregnancy BMI (kg m <sup>-2</sup> )	22.4 $\pm$ 3.6	24.8 $\pm$ 3.2	24.3 $\pm$ 3.0	24.5 $\pm$ 4.3
Blood pressure at delivery (mmHg)				
Systolic	111.2 $\pm$ 9.3	148.8 $\pm$ 9.1*	156.1 $\pm$ 9.2*	148.5 $\pm$ 10.1*
Diastolic	65.7 $\pm$ 8.2	97.3 $\pm$ 6.5*	102.3 $\pm$ 9.4*	98.1 $\pm$ 8.2*

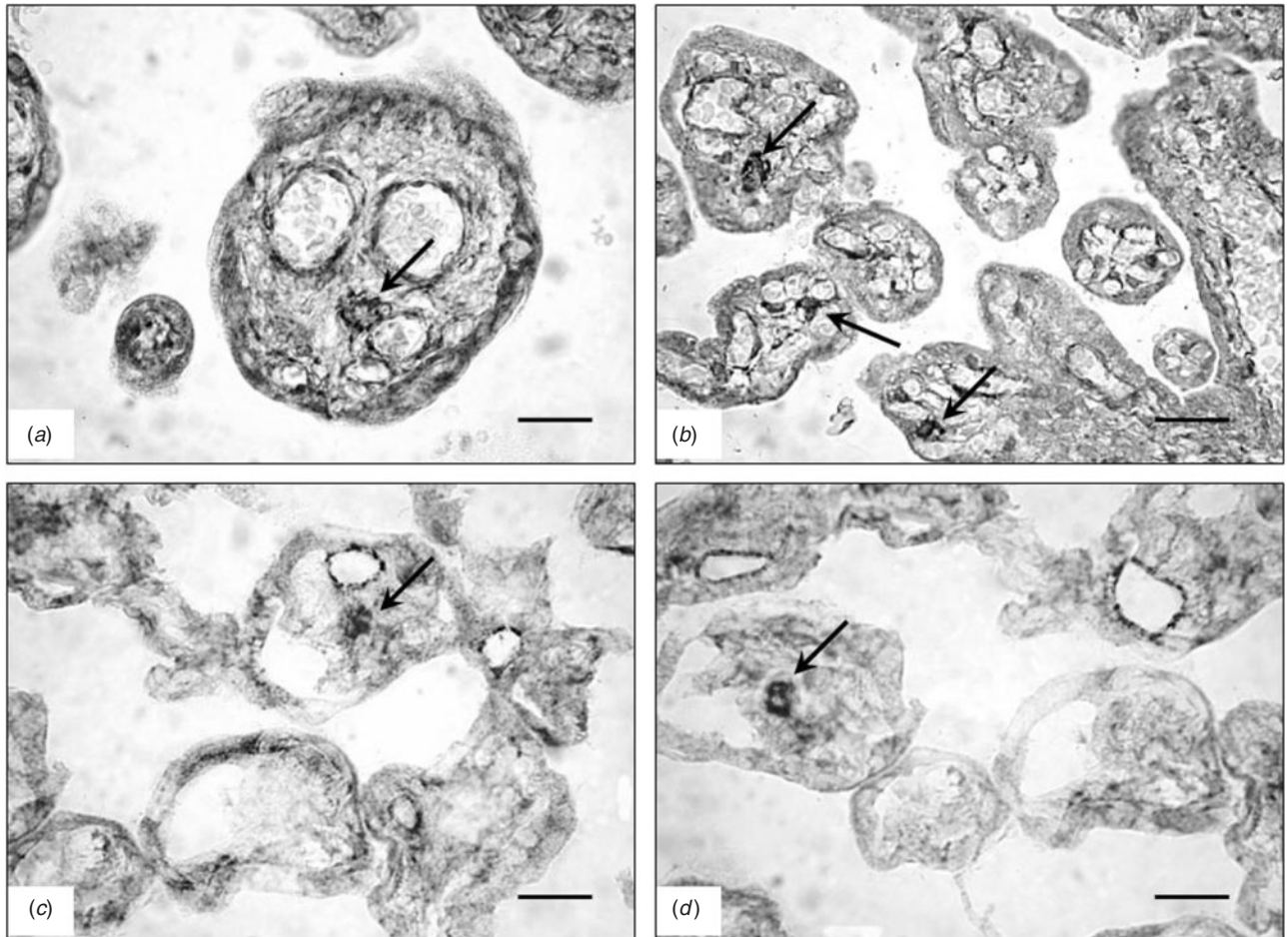
For gestation at delivery and birthweight, c, d v. a, b = \* $P < 0.01$ . For placental weight, c, d v. a, b and b v. a = \* $P < 0.01$ ; For systolic and diastolic blood pressure at delivery, b, d v. a, c v. a, b and c v. a = \* $P < 0.01$ .

BMI, body mass index; pre-eclampsia/HELLP syndrome, pre-eclampsia with haemolysis, elevated liver enzymes and low platelets.

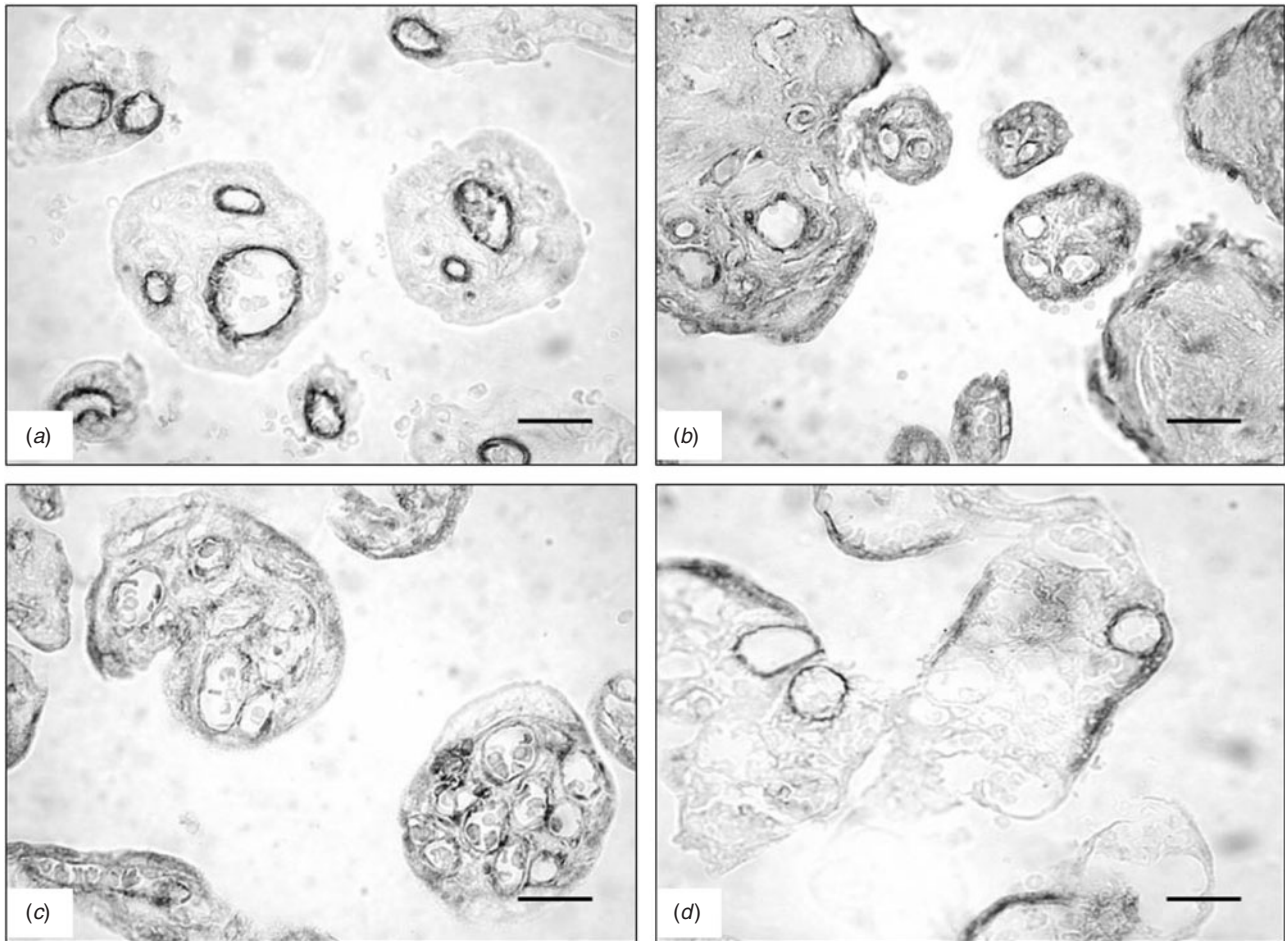
**Table 4. Assessment of vascular endothelial growth factor receptor (VEGFR)-1, VEGFR-2 and VEGFR-3 immunostaining in the placenta**

Study groups	Trophoblast			Vessels			Stromal cells			Hofbauer cells		
	R-1	R-2	R-3	R-1	R-2	R-3	R-1	R-2	R-3	R-1	R-2	R-3
Control	+	-	+	+	+	+	+	-	+	+	-	+
Hypertension	+	+	+	+	+	+	+	+	+	+	-	+
Pre-eclampsia	+*	+*	+*	+**	+	+	+§	+§	+	+	-	+
Pre-eclampsia/HELLP syndrome	+*	+*	+*	+**	+**	+**	+§	+§	+§	+	-	+

R-1, VEGFR-1; R-2, VEGFR-2; R-3, VEGFR-3; -, no reactivity; +, reactivity; \*, reactivity in some tracts of the trophoblast; \*\*, reactivity in some vessels; §, reactivity in cell clusters; pre-eclampsia/HELLP syndrome, pre-eclampsia with haemolysis, elevated liver enzymes and low platelets.



**Fig. 1.** Vascular endothelial growth factor receptor (VEGFR)-1 immunostaining in the placenta. (a) Control and (b) gestational hypertension at 37 weeks. The trophoblast, vessels, stromal cells and Hofbauer cells (arrows) are reactive. (c) Pre-eclampsia and (d) pre-eclampsia with haemolysis, elevated liver enzymes and low platelets (HELLP syndrome) at 36 weeks. Reactivity is observable in some portions of the trophoblast, in some vessels, in clusters of stromal cells and in Hofbauer cells (arrows). Scale bar = 25  $\mu$ m.



**Fig. 2.** Vascular endothelial growth factor receptor (VEGFR)-2 immunostaining in the placenta. (a) Control at 38 weeks. Reactivity is observable in the vessels. (b) Gestational hypertension at 38 weeks. The trophoblast, vessels and stromal cells are reactive. (c) Pre-eclampsia at 37 weeks. Some portions of the trophoblast, vessels and clusters of stromal cells show reactivity. (d) Pre-eclampsia with haemolysis, elevated liver enzymes and low platelets (HELLP syndrome) at 36 weeks. Some portions of the trophoblast, some vessels and clusters of stromal cells are reactive. Scale bar = 25  $\mu$ m.

reactivity (Fig. 2b). In cases of pre-eclampsia, some portions of trophoblast, the endothelial cells of all vessels and clusters of stromal cells were immunoreactive for VEGFR-2 (Fig. 2c). Cases of pre-eclampsia with HELLP syndrome showed immunoreactivity for VEGFR-2 only in some portions of the trophoblast, in endothelial cells of some vessels and in clusters of stromal cells (Fig. 2d).

#### VEGFR-3

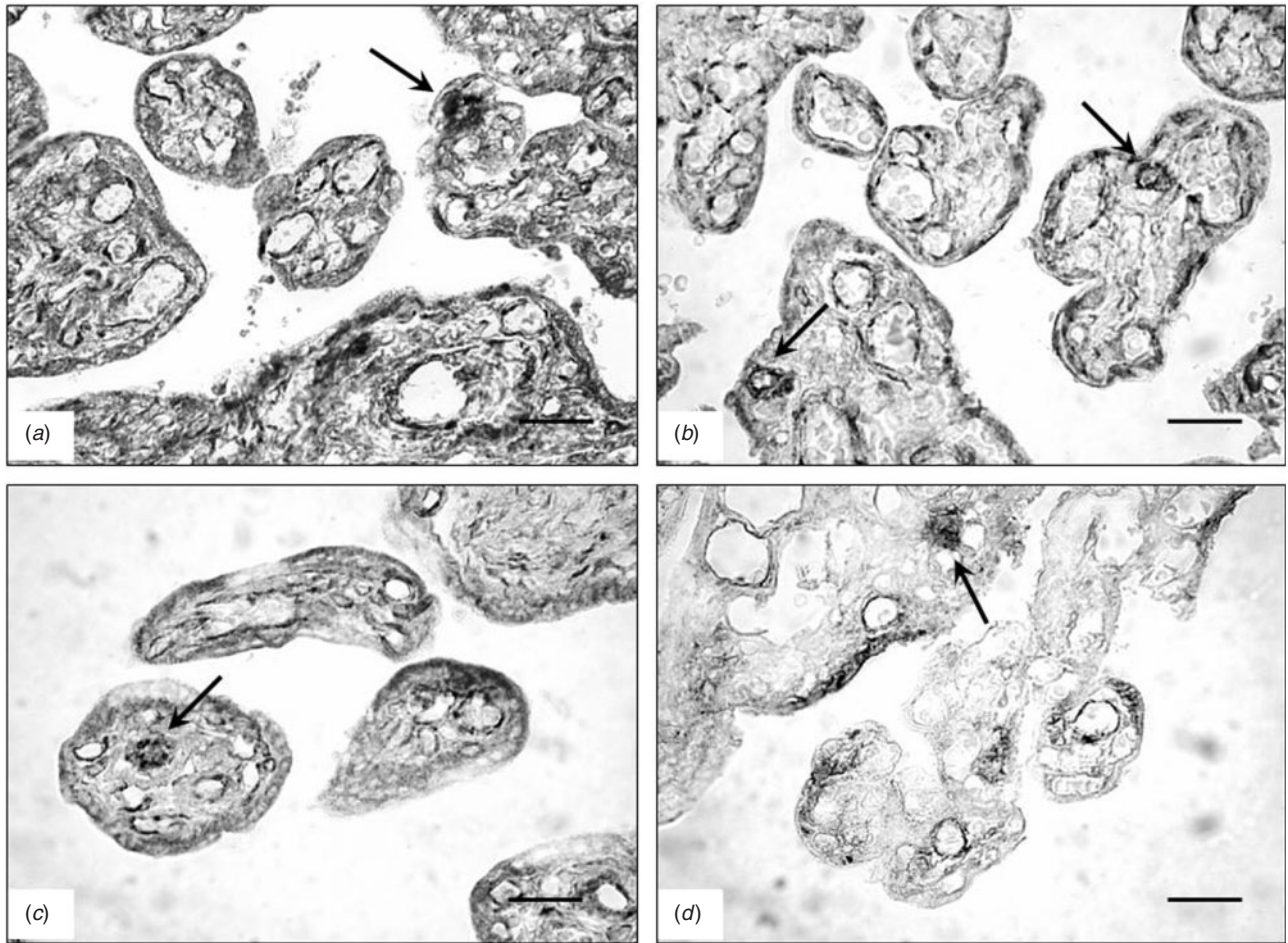
In the control group, all placental components were immunoreactive for VEGFR-3 (Fig. 3a).

In cases of gestational hypertension (Fig. 3b) and pre-eclampsia (Fig. 3c), all placental components showed immunoreactivity for VEGFR-3, although in cases of pre-eclampsia some portions of the trophoblast were not reactive. In cases of pre-eclampsia with HELLP syndrome, some portions of the trophoblast, the endothelial cells of some vessels, clusters of stromal cells and Hofbauer cells showed immunoreactivity for VEGFR-3 (Fig. 3d).

#### Statistical analysis of immunoreactivity

##### *Differences in data from the first type of measurement between the control and pathological groups*

The statistical analysis with regard to the first type of measurement showed that the intensity of VEGFR-1 immunoreactivity of the trophoblast in all pathological cases and of stromal cells in cases of pre-eclampsia and pre-eclampsia with HELLP syndrome was lower ( $P < 0.05$ ) compared with the control group; the vessels, in all pathological cases and the stromal cells in cases of gestational hypertension did not show significant differences in reactivity compared with the control group. The intensity of VEGFR-2 reactivity of the vessels in all pathological cases was significantly lower (hypertension and pre-eclampsia with HELLP syndrome  $P < 0.01$ ; pre-eclampsia  $P < 0.001$ ) compared with the control group. The VEGFR-3 reactivity of the trophoblast, stromal cells and vessels was significantly lower in cases of gestational hypertension ( $P < 0.05$ ), pre-eclampsia ( $P < 0.05$ ) and pre-eclampsia with HELLP syndrome (trophoblast and stromal cells  $P < 0.05$ ; vessel:  $P < 0.01$ ).



**Fig. 3.** Vascular endothelial growth factor receptor (VEGFR)-3 immunostaining in the placenta. (a) Control and (b) gestational hypertension at 38 weeks. The trophoblast, vessels, stromal cells and Hofbauer cells (arrows) show reactivity. (c) Pre-eclampsia 37 weeks. Some portions of the trophoblast, vessels, stromal cells and one Hofbauer cell (arrow) show reactivity. (d) Pre-eclampsia with haemolysis, elevated liver enzymes and low platelets (HELLP syndrome) at 36 weeks. Reactivity is observable in some portions of the trophoblast, in some vessels, in clusters of stromal cells and in one Hofbauer cell (arrow). Scale bar = 25  $\mu\text{m}$ .

There were no significant difference in VEGFR-1 and VEGFR-3 reactivity in Hofbauer cells between any of the pathological cases and the control group.

*Differences in data between the first and second types of measurement in each group*

With regard to the three receptors, the data obtained for all components in the control and gestational hypertension groups, as well as for the Hofbauer cells in all four study groups, there were no significant differences found between the first and second types of measurement. With regard to VEGFR-1, in cases of pre-eclampsia and pre-eclampsia with HELLP syndrome, values obtained for trophoblast ( $P < 0.01$ ), vessels ( $P < 0.001$ ) and stromal cells ( $P < 0.01$ ) were significantly lower in the second type of measurement compared with the first. With regard to VEGFR-2, values obtained for the trophoblast and stromal cells ( $P < 0.05$ ) in cases of pre-eclampsia and for the trophoblast ( $P < 0.01$ ), vessels ( $P < 0.01$ ) and stromal cells ( $P < 0.05$ ) in

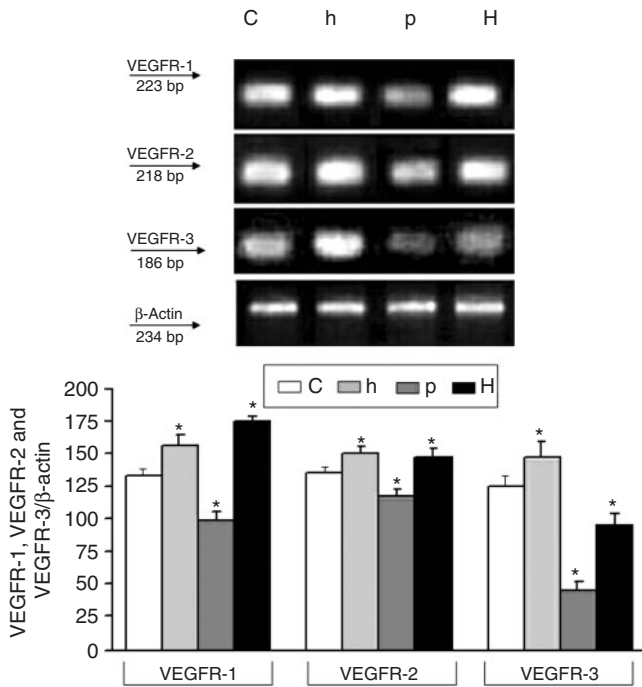
cases of pre-eclampsia with HELLP syndrome were significantly lower in the second type of measurement compared with the first. There were no significant differences in data obtained using the two measurements for vessels in cases of pre-eclampsia. With regard to VEGFR-3, values for the trophoblast ( $P < 0.001$ ) in cases of pre-eclampsia and the trophoblast ( $P < 0.001$ ), vessels ( $P < 0.01$ ) and stromal cells ( $P < 0.05$ ) in cases of pre-eclampsia with HELLP syndrome were significantly lower in the second type of measurement compared with the first; there were no significant differences between the two measurements in terms of data for vessels and stroma in cases of pre-eclampsia.

*RT-PCR assay*

*VEGFR-1*

Levels of placental VEGFR-1 mRNA were significantly higher in cases of gestational hypertension and pre-eclampsia with HELLP syndrome compared with control cases, whereas





**Fig. 4.** Reverse transcription–polymerase chain reaction analysis of vascular endothelial growth factor receptor (VEGFR)-1, VEGFR-2 and VEGFR-3 mRNA levels in placental tissue. Total RNA (1 g) of control (lane 1; C), hypertension (lane 2; h), pre-eclampsia (lane 3; p) and pre-eclampsia with haemolysis, elevated liver enzymes and low platelets (HELLP syndrome; lane 4; H) was reverse transcribed and amplified in parallel with the house-keeping gene  $\beta$ -actin. The upper panels display representative agarose gels showing VEGFR-1, VEGFR-2, VEGFR-3 and  $\beta$ -actin mRNA expression levels in placental samples from the control and pathological groups. Data are representative of at least three separate experiments. Histograms show VEGFR-1, VEGFR-2 and VEGFR-3 mRNA levels determined by densitometric analysis; each bar represents the mean  $\pm$  s.e.m. of three values of each amplification product normalised to the starting total RNA volumes and in reference to the corresponding  $\beta$ -actin values. \* $P < 0.05$  for VEGFR-1 h, p and H v. C (Student's *t*-test);  $P < 0.05$  for h v. p and H, and p v. H (ANOVA); \* $P < 0.05$  for VEGFR-2 h, p and H v. C (Student's *t*-test);  $P < 0.05$  for h v. p, and p v. H (ANOVA); \* $P < 0.05$  for VEGFR-3 h, p and H v. C (Student's *t*-test);  $P < 0.05$  h v. p and H, and p v. H (ANOVA).

they were lower in pre-eclampsia cases compared with control. The VEGFR-1 mRNA levels in cases of gestational hypertension and pre-eclampsia were significantly lower compared with levels in cases of pre-eclampsia with HELLP syndrome; VEGFR-1 mRNA levels in cases of pre-eclampsia were significantly lower compared levels in cases of gestational hypertension (Fig. 4).

#### VEGFR-2

The mRNA levels of VEGFR-2 were significantly higher in cases of gestational hypertension and pre-eclampsia with HELLP syndrome compared with control, whereas they were lower in cases of pre-eclampsia compared with control. The mRNA levels of VEGFR-2 in cases of gestational hypertension and pre-eclampsia with HELLP syndrome were significantly higher compared with mRNA levels in cases of

pre-eclampsia; no significant differences were found with respect to mRNA levels of VEGFR-2 in cases of gestational hypertension compared with pre-eclampsia with HELLP syndrome (Fig. 4).

#### VEGFR-3

The mRNA levels of VEGFR-3 in cases of gestational hypertension were significantly higher compared with control, whereas they were lower in cases of pre-eclampsia and pre-eclampsia with HELLP syndrome cases compared with control. In cases of gestational hypertension, the mRNA levels of VEGFR-3 were significantly higher compared levels in cases of pre-eclampsia and pre-eclampsia with HELLP syndrome; mRNA levels of VEGFR-3 in cases of pre-eclampsia were significantly lower compared with levels in cases of pre-eclampsia with HELLP syndrome (Fig. 4).

#### Western blot analysis

##### VEGFR-1 and VEGFR-2

Protein levels of VEGFR-1 and VEGFR-2 were significantly lower in cases of gestational hypertension, pre-eclampsia and pre-eclampsia with HELLP syndrome compared with control. Protein levels of VEGFR-1 and VEGFR-2 in gestational hypertension were significantly higher than in cases of pre-eclampsia and pre-eclampsia with HELLP syndrome; no significant differences were found in the expression of VEGFR-1 and VEGFR-2 protein in cases of pre-eclampsia compared with pre-eclampsia with HELLP syndrome (Fig. 5).

##### VEGFR-3

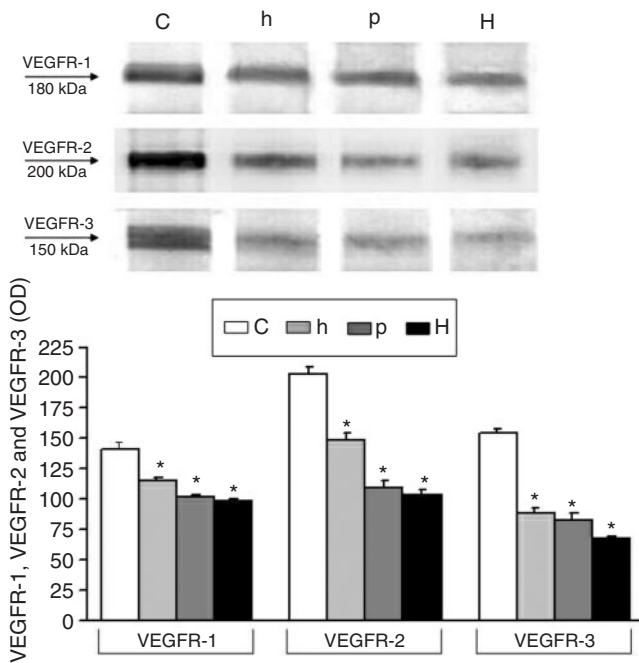
In cases of gestational hypertension, pre-eclampsia and pre-eclampsia with HELLP syndrome, protein levels of VEGFR-3 were significantly lower compared with control. The protein levels of VEGFR-3 in cases of gestational hypertension and pre-eclampsia were significantly higher compared with cases of pre-eclampsia with HELLP syndrome; no significant differences were found in protein levels between cases of gestational hypertension and pre-eclampsia (Fig. 5).

#### Discussion

Our previous study on the expression of placental VEGF-A was the first to be performed in pregnancies complicated by hypertensive disorders with varying degrees of clinical severity (Sgambati *et al.* 2004). In the present study, we wanted to determine, in the same types of cases, the expression of the placental receptors that mediate the functionality not only of VEGF-A, but also of other components of the VEGF family (PLGF, VEGF-B, VEGF-C and VEGF-D).

The findings obtained in the pathological cases were compared with those observed in cases of normal pregnancies considered to be the control group.

With regard to the control group, the immunohistochemistry results showed that VEGFR-1 and VEGFR-3 were localised in all placental components, whereas VEGFR-2 was detected only in endothelial cells. These findings are in partial agreement with those of previous investigations (Cooper *et al.* 1995; Clark *et al.*



**Fig. 5.** Western blot analysis of placental tissue. Total protein (30  $\mu$ g) from control (lane 1; C), hypertension (lane 2; h), pre-eclampsia (lane 3; p) and pre-eclampsia with haemolysis, elevated liver enzymes and low platelets (HELLP syndrome; lane 4; H) placenta was loaded onto a 4–12% polyacrylamide gel, electrophoresed, blotted onto nitrocellulose and exposed to anti-vascular endothelial growth factor receptor (VEGFR)-1, anti-VEGFR-2 and anti-VEGFR-3 antibodies. The position of molecular weight markers is indicated. Bars represent the intensity of the bands, determined by densitometry. Data are expressed as the mean  $\pm$  s.d. of triplicate determinations in a representative experiment from two independent experiments with similar results. \* $P < 0.05$  for VEGFR-1 h, p and H v. C (Student's *t*-test);  $P < 0.05$  for h v. p and H (ANOVA); \* $P < 0.05$  for VEGFR-2 h, p and H v. C (Student's *t*-test);  $P < 0.05$  for h v. p and H (ANOVA); \* $P < 0.05$  for VEGFR-3 h, p and H v. C (Student's *t*-test);  $P < 0.05$  for h and p v. H (ANOVA).

1996; Cheung 1997; Shore *et al.* 1997; Dunk and Ahmed 2001; Demir *et al.* 2004).

Regarding the location of VEGFR-1 and VEGFR-3, in pre-eclampsia and, particularly, in pre-eclampsia with HELLP syndrome, some portions of the trophoblast and/or some vessels and/or clusters of stromal cells did not express these receptors. Moreover, the intensity of immunoreactivity of some positive components was significantly lower in all pathological groups, particularly in the pre-eclampsia and pre-eclampsia with HELLP syndrome groups. With regard to VEGFR-2 in the pathological groups, its expression was detected not only in the vessels, but also in the trophoblast and stroma, especially in cases of gestational hypertension. However, the vessels of all pathological groups showed a significantly lower intensity of immunoreactivity compared with the control group.

The mRNA levels of the three receptors in the hypertension cases showed a statistically significant increase compared with the control group. Cases of pre-eclampsia exhibited mRNA levels of the three receptors that were significantly lower compared with the other three groups. In cases of pre-eclampsia

with HELLP syndrome, VEGFR-1 mRNA levels were significantly higher compared with the other groups; VEGFR-2 mRNA levels were significantly increase compared with the control and pre-eclampsia cases and VEGFR-3 mRNA levels were significantly increased only compared with levels in cases of pre-eclampsia.

Regarding protein expression levels, the data showed a decrease in all VEGFR in the pathological groups, particularly in the pre-eclampsia with HELLP syndrome group, compared with control.

Some studies performed on placentas from pregnancies complicated by pre-eclampsia with different degrees of clinical severity or on placentas under various pathological conditions, with all cases characterised by uteroplacental hypoperfusion, have shown that the hypoxic environment upregulates VEGF-A and its receptors, in particular VEGFR-1 (Helske *et al.* 2001; Kumazaki *et al.* 2002; Tsatsaris *et al.* 2003). In contrast, other authors have demonstrated that VEGF-A and VEGFR-1 are downregulated in placentas of pregnancies with severe pre-eclampsia and HELLP syndrome (Zhou *et al.* 2002) and studies on the effect of hypoxia on placental tissue have demonstrated that VEGF-A is upregulated, whereas VEGFR-1 is downregulated, by hypoxia (Ahmed *et al.* 2000). Moreover, some studies have shown that an increase in VEGF-A, together with other factors, may lead to the morphofunctional changes in placental tissue that characterise pre-eclampsia (Brockelsby *et al.* 2000; El-Salahy *et al.* 2001; Redman and Sargent 2001). From these discordant data, it could be hypothesised that an overproduction of VEGF-A in a definite period of gestation may lead to changes in placental tissue and that only the undamaged placental components may continue to overproduce VEGF-A (Sgambati *et al.* 2004). With regard to the data of the present study, in placentas from pregnancies with hypertension, a compensatory mechanism against the hypoxic environment occurs, with an increasing production of the mRNA all three receptors, as well as of the placental components that produce VEGFR-2. Nevertheless, the increases in the expression of mRNA of the receptors are not paralleled by increases in protein expression. This could be due to slight functional changes of the placental components that lead to altered protein synthesis. In cases of pre-eclampsia, a more severe complication characterised by evident morphofunctional changes, only some placental components may be able to produce the receptors. In cases of pre-eclampsia with HELLP syndrome, which can be considered a complication of pre-eclampsia or a completely different pathological condition (Ben Aissia *et al.* 2001; Tsokos *et al.* 2002; Zhou *et al.* 2002), there is probably greater damage of placental tissue triggered by an extremely hypoxic environment. This may elicit mRNA overexpression (in particular for VEGFR-1 and VEGFR-2) by all placental components, as well as those that are partially damaged. Nevertheless, only the few unaltered placental components may be able to produce adequate protein synthesis.

The findings of the present study are in partial agreement with those of previous studies on the expression of VEGF receptors in placentas of women with hypertensive disorders (Helske *et al.* 2001; Kumazaki *et al.* 2002; Tsatsaris *et al.* 2003). The disagreements may be due to the inclusion in the same study group

of cases of hypertensive disorders with different degrees of clinical severity, a wide range of gestational ages and to incorrect sampling of the tissue. In the present study, as in our previous investigation (Sgambati *et al.* 2004), we attempted to make homogeneous study groups with a limited range of gestational ages and we performed random sampling to obtain material representative of the entire organ in each case. Moreover, we used different investigation methods to completely evaluate receptor expression.

In conclusion, we have demonstrated that, in placental tissue from pregnancies complicated by hypertensive disorders, there is a dysregulation of the expression of the VEGF family receptors 1, 2 and 3 related to the different degrees of clinical severity. Therefore, all three receptors, with altered expression levels, may play an important role in the physiopathology of the placenta in these disorders.

## References

- Ahmed, A., Dunk, C., Ahmad, S., and Khaliq, A. (2000). Regulation of placental vascular endothelial growth factor (VEGF) and placenta growth factor (PLGF) and soluble Flt-1 by oxygen: a review. *Placenta (Suppl. A)* **21**, S16–S24. doi:10.1053/PLAC.1999.0524
- Ben Aissia, N., Sadfi, A., Batar, S., and Gara, F. (2001). The HELLP syndrome: report of 11 cases. *Tunis. Med.* **79**, 686–690.
- Benirschke, K., and Kaufmann, P. (1995). Oxygen as regulator of villous development. In 'Pathology of Human Placenta'. (Eds K. Benirschke and P. Kaufmann.) pp. 142–143. (Springer-Verlag: Heidelberg.)
- Bradford, M. M. (1976). A rapid and sensitive method for the quantitation of microgram quantities of protein utilizing the principle of protein-dye binding. *Anal. Biochem.* **72**, 248–254. doi:10.1016/0003-2697(76)90527-3
- Brockelsby, J. C., Anthony, F. W., Johnson, I. R., and Baker, P. N. (2000). The effects of vascular endothelial growth factor on endothelial cells: a potential role in preeclampsia. *Am. J. Obstet. Gynecol.* **182**, 176–183. doi:10.1016/S0002-9378(00)70510-2
- Cheng, Z., Lin, Q., and Shen, Z. (2001). Study on association of vascular endothelial growth factor with the pathogenesis of pregnancy induced hypertension. *Zhonghua Fu Chan Ke Za Zhi* **36**, 72–75. [In Chinese]
- Cheung, C. Y. (1997). Vascular endothelial growth factor: possible role in fetal development and placental function. *J. Soc. Gynecol. Invest.* **4**, 169–177. doi:10.1016/S1071-5576(97)00025-7
- Clark, D. E., Smith, S. K., Sharkey, A. M., and Charnock-Jones, D. S. (1996). Localization of VEGF and expression of its receptors flt and KDR in human placenta throughout pregnancy. *Hum. Reprod.* **11**, 1090–1098.
- Cooper, J. C., Sharkey, A. M., McLaren, J., Charnock-Jones, D. S., and Smith, S. K. (1995). Localization of vascular endothelial growth factor and its receptor, flt, in human placenta and decidua by immunohistochemistry. *J. Reprod. Fertil.* **105**, 205–213.
- Cooper, J. C., Sharkey, A. M., Charnock-Jones, D. S., Palmer, C. R., and Smith, S. K. (1996). VEGF mRNA levels in placentae from pregnancies complicated by pre-eclampsia. *Br. J. Obstet. Gynaecol.* **103**, 1191–1196.
- Crocker, I. P., Strachan, B. K., Lash, G. E., Cooper, S., Warren, A. Y., and Baker, P. N. (2001). Vascular endothelial growth factor but not placental growth factor promotes trophoblast syncytialization *in vitro*. *J. Soc. Gynecol. Invest.* **8**, 341–346. doi:10.1016/S1071-5576(01)00134-4
- Damsky, C. H., and Fisher, S. J. (1998). Trophoblast pseudo-vasculogenesis: faking it with endothelial adhesion receptors. *Curr. Opin. Cell Biol.* **10**, 660–666. doi:10.1016/S0955-0674(98)80043-4
- Demir, R., Kayisli, U. A., Seval, Y., Celik-Ozenci, C., Korgun, E. T., Demir-Wensten, A. Y., and Huppertz, B. (2004). Sequential expression of VEGF and its receptors in human placental villi during very early pregnancy: differences between placental vasculogenesis and angiogenesis. *Placenta* **25**, 560–572. doi:10.1016/J.PLACENTA.2003.11.011
- De Vries, C., Escobedo, J., Ueno, H., Houch, K., Ferrara, N., and Williams, L. T. (1992). The flms-like tyrosine kinase, a receptor for vascular endothelial growth factor. *Science* **255**, 989–991. doi:10.1126/SCIENCE.1312256
- Dunk, C., and Ahmed, A. (2001). Expression of VEGF-C and activation of its receptors VEGFR-2 and VEGFR-3 in trophoblast. *Histol. Histopathol.* **16**, 359–375.
- El-Salahy, E. M., Ahmed, M. I., El-Gharieb, A., and Tawfik, H. (2001). New scope in angiogenesis: role of vascular endothelial growth factor (VEGF), NO, lipid peroxidation, and vitamin E in the pathophysiology of pre-eclampsia among Egyptian females. *Clin. Biochem.* **34**, 323–329. doi:10.1016/S0009-9120(01)00230-2
- Enholm, B., Jussila, L., Karkkainen, M., and Alitalo, K. (1998). Vascular endothelial growth factor-C: a growth factor for lymphatic and blood vascular endothelial cells. *Trends Cardiovasc. Med.* **8**, 292–297. doi:10.1016/S1050-1738(98)00026-7
- Favier, J., and Corvol, P. (2001). Physiological angiogenesis. *Therapie* **56**, 455–463.
- Gu, B., Alexander, J. S., Gu, Y., Zhang, Y., Lewis, D. F., and Wang, Y. (2006). Expression of lymphatic vascular endothelial hyaluronan receptor-1 (LYVE-1) in the human placenta. *Lymphat. Res. Biol.* **4**, 11–17. doi:10.1089/LRB.2006.4.11
- Helske, S., Vourela, P., Carpén, O., Horning, C., Weich, H., and Halmesmäki, E. (2001). Expression of vascular endothelial growth factor receptors 1, 2 and 3 in placenta from normal and complicated pregnancies. *Mol. Hum. Reprod.* **7**, 205–210. doi:10.1093/MOLEHR/7.2.205
- Joukov, V., Pajusola, K., Kaipainen, A., Chilov, D., Lahtinen, I., Kukk, E., Saksala, O., Kalkkinen, N., and Alitalo, K. (1996). A novel vascular endothelial growth factor, VEGF-C, is the ligand for the Flt-4 receptor tyrosine kinase (VEGFR-3). *EMBO J.* **15**, 290–298.
- Kaushal, V., Mukunadzi, P., Dennis, R. A., Siegel, E. R., Jhonson, D. E., and Kahli, M. (2005). Stage-specific characterization of the vascular endothelial growth factor axis in prostate cancer: expression of lymphangiogenic markers is associated with advanced-stage disease. *Clin. Cancer Res.* **11**, 584–593.
- Kingdom, J., Huppertz, B., Seaward, G., and Kaufmann, P. (2000). Development of the placental villous tree and its consequences for fetal growth. *Eur. J. Obstet. Gynecol. Reprod. Biol.* **92**, 35–43. doi:10.1016/S0301-2115(00)00423-1
- Klagsbrun, M., and D'Amore, P. (1996). Vascular endothelial growth factor and its receptors. *Cytokine Growth Factors Rev.* **7**, 259–270. doi:10.1016/S1359-6101(96)00027-5
- Kumazaki, K., Nakayama, M., Suehara, N., and Yoshinai, W. (2002). Expression of vascular endothelial growth factor, placental growth factor, and their receptors flt-1 and KDR in human placenta under pathologic conditions. *Hum. Pathol.* **33**, 1069–1077. doi:10.1053/HUPA.2002.129420
- Lash, G. E., Cartwright, J. E., Whitley, G. S., Trew, A. J., and Baker, P. N. (1999). The effects of angiogenic growth factors on extravillous trophoblast invasion and motility. *Placenta* **20**, 661–667. doi:10.1053/PLAC.1999.0427
- Lyll, F., Yong, A., Boswell, F., Kingdom, J. C. P., and Greer, I. A. (1997). Placental expression of vascular endothelial growth factor in placenta from pregnancies complicated by pre-eclampsia and intrauterine growth restriction does not support placental hypoxia. *Placenta* **18**, 269–276. doi:10.1016/S0143-4004(97)80061-6
- Maglione, D., Guerriero, V., Viglietto, G., Delli-Bovi, P., and Persico, M. G. (1991). Isolation of a human placenta cDNA coding for a protein related to the vascular permeability factor. *Proc. Natl Acad. Sci. USA* **88**, 9267–9271. doi:10.1073/PNAS.88.20.9267

- Ni, Y., May, V., Braas, K., and Osol, G. (1997). Pregnancy augments uteroplacental vascular endothelial growth factor gene expression and vasodilator effects. *Am. J. Physiol.* **273**, 938–944.
- Pijnenborg, R. (1994). Trophoblast invasion. *Reprod. Med. Rev.* **3**, 53–73.
- Ranheim, T., Staff, A. C., and Henriksen, T. (2001). VEGF mRNA is unaltered in decidual and placental tissues in preeclampsia at delivery. *Acta Obstet. Gynecol. Scand.* **80**, 93–98. doi:10.1034/J.1600-0412.2001.080002093.X
- Redman, C. W., and Sargent, I. L. (2001). The pathogenesis of preeclampsia. *Gynecol. Obstet. Fertil.* **29**, 518–522. doi:10.1016/S1297-9589(01)00180-1
- Roberts, J. M., and Redman, C. W. G. (1993). Pre-eclampsia: more than pregnancy-induced hypertension. *Lancet* **341**, 1447–1451. doi:10.1016/0140-6736(93)90889-O
- Sgambati, E., Marini, M., Zappoli Thyron, G. D., Parretti, E., Mello, G., Orlando, C., Simi, L., Tricarico, C., Gheri, G., and Brizzi, E. (2004). VEGF expression in the placenta from pregnancies complicated by hypertensive disorders. *Br. J. Obstet. Gynaecol.* **111**, 564–570. doi:10.1111/J.1471-0528.2004.00143.X
- Shore, V. H., Wang, T. H., Wang, C. L., Torry, R. J., Caudle, M. R., and Torry, D. S. (1997). Vascular endothelial growth factor, placenta growth factor and their receptors in isolated human trophoblast. *Placenta* **18**, 657–665. doi:10.1016/S0143-4004(97)90007-2
- Taylor, C. M., Stevens, H., Anthony, F. W., and Wheeler, T. (1997). Influence of hypoxia on vascular endothelial growth factor and chorionic gonadotrophin production in the trophoblast-derived cell lines: JEG, Jar and BeWo. *Placenta* **18**, 451–458. doi:10.1016/S0143-4004(97)80047-1
- Terman, B., Dougher-Vermazen, M., Carrion, M. E., Dimitrov, D., Armellino, D. C., Gospodarowicz, D., and Bohlen, P. (1992). Identification of the KDR tyrosine kinase as a receptor for vascular endothelial growth factor. *Biochem. Biophys. Res. Commun.* **187**, 1579–1586. doi:10.1016/0006-291X(92)90483-2
- Torry, D. S., and Torry, R. J. (1997). Angiogenesis and the expression of vascular endothelial growth factor in endometrium and placenta. *Am. J. Reprod. Immunol.* **37**, 21–29.
- Tsatsaris, V., Goffin, F., Munaut, C., Brichout, J. F., Pignon, M. R., Noel, A., Scheaps, J. P., Cabrol, D., Frankenne, F., and Foidart, J. M. (2003). Overexpression of the soluble vascular endothelial growth factor receptor in preeclamptic patients: pathophysiological consequences. *J. Clin. Endocrinol. Metab.* **88**, 5555–5563. doi:10.1210/JC.2003-030528
- Tsokos, M., Longauer, F., Kardosova, V., Gavel, A., Anders, S., and Schulz, F. (2002). Maternal death in pregnancy from HELLP syndrome. A report of three medico-legal autopsy cases with special reference to distinctive histopathological alterations. *Int. J. Legal Med.* **116**, 50–53. doi:10.1007/S00414-001-0276-5
- Vuorela, P., Hatva, E., Lymbaassakis, A., Kaipainen, A., Joukov, V., Persico, M. G., Alitalo, K., and Halmesmaki, E. (1997). Expression of vascular endothelial growth factor and placenta growth factor in human placenta. *Biol. Reprod.* **56**, 489–494. doi:10.1095/BIOLREPROD56.2.489
- Zhou, Y., Damsky, C. H., and Fisher, S. J. (1997). Preeclampsia is associated with failure of human cytotrophoblast to mimic a vascular adhesion phenotype: one cause of defective endovascular invasion in this syndrome? *J. Clin. Invest.* **99**, 2152–2164.
- Zhou, Y., McMaster, M., Woo, K., Janatpour, M., Perry, J., Kortonen, T., Alitalo, K., Damsky, C., and Fisher, S. J. (2002). Vascular endothelial growth factor ligands and receptors that regulate human cytotrophoblast survival are dysregulated in severe preeclampsia and hemolysis, elevated liver enzymes, and low platelets syndrome. *Am. J. Pathol.* **160**, 1405–1423.

Manuscript received 25 September 2006, accepted 23 April 2007