



UNIVERSITÀ
DEGLI STUDI
FIRENZE

FLORE

Repository istituzionale dell'Università degli Studi di Firenze

The association between varicocele, premature ejaculation and prostatitis symptoms: possible mechanisms.

Questa è la Versione finale referata (Post print/Accepted manuscript) della seguente pubblicazione:

Original Citation:

The association between varicocele, premature ejaculation and prostatitis symptoms: possible mechanisms / Lotti F; Corona G; Mancini M; Biagini C; Colpi GM; Innocenti SD; Filimberti E; Gacci M; Krausz C; Sforza A; Forti G; Mannucci E; Maggi M.. - In: JOURNAL OF SEXUAL MEDICINE. - ISSN 1743-6095. - STAMPA. - 6:(2009), pp. 2878-2887.

Availability:

This version is available at: 2158/371805 since:

Terms of use:

Open Access

La pubblicazione è resa disponibile sotto le norme e i termini della licenza di deposito, secondo quanto stabilito dalla Policy per l'accesso aperto dell'Università degli Studi di Firenze (<https://www.sba.unifi.it/upload/policy-oa-2016-1.pdf>)

Publisher copyright claim:

(Article begins on next page)

The Association between Varicocele, Premature Ejaculation and Prostatitis Symptoms: Possible Mechanisms

Francesco Lotti, MD,* Giovanni Corona, MD,** Mario Mancini, MD,[†] Carlo Biagini, MD,[‡] Giovanni M. Colpi, MD,[†] Selene Degli Innocenti, PhD,* Erminio Filimberti, PhD,* Mauro Gacci, MD,[¶] Csilla Krausz, MD,* Alessandra Sforza, MD,** Gianni Forti, MD,* Edoardo Mannucci, MD,[§] and Mario Maggi, MD*

*Andrology Unit, Department of Clinical Physiopathology, University of Florence, Florence, Italy; [†]Andrology and Urology Unit, San Paolo Hospital, Milan, Italy; [‡]Alliance Medical SRL, Prato, Italy; [¶]Department of Urology, University of Florence, Florence, Italy; [§]Diabetes Section Geriatric Unit, Department of Critical Care, University of Florence, Florence, Italy; ^{**}Endocrinology Unit, Maggiore-Bellaria Hospital, Bologna, Italy

Francesco Lotti, MD and Giovanni Corona, MD equally contributed to this article.

DOI: 10.1111/j.1743-6109.2009.01417.x

ABSTRACT

Introduction. No study has ever systematically evaluated the impact of varicocele on sexual function.

Aim. Two cross-sectional studies were performed in patients attending an andrology unit either for male sexual dysfunction (study 1) or couple infertility (study 2). In study 1, we evaluated the impact of varicocele on sexual function. In study 2, we retrospectively evaluated a possible association between varicocele and prostatitis signs and symptoms.

Methods. Study 1 refers to a consecutive series of 2,448 (mean age 52.0 ± 12.9 years) subjects. Study 2 consists of a consecutive series of 139 male subjects (mean age 37.3 ± 6.3).

Main Outcome Measures. In study 1, varicocele was clinically classified into three grades according to Dubin criteria. Different hormonal parameters were also evaluated. All the patients of study 2 underwent simultaneous scrotal and transrectal color-Doppler ultrasonography (CDU) along with seminal characteristics and interleukin-8, a surrogate marker of prostatitis.

Results. After adjusting for age, subjects with severe varicocele ($N = 284$, 11.6%; Dubin grade 2 and 3) showed a reduction of testicular volume ($P < 0.01$), higher luteinizing hormone (LH) ($P < 0.05$), follicle stimulating hormone (FSH) ($P < 0.0001$) and prolactin ($P < 0.05$) levels, and also an enlarged or tender prostate at digito-rectal examination ($P < 0.05$). Premature ejaculation was the only sexual symptoms significantly associated with varicocele (29.2% vs. 24.9% in subjects with or without varicocele, respectively; $P < 0.05$). In study 2, subjects with severe echographic-defined varicocele (basal venous reflux increasing or not after Valsalva's maneuver; $N = 28$, 20.1%) showed CDU features of prostatitis and higher seminal interleukin-8 levels. The presence of any degree of varicocele ($N = 40$, 28.8%) was also associated with prostatitis symptoms, as measured by the National Institutes of Health Chronic Prostatitis Symptom Index scoring ($P < 0.05$), and in particular with the pain domain ($P < 0.05$).

Conclusions. In conclusion, signs and symptoms of prostatitis are more common in varicocele patients, who more often complain of premature ejaculation. **Lotti F, Corona G, Mancini M, Biagini C, Colpi GM, Innocenti SD, Filimberti E, Gacci M, Krausz C, Sforza A, Forti G, Mannucci E, and Maggi M. The association between varicocele, premature ejaculation and prostatitis symptoms: Possible mechanisms. J Sex Med 2009;6:2878–2887.**

Key Words. Varicocele; Premature Ejaculation; Prostatitis

Introduction

Varicocele, defined as the abnormal dilatation of testicular veins and pampiniform plexus, is characterized by retrograde flow in the affected veins [1]. Depending on the screening method, the

estimated incidence of clinically palpable varicocele is 15% in the general male population and 21–39% in subfertile men [2,3]. The possibility to revert infertility through varicocele treatment is under debate [1,3–6]. In fact, although a possible improvement of seminal parameters after

surgical varicocele treatment has been reported [see for review 4,7], a recent meta-analysis does not demonstrate any evidence that varicocele treatment in men from couples with otherwise unexplained subfertility improves the couple's chance of conception [6]. Beyond infertility, traditional indications for varicocele treatment include complaining of symptoms such as scrotal pain, painful swelling, dull scrotal or inguinal heaviness, and perineal discomfort [3,8,9]. However, it should be recognized that all of these symptoms are vague and nonspecific. In fact, they are in some way overlapping with symptoms of different clinical conditions including prostatitis, lower urinary tract symptoms, and/or chronic pelvic pain syndrome [10]. Quite unexpectedly, the relationship between these clinical conditions and varicocele has been poorly studied [11,12]. Lower urinary tract symptoms have been demonstrated to be an independent risk factor for erectile dysfunction (ED) [13], while prostatitis is a well-recognized cause of acquired premature ejaculation [14–18; for review, see 19,20]. Although a few authors have reported an association between ED and varicocele in a limited series of subjects [21,22], no study has systematically evaluated the impact of varicocele on sexual function.

Aim

The aim of the present study is to assess the impact of varicocele on sexual function in a large series of patients consulting for sexual dysfunction in a clinical facility. Results obtained demonstrated a significant association between varicocele, premature ejaculation, and enlarged prostate at digital-rectal examination. Because premature ejaculation has been described more often in subjects with prostatitis [14–18; for review, see 19,20], we retrospectively evaluated, in a second population of subjects attending our unit for male infertility, a possible association between varicocele and prostatitis signs and symptoms.

Patients and Methods

Two cross-sectional studies were performed in patients referring to an andrology unit either for male sexual dysfunction (study 1) or couple infertility (study 2). In study 1, a consecutive series of 2,448 patients attending our outpatient clinic for sexual dysfunction for the first time (from January 2001 to September 2008) was retrospectively studied. Only patients not fluent in Italian were

excluded from the analysis. All patients enrolled underwent the usual diagnostic protocol applied to newly-referred subjects at the andrology outpatient clinic. All the data provided were collected as part of the routine clinical procedure. All patients provided an informed consent to the study. The socio-demographic and clinical characteristics of the sample are summarized in Table 1. Patients were interviewed prior to the beginning of any treatment, and before any specific diagnostic procedures, using the Structured Interview on Erectile Dysfunction (SIEDY) [23]. This is a 13-item interview made up of three scales, which identify and quantify components concurring with sexual dysfunctions. Scale 1 deals with organic disorders, Scale 2 with disturbances in the relationship with a partner, and Scale 3 with psychological traits. Premature ejaculation was defined as ejaculation within 1 minute of vaginal intromission (as reported by the patient) according to previously described criteria [24,25]. Delayed ejaculation was defined as “slowness to ejaculate” (as reported by the patient) according to previously described criteria [25,26]. Hypoactive sexual desire was assessed with question number 14 of SIEDY as previously described [2,27–30]. Patients were asked to complete the Middlesex Hospital Questionnaire, modified (MHQ) [31], a brief self-reported questionnaire for the screening of mental disorders, which provides scores for free-floating anxiety (MHQ-A), phobic anxiety (MHQ-F), obsessive-compulsive traits and symptoms (MHQ-O), somatization (MHQ-S), depressive symptoms (MHQ-D) and hysterical traits and symptoms (MHQ-H).

Main Outcome Measures

All patients underwent a complete physical and andrological examination. The presence of clinical varicocele was bilaterally evaluated by palpation of the venous vessels in the scrotal sac and the observation of each spermatic cord with the patient standing before and during Valsalva's maneuver. Varicoceles were clinically classified into three grades according to Dubin criteria [32]. In particular, grade 1 was defined when varicocele was palpable only during Valsalva's maneuver; grade 2 when varicocele was palpable without Valsalva's maneuver and grade 3 when varicocele was both visible and palpable without Valsalva's maneuver.

Blood samples were drawn in the morning, after overnight fast, for determination of total testosterone (normal range: 10.4–34.6 nmol/L), prolactin,

Table 1 Characteristics of the sample

	All N = 2,448	No varicocele N = 1,819 (74.3%)	Any varicocele N = 629 (25.7%)
Age (years)	51.8 ± 13.1	50.7 ± 13.6	52.2 ± 12.9*
Marital status (%)			
Stable relationship living together	72.9	73.8	70.3
Stable relationship not living together	15.5	15.4	15.9
No stable relationship	11.5	10.8	13.8
Education (%)			
None/primary school	16.1	16.2	15.7
Secondary school	30.5	30.4	30.9
Secondary high school	34.6	34.9	33.6
University	18.8	18.4	19.8
Morbidities (%)			
Current smoker	32.9	33.3	31.8
Hypertension	25.5	25.8	24.8
Diabetes mellitus	25.4	25.8	24.3
Cardiovascular diseases	11.9	12.3	10.8
Clinical and laboratory parameters			
Body mass index (kg/m ²)	26.5 ± 4.1	26.5 ± 4.1	26.6 ± 4.1
Mean testis volume	19.3 ± 4.1	19.4 ± 4.3	19.1 ± 3.7
Log ₁₀ [FSH] (U/L)	0.68 ± 0.35	0.67 ± 0.35	0.68 ± 0.33
Log ₁₀ [LH] (U/L)	0.58 ± 0.28	0.57 ± 0.29	0.59 ± 0.25
Total testosterone (nmol/L)	16.1 ± 6.5	16.1 ± 6.3	16.2 ± 6.9
Log ₁₀ [prolactin] mU/L	2.21 ± 0.26	2.20 ± 0.27	2.22 ± 0.25
Sexual symptoms: number (%)			
Erectile dysfunction	2,211 (90.3)	1,615 (88.8)	596 (94.7)
Hypoactive sexual desire	903 (36.9%)	688 (37.8)	216 (34.4)
Premature ejaculation	637 (26%)	453 (24.9)	184 (29.3) [†]
Delayed ejaculation	157 (6.4%)	118 (6.5)	39 (6.2)
SIEDY scale score			
Scale 1 (organic domain of ED)	3.3 ± 2.5	3.3 ± 3.5	3.2 ± 2.5
Scale 2 (relational domain of ED)	1.9 ± 2.0	1.8 ± 2.0	2.1 ± 2.1 [†]
Scale 3 (intrapsychic domain of ED)	3.4 ± 2.1	3.4 ± 2.2	3.3 ± 2.1

Data are expressed as mean ± SD and as percentages when categorical.

**P* < 0.05.

[†]After adjustment for age.

LH = luteinizing hormone; ED = erectile dysfunction.

FSH, and LH (by elettrochemiluminescent method, Modular Roche, Milan, Italy).

In study 2, a consecutive series of 139 male patients seeking medical care for couple infertility at our outpatient clinic (from January 2008 to March 2009) was retrospectively studied. Only patients not fluent in Italian were excluded from the analysis. All patients enrolled underwent the usual diagnostic protocol applied to newly-referred subjects at the andrology outpatient clinic. All the data provided were collected as part of the routine clinical procedure. All patients provided an informed consent to the study. The socio-demographic and clinical characteristics of this sample are summarized in Table 2. All the patients underwent simultaneous scrotal and transrectal color-Doppler ultrasonography (CDU). In order to prevent bias on the part of the examiner, scrotal and transrectal CDU were performed intermittently by 2 experienced physicians (F.L. and M.M.) unaware of the clinical data.

Varicocele was diagnosed according to Sarteschi criteria [see in 33,34]. In particular, a severe

echographic-defined varicocele (corresponding to Dubin grade 3; [34]) was defined when venous vessels appeared enlarged in the supine position and CDU demonstrated a basal venous reflux increasing or not after Valsalva's maneuver (Sarteschi grade 4 or 5).

All patients attending our outpatient clinic underwent semen analysis according to the World Health Organization criteria (1999) [35]. Furthermore, seminal interleukin-8, a surrogate marker of prostatitis [36] was also measured. Finally, all patients were asked to complete the National Institutes of Health Chronic Prostatitis Symptom Index (NIH-CPSI) [10] in its validated Italian version [37], a brief self-reported questionnaire for the screening of prostatitis symptoms, which provides scores for pain, voiding symptoms, and quality of life.

Data were expressed as mean ± SD when normally distributed, when distribution could be normalized through logarithmic transformation, logarithmically transformed data have been reported. Correlations were assessed using Spear-

Table 2 Characteristics of the sample

	All n = 139	No varicocele n = 99 (71.2%)	Any varicocele n = 40 (28.8%)
Age (years)	37.3 ± 6.3	36.5 ± 5.9	37.9 ± 6.0
Education (%)			
None/primary school	5.4%	6.2	6.4
Secondary school	21.1%	22.1	23.1
Secondary high school	42.3%	45.2	43.4
University	31.2%	26.5	27.1
Morbidities (%)			
Current smoker	42.7%	43.1	41.2
Hypertension	2.2%	1.1	1.1
Diabetes mellitus	1.1%	0.6	0.5
Cardiovascular diseases	1.1%	0.5	0.6
Clinical and laboratory parameters			
Body mass index (kg/m ²)	25.7 ± 3.5	25.3 ± 2.7	25.7 ± 3.8
Log ₁₀ [systolic blood pressure] mmHg	2.01 ± 0.04	2.10 ± 0.03	2.11 ± 0.04
Log ₁₀ [diastolic blood pressure] mmHg	1.91 ± 0.04	1.90 ± 0.04	1.91 ± 0.03
Mean testis volume	17.0 ± 4.6	13.3 ± 4.4	12.7 ± 3.7
Log ₁₀ [interleukin 8] ng/ml	3.5 ± 0.5	3.4 ± 0.4	3.6 ± 0.3
Seminal parameters			
Sperm volume ml	3.0 ± 1.7	2.8 ± 1.6	3.2 ± 1.9
Sperm concentration, ×10 ⁶ /ml	38.8 ± 65.6	37.6 ± 90.9	27.8 ± 51.5
Sperm motility %motile (a + b)	35.5 ± 23.1	26.3 ± 21.2	25.0 ± 18.6
Sperm morphology, % normal forms	12.7 ± 10.5	8.9 ± 8.6	6.7 ± 6.3
NIH-CPSI score			
Total score	3.9 ± 5.9	3.3 ± 5.2	6.0 ± 7.6*
Pain domain (0–21)	1.6 ± 2.9	1.4 ± 2.8	2.9 ± 3.7*
Void domain (0–10)	1.0 ± 1.7	0.6 ± 1.3	1.2 ± 1.9
Quality of life impact (0–12)	1.4 ± 2.3	1.3 ± 2.2	2.0 ± 2.9

Data are expressed as mean ± SD, and as percentages when categorical. NIH-CPSI = National Institutes of Health Chronic Prostatitis Symptom Index. **P* < 0.05.

man's or Pearson's method whenever appropriate. Differences between more than two groups were assessed with one-way ANOVA or Kruskal–Wallis test, whenever appropriate. Unpaired two-sided Student's *t*-tests were used for comparisons of means of normally distributed parameters. In all other cases, Mann–Whitney *U*-test was used for comparisons between groups. Stepwise multiple linear or logistic regressions were applied for multivariate analysis, whenever appropriate. All statistical analysis was performed on SPSS for Windows 15.0.

Results

Study I

Among the patients studied, clinical evidence of varicocele was found in 629 (25.7%) subjects. In particular, a mild varicocele (Dubin grade 1) was detected in 345 (14.1%) patients, while a severe form (Dubin grade 2 and 3) was found in 284 (11.6%). Subjects with any form of varicocele were younger when compared with the rest of the sample (Table 1). In addition, subjects with mild varicocele were younger, while those with the

severe form were older than the rest of the sample (47.6 ± 13.8, 54.5 ± 12.3, 52.2 ± 12.9 years old for mild, severe, or no varicocele, respectively; *P* < 0.0001 at ANOVA). Hence, all the following associations were adjusted for age.

Among all the patients studied, subjects with mild varicocele did not show any difference in testis volume when compared with those without varicocele (19.1 ± 3.1 vs. 19.4 ± 4.3 cc; *P* = NS). Conversely, testis volume was significantly lower in subjects with severe varicocele, even after adjustment for age (Hazard ratio = 1.04[1.01–1.07]; *P* < 0.01 for each millimeter reduction of testis volume). Accordingly, subjects with severe varicocele showed higher LH (Hazard ratio = 1.63[1.01–2.63], *P* < 0.05 for each LH log. unit increment) and FSH (Hazard ratio = 2.84[1.86–4.32]; *P* < 0.0001 for each FSH log. unit increment) when compared with the rest of the sample. In addition, severe varicocele was also associated with higher prolactin levels, when compared with the rest of the sample (Hazard ratio = 1.60[1.03–2.50] for each prolactin log. unit increment; *P* < 0.05). Conversely, testosterone levels were not different in subjects with or without severe varicocele (Figure 1).

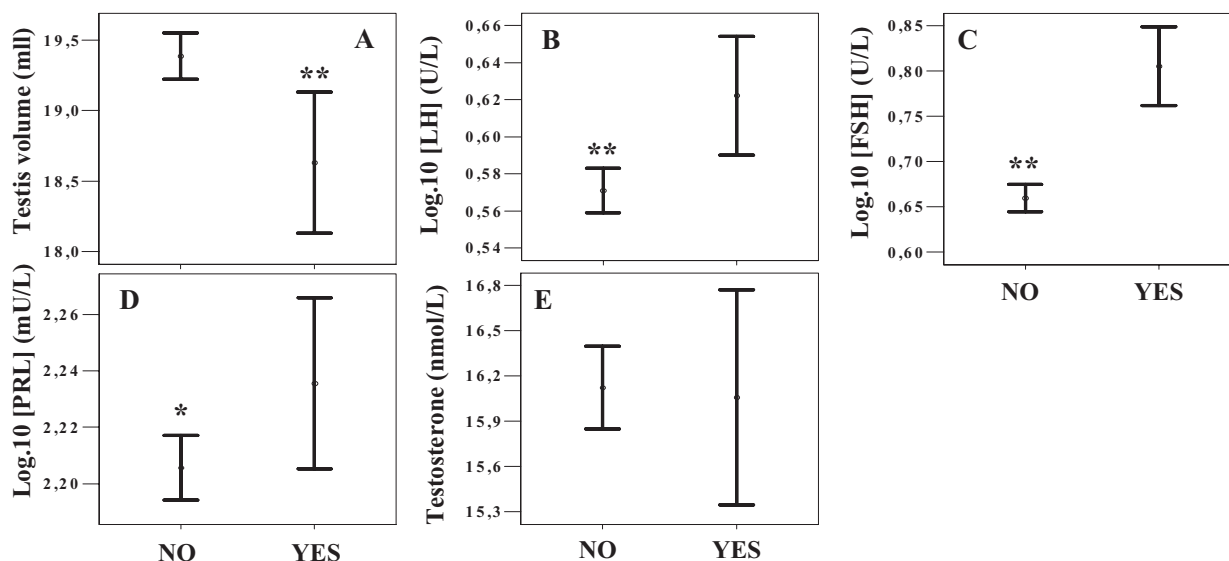


Figure 1 Testis volume (panel A) and hormonal parameters (panels B–E) in subjects with (YES) or without (NO) severe clinical varicocele (Dubin grade 2–3). PRL = prolactin. * $P = 0.05$; ** $P < 0.005$; *** $P < 0.0001$.

Premature ejaculation was the only sexual symptom significantly associated with the presence of clinical varicocele after adjustment for age (Table 1). In particular, the prevalence of premature ejaculation was significantly higher in subjects with any degree of varicocele when compared with the rest of the sample without any differences regarding premature ejaculation severity. In addition, subjects with varicocele more often reported orgasmic impairment in their partner (60.7% vs. 53.3%, $P < 0.005$). All of these associations were confirmed at logistic multivariate analysis after adjustment for confounding factors such as age, anxiety symptoms (as derived from MHQ-A score), and prolactin levels (Hazard ratio = 1.33[1.02–1.74], $P < 0.05$; 1.47[1.15–1.88], $P < 0.005$, respectively for premature ejaculation and partner's climax). In line with these observations, the relational domain of ED, as explored by SIEDY Scale 2 score, was more compromised in subjects with varicocele (Table 1; hazard ratio = 1.06[1.01–1.12]; $P < 0.05$ for each increment of SIEDY Scale 2 score).

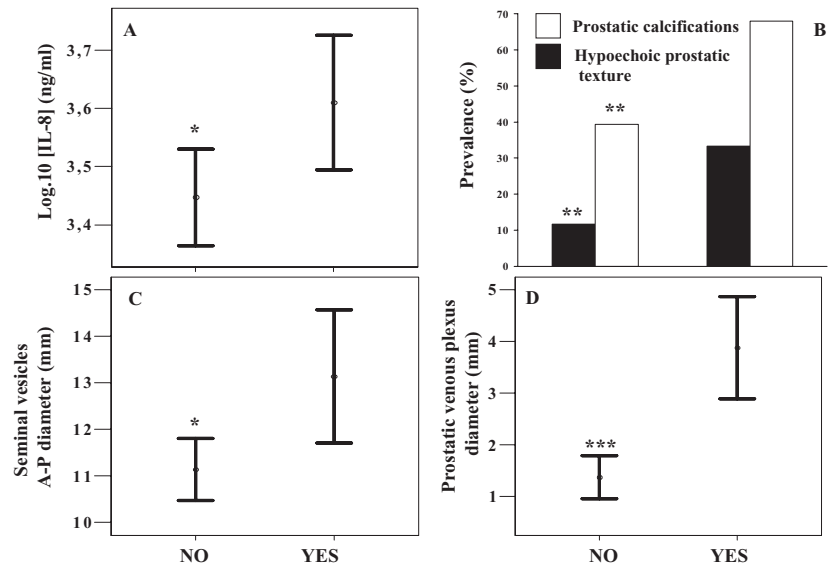
Finally, an abnormal (enlarged or tender) prostate was found more often at digito-rectal examination in subjects with severe varicocele (31.8%, 31.6%, 42.5% for no, mild, or severe varicocele, respectively; Adj $r = 0.06$; $P < 0.05$ after adjustment for age).

The presence of bilateral varicocele did not modify the results obtained (data not shown)

Study 2

In a separate clinical setting (male patients attending our andrology unit for couple infertility), we simultaneously studied prostatic, vesicular, and testicular features, and blood flow by color-Doppler-ultrasound, along with seminal characteristics and interleukin-8. Echographic-defined varicocele was found in 40 (28.8%) subjects, while a severe form (continuous spermatic venous reflux at rest increasing or not during Valsalva maneuver; Sarteschi grade 4 and 5) was observed in 28 (20.1%). No difference between patients with or without severe echographic varicocele was detected in sperm count, motility, and morphology (data not shown). Subjects with severe echographic varicocele showed higher seminal interleukin-8 ($P < 0.05$); in addition they presented a higher prevalence of ultrasound signs of prostatitis, such as hypoechoic prostatic texture ($P < 0.02$), prostatic calcifications ($P < 0.001$), higher seminal vesicle anterior-posterior diameter before ejaculation ($P < 0.05$), and higher prostatic venous plexus diameter ($P < 0.0001$) (Figure 2). All of these associations were confirmed at multivariate analysis after adjustment for age (Hazard ratio = 4.73[1.81–12.41], $P < 0.005$, 3.95[1.62–9.64], $P < 0.005$, 1.17[1.03–1.33], $P < 0.05$ and 1.53[1.27–1.84], $P < 0.0001$, for the presence of prostatic calcification, hypoechoic prostatic texture and for each millimeter increment of anterior-posterior seminal vesicle diameter or prostatic venous plexus

Figure 2 Interleukin-8 (IL-8) levels (panel A), presence of prostatic calcification and hypoechoic prostate texture (panel B), seminal vesicles diameter (panel C) and prostatic venous plexus diameter (panel D), as derived from ultrasound evaluation, in subjects with (YES) or without (NO) severe echographic varicocele (continuous spermatic venous reflux at rest increasing or not during Valsalva maneuver; Sarteschi grade 4 and 5). * $P < 0.05$; ** $P < 0.001$; *** $P < 0.0001$.



diameter, respectively). Venous reflux velocity in the internal spermatic vein correlated with arterial prostatic blood flow peak velocity ($r = 0.312$; $P < 0.005$). No positive association between prostate volume and varicocele was found (data not shown).

The presence of any degree of echographic varicocele was also significantly ($P < 0.05$) associated with symptoms of prostatitis, as measured by NIH-CPSI scoring and in particular with the pain domain (Table 2). These associations were confirmed after adjusting for age (Hazard ratio = 1.06[1.01–1.13], $P < 0.05$ and 1.12[1.00–1.26], $P = 0.05$ for total score and pain domain, respectively).

The presence of bilateral varicocele did not modify the results obtained (data not shown).

Discussion

In the present study, we report for the first time an association between varicocele and premature ejaculation in patients consulting for sexual dysfunction. In particular, premature ejaculation appears to be the only sexual symptom significantly associated with varicocele. Mechanisms linking varicocele with premature ejaculation appear to be complex and difficult to explain. We also confirm the previously reported association of varicocele with prostatitis [11,12] which is a well-known risk factor for premature ejaculation [14–18; for review, see 19,20]. Antibiotic treatment is able to delay ejaculation in patients with premature ejaculation associated with chronic bacterial

prostatitis [38,39]. The exact pathophysiology linking prostatitis and premature ejaculation is unknown. However, it has been proposed that prostatic inflammation may lead to an altered sensation and modulation of the ejaculatory reflex through a neurophysiologic pathway [19,40]. It can be speculated that varicocele, leading to intrapelvic congestion and prostatic inflammation, could be the primum movens for the onset of premature ejaculation, at least in some subjects. It has been reported that varicocele is associated with an underlying systemic venous abnormality [11,41,42], and with an increased diameter of the prostatic venous plexus in particular [43]. In addition, Gat et al. [44] recently demonstrated the presence of a venous blood reflux from the high pressure testicular venous drainage system to the low pressure prostatic drainage system, through a direct communication represented by the deferential vein and the vesicular plexus. It can be speculated that the presence of communication between the testicular and the prostatic venous system might justify a back-flow of venous blood from the testis to the prostate, which can lead to intrapelvic venous congestion. This could facilitate the onset of symptoms of prostatitis. Accordingly, it has been demonstrated that the selective occlusion of impaired venous drainage in the male reproductive system was associated with a reduction in prostate volume and benign-prostatic-hyperplasia-related symptoms [44]. Our findings are in line with this evidence. In fact, subjects with severe echographic varicocele were characterized by increased seminal interleukin-8 levels (a surrogate marker of non-

bacterial prostatitis; [36]) and a higher prevalence of echographic signs of prostate inflammation. In addition, we found an association between the presence of any degree of echographic varicocele and symptoms of prostatitis, as measured by NIH-CPSI scoring [10,37].

The clinical relevance of premature ejaculation should not be underestimated. In fact, although premature ejaculation is the main reason for referral to andrological consultation only in a minority of cases [19,24,25,45], it is a frequent condition in the general population [19,45,46] and it has a relevant impact on quality of life. In fact, premature ejaculation affects the psychosexual equilibrium of the couple [24,47]. Our findings are in line with the latter evidence, showing that subjects with premature ejaculation more often reported an impairment of relational domain and a partner with climax difficulties.

This study shows that varicocele is a further organic condition associated with premature ejaculation, besides hyperthyroidism [24,25,48–50] and chronic prostatitis [14–18; for review, see 19,20]. Hence, any patient with premature ejaculation should be screened for the aforementioned conditions.

Clinical varicocele has been associated with relative testicular hypotrophy [51]. Varicocele treatment may reduce this negative effect [51]. Our data are in line with these findings. In fact, subjects with severe varicocele showed lower testis volume and increased FSH levels (a marker of testicular damage) when compared with the rest of the sample.

The effect of varicocele on Leydig cell function and testosterone biosynthesis is still controversial [52]. Although some authors have reported that serum testosterone levels could be affected by varicocele [53,54] others did not find any correlation [42,51]. In addition, varicocelectomy did not show any effect on testosterone circulating levels [55,56] although only a limited series of subjects was evaluated. In agreement with the latter observations, we did not find any difference in testosterone levels between subjects with or without varicocele, probably due to the observed compensatory increase of LH, as previously reported [51,57,58]. Larger prospective studies are advisable in order to better clarify the relationship between varicocele and Leydig cell function. Finally, in line with other authors [57–60], an increase of prolactin levels was also observed in subjects with varicocele. The imbalance between androgens and oestrogens, due to the condition of

primary hypogonadism derived from the testicular damage could explain, at least partially, this observation [57–60].

Several limitations should be recognized. First of all, it should be clarified that study 1 was performed on patients with sexual dysfunction, and its results cannot be extended to a broader population. In addition, sexual dysfunction, and premature ejaculation in particular, was not investigated in study 2. It should be noted that the patients in study 2 were retrospectively evaluated in order to better clarify the association between varicocele and the enlarged prostate volume observed in study 1. Further prospective studies are advisable to better clarify the relationship between premature ejaculation and varicocele and symptoms of prostatitis. In particular, it should be clarified whether premature ejaculation or signs and symptoms of prostatitis will improve after varicocele repair.

Conclusions

Signs and symptoms of prostatitis are more common in patients with varicocele, who more often complain of premature ejaculation. Premature ejaculation should be considered a marker underlying organic diseases including varicocele, and chronic prostatitis could be the link between the two conditions.

Acknowledgment

We would like to thank Luisa Petrone, Alessandra Fisher, Angela Magini, Riccardo Mansani and Valentina Boddi, Elisa Bandini Andrology Unit of the University of Florence.

Corresponding Author: Prof. Mario Maggi, Andrology Unit, Department of Clinical Physiopathology Viale Pieraccini 6, 50139 Florence, Italy. Tel: +39-55-4271415; Fax: +39-55-4271413; E-mail: m.maggi@dfc.unifi.it

Conflict of Interest: None.

Statement of Authorship

Category 1

(a) Conception and Design

Francesco Lotti; Giovanni Corona; Mario Maggi

(b) Acquisition of Data

Francesco Lotti; Giovanni Corona; Mario Mancini; Giovanni M. Colpi; Carlo Biagini; Csilla Krausz; Selene Degli Innocenti; Erminio Filimberti; Mauro Gacci; Mario Maggi

(c) Analysis and Interpretation of Data

Francesco Lotti; Giovanni Corona; Mario Mancini;
Gianni Forti; Mario Maggi

Category 2**(a) Drafting the Manuscript**

Francesco Lotti; Giovanni Corona; Mario Maggi

(b) Revising It for Intellectual Content

Francesco Lotti; Giovanni Corona; Mario Mancini;
Gianni Forti; Mario Maggi

Category 3**(a) Final Approval of the Completed Manuscript**

Francesco Lotti; Giovanni Corona; Mario Maggi

References

- Forti G, Krausz C. Clinical review 100: Evaluation and treatment of the infertile couple. *J Clin Endocrinol Metab* 1998;83:4177–88.
- Meacham RB, Townsend RR, Rademacher D, Drose JA. The incidence of varicoceles in the general population when evaluated by physical examination, gray scale sonography and color Doppler sonography. *J Urol* 1994;151:1535–8.
- Nieschlag E, Behre HM, Meschede D, Kamischke A. Disorder at the testicular level. Varicocele. In: Nieschlag E, Behre HM, eds. *Andrology: Male reproductive health and dysfunction*. 2nd edition. Berlin: Springer-Verlag Berlin Heidelberg; 2001: 148–52.
- Forti G, Krausz C, Cilotti A, Maggi M. Varicocele and infertility. *J Endocrinol Invest* 2003;26:564–9.
- Ficarra V, Cerruto MA, Liguori G, Mazzoni G, Minucci S, Tracia A, Gentile V. Treatment of varicocele in subfertile men: The Cochrane Review—A contrary opinion. *Eur Urol* 2006;49:258–63.
- Evers JH, Collins J, Clarke J. Surgery or embolisation for varicoceles in subfertile men. *Cochrane Database Syst Rev* 2009;21:479.
- Dohle GR, Colpi GM, Hargreave TB, Papp GK, Jungwirth A, Weidner W, The EAU Working Group on Male Infertility. EAU guidelines on male infertility. *Eur Urol* 2005;48:703–11.
- Khera M, Lipshultz LI. Evolving approach to the varicocele. *Urol Clin North Am* 2008;35:183–9.
- Zampieri N, Ottolenghi A, Camoglio FS. Painful varicocele in pediatric age: Is there a correlation between pain, testicular damage and hormonal values to justify surgery? *Pediatr Surg Int* 2008;24: 1235–8.
- Litwin MS, McNaughton-Collins M, Fowler FJ Jr, Nickel JC, Calhoun EA, Pontari MA, Alexander RB, Farrar JT, O’Leary MP. The National Institutes of Health chronic prostatitis symptom index: Development and validation of a new outcome measure. Chronic Prostatitis Collaborative Research network. *J Urol* 1999;162:369–75.
- Pavone C, Caldarera E, Liberti P, Miceli V, Di Trapani D, Serretta V, Porcu M, Pavone-Macaluso M. Correlation between chronic prostatitis syndrome and pelvic venous disease: A survey of 2,554 urologic outpatients. *Eur Urol* 2000;37:400–3.
- Gattuccio F, Di Trapani D, Romano C, Turtulici B, Milici M, Pavone C, D’Alia O, Alaimo R, Latteri MA. Urogenital inflammations: Aetiology, diagnosis and their correlation with varicocele and male infertility. *Acta Eur Fertil* 1988;19:201–8.
- Rosen R, Altwein J, Boyle P, Kirby RS, Lukacs B, Meuleman E, O’Leary MP, Puppò P, Robertson C, Giuliano F. Lower urinary tract symptoms and male sexual dysfunction: The multinational survey of the aging male (MSAM-7). *Eur Urol* 2003;44:637–49.
- Screponi E, Carosa E, Di Stasi SM, Pepe M, Carruba G, Jannini EA. Prevalence of chronic prostatitis in men with premature ejaculation. *Urology* 2001;58:198–202.
- Liang CZ, Zhang XJ, Hao ZY, Shi HQ, Wang KX. Prevalence of sexual dysfunction in Chinese men with chronic prostatitis. *BJU Int* 2004;93:568–70.
- Gonen M, Kalkan M, Cenker A, Ozkardes H. Prevalence of premature ejaculation in Turkish men with chronic pelvic pain syndrome. *J Androl* 2005; 26:601–3.
- Shamloul R, El-Nashaar A. Chronic prostatitis in premature ejaculation: A cohort study in 153 men. *J Sex Med* 2006;3:150–4.
- Trinchieri A, Magri V, Cariani L, Bonamore R, Restelli A, Garlaschi MC, Perletti G. Prevalence of sexual dysfunction in men with chronic prostatitis/ chronic pelvic pain syndrome. *Arch Ital Urol Androl* 2007;79:67–70.
- Jannini EA, Lenzi A. Ejaculatory disorders: Epidemiology and current approaches to definition, classification and subtyping. *World J Urol* 2005;23: 68–75.
- Schultheiss D. Urogenital infections and male sexuality: Effects on ejaculation and erection. *Andrologia* 2008;40:125–9.
- Comhaire F, Vermeulen A. Plasma testosterone in patients with varicocele and sexual inadequacy. *J Clin Endocrinol Metab* 1975;40:824–9.
- Younes AK. Low plasma testosterone in varicocele patients with impotence and male infertility. *Arch Androl* 2000;45:187–95.
- Petrone L, Mannucci E, Corona G, Bartolini M, Forti G, Giommi R, Maggi M. Structured interview on erectile dysfunction (SIEDY): A new, multidimensional instrument for quantification of pathogenetic issues on erectile dysfunction. *Int J Impot Res* 2003;15:210–20.
- Corona G, Petrone L, Mannucci E, Jannini EA, Mansani R, Magini A, Giommi R, Forti G, Maggi M. Psycho-biological correlates of rapid ejaculation in patients attending an andrologic unit for sexual dysfunctions. *Eur Urol* 2004;46:615–22.

- 25 Corona G, Jannini EA, Mannucci E, Fisher AD, Lotti F, Petrone L, Balercia G, Bandini E, Chiarini V, Forti G, Maggi M. Different testosterone levels are associated with ejaculatory dysfunction. *J Sex Med* 2008;5:1991–8.
- 26 Corona G, Mannucci E, Petrone L, Fisher AD, Balercia G, De Scisciolo G, Pizzocaro A, Giommi R, Chiarini V, Forti G, Maggi M. Psychobiological correlates of delayed ejaculation in male patients with sexual dysfunctions. *J Androl* 2006;27:453–8.
- 27 Corona G, Mannucci E, Petrone L, Giommi R, Mansani R, Fei L, Forti G, Maggi M. Psychobiological correlates of hypoactive sexual desire in patients with erectile dysfunction. *Int J Impot Res* 2004;16:275–81.
- 28 Corona G, Petrone L, Mannucci E, Ricca V, Balercia G, Giommi R, Forti G, Maggi M. The impotent couple: Low desire. *Int J Androl* 2005;28(2 suppl):46–52.
- 29 Corona G, Mannucci E, Fisher AD, Lotti F, Ricca V, Balercia G, Petrone L, Forti G, Maggi M. Effect of hyperprolactinemia in male patients consulting for sexual dysfunction. *J Sex Med* 2007;4:1485–93.
- 30 Corona G, Ricca V, Bandini E, Mannucci E, Petrone L, Fisher AD, Lotti F, Balercia G, Faravelli C, Forti G, Maggi M. Association between psychiatric symptoms and erectile dysfunction. *J Sex Med* 2008;5:458–68.
- 31 Crown S, Crisp AH. A short clinical diagnostic self-rating scale for psychoneurotic patients. The Middlesex Hospital Questionnaire (M.H.Q.). *Br J Psychiatry* 1966;112:917–23.
- 32 Dubin L, Amelar RD. Varicocele size and results of varicolectomy in selected subfertile men with varicocele. *Fertil Steril* 1970;21:606–9.
- 33 Liguori G, Trombetta C, Garaffa G, Bucci S, Gattuccio I, Salamè L, Belgrano E. Color Doppler ultrasound investigation of varicocele. *World J Urol* 2004;22:378–81.
- 34 Isidori AM, Lenzi A. Varicoceles. In: Isidori and Lenzi eds. *Scrotal ultrasound: Morphological and functional atlas*. Genova: Forum Service Editore s.r.l.; 2008:141–56.
- 35 World Health Organization. *WHO Laboratory manual for the examination of human semen and sperm-cervical mucus interaction*. 4th edition. New York: Cambridge University press; 1999.
- 36 Penna G, Mondaini N, Amuchastegui S, Degli Innocenti S, Carini M, Giubilei G, Fibbi B, Colli E, Maggi M, Adorini L. Seminal plasma cytokines and chemokines in prostate inflammation: Interleukin 8 as a predictive biomarker in chronic prostatitis/chronic pelvic pain syndrome and benign prostatic hyperplasia. *Eur Urol* 2007;51:524–33.
- 37 Giubilei G, Mondaini N, Crisci A, Raugei A, Lombardi G, Travaglini F, Del Popolo G, Bartoletti R. The Italian version of the National Institutes of Health Chronic Prostatitis Symptom Index. *Eur Urol* 2005;47:805–11.
- 38 El-Nashaar A, Shamloul R. Antibiotic treatment can delay ejaculation in patients with premature ejaculation and chronic bacterial prostatitis. *J Sex Med* 2007;4:491–6.
- 39 Abdel-Hamid IA, Jannini EA, Andersson KE. Premature ejaculation: Focus on therapeutic targets. *Expert Opin Ther Targets* 2009;13:175–93.
- 40 Jannini EA, Simonelli C, Lenzi A. Disorders of ejaculation. *J Endocrinol Invest* 2002;25:1006–19.
- 41 Callam MJ. Epidemiology of varicose veins. *Br J Urol* 1994;81:167–73.
- 42 Canales BK, Zapzalka DM, Ercole CJ, Carey P, Haus E, Aeppli D, Pryor JL. Prevalence and effect of varicoceles in an elderly population. *Urology* 2005;66:627–31.
- 43 Sakamoto H, Ogawa Y. Is varicocele associated with underlying venous abnormalities? Varicocele and the prostatic venous plexus. *J Urol* 2008;180:1427–31.
- 44 Gat Y, Gornish M, Heiblum M, Joshua S. Reversal of benign prostate hyperplasia by selective occlusion of impaired venous drainage in the male reproductive system: Novel mechanism, new treatment. *Andrologia* 2008;40:273–81.
- 45 Waldinger MD. The neurobiological approach to premature ejaculation. *J Urol* 2002;168:2359–67.
- 46 Nicolosi A, Laumann EO, Glasser DB, Moreira ED Jr, Paik A, Gingell C. Global Study of Sexual Attitudes and Behaviors Investigators' Group. Sexual behavior and sexual dysfunctions after age 40: The global study of sexual attitudes and behaviors. *Urology* 2004;64:991–7.
- 47 Jannini EA, Simonelli C, Lenzi A. Sexological approach to ejaculatory dysfunction. *Int J Androl* 2002;25:317–23.
- 48 Carani C, Isidori AM, Granata A, Carosa E, Maggi M, Lenzi A, Jannini EA. Multicenter study on the prevalence of sexual symptoms in male hypo- and hyperthyroid patients. *J Clin Endocrinol Metab* 2005;90:6472–9.
- 49 Donatucci CF. Etiology of ejaculation and pathophysiology of premature ejaculation. *J Sex Med* 2006;3(4 suppl):303–8.
- 50 Cihan A, Demir O, Demir T, Aslan G, Comlekci A, Esen A. The relationship between premature ejaculation and hyperthyroidism. *J Urol* 2009;181:1273–80.
- 51 Sakamoto H, Ogawa Y. Does a clinical varicocele influence the relationship between the testicular volume by ultrasound and the testicular function in patients with infertility? *Fertil Steril* 2008 [Epub ahead of print].
- 52 Irkilata HC, Yildiz O, Yildirim I, Seyrek M, Basal S, Dayanc M, Ulku C. The vasodilator effect of testosterone on the human internal spermatic vein and its relation to varicocele grade. *J Urol* 2008;180:772–6.
- 53 Su LM, Goldstein M, Schlegel PN. The effect of varicolectomy on serum testosterone levels in

- infertile men with varicoceles. *J Urol* 1995;154:1752–5.
- 54 Cayan S, Kadioglu A, Orhan I, Kandirali E, Tefekli A, Tellaloglu S. The effect of microsurgical varicocelectomy on serum follicle stimulating hormone, testosterone and free testosterone levels in infertile men with varicocele. *BJU Int* 1999;84:1046–9.
- 55 Segenreich E, Shmuely H, Singer R, Servadio C. Andrological parameters in patients with varicocele and fertility disorders treated by high ligation of the left spermatic vein. *Int J Fertil* 1986;31:200–3.
- 56 Pasqualotto FF, Sundaram A, Sharma RK, Borges E Jr, Pasqualotto EB, Agarwal A. Semen quality and oxidative stress scores in fertile and infertile patients with varicocele. *Fertil Steril* 2008;89:602–7.
- 57 Freire FR, Nahoum CR. Endocrine evaluation in infertile men with varicocele. *Andrologia* 1981;13:395–404.
- 58 Mičić S, Dotlić R, Ilić V, Genbačev O. Seminal plasma hormone profile in infertile men with and without varicocele. *Arch Androl* 1986;17:173–8.
- 59 Hudson RW, Perez-Marrero RA, Crawford VA, McKay DE. Hormonal parameters in incidental varicoceles and those causing infertility. *Fertil Steril* 1986;45:692–700.
- 60 Raman JD, Schlegel PN. Aromatase inhibitors for male infertility. *J Urol* 2002;167:624–9.