UNIVERSITÀ DEGLI STUDI FIRENZE

FLORE
Repository istituzionale dell'Università degli Studi di Firenze

Expression of protease-activated receptors 1 and 2 in melanocytic nevi and malignant melanoma

Questa è la Versione finale referata (Post print/Accepted manuscript) della seguente pubblicazione:

Original Citation:

Expression of protease-activated receptors 1 and 2 in melanocytic nevi and malignant melanoma / D. Massi; A. Naldini; C. Ardinghi; F. Carraro; A. Franchi; M. Paglierani; F. Tarantini; S. Ketabchi; G. Cirino; M. D. Hollenberg; P. Geppetti; M. Santucci. - In: HUMAN PATHOLOGY. - ISSN 0046-8177. - STAMPA. - 36:(2005), pp. 676-685.

Availability:

This version is available at: 2158/330217 since:

Terms of use:

Open Access

La pubblicazione è resa disponibile sotto le norme e i termini della licenza di deposito, secondo quanto stabilito dalla Policy per l'accesso aperto dell'Università degli Studi di Firenze (https://www.sba.unifi.it/upload/policy-oa-2016-1.pdf)

Publisher copyright claim:

(Article begins on next page)

12 October 2024

Human Pathology (2005) **36**, 676–685

Human PATHOLOGY

www.elsevier.com/locate/humpath

Expression of protease-activated receptors 1 and 2 in melanocytic nevi and malignant melanoma☆

Daniela Massi MD[a,1], Antonella Naldini PhD[b,1], Camilla Ardinghi PhD[b], Fabio Carraro MD, PhD[b], Alessandro Franchi MD[a], Milena Paglierani PhD[a], Francesca Tarantini MD[c], Sheyda Ketabchi MD[a], Giuseppe Cirino MD[d], Morley D. Hollenberg MD[e], Pierangelo Geppetti MD[c], Marco Santucci MD[a,*]

[a]*Department of Human Pathology and Oncology, University of Florence, 50134 Florence, Italy*
[b]*Department of Physiology, University of Siena, 53100 Siena, Italy*
[c]*Department of Critical Care Medicine and Surgery, University of Florence, 50139 Florence, Italy*
[d]*Department of Experimental Pharmacology, University of Naples, 80131 Naples, Italy*
[e]*Department of Pharmacology and Therapeutics, University of Calgary, T2N 4N1 Calgary, Alberta, Canada*

Received 8 March 2005; accepted 18 April 2005

Keywords:
Protease-activated receptor 1;
Protease-activated receptor 2;
Melanocytic nevi;
Cutaneous melanoma;
Skin;
Ribonuclease protection assay

Summary Protease-activated receptors (PARs) are members of the G protein–coupled receptor superfamily that are activated by the proteolytic cleavage of their amino terminal domain. PAR-1 activation by thrombin results in several biologic effects, including platelet adhesion to other cells or extracellular matrix, fibroblast, and endothelial cell growth, whereas PAR-2, activated by trypsin, has mainly a proinflammmatory and angiogenetic role. PAR-1 and PAR-2 modulate cell proliferation in physiopathologic cell invasion processes, suggesting that they may play a role in the setting of cancer growth and metastasis. Here, we have investigated the expression of PAR-1 and PAR-2 proteins by immunohistochemistry in a series of benign and malignant melanocytic lesions: 20 melanocytic lesions (10 common melanocytic nevi and 10 atypical or "dysplastic" melanocytic nevi) and 50 melanomas (10 in situ melanomas, 10 melanomas T1, 10 melanomas T2, 10 melanomas T3 to T4, and 10 metastatic melanomas). PAR-1 was significantly overexpressed in atypical nevi and melanomas in comparison with common melanocytic nevi. PAR-2 was strongly and diffusely expressed by immunohistochemistry in all melanocytic lesions, with no statistically significant differences between nevi and melanomas. Because we found a differential expression in PAR-1 protein, but not in PAR-2, we next investigated the expression of PAR-1 messenger RNA (mRNA) by ribonuclease protection assay in paraffin-embedded tissues using a paraffin block RNA isolation procedure. Similarly to immunohistochemical results, PAR-1 mRNA expression was significantly higher in atypical nevi and melanomas in comparison with common nevi and controls. Overexpression of PAR-1 in atypical nevi and melanomas supports a role for

☆ This study was financially supported by grants from MIUR (PRIN 2004) to G. C. (2004063945) and to M. S. (2004062950) as well as by funding from Fondazione MPS, Siena, Italy to A. N.

* Corresponding author. Dipartimento di Patologia Umana ed Oncologia, Università degli Studi di Firenze, I-50134 Firenze, Italia.
E-mail address: marco.santucci@unifi.it (M. Santucci).

[1] Daniela Massi and Antonella Naldini equally participated to the study.

0046-8177/$ – see front matter © 2005 Elsevier Inc. All rights reserved.
doi:10.1016/j.humpath.2005.04.008

PAR-1 in the initial phases of melanoma development as well as in tumor progression and metastasis. Conversely, the significance of PAR-2 up-regulation in both benign and malignant melanocytic lesions requires further research.
© 2005 Elsevier Inc. All rights reserved.

1. Introduction

Recently, there has been considerable interest in understanding the biologic significance of protease-activated receptors (PARs) in physiological and pathological conditions, including neoplastic diseases [1,2]. PARs constitute a family of G protein–coupled receptors that show a unique mechanism of activation being enzymatically activated by serine proteases through cleavage of their amino terminal domain. So far, 4 PARs have been cloned, PAR-1 and PAR-3, which are activated by thrombin; PAR-4, which is activated by thrombin and trypsin; and PAR-2, which is activated by trypsin, mast cell tryptase, and coagulation factors [3-7]. PARs are expressed in several tissues by a variety of cells, and their activation is implicated in numerous biologic effects, including coagulation, inflammation, mitogenesis, and cell proliferation [1,2,8].

There is emerging evidence that PAR-1 modulates cell proliferation and motility in physiopathologic cell invasion processes, suggesting that it plays a role in the setting of cancer growth and metastasis [9-13]. Indeed, overexpression of PAR-1 has been detected in numerous human cancers, including colon [14,15], laryngeal [16], breast [10], pancreatic [17,18], and oral cavity carcinomas [19]. Of interest, an up-regulation of PAR-1 and PAR-2 has been demonstrated in stromal fibroblasts surrounding neoplastic aggregates in human malignant tissues [20]. In cutaneous melanomas, it has been recently shown that loss of expression of the transcription factor activator protein 2α correlates with overexpression of PAR-1, which in turn contributes to the acquisition of a malignant phenotype [21]. Less is known concerning the role of PAR-2 in cell growth, although it may also contribute to tumor development and metastasis by stimulating proliferation of neoplastic cells [22]. More recently, it has been reported that both PAR-1 and PAR-2 contribute to tumor cell motility and metastasis [23].

In the development of malignant melanoma, the critical steps of tumor progression were originally postulated as follows: from benign common melanocytic nevi, to atypical, "dysplastic" nevi, to early radial growth phase melanomas (incapable of metastasis), to vertical growth phase invasive melanomas with competence for metastasis to metastatic melanomas [24]. Although it has been suggested that such stepwise melanocytic tumor progression may reflect distinct gene expression patterns and messenger RNA (mRNA) profiles, the exact molecular pathogenetic events underlying the transition from normal melanocytes into various forms of melanocytic nevi and melanomas are not fully understood [25-27]. Great attention has been recently focused on the identification of markers of tumor progression, including growth factors, cell surface antigens, extracellular matrix proteins, and angiogenetic factors, which are differently expressed in common benign nevi, "dysplastic nevi," and in situ, radial, vertical, and metastatic phases of melanomas. However, data on PAR-1 and PAR-2 activity in situ in benign melanocytic nevi, atypical nevi, and human melanoma tissue samples are not available.

To define the possible role of PAR-1 and PAR-2 in melanocytic tumor progression, we evaluated PAR-1 and PAR-2 immunohistochemical expression in benign and malignant melanocytic lesions. Because we found a differential expression in PAR-1 protein, but not in PAR-2 protein, in melanocytic nevi and melanomas, we next sought to confirm these results at mRNA level through analysis of PAR-1 expression by ribonuclease protection assay (RPA) applied to selected archival formalin-fixed paraffin-embedded tissue samples of the same series.

2. Materials and methods

2.1. Specimen selection

The study series included 10 cutaneous common melanocytic nevi; 10 atypical or dysplastic nevi, 10 cutaneous melanomas in situ, 10 pT1 invasive melanomas, 10 pT2 invasive melanomas, 10 pT3 and pT4 invasive melanomas, and 10 subcutaneous melanoma metastases. All samples, with the exclusion of subcutaneous melanoma metastases, showed both tumor and normal adjacent epidermis. For each melanoma case, the patients' charts were analyzed for age at diagnosis, sex, site of the tumor, and disease-specific survival. The median age of patients with melanoma in situ was 43 years (range, 30-63 years). There were 7 women and 3 men. Tumor site distribution was upper and lower extremities (6 cases) and trunk (4 cases). These cases were all superficial spreading melanomas in situ. The median age of patients with primary invasive malignant melanoma was 52 years (range, 32-81 years). Eleven patients were men, and 19 patients were women. Tumor site distribution was as follows: head and neck, 7 patients; upper and lower extremities, 14 patients; trunk, 8 patients; acral regions, 1 patient. Histopathologic slides were reviewed for the following parameters: tumor thickness, level, presence of ulceration, histotype, tumor growth phase (radial versus vertical). Eight cases were Clark level II; 12 cases were level III; 8 cases were level IV, and 2 cases were level V. Eleven cases displayed superficial ulceration. Superficial spreading

melanoma was the most common histological type (63.3%), followed by nodular melanoma (13.4%), lentigo maligna (20%), and acral lentiginous melanoma (3.3%). Seven invasive melanomas were in radial growth phase, whereas 23 melanomas were in vertical growth phase.

2.2. Immunohistochemistry

Sections, 4 μm in thickness, were cut from tissue blocks of formalin-fixed paraffin-embedded tissues obtained from the Department of Human Pathology and Oncology, University of Florence. Slides were deparaffinized in Bio-Clear (Bio-Optica, Milan, Italy) and hydrated with graded ethanol concentrations until distilled water. Tissue sections were immunostained with mouse thrombin R (ATAP 2), also designated PAR-1, monoclonal antibody raised against amino acids 42 to 45 of thrombin receptor of human origin (Santa Cruz Biotechnology, Santa Cruz, Calif) and rabbit PAR-2 polyclonal antibody (B5) prepared as described previously [28]. Unfortunately, none of the available anti–PAR-2 antibodies (eg, B5, SAM11) visualize the receptor on Western blot analyses but identify an unknown non–PAR-2–related epitope (unpublished data). B5, however, reliably identifies the receptor for immunohistochemistry procedures and visualizes PAR-2 from a number of species, including the human and guinea pig [29]. Antigen retrieval was routinely performed by microwave pretreatment (Microwave MicroMED T/T Mega, Milestone, Bergamo, Italy) in TEC (Tris-EDTA-citrate buffer pH 7.8) for 35 minutes. Briefly, endogenous peroxidase activity was blocked by immersing slides in 3.0% hydrogen peroxidase in distilled water for 20 minutes. After blocking nonspecific antigen with normal horse serum (UltraVision, LabVision, Fremont, Calif), the sections were incubated with primary antibody anti–PAR-1 diluted 1:100 in antibody diluent (Ventana Medical Systems, Tucson, Ariz) for 2 hours at room temperature and with primary antibody anti–PAR-2 diluted 1:50 and incubated overnight at 4°C. Staining was achieved using a biotin-conjugated antimouse and antirabbit secondary antibody (UltraVision) and streptavidin-peroxidase (UltraVision). The bound antibodies were visualized with aminoethylcarbazol (AEC, LabVision) as chromogen. Nuclei were slightly counterstained with Mayer's hematoxylin. Negative controls were performed by substituting the primary antibodies with a nonimmune serum at the same concentration. The control sections were treated in parallel with the samples in the same run.

PAR-1 and PAR-2 immunostained sections were independently assessed by 3 observers (D. M., A. F., M. S.). The results were expressed according to semiquantitative criteria as negative staining (score 0), 1% to 20% (score 1+), 21% to 50% of positive cells (score 2+), and more than 50% of positive cells (score 3+). The staining intensity was scored on a scale as weak, moderate, or strong. The level of concordance, expressed as percentage of agreement between the observers, was 92.8% (65/70 specimens). In the remaining 5 cases, unanimous concordance was reached upon revision and discussion.

2.3. Extraction of RNA from formalin-fixed paraffin-embedded sections

Total RNA was extracted using a paraffin block RNA isolation procedure (Ambion, Austin, Tex). Briefly, two 10-μm sections were treated with xylene and incubated for 20 minutes at room temperature. After discarding the xylene, the sections were washed with absolute ethanol and then air-dried at room temperature. Each sample was digested with proteinase K. After total RNA was extracted using an acid phenol–chloroform solution provided by manufacturer; to maximize the recovery of RNA, linear acrylamide was used (Ambion) before precipitation with isopropanol. After centrifugation and washes with ethanol, the RNA pellet was air-dried, resuspended in nuclease-free water, and then analyzed by RPA.

2.4. Ribonuclease protection assay

PAR-1 mRNA levels were evaluated in 35 samples, including normal skin (n = 3), common melanocytic nevi (n = 9), atypical nevi (n = 9), and melanomas (n = 9). These cases had also been examined by immunohistochemistry. Samples were analyzed by RPA. The total RNA, isolated from the formalin-fixed paraffin-embedded sections, as described above, was hybridized overnight to the biotin-labeled RNA probe, which had been previously synthesized from the supplied template set (hAngio-1, RiboQuant multiprobe set; BD Biosciences, San Jose, Calif). Hybridization was followed by RNase A/T1 and proteinase K digestion, as previously described [30]. Subsequently, the products separated for analysis on a denaturing polyacrylamide (5%) gel. Gels were then transferred to a positively charged nylon membrane, using a semidry transfer unit (Hoefer Pharmacia Biotech, San Francisco, Calif). The nucleic acids were then immobilized by UV cross-linking. Nonisotopic detection was performed by BrightStar BioDetect kit (Ambion), following manufacturer's instructions.

Table 1 Distribution of PAR-1 expression in common nevi, atypical nevi and malignant melanoma (n = 70)

Cases	Score			
	0	1+	2+	3+
Common melanocytic nevi (n = 10)	2	2	3	3
Atypical nevi (n = 10)			1	9
In situ melanomas (n = 10)				10
T1 melanomas (n = 10)				10
T2 melanomas (n = 10)				10
T3-T4 melanomas (n = 10)				10
Melanoma metastases (n = 10)				10

Score 0 indicates negative staining; 1+, 1%-20% of positive cells; 2+, 21%-50% of positive cells; 3+, more than 50% of positive cells.

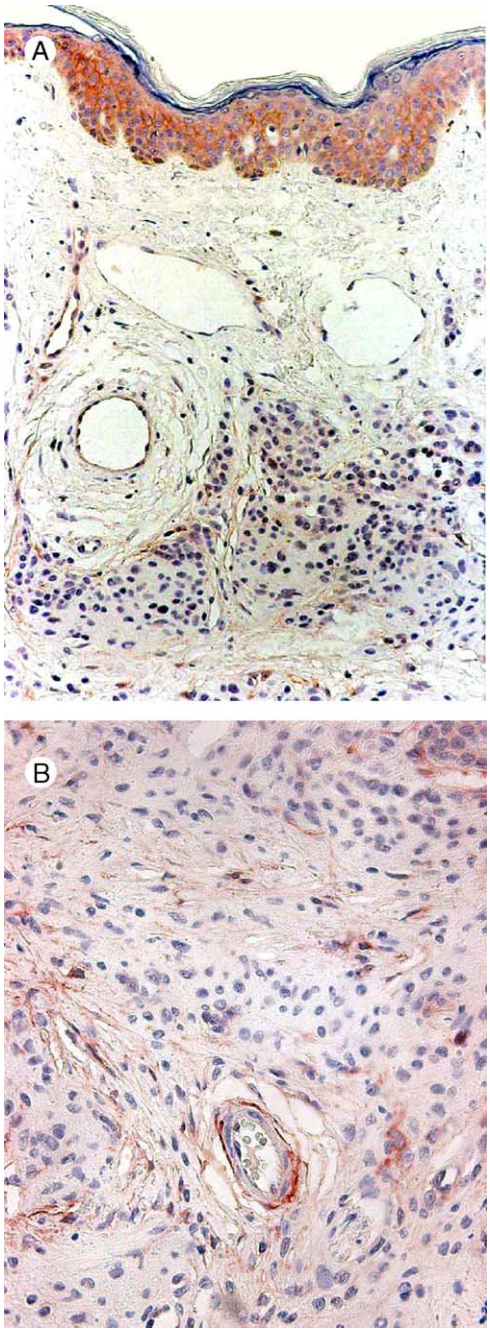

Fig. 1 (A) PAR-1 immunoreactivity in benign common melanocytic nevus. Clusters of nevus cells are negative, whereas PAR-1 is strongly and diffusely expressed in basal and suprabasal epidermal keratinocytes. (B) Note the positive staining in pericytes around the vessel wall.

PAR-1 and the housekeeping gene L32 transcripts were identified by the lengths of the respective fragments. Gel electrophoretic autoradiographs were then quantified using Sigma Gel analysis software (Jandel Scientific, San Rafael, CA). PAR-1 values were expressed as a percentage of L32 expressed for each sample (relative area units).

2.5. Statistical analysis

Differences between data groups were analyzed using the nonparametric Kruskal-Wallis analysis of variance followed by the Bonferroni test. The relationship between PARs protein expression and clinicopathologic variables was assessed by the 2-tailed Fisher exact test or by the Pearson χ^2 method. A P value of <.05 was considered statistically significant. Statistical analysis was performed with the SPSS software, release 9.0 (SPSS Inc, Chicago, Ill).

3. Results

3.1. Immunohistochemical analysis

PAR-1 immunohistochemical expression was confined to the cells' cytoplasm, with occasional peripheral membrane pattern, whereas evaluation of PAR-2 immunoreactions displayed predominantly cytoplasmic with occasional cell membrane and nuclear staining in normal as well as in tumor cells.

In normal skin adjacent to melanocytic lesions, PAR-1 was strongly and diffusely expressed in basal and suprabasal epidermal keratinocytes but not in the granular layer or in the stratum corneum. PAR-1 positivity was also consistently observed in the inner root sheath of hair follicles,

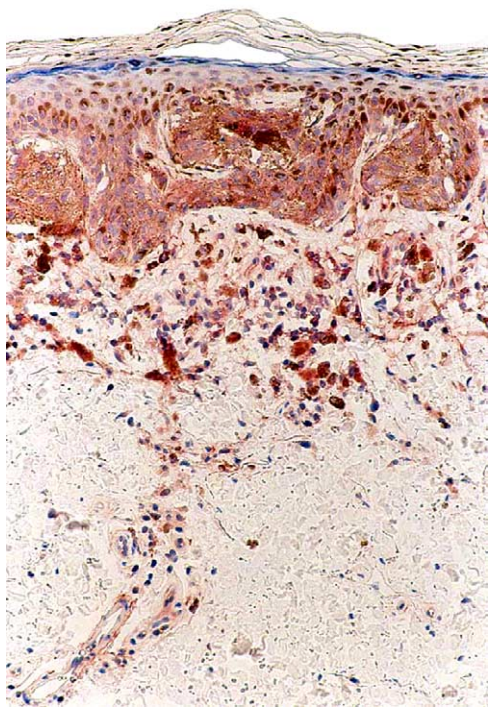

Fig. 2 PAR-1 immunoreactivity in dysplastic melanocytic nevus. Atypical melanocytes are arranged in nests at the dermoepidermal junction and show strong and diffuse cytoplasmic PAR-1 staining. Scattered macrophages and spindle-shaped fibroblasts beneath the lesion are also positive.

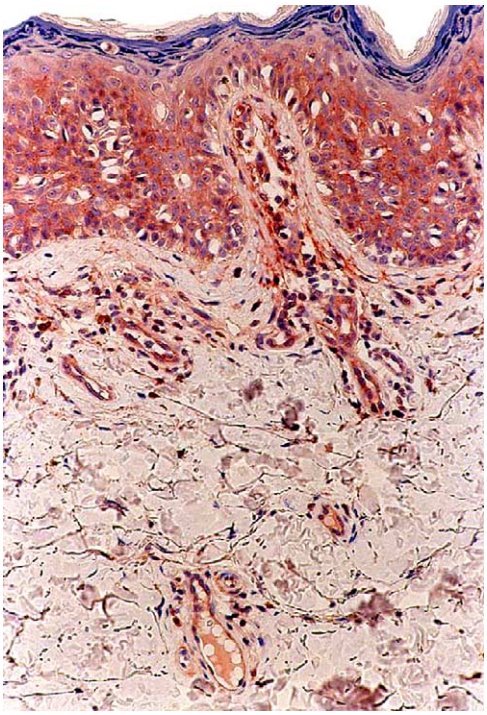

Fig. 3 PAR-1 immunoreactivity in malignant melanoma in situ. PAR-1–positive strikingly atypical melanocytes in single units are seen at the junction and in pagetoid spread within the epidermis.

myoepithelial cells of sweat glands, sebaceous glands, and blood vessels. Interestingly, immunostaining of blood vessels showed a stronger labeling in pericytes (vascular smooth muscle cells) in comparison with endothelial cells. In some specimens, blood vessels of the superficial capillary plexus were consistently reactive for PAR-1, whereas vascular structures more deeply located in the reticular dermis, far from the tumor, decreased their immunostaining, indicating a modulation of PAR-1 expression in endothelial cells. Scattered dermal fibroblasts and macrophages were also PAR-1–positive. Lymphocytes were PAR-1–negative.

PAR-2 immunoreactivity was predominantly localized to the basal and suprabasal spinous layers, whereas the upper superficial layers were unstained. Endothelial cells of superficial dermal blood vessels also stained positive. Strong PAR-2 staining was detected throughout adnexal (hair follicular and eccrine) structures. Stromal fibroblasts, macrophages, and mast cells stained positive.

Normal epidermal melanocytes generally did not express either PAR-1 or PAR-2, although in some specimens, occasional melanocytes showed a faint cytoplasmic positivity. The immunolabeling in normal epidermal melanocytes was found at times difficult to evaluate because of the presence of a perinuclear clear halo resulting from marked cytoplasmic retraction.

Table 1 summarizes the results of PAR-1 immunostaining in the whole series of 70 benign and malignant cutaneous melanocytic lesions categorized according to semiquantitative criteria. The mean percentages of PAR-1 immunoreactive neoplastic cells in benign and malignant melanocytic lesions were as follows: common melanocytic nevi, 35% ± 24.61%; atypical melanocytic nevi, 86% ± 22.21%; melanoma in situ, 79% ± 8.76%; T1 invasive melanoma, 95% ± 9.72%; T2 invasive melanoma, 97% ± 9.49%; T3 to T4 invasive melanoma, 94% ± 15.78%; and melanoma metastases, 95% ± 7.07%. When all cutaneous melanoma samples (in situ, invasive, and metastatic) were grouped together for statistical analysis, the mean percentage of PAR-1 expression was 92% ± 12.12%.

Overall, common melanocytic nevi (Fig. 1) displayed significantly less PAR-1 immunostaining in comparison with atypical nevi and melanoma samples. Most atypical nevi (Fig. 2) displayed a staining pattern in terms of distribution similar to that of in situ (Fig. 3), invasive melanomas (Figs. 4 and 5), and melanoma metastases (Fig. 6). Regarding the intensity of the immunostaining, in cutaneous invasive melanoma samples and melanoma metastases, neoplastic cells were strongly PAR-1–positive, whereas the intensity of staining was weak in common nevi and mostly moderate in atypical nevi and in situ melanomas. However, in some invasive melanomas, we observed that neoplastic melanocytes in their progressive descent into the deeper portions of the reticular dermis showed a progressive decrease in PAR-1 immunoreactivity. PAR-1 staining intensity in stromal fibroblasts and macrophages surrounding

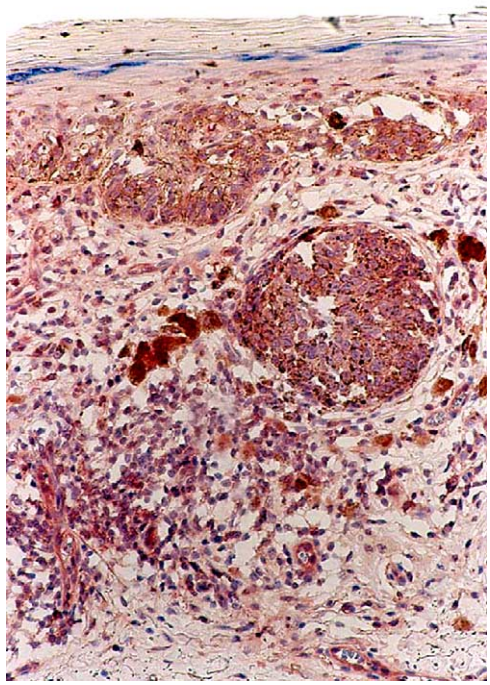

Fig. 4 Strong and diffuse PAR-1 staining in neoplastic melanocytes in a thin cutaneous melanoma. Note that stromal macrophages, fibroblasts, and endothelial cells in the areas of regression around the tumor are strongly positive.

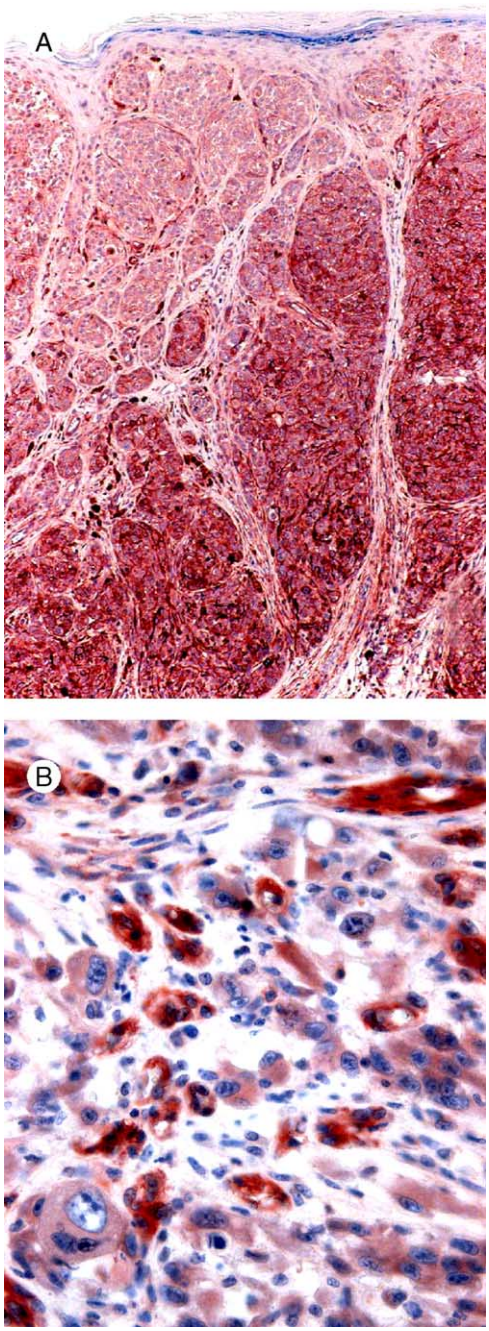

Fig. 5 (A) Intense and diffuse PAR-1 immunoreactivity in thick invasive cutaneous melanoma. (B) The PAR-1–positive reaction is evident also in the endothelial cells of microvessels inside the tumor.

melanoma cells was not significantly different in comparison with dermal fibroblasts and macrophages adjacent to normal epidermis.

Statistical analysis showed that PAR-1 was significantly overexpressed in atypical nevi and melanomas in comparison with common melanocytic nevi ($P < .001$) (Fig. 7). Conversely, PAR-2 was strongly and diffusely expressed by immunohistochemistry in all benign and malignant

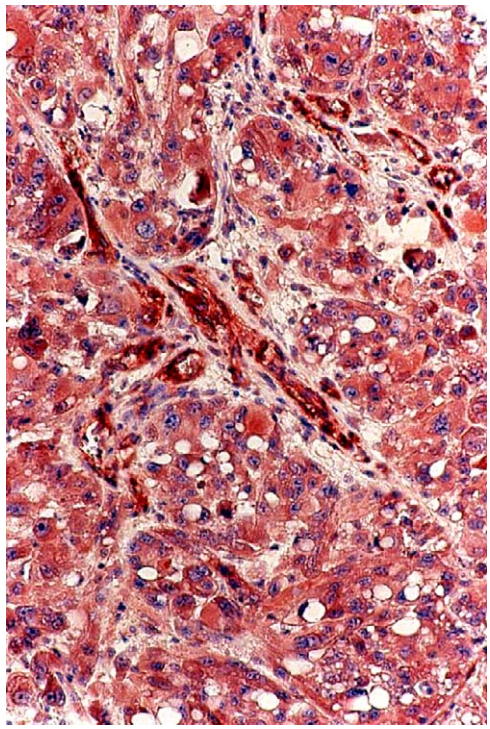

Fig. 6 Intense and diffuse cytoplasmic PAR-1 staining in subcutaneous melanoma metastasis.

melanocytic lesions, with no statistically significant differences between nevi and melanomas (Figs. 8 and 9).

Concerning invasive melanomas, no significant correlation was found between PAR-1 or PAR-2 expression and both disease-specific survival and histopathologic parameters, such as histotype, level, thickness, presence of regression, and tumor growth phase.

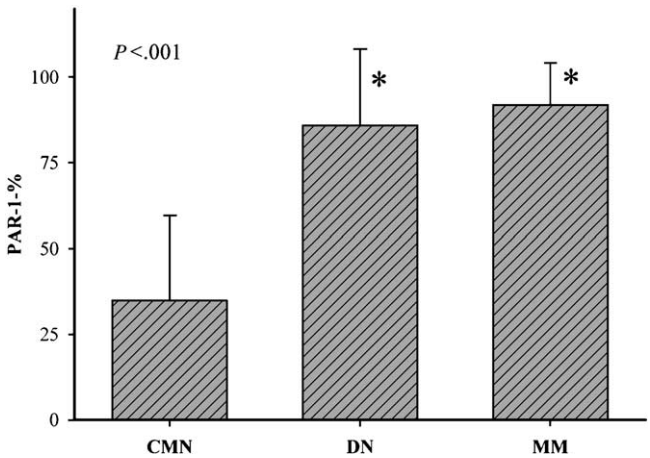

Fig. 7 Percentage of PAR-1 cytoplasmic staining in tissue samples of common melanocytic nevi (CMN), dysplastic nevi (DN), and malignant melanomas (MM). PAR-1 resulted significantly overexpressed in DN and MM in comparison with CMN ($P < .001$).

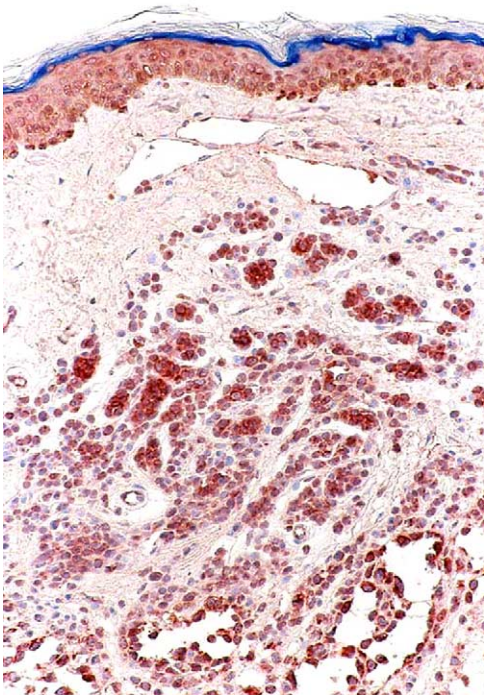

Fig. 8 Strong and diffuse PAR-2 cytoplasmic and nuclear immunoreactivity in benign common melanocytic nevus. PAR-2 immunoreactivity is also localized to the basal and suprabasal spinous epidermal layers.

3.2. PAR-1 mRNA expression

RPA analysis showed that PAR-1 mRNA levels were significantly higher in samples of atypical nevi (28 ± 3) and melanoma (27 ± 4) in comparison with common melanocytic nevi (18 ± 3), as reported in Fig. 10. It is evident that no significant differences were found in PAR-1 mRNA expression between common melanocytic nevi (18 ± 3) and normal skin samples (16 ± 2). No significant differences were observed between PAR-1 mRNA expressed in melanoma in situ and invasive melanoma (data not shown). On the basis of the results of the immunohistochemical study, the PAR-1 mRNA signal observed in common melanocytic nevi and controls samples (normal skin) may be ascribed to the presence of PAR-1 transcript within the epidermal and adnexal keratinocytes and other PAR-1–positive stromal cells.

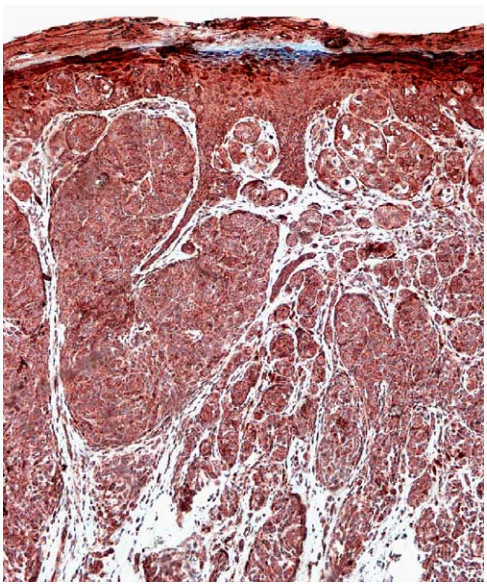

Fig. 9 Most neoplastic cells stain strongly for PAR-2 in thick cutaneous melanoma.

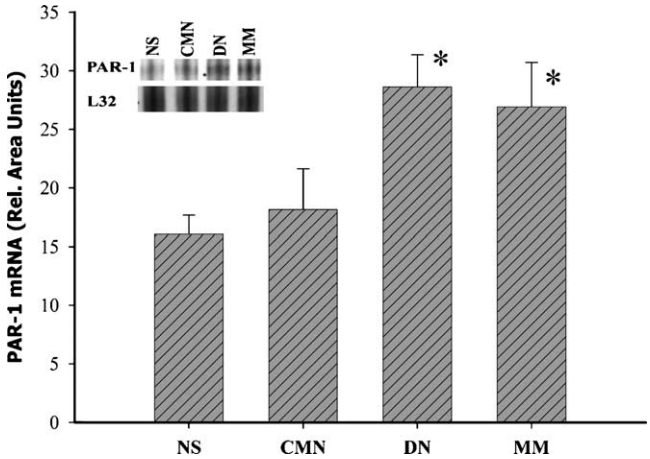

Fig. 10 PAR-1 mRNA expression in human melanocytic lesions by RPA. The blot shown in the figure is one representative of multiple blots obtained in independent experiments with similar results. PAR-1 mRNA expression values are shown as a percentage of the housekeeping gene L32 present in each sample (relative area units). The data obtained are presented as means ± SD. Asterisks indicate statistically significant ($P < .05$) differences between PAR-1 mRNA expressed by dysplastic nevi (DN, n = 9) and malignant melanoma (MM, n = 9) versus common melanocytic nevi (CMN, n = 9), as judged by Student *t* test and the Bonferroni correction. Results regarding PAR-1 mRNA expression in normal skin (NS, n = 3) are also reported. DN and MM show higher levels of PAR-1 mRNA in comparison with CMN. The low PAR-1 mRNA signal observed in CMN and NS may be ascribed to the presence of PAR-1 mRNA within the epidermal and adnexal keratinocytes.

4. Discussion

Our results indicate that PAR-1 is overexpressed in dysplastic nevi as well as in primary and metastatic melanomas in comparison with benign common nevi, thus supporting a critical role for PAR-1 in the initial phases of melanocytic tumor transformation and progression. To the best of our knowledge, this is the first evidence of PAR-1 in situ expression in human tissue samples of cutaneous melanocytic nevi and malignant melanoma. PAR-2 protein was also highly up-regulated in all melanocytic lesions. However, no significant difference between nevi and melanomas regarding PAR-2 expression was observed. These findings support and expand previous observations

that PAR-1 expression is up-regulated in the human metastatic cell line A375SM [12]. It has been previously shown that in human melanoma cells, loss of the transcription factor activator protein 2α contributes to PAR-1 up-regulation, eventually contributing to the acquisition of the metastatic phenotype [31,32].

The mechanisms by which PAR-1 affects melanoma development and progression are complex and yet to be fully clarified. PAR-1 has been demonstrated to modulate the distribution of cell-surface $\alpha v\beta 5$ integrins promoting cytoskeletal reorganization, a key step in the processes of invasion and metastasis [32]. Furthermore, the activation of PAR-1 contributes to tumor angiogenesis through increased expression of vascular endothelial growth factor mRNAs and of functional vascular endothelial growth factor proteins [32]. PAR-1 also regulates the induction and release of matrix metalloproteinases, including matrix metalloproteinases 1, 2, 3, and 9, enzymes involved in the proteolytic degradation of components of the basement membrane and extracellular matrix [19,33]. PAR-1 has also been attributed a putative oncogenic role in NIH3T3 cells [34], and we have previously reported that thrombin down-regulates the expression of $p21^{waf1/cip1}$ and up-regulates cyclin D1 mRNA expression, thus contributing to unrestricted proliferation in certain tumor cells lines [35].

In our study, the immunolocalization of PAR-1 and PAR-2 was largely found in tumor cells and also in epidermal and adnexal keratinocytes, scattered fibroblasts, macrophages, and endothelial cells in the adjacent stroma, providing evidence that both neoplastic and stromal cells are the sources of PARs in tumor tissues. It is conceivable that, in the tumor microenvironment, dynamic host-tumor interactions modulate PARs activity in the progression of human tumors, including malignant melanomas. However, no significant difference was noted in terms of PAR-1 and PAR-2 staining intensity in dermal fibroblasts and macrophages surrounding melanoma cells in comparison with those located in proximity of the normal epidermis, far away from tumor cells. Furthermore, dermal fibroblasts in normal skin and in benign common melanocytic nevi were also PAR-1– and PAR-2–positive. These findings are at variance with previous observations indicating PAR-2 negativity in normal dermal fibroblasts [36,37] as well as absence of PAR-1 and PAR-2 immunolabeling in stromal fibroblasts surrounding normal and breast benign tissues in contrast with the moderate to strong PAR-1 and PAR-2 staining observed in the stromal fibroblasts in most breast malignant tissues [20]. One possible explanation for our findings could be that resident dermal fibroblasts have acquired a myofibroblastic phenotype. PAR-1 and PAR-2 marked expressions have been documented in smooth muscle cells in a variety of human tissues [37-39].

A major finding of our study is the up-regulation of PAR-1 expression in atypical so-called dysplastic nevi in comparison with common melanocytic nevi. This result suggests that early melanocytic transformation is associated with the induction of PAR-1 gene expression and supports the hypothesis that atypical dysplastic nevi represent not only a risk factor but a true precursor of cutaneous melanomas. However, in spite of a wide amount of epidemiological, clinical, and biologic data accumulated on this hypothesis, several issues remain unresolved regarding melanocytic dysplasia: (*a*) lack of a uniformly recognized terminology, (*b*) significant interobserver variability in the criteria for histopathologic diagnosis, (*c*) absence of well-defined dysplastic features associated to most malignant melanomas, and (*d*) a limited understanding of the clinical significance of a diagnosis of dysplasia, in terms of actual risk and time frame of progression to melanoma. Further studies aimed to determine the biologic differences between cells from different stages of melanocytic tumor progression are clearly needed to gain more insight into the tumor biology of cutaneous melanoma.

Results of PAR-1 protein immunohistochemical expression in melanocytic lesions were corroborated by PAR-1 mRNA study with the RPA technique on formalin-fixed paraffin-embedded specimens. RPA confirmed immunohistochemical results showing overexpression of PAR-1 mRNA in atypical nevi as well as in malignant melanomas in comparison with benign common nevi. Maximum mRNA expression was already detected in dysplastic nevi, as it remained constant in all the other instances irrespective of increased level malignancy. In addition, no significant differences were found in PAR-1 mRNA levels between common melanocytic nevi and normal skin samples. The PAR-1 mRNA signal observed in common melanocytic nevi and normal skin specimens may be ascribed to the presence of PAR-1 transcript within the epidermal and adnexal keratinocytes and other PAR-1–positive stromal cells, as shown by the immunohistochemical study.

The biologic significance of PAR-2 up-regulation in both benign and malignant melanocytic lesions requires further investigation. It is known that PAR-2 is implicated in a broad spectrum of physiopathologic processes, including cell growth, mitogenesis, and angiogenesis [1,2]. Recently, considerable interest has been paid to the role of PAR-2 in cutaneous pigmentation. Indeed, in keratinocyte-melanocyte cocultures, PAR-2 activation increases the phagocytosis of melanosomes by keratinocytes and thereby plays a crucial role in pigmentation [40,41]. Because melanocytic nevi of different type contain variable melanin granules, we could speculate that PAR-2 overexpression may be functionally relevant to nevi pigmentation.

In conclusion, our results demonstrate for the first time an overexpression of PAR-1 in atypical nevi and malignant melanoma in comparison with benign common melanocytic nevi, suggesting that PAR-1 is likely to play a crucial role in the initial phases of melanoma development as well as in tumor progression and metastasis. Conversely, the significance of PAR-2 up-regulation in both benign and malignant melanocytic lesions represents an intriguing issue for further research.

References

[1] MacFarlane SR, Seatter MJ, Kanke T, Hunter GD, Plevin R. Proteinase-activated receptors. Pharmacol Rev 2001;53:245-82.

[2] Ossovskaya VS, Bunnett NW. Protease-activated receptors: contribution to physiology and disease. Physiol Rev 2004;84: 579-621.

[3] Vu TK, Hung DT, Wheaton VI, Coughlin SR. Molecular cloning of a functional thrombin receptor reveals a novel proteolytic mechanism of receptor activation. Cell 1991;64:1057-68.

[4] Nystedt S, Emilsson K, Wahlestedt C, Sundelin J. Molecular cloning of a potential proteinase activated receptor. Proc Natl Acad Sci U S A 1994;91:9208-12.

[5] Bohm SK, Kong W, Bromme D, Smeekens SP, Anderson DC, Connolly A, et al. Molecular cloning, expression and potential functions of the human proteinase–activated receptor-2. Biochem J 1996;314:1009-16.

[6] Ishihara H, Connolly AJ, Zeng D, Kahn ML, Zheng YW, Timmons C, et al. Protease-activated receptor 3 is a second thrombin receptor in humans. Nature 1997;386:502-6.

[7] Xu WF, Andersen H, Whitmore TE, Presnell SR, Yee DP, Ching A, et al. Cloning and characterization of human protease–activated receptor 4. Proc Natl Acad Sci U S A 1998;95:6642-6.

[8] Vergnolle N, Wallace JL, Bunnett NW, Hollenberg MD. Protease-activated receptors in inflammation, neuronal signaling and pain. Trends Pharmacol Sci 2001;22:146-52.

[9] Even-Ram S, Uziely B, Cohen P, Grisaru-Granovsky S, Maoz M, Ginzburg Y, et al. Thrombin receptor overexpression in malignant and physiological invasion processes. Nat Med 1998;4: 909-14.

[10] Henrikson KP, Salazar SL, Fenton II JW, Pentecost BT. Role of thrombin receptor in breast cancer invasiveness. Br J Cancer 1999;79: 401-6.

[11] Kamath L, Meydani A, Foss F, Kuliopulos A. Signaling from protease-activated receptors-1 inhibits migration and invasion of breast cancer cells. Cancer Res 2001;61:5933-40.

[12] Even-Ram SC, Maoz M, Pokroy E, Reich R, Katz BZ, Gutwein P, et al. Tumor cell invasion is promoted by activation of protease-activated receptor-1 in cooperation with $\alpha 5\beta 1$ integrin. J Biol Chem 2001;276:10952-62.

[13] Yin YJ, Salah Z, Grisaru-Granovsky S, Cohen I, Even-Ram SC, Maoz M, et al. Human protease–activated receptor 1 expression in malignant epithelia. Role of invasiveness. Arterioscler Thromb Vasc Biol 2003; 23:940-4.

[14] Wojtukiewicz MZ, Tang DG, Ben-Josef E, Renaud C, Walz DA, Honn KV. Solid tumor cells express functional "tethered ligand" thrombin receptor. Cancer Res 1995;55:698-704.

[15] Darmoul D, Gratio V, Devaud H, Lehy T, Laburthe M. Aberrant expression and activation of the thrombin receptor protease-activated-1 induces cell proliferation and motility in human colon cancer cells. Am J Pathol 2003;162:1503-13.

[16] Kaufmann R, Schafberg H, Rudroff C, Nowak G. Thrombin receptor activation results in calcium signalling and protein kinase C–dependent stimulation of DNA synthesis in Hep-2g laryngeal carcinoma cells. Cancer 1997;80:2068-74.

[17] Rudroff C, Schafberg H, Nowak G, Weinel R, Scheele J, Kaufmann R. Characterization of functional thrombin receptors in human pancreatic tumor cells (MIA PACA-2). Pancreas 1998;16: 189-94.

[18] Rudroff C, Seibold S, Kaufmann R, Zetina CC, Reise K, Schafer U, et al. Expression of the thrombin receptor PAR-1 correlates with tumour cell differentiation of pancreatic adenocarcinoma in vitro. Clin Exp Metastasis 2002;19:181-9.

[19] Liu Y, Gilcrease MZ, Henderson Y, Yuan XH, Clayman GL, Chen Z. Expression of protease-activated receptor-1 in oral squamous cell carcinoma. Cancer Lett 2001;169:173-80.

[20] D'Andrea MR, Derian CK, Santulli RJ, Andrade-Gordon P. Differential expression of protease-activated receptors-1 and -2 in stromal fibroblasts of normal, benign, and malignant human tissues. Am J Pathol 2001;158:2031-41.

[21] Tellez C, McCarty M, Ruiz M, Bar-Eli M. Loss of activator protein-2α results in overexpression of protease-activated receptor-1 and correlates with the malignant phenotype of human melanoma. J Biol Chem 2003;278:46632-42.

[22] Darmoul D, Marie JC, Devaud H, Gratio V, Laburthe M. Initiation of human colon cancer cell proliferation by trypsin acting at protease-activated receptor-2. Br J Cancer 2001;85:772-9.

[23] Shi X, Gangadharan B, Brass LF, Ruf W, Mueller BM. Protease-activated receptors (PAR1 and PAR2) contribute to tumor cell motility and metastasis. Mol Cancer Res 2004;2:395-402.

[24] Clark Jr WH, Elder DE, Guerry IV D, Epstein MN, Greene MH, Van Horn M. A study of tumor progression: the precursor lesions of superficial spreading and nodular melanoma. HUM PATHOL 1984;15:1147-65.

[25] Meier F, Satyamoorthy K, Nesbit M, Hsu MY, Schittek B, Garbe C, et al. Molecular events in melanoma development and progression. Front Biosci 1998;3:1005-10.

[26] Bar-Eli M. Gene regulation in melanoma progression by the AP-2 transcription factor. Pigment Cell Res 2001;14:78-85.

[27] Meije CB, Hakvoort TBM, Swart GWM, Westerhof W, Lamers WH, Das PK. Gene expression patterns in melanocytic cells: candidate markers for early stage and malignant transformation. J Pathol 2002; 196:51-8.

[28] Al-Ani B, Saifeddine M, Kawabata A, Renaux B, Mokashi S, Hollenberg MD. Proteinase-activated receptor 2 (PAR(2)): development of a ligand-binding assay correlating with activation of PAR(2) by PAR(1)- and PAR(2)-derived peptide ligands. J Pharmacol Exp Ther 1999;290:753-60.

[29] Saifeddine M, Al-Ani B, Sandhu S, Wijesuriya SJ, Hollenberg MD. Contractile actions of proteinase-activated receptor-derived polypeptides in guinea-pig gastric and lung parenchymal strips: evidence for distinct receptor systems. Br J Pharmacol 2001;132: 556-66.

[30] Naldini A, Carraro F. Hypoxia modulates cyclin and cytokine expression and inhibits peripheral mononuclear cell proliferation. J Cell Physiol 1999;181:448-54.

[31] Tellez C, Bar-Eli M. Role and regulation of the thrombin receptor (PAR-1) in human melanoma. Oncogene 2003;22:3130-7.

[32] Yin YJ, Salah Z, Maoz M, Cohen Even-Ram S, Ochayon S, Neufeld G, et al. Oncogenic transformation induces tumor angiogenesis: a role for PAR-1 activation. FASEB J 2003;17:163-74.

[33] Wilson SR, Gallagher S, Warpeha K, Hawthorne SJ. Amplification of MMP-2 and MMP-9 production by prostate cancer cell lines via activation of protease-activated receptors. Prostate 2004;60: 168-74.

[34] Martin CB, Mahon GM, Klinger MB, Kay RJ, Symons M, Der CJ, et al. The thrombin receptor, PAR-1, causes transformation by activation of Rho-mediated signalling pathways. Oncogene 2001; 20:1953-63.

[35] Naldini A, Carney DH, Pucci A, Carraro F. Human alpha-thrombin stimulates proliferation of interferon-gamma differentiated, growth-arrested U937 cells, overcoming differentiation-related changes in expression of $p21^{cip1/waf1}$ and cyclin D1. J Cell Physiol 2002;191: 290-7.

[36] Santulli RJ, Derian CK, Darrow AL, Tomko KA, Eckardt AJ, Seiberg M, et al. Evidence for the presence of a protease-activated receptor distinct from the thrombin receptor in human keratinocytes. Proc Natl Acad Sci U S A 1995;92:9151-5.

[37] D'Andrea MR, Derian CK, Leturcq D, Baker SM, Brunmark A, Ling P, et al. Characterization of protease-activated receptor-2 immunoreactivity in normal human tissues. J Histochem Cytochem 1998;46:157-64.

[38] Schmidlin F, Amadesi S, Vidil R, Trevisani M, Martinet N, Caughey G, et al. Expression and function of proteinase-activated receptor 2 in human bronchial smooth muscle. Am J Respir Crit Care Med 2001; 164:1276-81.
[39] Tognetto M, D'Andrea MR, Trevisani M, Guerrini R, Salvadori S, Spisani L, et al. Proteinase-activated receptor-1 (PAR-1) activation contracts the isolated human renal artery in vitro. Br J Pharmacol 2003;139:21-7.
[40] Seiberg M, Paine C, Sharlow E, Andrade-Gordon P, Costanzo M, Eisinger M, et al. The protease-activated receptor 2 regulates pigmentation via keratinocyte-melanocyte interactions. Exp Cell Res 2000;254:25-32.
[41] Sharlow ER, Paine CS, Babiarz L, Eisinger M, Shapiro S, Seiberg M. The protease-activated receptor-2 upregulates keratinocyte phagocytosis. J Cell Sci 2000;113:3093-101.