



UNIVERSITÀ
DEGLI STUDI
FIRENZE

FLORE

Repository istituzionale dell'Università degli Studi di Firenze

The diagnostic labyrinth.

Questa è la Versione finale referata (Post print/Accepted manuscript) della seguente pubblicazione:

Original Citation:

The diagnostic labyrinth / P.A. Modesti. - In: INTERNAL AND EMERGENCY MEDICINE. - ISSN 1828-0447. - STAMPA. - 1:(2006), pp. 217-218. [10.1007/BF02934741]

Availability:

This version is available at: 2158/347465 since: 2016-07-12T13:48:37Z

Published version:

DOI: 10.1007/BF02934741

Terms of use:

Open Access

La pubblicazione è resa disponibile sotto le norme e i termini della licenza di deposito, secondo quanto stabilito dalla Policy per l'accesso aperto dell'Università degli Studi di Firenze (<https://www.sba.unifi.it/upload/policy-oa-2016-1.pdf>)

Publisher copyright claim:

(Article begins on next page)

Diffuse acute abdominal pain and palpation of the lower limb pulses: what kind of link?

Roberto Galeotti¹, Sepideh Torabi Parizi¹, Giorgio Vasquez², Paolo Zamboni²,
Roberto Manfredini³, Benedetta Boari³

¹Department of Radiology, ²Department of General Surgery, ³Department of Internal Medicine, Vascular Diseases Centre, University of Ferrara, Ferrara, Italy

(Intern Emerg Med 2006; 1 (3): 216-218)

A 71-year-old woman was referred to our hospital complaining of abrupt onset of diffuse abdominal pain and vomiting. The medical history included arterial hypertension and atrial fibrillation under pharmacological treatment with calcium channel blockers, digoxin, and aspirin. At physical examination, the sensorium was clear, axillary temperature was 36.7°C; arterial blood pressure 140/80 mmHg; pulse 68 bpm, dysrhythmic, no presence of a heart murmur; respiration 18 breaths/min. The chest was clear. Examination of the abdomen revealed diffuse tenderness. The left leg appeared pale and cold, the right lower extremity pulses were normal, but pulses distal to the left femoral artery were absent. On further persistent questioning, the patient reported the presence of pain in the left leg, but she gave no importance to this symptom due to the preponderant abdominal pain. Laboratory data showed a white blood cell count 12 000/mm³ (86% neutrophils); fibrinogen 735 mg/dl; erythrocyte sedimentation rate 60 mm/h; C-reactive protein 10.0 mg/dl. A chest X-ray study, and abdominal ultrasonography were negative. Duplex ultrasonography revealed an acute embolisation of left superficial femoral artery. Selective angiography showed a complete embolic obstruction of the superficial femoral artery and the ileo-colic branch of the superior mesenteric artery (Fig. 1A). Local regional transcatheter thrombolysis was performed in both arteries, giving priority to the mesenteric artery, more sensitive to ischaemic injury. A bolus of 100 000 IU of urokinase was administered, followed by a

continuous infusion of 50 000 IU/h. Twelve hours later, partial lysis of the embolus with signs of initial revascularisation were evident (Fig. 1B). Infusion was prolonged, and control at 24 h showed complete recanalisation of the ileo-colic artery and its branches (Fig. 1C). Subsequently, mechanical thrombolysis by means of a straight angiographic guidewire was performed in the femoral artery, followed by a bolus administration of 100 000 IU of urokinase, and continuous perfusion of 50 000 IU/h. Total treatment consisted of 2 600 000 IU of urokinase, with no bleeding and complete recanalisation of both vessels. The patient was discharged a few days later, in good clinical conditions.

Acute thromboembolic occlusion of the superior mesenteric artery or one of its branches is a life-threatening clinical condition, and is the most frequent cause of acute mesenteric ischaemia accounting for 1-2 per 1000 hospital admissions¹. Approximately 70% of the cases are due to circulating emboli, and 30% to local thrombosis. In a recent necropsy-based study on a series of fatal acute thromboembolic occlusions, multiple embolism and sources of emboli were present in 94% of cases⁵. Due to the intestine's low tolerance to ischaemia, early diagnosis and immediate treatment are crucial keys for patients' survival. Indeed, the high mortality, recently estimated at 62% in an unselected population, is considered to be due to the non-specificity of the early phase symptoms, and the lack of specific clinical, haematochemical or radiological findings^{2,3}.

In our patient, a careful physical examination with the abrupt onset of abdominal pain allowed us to conclude there were multiple emboli leading to a prompt diagnosis and treatment. The clinical triad including a) abdominal pain disproportional to the signs, b) vomiting or diarrhoea, c) and an obvious source of embolisation (atrial fibrillation) was indeed associated with signs suggestive of multiple thromboembolic events^{4,5}. Angiography was both diagnostic and therapeutic due to the efficacy of local thrombolysis in quickly restoring the mesenteric flow. When multiple contemporary emboli are present, mesenteric occlusion should be treated first, since other anatomic regions are better able to tolerate ischaemic damage.

Address for correspondence: Dr. Benedetta Boari, Department of Clinical and Experimental Medicine, Vascular Diseases Centre, University of Ferrara, Via Savonarola 9, 44100 Ferrara, Italy.
E-mail: brobdt@unife.it

© 2006 CEPI Srl

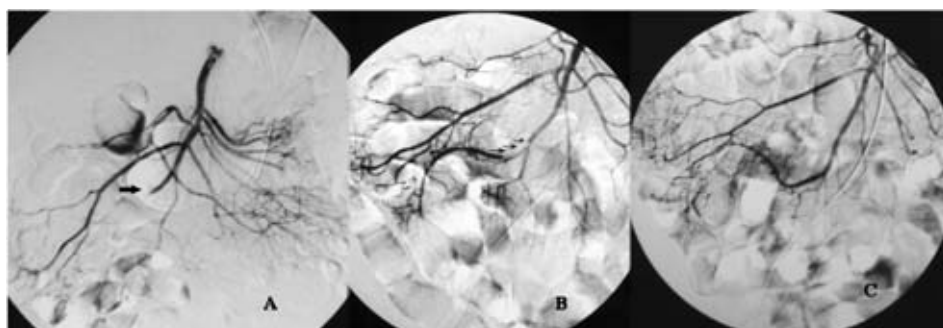


Figure 1. Selective angiography of the superior mesenteric artery. *A:* obstruction of the ileo-colic artery (arrow). *B:* angiographic control after 12 h, partial recanalisation of the vessel (arrows). *C:* final control after 24 h, complete recanalisation of the vessel and its branches.

References

1. Kaleya RN, Boley SJ. Acute mesenteric ischemia. *Crit Care Med* 1995; 11: 479-512.
2. Acosta S, Björck M. Acute thrombo-embolic occlusion of the superior mesenteric artery: a prospective study in a well defined population. *Eur J Vasc Endovasc Surg* 2003; 26: 179-83.
3. Mamode N, Pickford I, Leiberman P. Failure to improve outcome in acute mesenteric ischaemia. *Eur J Surg* 1999; 165: 203-8.
4. Björck M, Acosta S, Lindberg G, Troeng T, Bergqvist D. Revascularization of acute thromboembolic occlusion of the superior mesenteric artery in sixty patients. *Br J Surg* 2002; 89: 923-7.
5. Acosta S, Ogren M, Sternby NH, Bergqvist D, Björck M. Clinical implications for the management of acute thromboembolic occlusion of the superior mesenteric artery: autopsy findings in 213 patients. *Ann Surg* 2005; 241: 516-22.

Editorial comment

The diagnostic labyrinth

Pietro Amedeo Modesti

Clinical Medicine and Cardiology, Department of Critical Care Medicine and Surgery, University of Florence, Florence, Italy

A prompt diagnosis of acute intestinal thromboembolism with exclusion of other more usual causes of an acute abdomen is crucial to limit the consequences of bowel ischaemic injury. The high in-hospital mortality rates, still ranging between 59 and 90%, seem however to support the pessimistic opinion of Cokkinis, expressed more than 75 years ago, "... the diagnosis of acute intestinal ischaemia is impossible, the prognosis hopeless and the treatment useless ..."¹.

There is only a short time that the family practitioner or ward physician have to assess abdominal pain and to make a decision to reassure the patient or to request help.

Address for correspondence: Prof. Pietro Amedeo Modesti, Clinica Medica e Cardiologia, Dipartimento di Area Critica Medico Chirurgica, Università degli Studi, Viale Morgagni 85, 50134 Firenze, Italy. E-mail: pa.modesti@unifi.it

© 2006 CEPI Srl

Which factor(s) might contribute to delay a medical diagnosis of thromboembolism? How easy is it to persuade the local radiologist to perform angiography? The initial thought might be "that's just too unusual. I can't send every patient with abdominal pain to vascular angiography". In thinking that, we use pattern recognition, a common approach to clinical diagnosis. The more familiar is the condition, the more frequently we can think of the disease and the consequent diagnostic hypothesis. Cardiovascular surgeons² and nephrologists³ are familiar with acute intestinal ischaemia in patients undergoing major vascular surgery, and in those on haemodialysis. Conversely, the true incidence of acute intestinal ischaemia is often underestimated by gastroenterologists because they are more familiar with other causes of an acute abdomen, and embolism is low on the list for abdominal crisis⁴. This has also consequences in assessing the history because clinicians interpret symptoms in the light of what they believe are the possible diagnoses for the patient in front of them. These are the limits of the highly applied "heuristic-frequentist" approach to medical diagnosis, which sometimes forces the physician to walk a known pathway, rather than using all available information to solve the diagnostic labyrinth. Indeed, at variance with Christian pilgrims of the Medieval period, who were led laboriously but inevitably to the final destination by a single complicated path within the labyrinths of great Christian Cathedrals (Fig. 1), the physician needs to decide alone the right direction in the

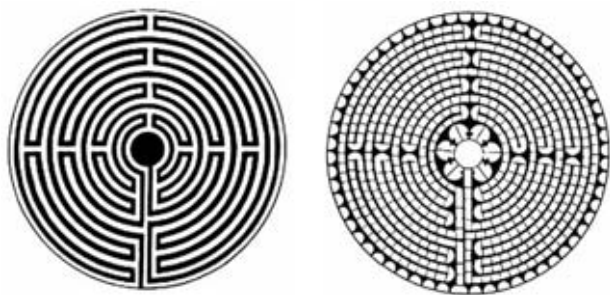


Figure 1. The same labyrinth in the Cathedrals of Lucca (*left*) and Chartres (*right*) (both date from the 12th century). Unlike the maze in which one may get lost, such as that designed by Dedalus, most labyrinths, both Christian and non-Christian, have a single complicated path, being a symbol of the journey from birth to death. In Christian labyrinths all pilgrims are laboriously and inevitably led to a single final destination, death is not the end but the door through which Heavenly Jerusalem may be entered.

ramified diagnostic labyrinth. In clinical decision-making the physician may get lost as Dedalus did in his own designed maze. Confidence is an important factor in decision-making, and may influence patient care. However, the proper use of all available relevant information may avoid the loss of valuable time in

exploring wrong directions. The present case report stresses the importance of giving to physical signs at least the same attention as that given to more refined diagnostic modalities.

The patient was at high risk for multiple emboli because of atrial fibrillation, and because of the absence of pulses distal to the left femoral artery. With a systematic Bayesian approach to diagnosis, the help given by physical examination was used to estimate the prior probability of disease, and the history was then reassessed. Consequently, the physician was able to think of such a rare cause of an abdominal emergency, and thus was much more confidently able to convince the radiologist to perform the angiography that clinched the diagnosis and enabled effective and life-saving therapy.

References

1. Cokkinis AJ. Mesenteric vascular occlusion. London: Bailliere, Tindall and Cox, 1926.
2. Gennaro M, Ascer E, Matano R, Jacobowitz IJ, Cunningham JN, Uceda P. Acute mesenteric ischemia after cardiopulmonary bypass. *Am J Surg* 1993; 166: 2321-36.
3. Diamond S, Emmett M, Henrich WL. Bowel infarction as a cause of death in dialysis patients. *JAMA* 1986; 256: 2545-7.
4. Yasuhara H. Acute mesenteric ischemia: the challenge of gastroenterology. *Surg Today* 2005; 35: 185-95.