UNIVERSITÀ DEGLI STUDI FIRENZE

FLORE
Repository istituzionale dell'Università degli Studi di Firenze

Multiple marker studies on a malignant fibrous hystiocytoma with primary cutaneous localization.

Questa è la Versione finale referata (Post print/Accepted manuscript) della seguente pubblicazione:

Original Citation:

Multiple marker studies on a malignant fibrous hystiocytoma with primary cutaneous localization / S. Moretti; M. Santucci; L. Brogelli; A. Palermo; U. Reali; N. Pimpinelli; A. Fattorossi.. - In: TUMORI. - ISSN 0300-8916. - STAMPA. - 74:(1988), pp. 609-615.

Availability:

This version is available at: 2158/352647 since:

Terms of use:

Open Access

La pubblicazione è resa disponibile sotto le norme e i termini della licenza di deposito, secondo quanto stabilito dalla Policy per l'accesso aperto dell'Università degli Studi di Firenze (https://www.sba.unifi.it/upload/policy-oa-2016-1.pdf)

Publisher copyright claim:

(Article begins on next page)

12 October 2024

Tumori, 74: 609-615, 1988

MULTIPLE MARKER STUDIES ON A MALIGNANT FIBROUS HISTIOCYTOMA WITH PRIMARY CUTANEOUS LOCALIZATION

Silvia Moretti,[1] Marco Santucci,[2] Laura Brogelli,[1] Alessandro Palermo,[1] Umberto Maria Reali,[1] Nicola Pimpinelli [1] and Andrea Fattorossi [1]

([1] Clinica Dermatologica II, Università di Firenze, and [2] Istituto di Anatomia e Istologia Patologica, Università di Firenze)

Continuing controversy exists concerning a possible relation between neoplastic cells of malignant fibrous histiocytoma (MFH) and the mononuclear phagocyte system. The aim of this study was to investigate the membrane and cytoenzymatic phenotype of a primary cutaneous MFH, storiform pleomorphic type, and to compare these data with ultrastructural observations. Cytoplasmic proteins (acid phosphatase, non specific esterase, alpha-1 antitrypsin, and lysozyme) suggestive of a mononuclear phagocyte origin were demonstrated in varying amounts in neoplastic cells infiltrating the dermis. Consistent with these data, two (LeuM3 and OKM5) out of four (OKM1 and LeuM1) monoclonal antibodies directed against mononuclear phagocyte antigens stained most of the neoplastic cells. Class II MCH antigens (DR and DQ) were variably expressed on distinct groups of neoplastic cells, suggesting different activation/differentiation states. The results favor the view that the present case of primary cutaneous MFH was of mononuclear phagocyte origin. However, the observed phenotypic profile was expressed on neoplastic cells irrespective of their ultrastructural morphology (histiocytic or fibroblastic). Together with previous data in the literature, the latter finding corroborates the view that distinction between these two cell types in MFH is likely to reflect divergent growth and differentiation patterns rather than histogenesis.

Malignant fibrous histiocytoma (MFH) is the most common soft tissue sarcoma in adults (5). It usually arises on the limbs, chest wall or retroperitoneum and very rarely in the skin (5, 7, 11). From a histological and cytological point of view, MFH is a rather heterogeneous tumor, and its histogenesis is still disputed. Fibroblast, histiocyte, or undifferentiated precursor cell derivations have been reported on the basis of ultrastructural and/or cytochemical investigations (1, 5, 7, 9, 11, 12, 14, 16, 21). Knowledge of the major trend of differentiation in a given tumor can, in principle, be useful for diagnostic and prognostic purposes. In this respect, immunohistochemical techniques have been widely employed in recent years to characterize a vast series of otherwise unclassifiable lymphoid tumors (8). However, in MFH immunohistochemical studies are controversial: some authors have failed to demonstrate monocyte lineage-specific determinants on MFH cells by the use of monoclonal antibodies against cells of monocytic lineage (2, 17). Conversely, Strauchen and Dimitriu-Bona have reported data that support the view of a mononuclear phagocytic origin.

To our knowledge, no detailed report exists in the dermatologic literature on the phenotypic

Acknowledgments: The authors thank Mr. Daniele Dainelli for his technical expertise with electron microscopy and photography, and Mr. John G. Pizzolo for excellent secretarial and editorial assistance.

Address for reprint requests: Dr. S. Moretti, Clinica Dermatologica II, Via della Pergola 58, 50121 Firenze, Italia.

Received February 22, 1988.

profile of MFH with a primary cutaneous localization. The aim of the present paper was therefore to investigate the phenotype of abnormal cells infiltrating the skin of a patient with subcutaneous MFH, using a panel of monoclonal antibodies towards differentiation antigens of mononuclear phagocytes. The results were evaluated together with those obtained with cytochemistry and electron microscopy.

Material and methods

Case report: A 76 year-old-man was admitted to hospital with a 5 cm wide, exophytic, nodular, hard and easily bleeding lesion on his right forearm (fig. 1). A second, smaller nodule was present on his right axilla. No superficial lymph nodes were palpable. Laboratory values were within normal limits. Abdominal sonography and thoracic CAT scanning revealed no abnormalities. Both nodules were surgically excised. Histological examination of the lesions showed a dense dermal infiltrate composed of fibroblast-like spindle-shaped cells arranged in a storiform pattern.

Scattered histiocyte-type mononuclear cells and a small number of multinucleated giant cells were also seen (fig. 2). These histological features were the basis of the diagnosis of MFH, storiform-pleomorphic type, according to Enzinger and Weiss (5).

Fig. 1 -An exophytic nodule and a small deep nodular lesion.

Electron microscopy: One mm cubes of tissue were fixed in buffered glutaraldeyde, postfixed in buffered osmium tetroxide, dehydrated and then embedded in Araldite. Ultrathin sections were stained with uranyl acetate and lead citrate and examined with a Hitachi HU-IIB electron microscope.

Enzyme cytochemistry: Nonspecific, esterase (NSE), acid phosphatase (AcP) and myeloperoxidase activity (MPO) were tested as previously described (6). AcP sensitivity to L+ tartaric acid and NSE sensitivity to NaF^- were also tested. Appropriate positive and negative controls were included in parallel for each cytochemical assay.

Immunohistochemistry: A panel of monoclonal antibodies were used on frozen sections (table 1). Technical procedures have been described elsewhere (6, 20). Briefly, cryostat-cut, 5 micron thick sections were fixed in an acetone-chloroform mixture and layered with monoclonal antibody. Slides were then incubated with biotin-labeled anti-mouse Ig antiserum (Vector Laboratories, Burlingame, CA, USA), washed and covered with fluorescein-conjugated avidin for immunofluorescence studies (Vector Laboratories) or with avidin-biotin-peroxidase complex (Vector Laboratories) followed by ethylcarbazole for immunoperoxidase studies. Rabbit antiserum against lysozyme or alpha-1 antitrypsin (Ortho, Raritan, NJ, USA) was tested on paraffin sections in an indirect immunoperoxidase assay. In all instances, positive and negative controls were run in parallel.

Results

Electron microscopy: Submicroscopic investigation showed that the ultrastructural pattern of the abnormal cell population was rather heterogeneous (fig. 3). Most of the neoplastic cells displayed a variable combination of histiocytic and fibroblastic features, i.e., many primary and secondary lysosomes and lipid droplets or a well developed rough endoplasmic reticulum, respectively. Some cells only exhibited either histiocytic or fibroblastic features in addition to the described cytoplasmic characteristics; the histiocytic elements were with prominent cytoplasmic projections

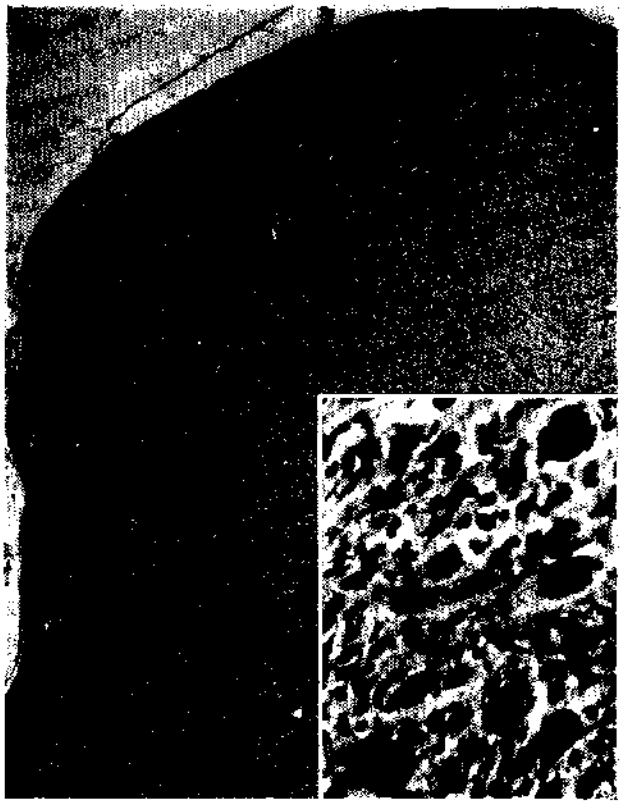

Fig. 2 - Low power view of the tumor; the overlying epidermis is not infiltrated (× 19). Inset: pleomorphic infiltrate with an admixture of fibroblast-like cells, mononuclear cells and multinucleated giant cells (× 239).

whereas the fibroblast-type elements were generally spindle-shaped or stellate. Finally, a few cells lacked both histiocyte and fibroblast features. Few giant cells were detectable; most of them had histiocyte-associated features.

Cytochemistry: Diffuse NaF sensitive NSE and tartrate sensitive AcP activity was demonstrated in the cytoplasm of most cells. Conversely, MPO activity was found almost exclusively in giant cells.

Immunohistochemistry: Results of immunohistochemical investigations are shown in Table 2. Monoclonal antibody Leu M3 stained most of the atypical cells in the infiltrate (fig. 4). A few distinct groups of cells were marked by OKM5, OKIa-1, and anti-Leu 10. No stained cell was observed for Leu M1 and OKM1. Unfortunately, despite careful examination of serial sections, we were unable to identify all those cells that were stained with more than one monoclonal antibody. However, some clusters of cells with cytoplasmic positivity for anti-kappa or -lambda light chains

Table 1 - Monoclonal antibodies.

Antibody	Specificity
OKM1 [1]	Phagocytes, null cells, Tγ
OKM5 [1]	Mononuclear phagocytes
Leu M1 [2]	Phagocytes
Leu M3 [2]	Mononuclear phagocytes
OK Ia-1 [1]	HLA-DR
Leu 10 [2]	HLA-DQ
Anti-K [2]	K light chain
Anti-λ [2]	λ light chain
OK T3 [1]	Pan T
OK T4 [1]	Helper/inducer T cells
OK T8 [1]	Cytotoxic/suppressor T cells
OK B2 [1]	B lymphocytes, granulocytes
OK B7 [1]	B lymphocytes

Purchased from:
[1] Ortho Diagnostic System, Raritan, NJ, USA.
[2] Becton Dickinson, Mountainview, CA, USA.

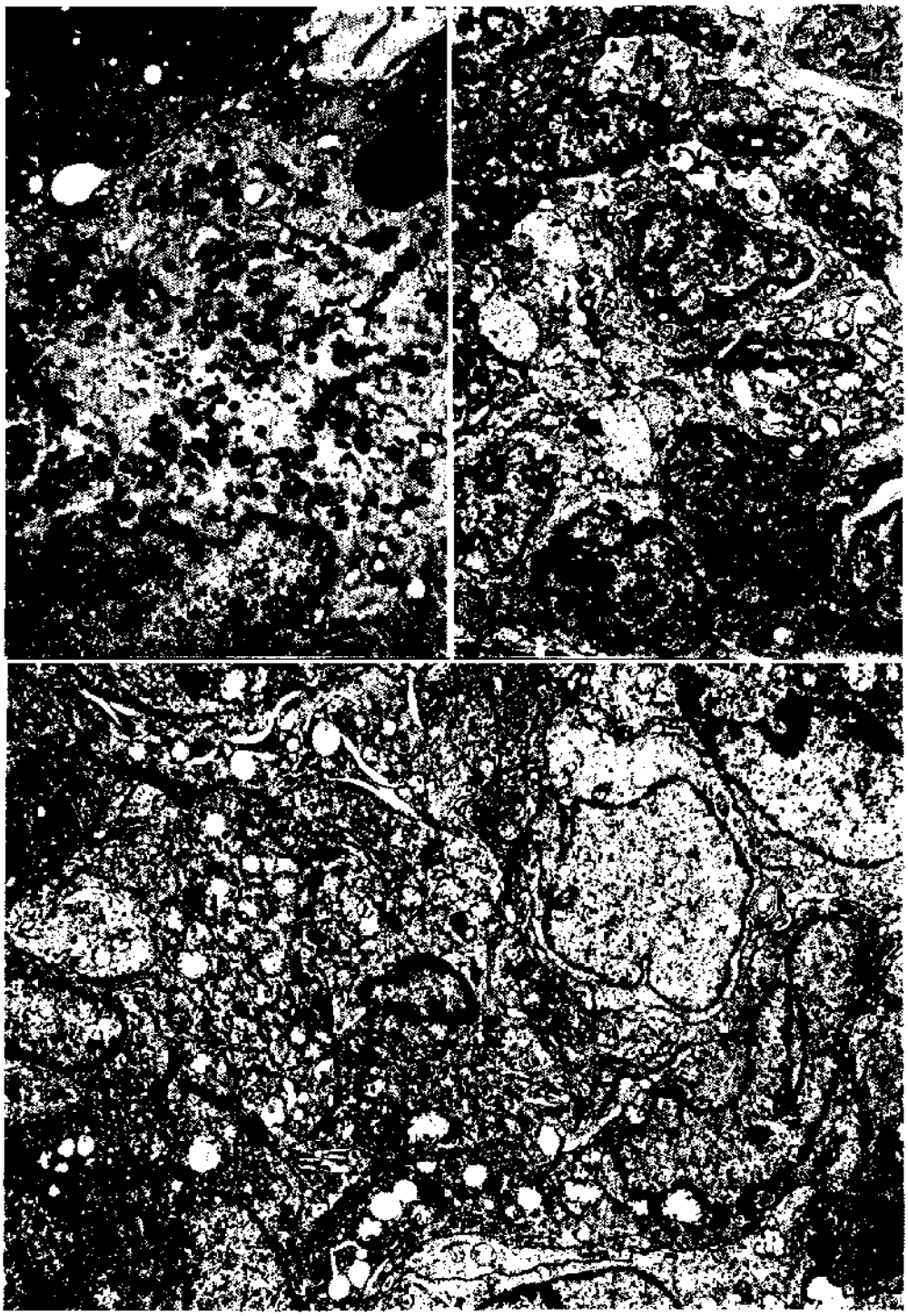

Fig. 3 - (Top left) Neoplastic cell, histiocytic type, characterized by the presence of many primary and secondary lysosomes; the rough endoplasmic reticulum is inconspicuous (× 4000). (Top right) Neoplastic cells, fibroblastic type, containing an abundant rough endoplasmic reticulum and a few lysosomes (× 3400). (Bottom) Neoplastic cells showing either the ultrastructural markers for both histiocytes and fibroblasts or for neither (undifferentiated cells) (× 4000).

Table 2 - Immunohistochemical profile of atypical cells.

Antibody	Reactivity
OKM1	—[1]
OKM5	Few groups
Leu M1	—
Leu M3	Numerous cells
OK Ia-1	Few groups
Leu 10	Few groups
Anti-kappa chain	Few groups
Anti-lambda chain	Few groups

[1] — = negative, i.e., less than 2-3 % positive cells.

were seen to overlap in serial sections indicating that a given cell contained both types of light chains.

Cells of T- and B-lymphocyte lineage were virtually absent, although a few elements did react with OKT8. These cells were round, of intermediate size and were interpreted as normal reactive cytotoxic-type lymphocytes. Only giant cells were stained with anti-alpha-1 antitrypsin and anti-lysozyme serum.



Fig. 4 - MFH cells stained with a LeuM3 monoclonal antibody (Immunofluorescence, × 501).

Discussion

In the present study we investigated the immunohistochemical and cytochemical features of one case of cutaneous MFH. MFH cells have ultrastructural features of both fibroblast and histiocytes (1, 5, 7, 9, 11, 12, 21). Such a composite pattern has led to considerable uncertainty regarding the origin of the tumor. Cytochemistry and, more recently, immunohistochemical investigations could not solve this problem since both a mononuclear phagocytic and a fibroblastic derivation have been supported by various authors (2, 14, 16, 17, 19). In the present case, cytochemical data point towards a predominantly histiocytic differentiation of atypical cells (3, 4). Interestingly, alpha-1 antitrypsin, lysozyme, and MPO were found almost exclusively in giant cells. This observation is in keeping with Roholl et al.'s data (16) and suggests that neoplastic cells were in different activation/differentiation states. Also the immunological phenotype suggests that phagocytic differentiation is prevalent in this case. Most cells stained with monoclonal antibodies Leu M3 and, to a lesser extent, OKM5: these are reagents specifically directed against mononuclear phagocyte antigens. Monoclonal antibodies OKIa-1 and Leu 10, which recognize distinct class II MHC determinants, were also positive in a considerable number of cells. The presence of class II MHC antigens on MFH cells, storiform type as in the present case, is in good keeping with previous observations (17). Interestingly, Kamitakis et al. (13) found class II MHC antigen positive cells in the dermal infiltrate of cutaneous histiocytofibromas, the benign counterpart of MFH. These authors, however, reported numerous OKM1 + cells as well. No OKM1 + cells were found in our MFH case, suggesting that neoplastic histiocytes can modulate their antigenic phenotype variably, probably in a differentiation-dependent fashion. This view appears to be supported by in vitro experiments in which phagocyte-derived cell lines readily express OKM1 antigen at incubation with differentiating agents (10). The positivity of antibodies against both kappa and lambda light chains in the cytoplasm of a given cell may be due to the cell competence for endocytosis and is therefore consistent with the phagocytic differentiation in the present case (the possibility of a passive diffusion of light chains cannot, however, be absolutely excluded). Some authors (2, 17) failed to find monocyte-associated antigens on the cell membrane of their cases of MFH. Unfortunately, they did not use just the

monoclonal antibodies directed towards mononuclear phagocytes (i.e. LeuM3 and OKM5), which did react in our case. On the other hand, the present findings are in accordance with those of Strauchen and Dimitriu-Bona (19) who reported reactivity for mononuclear phagocyte determinants and for class II MHC antigens in MFH, pleomorphic type, as in the present case. There is no obvious explanation for these discrepancies. Differences among reagents and among cases may account for the divergent results. It is also possible that a given tumor exhibits different phenotypic features at different times and in different localizations. In this regard it should be noted that to the best of our knowledge the present report is the first phenotypic study dealing with MFH of primary cutaneous localization.

Relevant to the present study are the observations that histiocytic-like cells have been obtained by cloning a MFH (18) and that cultured murine fibroblasts can be induced to differentiate in a histiocytic direction under appropriate stimuli (15). This suggests a close relation between the two cell types and may also help to explain the non homogeneous neoplastic cell population characterizing MFH. In the present case, electron microscopy revealed a very heterogeneous neoplastic cell population with either histiocytic or fibroblastic features or both. Evaluation of comparable specimens showed no obvious correlation between these ultrastructural data and the phenotypic profile, suggesting that in MHF ultrastructurally heterogeneous cells may have similar phenotypic features. The present observations seem to uphold the hypothesis of multidirection differentiation trends for the neoplastic cells of MFH (1, 5, 9, 12, 21). This case of MFH showed a histiocytic (mononuclear phagocyte) differentiation trend, although heterogeneous ultrastructural features of neoplastic cells were demonstrated.

Studio di un caso di istiocitoma fibroso maligno a localizzazione cutanea primaria

La possibilità di una correlazione fra le cellule neoplastiche dell'istiocitoma fibroso maligno (IFM) e il sistema dei fagociti mononucleati è tuttora controversa. Lo scopo del nostro studio è stato di valutare il fenotipo di membrana e citoenzimatico delle cellule neoplastiche in un caso di IFM a primitiva insorgenza cutanea (tipo storiforme pleomorfo) confrontandolo con i dati ultrastrutturali. Fosfatasi acida, esterasi non specifiche, alfa-1 antitripsina e lisozima erano presenti in una certa percentuale di cellule neoplastiche. In accordo con questi dati, le cellule tumorali risultavano in larga parte marcate da due (OKM5 e LeuM3) dei quattro (OKM1 e LeuM1) anticorpi monoclonali diretti contro antigeni del sistema dei fagociti mononucleati. Gli antigeni di classe II del MHC (DR e DQ) risultavano variamente espressi da gruppi di cellule neoplastiche, verosimilmente in rapporto a stati diversi di attivazione/differenziazione. Questi dati sono indicativi di una differenziazione in senso monocitario-macrofagico di questo caso di IFM a primitiva insorgenza cutanea. È da sottolineare inoltre che il profilo fenotipico delle cellule neoplastiche non appariva correlato al loro aspetto ultrastrutturale (istiocitico o fibroblastico). Insieme a precedenti dati della letteratura, questo dato sostiene l'ipotesi che la distinzione tra questi due tipi celluluri nel IFM probabilmente riflette diversi pattern di crescita e differenziazione piuttosto che di istogenesi.

References

1. Agualcil-Garcia A., Unni K., Goellner J.R.: Malignant fibrous histiocytoma: an ultrastructural study of six cases. Am. J. Clin. Pathol., 69: 121-129, 1978.

2. Brecher M.E., Franklin W.A.: Absence of mononuclear phagocyte antigens in malignant fibrous histiocytoma. Am. J. Clin. Pathol., 86: 344-348, 1-986.

3. Burgdorf W.H.C., Duray P., Rosai J.: Immunohistochemical identification of lysozyme in cutaneous lesions of alleged histiocytic nature. Am. J. Clin. Pathol., 75: 162-167, 1981.

4. du Boulay C.E.H.: Demonstration of alpha-1-antitrypsin in fibrous histiocytoma using immunoperoxidase technique. Am. J. Surg. Pathol., 6: 559-564, 1982.

5. Enzinger F.H., Weiss S.W.: Soft Tissue Tumors. pp. 116-198. C.V. Mosby Co., St. Louis, Toronto, London, 1983.

6. Fattorossi A., Moretti S., Palermo A., Santucci M., Bondi R., Giannotti B.: Cell surface marker studies in a patient with cutaneous multilobated T-cell lymphoma. Br. J. Dermatol., 113: 587-596, 1985.

7. Fletcher C., McKee P.H.: Sarcomas - a clinicopathological guide with particular reference to cutaneous manifestation. I. Dermatofibrosarcoma protuberans, malignant fibrous histiocytoma and the epithelioid sarcoma of Enzinger. Clin. Exp. Dermatol., 9: 451-465, 1984.

8. Foon A., Todd R.F.: Immunologic classification of leukemia and lymphoma. Blood, 68 (1): 1-31, 1986.

9. Fu Y.S., Gabbiani G., Kaye G., Lattes R.: Malignant soft tissue tumors of probable histiocytic origin (malignant fibrous histiocytoma): general considerations and electron microscopic and tissue culture studies. Cancer, 35: 176-198, 1975.

10. Gilbert D., Peulve P., Daveau M., Ripoche J., Fontaine M.: Modulation of complement receptors of a human monocyte cell line, U937, during incubation with phorbol myristate acetate: expression of a C3bi-specific receptor (CR3). Eur. J. Immunol., 15: 986-991, 1985.

11. Headington J.T.: Primary malignant fibrous histiocytoma of skin. J. Cutan. Pathol., 5: 329-338, 1978.

12. Iwasaki H., Kikuchi M., Enjoi M.: Benign and malignant fibrous histiocytomas of the soft tissues. Cancer, 50: 520-530, 1982.

13. Kamitakis J., Schmitt D., Thivolet J.: Immunohistologic study of cellular population of histiocytofibromas (dermatofibromas). J. Cutan. Pathol., 11: 88-94, 1984.

14. Kindblom L.G., Jacobsen G.K., Jacobsen M.: Immunohistochemical investigations of tumors of supposed fibroblastic-histiocytic origin. Hum. Pathol., 13: 834-840, 1982.

15. Krawisz B.R., Florine D.L., Scott R.E.: Differentiation of fibroblastic-like cells into macrophages. Cancer Res., 41: 2891-2899, 1981.

16. Roholl G.D., Kleyne J., Elbers H., Van der Vegt M.C.D., Albus Lutter C.H., Van Unnik J.A.M.: Characterization of tumour cells in malignant fibrous histiocytomas and other soft tissue tumours in comparison with malignant histiocytes. I. Immunohistochemical study on paraffin sections. J. Pathol., 147: 87-95, 1985.

17. Roholl G.D., Kleyne J., Van Unnik J.: Characterization of tumor cells in MFH and other soft tissue tumors in comparison with malignant histiocytes. II. Immunoperoxidase study on cryostat sections. Am. J. Pathol., 121: 269-274, 1985.

18. Shirasuna K., Sugiyama M., Miyazaki T.: Establishment and characterization of neoplastic cells from a malignant fibrous histiocytoma. Cancer, 55: 2521-2532, 1985.

19. Strauchen J.A., Dimitriu-Bona A.: Malignant fibrous histiocytoma. Expression of monocyte/macrophage differentiation antigens detected with monoclonal antibodies. Am. J. Pathol., 124: 303-309, 1986.

20. Taccari E., Fattorossi A., Moretti S., Riccieri V., Fasani M., Zoppini A.: Phenotypic profile of major synovial cell populations in longstanding psoriatic arthritis. J. Rheumatol., 14: 525-530, 1987.

21. Taxy B., Battifora H.: MFH: an electron microscopic study. Cancer, 40: 254-267, 1977.