



UNIVERSITÀ
DEGLI STUDI
FIRENZE

FLORE

Repository istituzionale dell'Università degli Studi di Firenze

Acute abdomen following dermoid cyst rupture during transvaginal ultrasonographically guided retrieval of oocytes

Questa è la Versione finale referata (Post print/Accepted manuscript) della seguente pubblicazione:

Original Citation:

Acute abdomen following dermoid cyst rupture during transvaginal ultrasonographically guided retrieval of oocytes / M. Coccia; C. Becattini; G. Bracco; G. Scarselli. - In: HUMAN REPRODUCTION. - ISSN 0268-1161. - STAMPA. - 11 (9):(1996), pp. 1897-1899.

Availability:

The webpage <https://hdl.handle.net/2158/352931> of the repository was last updated on

Terms of use:

Open Access

La pubblicazione è resa disponibile sotto le norme e i termini della licenza di deposito, secondo quanto stabilito dalla Policy per l'accesso aperto dell'Università degli Studi di Firenze (<https://www.sba.unifi.it/upload/policy-oa-2016-1.pdf>)

Publisher copyright claim:

La data sopra indicata si riferisce all'ultimo aggiornamento della scheda del Repository FloRe - The above-mentioned date refers to the last update of the record in the Institutional Repository FloRe

(Article begins on next page)

CASE REPORT

Acute abdomen following dermoid cyst rupture during transvaginal ultrasonographically guided retrieval of oocytes

Maria Elisabetta Coccia¹, Carolina Becattini,
Gian Luca Bracco and Gianfranco Scarselli

Department of Obstetrics and Gynecology, Ospedale di Careggi,
Florence, Italy

¹To whom all correspondence should be addressed at Via Ippolito Nievo 2, 50129 Florence, Italy

We report a case of acute abdomen due to puncture of a dermoid cyst during oocyte aspiration, which required laparotomy. A woman who had undergone an in-vitro fertilization and embryo transfer required hospitalization due to onset of an acute abdomen. An ultrasonographic scan showed a pelvic mass with the features of dermoid cyst. The patient required diagnostic laparotomy which confirmed the presence of a ruptured dermoid cyst with subsequent peritonitis.

Key words: acute abdomen/in-vitro fertilization/transvaginal oocyte retrieval complications

Introduction

Transvaginal ultrasonographically guided aspiration of oocytes is a well-accepted and universally used method in most in-vitro fertilization (IVF) programmes today (Wikland *et al.*, 1985). Transvaginal oocyte retrieval under ultrasonographically guided puncture has proved to be a practical and efficient method in large reported series of IVF and embryo transfer patients. While the original laparoscopic method for oocyte collection (Stephoe and Edwards, 1970) involved the occasional complications of general anaesthesia and possible damage to internal organs (Lewin *et al.*, 1985; Mastroyanni *et al.*, 1987), complications in ultrasonically guided retrievals are rare (Howe *et al.*, 1988; Van Hoorde *et al.*, 1992; Tureck *et al.*, 1993; Marlowe and Lupetin, 1995).

We report here on a case of acute abdomen due to accidental puncture of a dermoid cyst during oocyte aspiration, which required laparotomy.

Case report

A 37 year old woman was admitted to our Unit, with a complaint of general malaise, fever (38°C) and severe colicky pain in the lower abdominal quadrants which had developed gradually during the previous 2 weeks and was preceded by episodes of vaginal bleeding. Three weeks before admission, the patient had undergone transvaginal ultrasonographically

guided aspiration of oocytes in the context of an IVF-embryo transfer programme in a private centre. There was nothing else noticeable in the past medical history. The IVF-embryo transfer programme involved the use of gonadotrophin-releasing hormone (GnRH) agonist and subsequent gonadotrophin treatment with human menopausal gonadotrophin; the ovulation was induced with a single dose of human chorionic gonadotrophin (HCG). At 35 h after HCG administration, transvaginal sonographically guided oocyte retrieval was performed and after 2 days four embryos were replaced.

On admission, the patient looked anxious and sweaty and complained of diaphoresis. She was pyrexial (38.2°C), her blood pressure was 90/50 mm Hg, and her heart rate was 130 bpm. On physical examination the abdomen was distended and exquisitely tender on palpation of the lower quadrants, with a positive Blumberg sign. Vaginal examination could not be performed because of severe tenderness. Routine laboratory tests were performed, showing marked leukocytosis (16 400/mm³) and a β -HCG value <10 IU. All other values were normal (Table I). Transvaginal ultrasonographic evaluation showed a normal antverted uterus with an endometrial thickness of <3 mm and a right ovary with two hypo-echogenic areas, 20 and 21 mm in diameter. In the left pelvis a hyper-echogenic cyst, 50×34 mm, and a hypo-echogenic structure, 23 × 30 mm, were described in the context of a complex mass measuring 74×77 mm (Figure 1). Hyper-echogenic free fluid consistent with the presence of blood was observed in the recess of Douglas. Radiograms of the abdomen (supine and upright views) showed no free i.p. gas, but a round-shaped non-homogeneous calcification was evident in the left pelvis, 30 mm in diameter, suggesting the presence of a dermoid cyst (Figure 2).

On the same day the patient underwent exploratory laparotomy. On opening the abdomen, there was diffuse purulent peritonitis and yellow sebaceous fragments were scattered in the pelvis. The ovaries were both enlarged and cystic in appearance. Among several cysts attributable to recent corpora

Table I. Haematological values

| | Day 1 | Day 3 | Day 7 |
|---|-----------|-----------|-----------|
| Haematocrit (%) | 31.2 | 30.6 | 29.4 |
| White cell count (per mm ³) | 17 400 | 9800 | 7200 |
| Red cell count (per mm ³) | 3 450 000 | 3 330 000 | 3 220 000 |
| Haemoglobin (g/l) | 11.2 | 10.6 | 10.4 |
| Platelet count (per mm ³) | 284 000 | 292 000 | 241 000 |

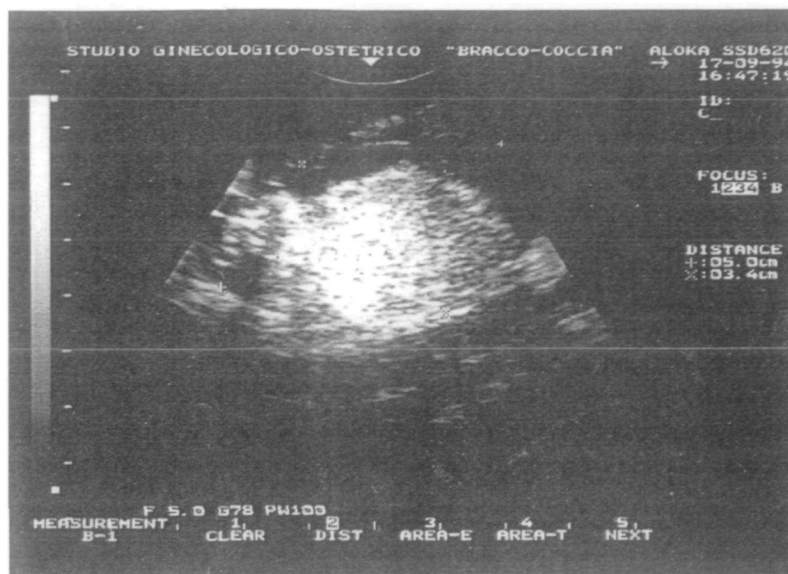


Figure 1. Hyper-echogenic cyst measuring 50 × 34 mm in diameter described in the context of a complex mass measuring 74 × 77 mm in the left pelvis.

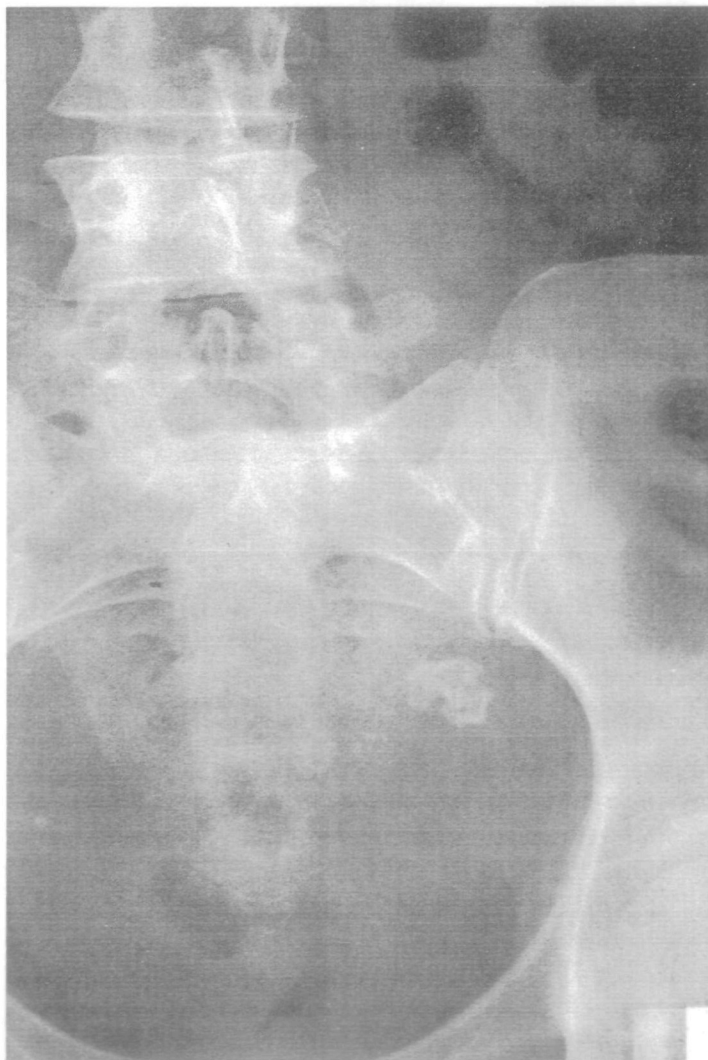

Figure 2. Radiogram of the abdomen (upright view) showing a round-shaped non-homogeneous calcification in the left pelvis, 30 mm in diameter.

lutea, we found a partially opened cyst 5 cm in diameter containing yellowish fluid, which was strongly suggestive of a dermoid cyst. Bilateral ovarian resection was performed in order to remove the cysts. Appendicectomy and accurate abdominal lavages with Ringer solution were performed before completing the intervention. In the following 2 days the patient's body temperature returned to normal values; white cell count fell to 7200/mm³ on day 7 (Table I). The patient was discharged in a good state of health on day 9. Microscopical examination of the ovaries showed the presence of two dermoid cysts.

Discussion

Laparoscopic follicular aspiration was the most prevalent method of oocyte retrieval for the first several years in IVF programmes and still finds application in related procedures such as gamete intra-Fallopian transfer (GIFT; Steptoe and Edwards, 1970). More recently, transvaginal follicle aspiration using a transvaginal transducer, first reported by Wikland *et al.* (1985), has become the dominant approach worldwide. This technique has significant advantages as compared to laparoscopy, such as decreased recovery time, avoidance of general anaesthesia and carbon dioxide pneumoperitoneum, reduced operative time and lower morbidity (Lewin *et al.*, 1985; Mastroyanni *et al.*, 1987). However, complications may occasionally occur with transvaginal ultrasonographically guided oocyte retrieval, such as puncture of a pelvic vein or post-retrieval pelvic infection (potentially leading to adnexal abscess formation) (Howe *et al.*, 1988; Van Hoorde *et al.*, 1992; Tureck *et al.*, 1993; Marlowe and Lupetin, 1995). Other complications may derive from accidental rupture of pre-existing cystic formation present in the pelvis.

We have reported here a case of acute abdomen following dermoid cyst rupture during oocyte retrieval, representing an example of potentially life-threatening complications which may rarely occur in the course of ultrasonically guided ovum

retrieval for IVF–embryo transfer. However, the occurrence of such complications may be avoided by accurate echographic pelvic examinations to exclude coexisting hazardous conditions (e.g. dermoid cyst). In particular, in our centre every patient undergoing an IVF–embryo transfer procedure is routinely given at least two to three previous pelvic examinations before admission to the IVF programme, in mid-luteal phase before administration of GnRH analogue and during the subsequent menstrual period before starting gonadotrophin treatment. If ovarian cysts are diagnosed during ultrasound examinations, we prefer to remove the cysts before starting the gonadotrophin treatment. Endoscopic cystectomy is usually preferable in fertile women because of the well-known advantages over laparotomy (Hasson, 1990; Mage *et al.*, 1990; Operative Laparoscopy Study Group, 1991). Even the spillage of the cyst's content with spread of sebaceous material in the abdominal cavity does not lead to any complication. In such cases, copious irrigation and washing of the abdominal and pelvic cavities should be performed to cleanse the peritoneal surface (Nezhat *et al.*, 1989; Bollen *et al.*, 1992; Reich *et al.*, 1992; Chapron *et al.*, 1994). Unfortunately, in our case the patient was submitted to our unit 3 weeks after the oocyte retrieval and at this time the peritoneal irritation due to sebaceous material spilled from the ruptured dermoid cyst was severe and required the laparotomy approach.

In conclusion, this case represents an example of potentially life-threatening complications which may rarely occur in the course of ultrasonically guided ovum retrieval for IVF–embryo transfer. The occurrence of such complications may be avoided by accurately identifying coexisting hazardous conditions at previous ultrasound examinations.

References

- Bollen, N., Camus, M., Tournaye, H. *et al.* (1992) Laparoscopic removal of benign mature teratoma. *Hum. Reprod.*, **7**, 1429–1432.
- Chapron, C., Dubuisson, J.B., Samouh, N. *et al.* (1994) Treatment of ovarian dermoid cysts. Place and modalities of operative laparoscopy. *Surg. Endosc.*, **8**, 1092–1095.
- Hasson, H.M. (1990) Laparoscopic management of ovarian cysts. *J. Reprod. Med.*, **35**, 863–867.
- Howe, R.S., Wheeler, C., Mastroianni, L. Jr *et al.* (1988) Pelvic infection after transvaginal ultrasound guided ovum retrieval. *Fertil. Steril.*, **49**, 726–728.
- Lewin, A., Margalioth, E.J., Rabinowitz, R. and Schenker, J.G. (1985) Comparative study of ultrasonically guided percutaneous aspiration with local anesthesia and laparoscopic aspiration of follicles in an in vitro fertilization program. *Am. J. Obstet. Gynecol.*, **151**, 621–625.
- Mage, G., Canis, M., Manhes, H. *et al.* (1990) Laparoscopic management of adnexal cystic masses. *J. Gynecol. Surg.*, **6**, 71–79.
- Marlowe, S.D. and Lupetin, A.R. (1995) Tuboovarian abscess following transvaginal oocyte retrieval for in vitro fertilization: imaging appearance. *Clin. Imaging*, **19**, 180.
- Mastroianni, C., Hosoi, Y., Yoshimura, Y. *et al.* (1987) The effect of carbon dioxide pneumoperitoneum on rabbit follicular oocytes and early embryonic development. *Fertil. Steril.*, **47**, 1025.
- Nezhat, C., Winer, W.K. and Nezhat, F. (1989) Laparoscopic removal of dermoid cysts. *Obstet. Gynecol.*, **73**, 278–280.
- Operative Laparoscopy Study Group (1991) Postoperative adhesion development after operative laparoscopy: evaluation of early second-look procedure. *Fertil. Steril.*, **55**, 700–704.
- Reich, H., McGlynn, F., Sekel, L. and Taylor, P. (1992) Laparoscopic management of ovarian dermoid cysts. *J. Reprod. Med.*, **37**, 640–644.
- Stephens, P.C. and Edwards, R.G. (1970) Laparoscopic recovery of preovulatory human oocytes after pruming of ovaries with gonadotropins. *Lancet*, **i**, 683.
- Tureck, R.W., Garcia, C.R., Blasco, L. and Mastroianni, L. Jr. (1993) Perioperative complications arising after transvaginal oocyte retrieval. *Obstet. Gynecol.*, **81**, 590–593.
- Van Hoorde, G.J., Verhoeff, A. and Zeilmaker, G.H. (1992) Perforated appendix following transvaginal oocyte retrieval for in-vitro fertilization and embryo transfer. *Hum. Reprod.*, **7**, 850–851.
- Wikland, M., Enk, L. and Hamberger, L. (1985) Transvesical and transvaginal approaches for the aspiration of follicles by use of ultrasound. *Ann. N.Y. Acad. Sci.*, **442**, 182–194.

Received on January 22, 1996, accepted on June 14, 1996