



UNIVERSITÀ
DEGLI STUDI
FIRENZE

FLORE

Repository istituzionale dell'Università degli Studi di Firenze

Clinical Importance of the Supra-Isthmic Anastomosis between the Superior Thyroid Arteries in Six Cases of Occlusion of the Common

Questa è la Versione finale referata (Post print/Accepted manuscript) della seguente pubblicazione:

Original Citation:

Clinical Importance of the Supra-Isthmic Anastomosis between the Superior Thyroid Arteries in Six Cases of Occlusion of the Common Carotid Artery / C.Macchi; C.Catini. - In: SURGICAL AND RADIOLOGIC ANATOMY. - ISSN 0930-1038. - STAMPA. - 17:(1995), pp. 65-69.

Availability:

This version is available at: 2158/353204 since:

Terms of use:

Open Access

La pubblicazione è resa disponibile sotto le norme e i termini della licenza di deposito, secondo quanto stabilito dalla Policy per l'accesso aperto dell'Università degli Studi di Firenze (<https://www.sba.unifi.it/upload/policy-oa-2016-1.pdf>)

Publisher copyright claim:

(Article begins on next page)

Clinical importance of the supra-isthmic anastomosis between the superior thyroid arteries in six cases of occlusion of the common carotid artery

C Macchi¹ and C Catini²

¹ Institute of Gerontology and Geriatric Medicine, ² Department of Human Anatomy and Histology, University of Florence, Italy

Summary. In six cases of occlusion of a single common carotid artery, antegrade blood flow was demonstrable in the ipsilateral internal carotid artery by doppler ultrasonography. Antegrade blood flow was also observed in the intracranial portion of the internal carotid artery, comparatively reduced and irregular with respect to that of the corresponding contralateral artery. Studies by color doppler ultrasound and digital subtraction angiography revealed the presence of a collateral arch that passed through the supra-isthmic anastomosis between the superior thyroid arteries. All six subjects examined had presented with neurological deficits that subsequently almost completely regressed. The regression of symptomatology indicates the clinical importance of the collateral circle.

Importance clinique de l'anastomose supra-isthmique entre les artères thyroïdiennes supérieures dans 6 cas d'occlusion de l'artère carotide commune

Résumé. Dans 6 cas d'occlusion d'une seule a. carotide commune, un flux sanguin antérograde dans l'a. carotide inter-

ne ipsilatérale a été prouvé par ultrasonographie doppler. Un flux sanguin antérograde était également observé dans la partie intra-crânienne de l'a. carotide interne, mais il était irrégulier et réduit en comparaison avec celui de l'a. homonyme controlatérale. Le doppler couleur et l'angiographie digitalisée avec soustraction ont révélé la présence d'une circulation collatérale qui empruntait l'anastomose supra-isthmique unissant les deux aa. thyroïdiennes supérieures. Ces six patients examinés avaient présenté des déficits neurologiques qui ont ensuite presque complètement régressés. La régression de la symptomatologie indique l'importance clinique de la circulation collatérale.

Key words: Superior thyroid arteries — Supra-isthmic anastomosis — Clinical importance

Occlusion of the common carotid a. at its origin was incidentally observed in six patients who had been referred by their primary physicians for doppler ultrasonography; a blood flow was demonstrable in the ipsilateral internal carotid a. distal to the bifurcation. This flow, which is normally directed toward the brain, was also detectable in the intracranial portion of the ipsilateral internal carotid a. All these arteries,

which were explored using doppler and color doppler ultrasonography, were found to have antegrade blood flow, albeit reduced and irregular with respect to that of the corresponding arteries on the other side. The aim of this study was first to identify exactly the collateral arch which permits the presence of blood flow within the internal carotid a. ipsilateral to the occluded common carotid a. and then to define its clinical importance.

Material and methods

General data of each of the six patients are reported in Table 1.

The doppler ultrasound studies of the supra-aortic trunks and intracranial vessels were performed using continuous wave doppler (Meda Sonic D9) with a 5 MHz transducer; color doppler studies were performed using a color duplex scanner (Acuson, model 128) with a 5 and 2 MHz transducer. The carotid angiographies were carried out by digital subtraction using a Philips DVI 2 system.

Results

Examination of the carotid aa. with color doppler ultrasound (Table 2) demonstrated that four patients out of six (nos. 1, 3, 5, and 6) presented an

Correspondence to: C Catini, Dipartimento di Anatomia umana ed Istologia, Policlinico di Careggi, I-50134 Florence, Italy

Table 1. Data of individual patients showing age, sex, neurological symptomatology (NS), and its duration (D)

Données concernant les patients : âge, sexe, symptomatologie neurologique (NS) et son début (D)

Case no. #	Sex	Age	NS	D
1	F	38	transient left hemiparesis	2 years
2	F	42	several TIA	5 years
3	F	49	several TIA	3 years
4	F	65	several TIA	7 years
5	M	62	transient right amaurosis	10 days
6	M	59	left monoparesis	30 days

Table 2. Doppler velocimetric patterns (systolic velocity, cm/s) in the right (R) and left (L) internal carotid aa. (ICA) before and after compression of the contralateral common carotid a.

Données apportées par la vélocimétrie doppler (vitesse systolique en cm/s) des aa. carotides internes (ICA) droite (R) et gauche (L) avant et après la compression de l'a. carotide commune controlatérale

Case no. #	Side of occlusion	Velocimetry patterns	Systolic velocity		Compression
			R ICA	L ICA	
1	R	antegrade flow	25	54	stoppage of flow
2	L	"	57	23	"
3	R	"	34	68	"
4	L	"	63	29	"
5	R	"	24	61	"
6	R	"	24	59	"

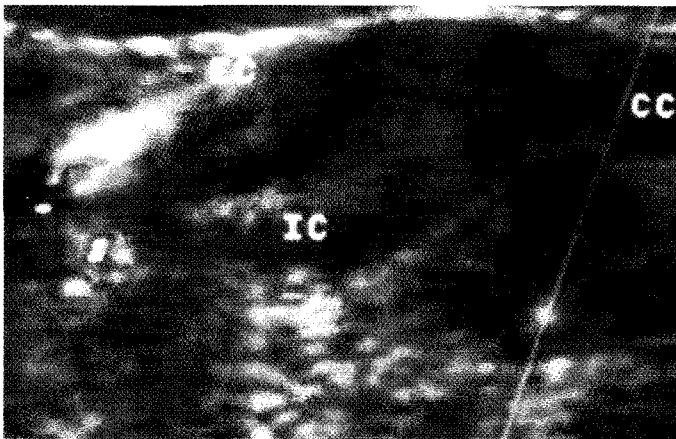


Fig. 1

Carotid color doppler of a 38-year-old woman. Right common carotid (CC) occlusion: note the retrograde blood flow (red) in the external carotid a. (EC) and the antegrade blood flow in the internal carotid a. (IC)

Doppler couleur de l'a. carotide d'une femme de 38 ans. Occlusion de l'a. carotide commune droite (CC) : noter le flux sanguin rétrograde (rouge) dans l'a. carotide externe (EC) et le flux sanguin antérograde dans l'a. carotide interne

occlusion of the right common carotid a., while the remaining two had occlusion of the left common carotid a. In all the six patients the occlusion of the common carotid a. extended from the point of origin of the vessel to a few millimeters proximal to the bifurcation, keeping patent the highest part of the carotid bulb. In all the six patients an antegrade blood flow in the internal carotid a. ipsilateral to the occlusion, (reduced and irregular in comparison with the contralateral internal carotid a.), was detected. As an example, echo color doppler morphology of the common, internal and external carotid aa. and echo color doppler patterns of the supra-aortic vessels of a 38-year-old woman (case no. 1) are shown in Figs. 1 and 2, respectively. In those patients (nos. 1, 2, 3, and 5) in whom the origin of the superior thyroid a. was from the external carotid, the blood flow in the internal carotid ipsilateral to the obstruction originated from the ipsilateral external carotid. In turn, the external carotid was supplied by the contralateral external carotid. The blood flow followed the following path: from the contralateral external carotid and superior thyroid a., through the supra-isthmus anastomosis, it reached the ipsilateral external carotid, then flowed in a retrograde fashion toward the carotid bifurcation and toward the internal carotid, since the vascular territory of this artery offers lower resistance to flow than that of the external carotid a. The origin of the blood flow in the internal carotid, ipsilateral to the lesion, from the contralateral external carotid, was proved by compression of the latter artery at the level of the carotid bifurcation with the index finger of the examiner after it had been ascertained that this vascular region was unaffected by atherosclerosis. The consequent stoppage of flow in the internal and external carotid aa. ipsilateral to the occlusion confirmed the existence of a collateral arch which was shown to make use of the superior thyroid a. In patients nos. 4 and 6 a similar collateral circuit existed even though the superior thyroid a. originated from the carotid bulb. Obviously, a compression test was performed on the contralateral common carotid a.; this was done

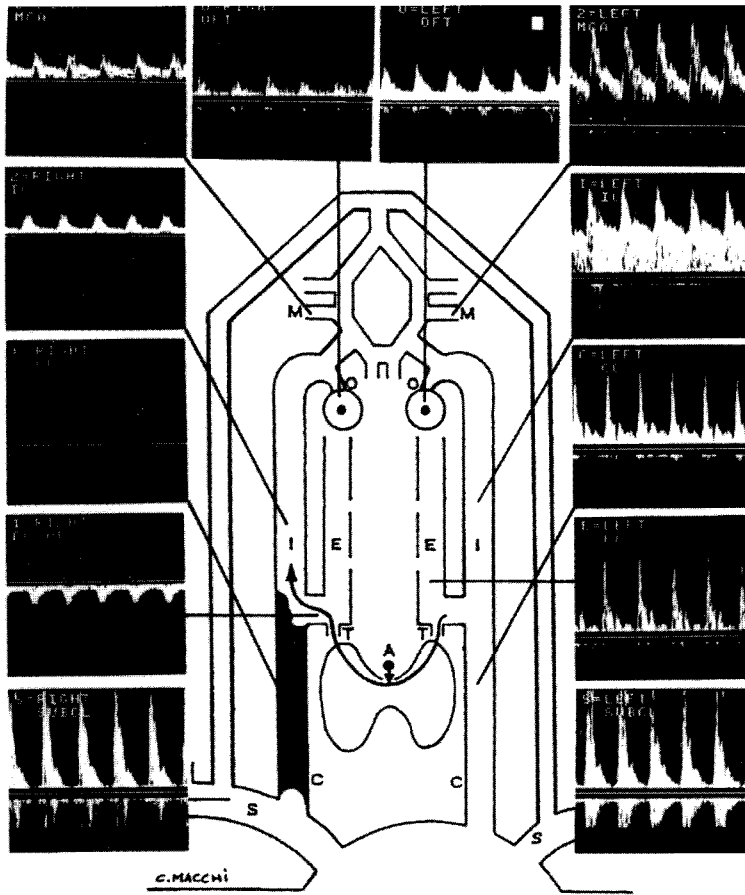


Fig. 2

Doppler velocimetry of the supra-aortic vessels and semi-diagrammatic representation of the collateral circle of the same patient. A supra-isthmic anastomosis between the superior thyroid aa.; T,T superior thyroid aa.; E,E external carotid aa.; I,I internal carotid aa.; O,O ophthalmic aa.; M,M middle cerebral aa.

Vélocimétrie doppler des troncs supra-aortiques et représentation semi-schématique de la circulation collatérale de la patiente de 38 ans. A anastomose supra-isthmique entre les aa. thyroïdiennes supérieures; T,T aa. thyroïdiennes supérieures; E,E aa. carotides externes; I,I aa. carotides internes; O,O aa. ophtalmiques; M,M aa. cérébrales moyennes

Discussion and conclusions

The thyroid gland is supplied by two paired arteries: the superior and inferior thyroid arteries.

Faller and Sharer [5] have demonstrated that the superior thyroid a. arises from the common carotid a. in 18% of individuals, from the external carotid in 46% and from the bifurcation of the common carotid in 36%. Our data have shown that in four out of six cases the superior thyroid a. arises from the external carotid, and in the remainder from the bifurcation of the common carotid a.

The inferior thyroid a. usually arises from the thyrocervical trunk; only in about 15% of individuals may it arise directly from the subclavian a. [19].

In 4% of individuals [5] an accessory artery to the thyroid gland may be present: the thyroidea ima a. This abnormal artery may arise from the right brachiocephalic trunk, or from the right common carotid a., or the aortic arch, or the internal thoracic a.

with due caution and after ascertaining that this vascular region was unaffected by atherosclerosis. In all patients, the exploration of cerebral blood flow by means of transcranial color doppler ultrasound demonstrated the presence of antegrade blood flow in the middle cerebral a. ipsilateral to the occlusion, but it was reduced and irregular compared with that of the corresponding

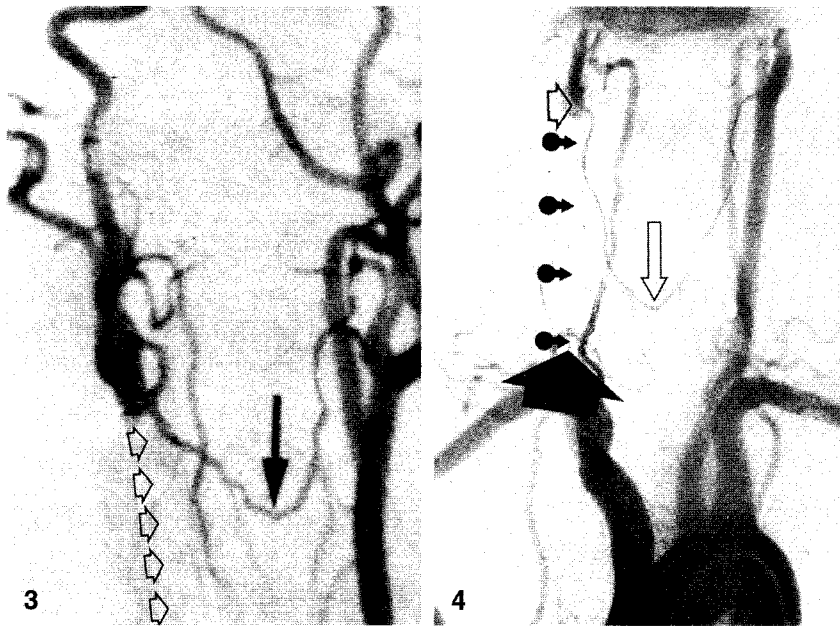
contralateral artery (Table 3). Digital subtraction angiography of the supra-aortic vessels was performed in each patient; Fig. 3 shows, for example, that of case no. 1; Fig. 4 shows that of the case no. 5. The existence of a collateral circle through a supra-isthmic anastomosis of the superior thyroid aa. was shown in all the patients. No other collateral circle was detected (Table 4).

Table 3. Systolic velocity cm/s in the right (R) and left (L) middle cerebral aa. (MCA) as measured by transcranial echo color doppler
Vélocimétrie systolique (en cm/s) dans les aa. cérébrales moyennes (MCA) droite (R) et gauche (L) par doppler couleur trans-crânien

Case no. #	R MCA	L MCA
1	29	57
2	56	24
3	28	64
4	59	29
5	22	58
6	24	55

Table 4. Angiographic patterns of the superior thyroid a. (STA)
Données fournies par l'angiographie des aa. thyroïdiennes (STA)

Case no. #	Origin of the STA	Collateral circulation
1	external carotid bilaterally	supra-isthmic anastomosis
2	external carotid bilaterally	"
3	external carotid bilaterally	"
4	carotid bulb bilaterally	"
5	external carotid bilaterally	"
6	carotid bulb bilaterally	"

**Fig. 3**

Digital subtraction angiography of the supra-aortic trunk in the same patient. The right common carotid artery is obstructed (*small arrows*), and there is antegrade blood flow in the ipsilateral internal carotid, which is supplied by the contralateral superior thyroid a. by means of the supra-isthmus anastomosis (*black arrow*)

Angiographie digitalisée avec soustraction des troncs supra-aortiques de la femme de 38 ans. L'a. carotide commune droite est thrombosée (*petites flèches*) et il y a un flux sanguin antérograde dans l'a. carotide interne ipsilatérale qui est revascularisée par l'a. thyroïdienne supérieure controlatérale grâce à l'anastomose supra-isthmique (*flèche noire*)

Fig. 4

Digital subtraction angiography of the supra-aortic trunk of a 62-year-old man. The right common carotid a. is obstructed at its origin (*black arrow*), and there is antegrade blood flow in the ipsilateral internal carotid (*small open arrow*), which is supplied by the contralateral superior thyroid a. by means of the supra-isthmus anastomosis (*large open arrow*)

Angiographie digitalisée avec soustraction des troncs supra-aortiques de la patiente de 62 ans. L'a. carotide commune droite est thrombosée à son origine (*flèches noires*), il y a un flux sanguin antérograde dans l'a. carotide interne ipsilatérale (*petite flèche ouverte*) revascularisée par l'a. thyroïdienne supérieure controlatérale grâce à l'anastomose supra-isthmique (*large flèche ouverte*)

Many authors, even in the last century, described anastomoses between the thyroid aa.

According to Cruveilhier [3] the superior thyroid a. ramifies into 3 branches in the proximity of the thyroid gland: one branch runs between the gland lobes and the trachea, the other follows the lateral surface of the lobes of the gland, and the last is located

along the inner side of the lobes and anastomoses with the contralateral branch at the midline.

Romiti [16], while confirming the existence of a transverse anastomosis between the superior thyroid aa., describes a further transverse anastomosis between the inferior thyroid aa. This author also reported the presence of longitudinal anastomoses on each side,

between the superior and inferior thyroid aa.

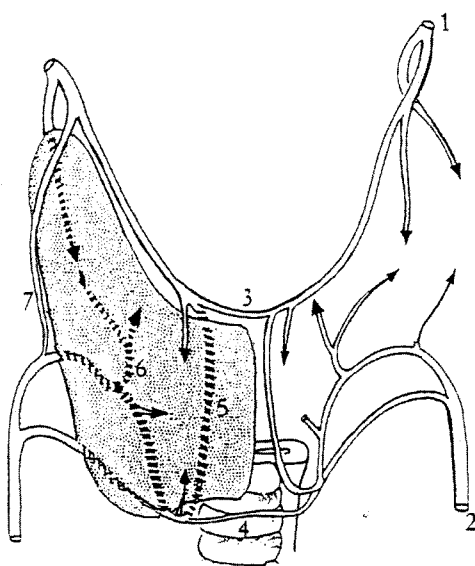
Braine and Funk-Brentano [2] have described in detail the two transverse anastomoses between the thyroid aa.; in addition they introduced a still widely accepted nomenclature, using "supra-isthmus anastomosis" for the larger anastomosis between the two superior thyroid aa. and "infra-isthmus anastomosis" for the thinner anastomosis between the two inferior thyroid aa.

Allara [1] has confirmed the existence of the supra and infra-isthmus anastomoses, and has specified that the posterior longitudinal anastomosis is the larger.

Recently, the use of angiographic methods [12] has confirmed the distribution of the vessels to the thyroid gland as well as the existence of transverse and longitudinal anastomoses between the arteries of the gland. A diagram of these latter data is given in Fig. 5.

The present study has demonstrated how thyroid arteries that are normally independent of the cerebral circulation, may constitute under special conditions a functional collateral arch

As a consequence of occlusion of the common carotid a., the superior thy-

**Fig. 5**

Diagrammatic representation of transverse and longitudinal anastomoses between the thyroid aa. as shown by angiography: 1 superior thyroid artery, 2 inferior thyroid artery, 3 supra-isthmus anastomosis, 4 infra-isthmus anastomosis, 5 retro-isthmus anastomosis, 6 retro-glandular anastomosis, 7 lateral glandular anastomosis

Représentation schématique des anastomoses transversales et longitudinales entre les aa. thyroïdiennes comme elles furent précisées par l'angiographie: 1 a. thyroïdienne supérieure; 2 a. thyroïdienne inférieure; 3 anastomose supra-isthmique, 4 anastomose infra-isthmique, 5 anastomose rétro-isthmique, 6 anastomose rétro-glandulaire, 7 anastomoses latéro-glandulaire

roid aa. can assume a critical significance in guaranteeing an adequate blood supply to the brain. Several investigators have already described analogous cases of obstruction of the common carotid a. in which a compensatory blood flow was established through the thyroid aa. [2, 4], while others have demonstrated the wide range of neurological deficits caused by the same type of occlusion of the carotid bed [6, 14, 18].

The above-mentioned authors, however, failed to define precisely the anastomosis between the superior thyroid aa. that we have described by comparing the color doppler ultrasonographic and angiographic findings. The anatomic importance of the thyroid aa. was already well-known in the relationship between the vascular bed and the thyroid parenchyma [17, 7]. However, it was difficult to demonstrate that these arteries could function as a temporary collateral arch in the event of carotid occlusion.

With the assistance of echo doppler ultrasonography, we have demonstrated that this hypothesis is not improbable. The superior thyroid aa. are small-caliber vessels; 1 cm after their origin, their diameter is 1.7 ± 0.3 mm. Nevertheless, this caliber permits the transit of a sufficient amount of blood to sustain cerebral perfusion [10, 9]. On this subject, it is known that a stenosis of the internal carotid artery of less than 80% is not hemodynamically significant [15, 13, 11, 8]. Any artery, however small and apparently insignificant, may constitute a sole, critical temporary pathway in the event of occlusion of an important vessel, such as the common carotid a.

Awareness of these collateral paths is of a great help to the clinician, because their recognition and the definition of their hemodynamic importance is required, not only for formulating a prognosis, but also and especially for selecting therapy.

The importance of our data is not so much that they describe a new compensatory circulation, as that they confirm that it is hemodynamically adequate. In other words, that an event as critical as

occlusion of a common carotid a. is not associated with a significant neurological deficit must lead to the conclusion that such a collateral circulation is hemodynamically comparable to that making use of the ophthalmic artery which sometimes occurs to compensate for occlusions of the external and internal carotid aa. In such instances, the compensatory flow is such as to provide a blood supply sufficient to the brain's needs.

The clinical significance of these collateral circulations becomes particularly evident in prognostic assessments. For instance, surgical intervention is often indicated for stenotic lesions of the internal carotid a. However, it is of fundamental importance that the adequacy of the blood flow in the collateral circulation described be guaranteed prior to the intervention. In the course of carotid thromboendarterectomy, the artery must be clamped for the entire duration of the procedure; thus, it is necessary to ensure that the flow of blood in the contralateral carotid is adequate to meet the brain's metabolic needs. In this situation, the presence of sufficient flow in the recanalized internal carotid from the external carotid by means of the superior thyroid a. may thus guarantee a favorable outcome.

It is interesting to remember that longitudinal anastomoses between the ipsilateral thyroid arteries may also be able to sustain cerebral perfusion. Wolpert [20] has shown that cerebral blood flow may be preserved even after ligation of the common carotid a., by a collateral circle between the thyroidea ima a. and the inferior thyroid a., demonstrated by selective brachiocephalic angiography.

References

- Allara E (1936) La vascularizzazione arteriosa della ghiandola tiroide dell'uomo. *Arch It Anat Embriol* 2 : 269-318
- Braine J, Funk-Brentano P (1934) Les variations des artères du corps thyroïde. *Ann Anat Pathol* XI : 125-155
- Cruveilhier F (1838) *Anatomie descriptive*, vol II. Meline, Cans, Brussels, p 43
- Dauzat M, Laroche JP, De Bray JM, Juhel P,

- Becker F, Cesari JB, Jonnart L, Domergue A, Carette J, Duvauferrier R, Heyden D, Maugin D, Vonsgouthi S, Davinroy M (1986) *Pratique de l'ultrasonographie vasculaire (Doppler echographie)*. Vigot, Paris, pp 129-134
- Faller A, Scharer O (1947) Über die Variabilität der Arteriae thyreoideae. *Acta Anat* 4 [Suppl] : 119-122
- Fazio C (1926) Haemodynamic factors in the pathogenesis of brain infarct. *Europ Neurol* 2 : 76-81
- Fazzari I (1926) Contributo allo studio morfologico e statistico della ghiandola tiroide in Sicilia. *Endocr Pat Costituzionale* 9 : 8-15
- Franceschi C, Luizi F, Jardin M, Martelli L, Tanitte M (1980) La carotide externe sous-parotidienne : un point de compression méconnu mais de grande valeur diagnostique. *Ultrasons I* : 295-298
- Franceschi C (1992) L'indagine vascolare con ultrasonografia doppler. Masson, Milano, pp 61-66
- Hennerici M, Neuerburg HD (1991) Diagnostica vascolare con ultrasuoni. Il pensiero scientifico, Rome, pp 74-85
- Labauge R, Blard JM, Rachdi M (1974) L'ultrasonographie directionnelle à effet doppler dans le diagnostic des occlusions et sténoses serrées de l'axe carotidien. Correlation avec les données de l'angiographie. *Colloque de SFAUMB*, pp 78-84
- Lasjaunias P, Berenstein A (1987) *Surgical Neuroangiography*, vol I. Springer-Verlag, Berlin, pp 207-219
- Muller HR (1972) Contribution au diagnostic différentiel des hémiplegies vasculaires par les méthodes ultrasoniques. *Médecine et Hygiène* 30 : 1812-1813
- Pastore E, Pistolesse G, Agnoli A, Citone G, Fioravanti P (1972) La insufficienza cerebrovascolare da lesione dei vasi cerebrali nel tratto extracranico. *Min Anestesiol* 30: 533-539
- Planiol Th, Pourcelot L (1972) Etude des troubles de la circulation cérébrale par effet doppler. *Communication à la Soc Suisse Angiologie*, Dec 2, Genève, pp 44-47
- Romiti G (1893) *Trattato di Anatomia dell'Uomo*, vol I. Vallardi, Milano, pp 818-819 and 846-847
- Rindone A (1929) Studio sulle arterie tiroidee e sulla ghiandola tiroide con particolare riguardo al rapporto tra diametro arterioso e sviluppo della ghiandola. *Arch It Anat Embriol* 2 : 230-253
- Stebbens WE (1972) *Pathology of the cerebral blood vessels*. Mosby, London, pp 58-73
- Tzinas S, Droulias C, Harlaftis N, Akin J T, Gray S W, Skandalakis JE (1976) Vascular patterns of the thyroid gland. *Am Surgeon* 42 : 639-644
- Wolpert SM (1969) The thyroidea ima artery: an unusual collateral vessel. *Radiology* 92 : 333-334

Received June 16, 1993 / Resubmitted June 8, 1994 / Accepted in final form November 18, 1994

Exchange of Contents with Clinical Anatomy (contd. from page 64)

- 143 **Coexistent Diaphragmatic Herniation and Eventration: Embryologic Rationale for Therapeutic Interventions**
Lewis J. Kaplan, Charles F. Bellows, Glenn J.R. Whitman,
and Anne U. Barnes

Medical Education

- 152 **Teaching Anatomy in the Middle East: Opportunities and Challenges at a New Medical School**
P.F. Harris, M.F. Abu-Hijleh, and S. Moqattash
- 156 **The Surgeon as a Teacher of Anatomy**
Harold Ellis
- 162 **Abstracts Presented at the Winter Meeting of the British Association of Clinical Anatomists, December 20, 1993, York, United Kingdom**

166 Book Review

- 167 In Memoriam: Dr. Xian-Hua Gao
- 169 **American Association of Clinical Anatomists Criteria and Application for Membership**

171 Notices

VOLUME 7, NUMBER 4, 1994

Original Communications

- 173 **Morphometric Comparison of Computed Tomography to Magnetic Resonance Imaging in the Evaluation of the Lumbar Intervertebral Foramina**
Gregory D. Cramer, Joseph Howe, William V. Glenn, Jay Greenstein, and William Potvin
- 181 **Regional Lymph Drainage Routes From the Diaphragm in the Rat**
M.F. Abu-Hijleh and R.J. Scothorne
- 189 **Distribution of Mesothelial Stomata in the Rat**
M.F. Abu-Hijleh, O. Reid, J. McGadey, and R.J. Scothorne
- 204 **Typology of the Subclavian and Axillary Lymphatics**
Gen Murakami, Kazuyuki Shimada, Iwao Sato, Hiroyuki Kunieda,
Seiichi Suzuki, and Hajime Hoshi
- 215 **Observations on Detailed Histology of the Internal Thoracic Artery and Their Relevance to Its Comparatively Low Incidence of Atheroma**
Stephen B. Wharton, Nathaniel R.B. Cary, and G. Austin Gresham

Case Reports

- 219 **Vascular Anomalies of First and Second Unpaired Branches of the Abdominal Aorta: A Case Study**
S.J. Lewis

(contd. page 76)