



UNIVERSITÀ  
DEGLI STUDI  
FIRENZE

## FLORE

# Repository istituzionale dell'Università degli Studi di Firenze

### **Modified insertion technique for immediate implant placement into fresh extraction socket in the first maxillary molar sites: a 3-year**

Questa è la Versione finale referata (Post print/Accepted manuscript) della seguente pubblicazione:

*Original Citation:*

Modified insertion technique for immediate implant placement into fresh extraction socket in the first maxillary molar sites: a 3-year prospective study / Acocella A; Bertolai R; Sacco R.. - In: IMPLANT DENTISTRY. - ISSN 1056-6163. - STAMPA. - 19:(2010), pp. 220-228.

*Availability:*

The webpage <https://hdl.handle.net/2158/471658> of the repository was last updated on

*Terms of use:*

Open Access

La pubblicazione è resa disponibile sotto le norme e i termini della licenza di deposito, secondo quanto stabilito dalla Policy per l'accesso aperto dell'Università degli Studi di Firenze (<https://www.sba.unifi.it/upload/policy-oa-2016-1.pdf>)

*Publisher copyright claim:*

La data sopra indicata si riferisce all'ultimo aggiornamento della scheda del Repository FloRe - The above-mentioned date refers to the last update of the record in the Institutional Repository FloRe

(Article begins on next page)



# Modified Insertion Technique for Immediate Implant Placement into Fresh Extraction Socket in the First Maxillary Molar Sites: A 3-Year Prospective Study

Alessandro Acocella, DDS,\* Roberto Bertolai, MD, DMD,† and Roberto Sacco, DDS‡

Over the past 20 years, the use of dental implants has become an established method to support and retain fixed posterior prostheses.<sup>1</sup>

Stable and predictable esthetic and functional results can be achieved with different surgical and prosthetic management techniques of the hard and soft tissue around implant restorations.<sup>2</sup> It has been suggested that immediate implant placement after tooth extraction preserves the dimensions of the alveolar ridge regardless of the mode of tooth failure.<sup>3,4</sup> Such a restorative procedure, well documented in different clinical situations, was also recommended to reduce the number of surgical stages and the interval between tooth removal and the insertion of the implant-supported restoration.<sup>5-7</sup> Ideally, an implant could be placed at the time of maxillary molar extraction, and concomitant regenerative therapy could be performed if necessary.<sup>8</sup>

After tooth extraction, the residual alveolar ridge generally provides limited bone volume because of ongoing,

**Background:** Immediate implant placement after tooth extraction is a predictable solution in various clinical situations. The purpose of this study was to evaluate the predictability of a treatment, including the placement of implants, using a modified insertion technique at the time of maxillary molar extraction.

**Materials:** Sixty-eight patients with a total of 68 teeth scheduled for tooth extraction and immediate implant placement into fresh sockets were included in the study. Implants were positioned just after teeth removal and, in case of necessity, a regenerative therapy was performed at the same time. After a 3-month period

of healing, implants were restored with single crown fixed prostheses.

**Results:** All implants restored with single crowns were monitored for 36 months; only, 3 implants failed with a cumulative survival rate of 97.96%.

**Conclusion:** The combination of atraumatic extraction of maxillary molars, sufficient residual inter-radicular bone, and the use of appropriate regenerative material at the time of implant insertion, represents a predictable long-term treatment. (Implant Dent 2010;19:1-●●●)

**Key Words:** dental implants, immediate implant placement, maxillary area, postextraction sites

progressive bone resorption. Healing events within postextraction sockets reduce the dimensions of the socket over time. A reduction of ~50% in both horizontal and vertical directions has been observed during 12 months, with two-thirds of the reduction occurring in the first 3 months. Reductions were slightly greater in molar than in premolar sites and in the mandible when compared to the maxilla.<sup>9</sup>

Bone modeling and remodeling of the socket after tooth extraction was documented by Botticelli et al,<sup>10</sup> so that further clinical considerations can be stated in planning for an ideal 3-dimensional implant position.<sup>11</sup>

Clinical studies demonstrated that, after implant installation, a mar-

ginal gap <2 mm occurring between the implant body and the bony wall in an extraction socket may predictably heal with new bone formation and defect resolution. The finding that localized marginal defects that occur in extraction sockets after implant placement may heal without the use of space maintaining barrier membranes or filler material is the sign that the hard-tissue formation was the result of proper clot maturation in the protected environment that was established in the confined defect lateral of the implant.<sup>10-12</sup>

The rate and pattern of bone resorption may be altered if pathologic and traumatic processes have damaged 1 or more of the bony walls of the

\*Specialist in Oral Surgery, Department of Odontostomatology, Division of Maxillo-Facial Surgery, Faculty of Medicine, University of Florence, Italy.

†Director of Maxillo-Facial Surgery Division, Department of Odontostomatology, Faculty of Medicine, University of Florence, Italy.

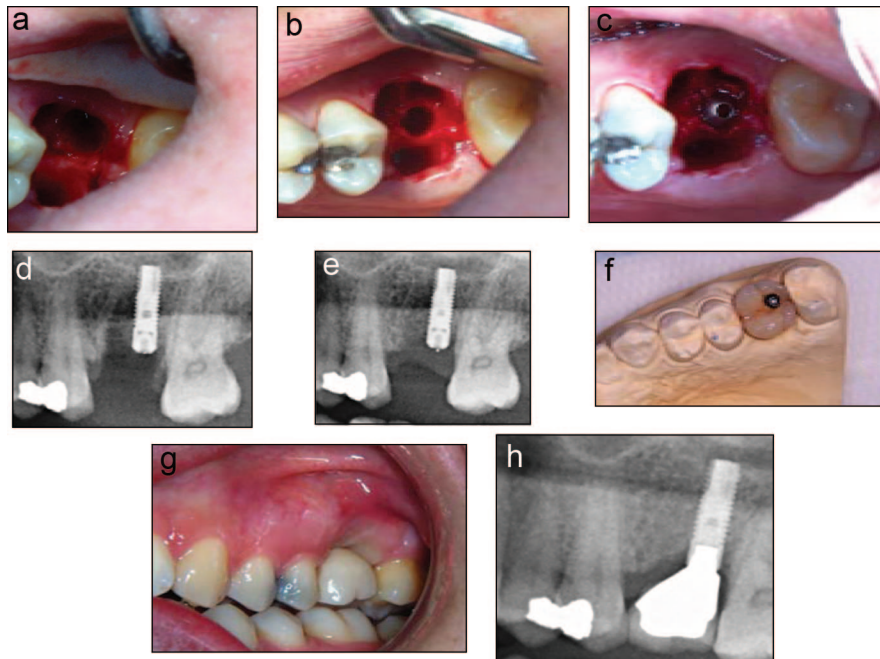
‡Oral Surgery Program Resident, Department of Odontostomatology, Faculty of Medicine-University of Sassari, Italy.

Reprint requests and correspondence to: Sacco Roberto, DDS, Via Alcide De Gasperi, 113 Prato 59100, Italy, Phone: +39 349-5858220, E-mail: sacco roberto@yahoo.it

ISSN 1056-6163/10/01903-001  
Implant Dentistry  
Volume 19 • Number 3  
Copyright © 2010 by Lippincott Williams & Wilkins  
DOI: 10.1097/ID.0b013e3181d8e2fe

**Table 1.** Reason for the Extraction in Both Genders

Cause of Teeth Extraction in Both Genders	Caries	Fracture	Total
Male	13	24	37
Female	10	21	31
Total	23	45	68



**Fig. 1.** (a) clinical aspect of bone septum with dimension  $>2.5$  mm; (b) surgical step, tapered-end osteotome utilized to compress and implode the interradicular bone beneath the tip of the osteotome and to spread the interradicular bone lateral to the osteotome, with tapered-end osteotome to compress and implode the interradicular bone; (c) implant placed in the interradicular bone; (d) radiograph after surgical procedure; (e) radiograph after 3 months of healing; (f) metal ceramic crown on the model cast; (g) clinical aspect of the metal ceramic crown; (h) radiograph at 36 months.

socket. In these circumstances, fibrous tissue will likely occupy part of the socket, preventing normal healing and osseous regeneration. These morphologic changes may affect the successful placement and osseointegration of dental implants.<sup>13</sup>

Augmentation of an extraction socket at the time of tooth removal has demonstrated to be a reliable technique to regenerate damaged alveolar bone.<sup>8,14,15</sup> Such a treatment approach, in fact, helps attenuate the alveolar remodeling and atrophy, which would occur after tooth removal in the absence of implant placement and/or regenerative therapy.<sup>16</sup>

Immediate implant insertion in maxillary molar extraction sockets raises a series of challenges for clini-

cians. In the first instance, there is the need to preserve the inter-radicular bone at the time of tooth removal and there is the often problematic position of the maxillary sinus around the roots of the tooth to be extracted. Moreover, the compromised nature of the residual inter-radicular bone in case of periodontal diseases and the difficulty in positioning the implant, as a result of the position of the residual inter-radicular bone, so that it can receive a correct prosthetic rehabilitation.<sup>17</sup>

For these reasons, single-rooted teeth, predominately incisors and premolars, are the most frequently chosen sites for immediate implantation and very little data can be found in the literature about immediate placement in the molar area.<sup>16-18</sup> Placement of an

implant in 1 of the 3 existing root sockets after maxillary molar removal will result in a less-than-ideal implant emergence profile, significant off-angle loading, and the creation of a cantilever effect either buccally, mesially, or distally, depending on which extraction socket is chosen to accept the implant.

Some authors report that 5-year cumulative survival rate (CSR) of maxillary implants placed at the time of maxillary molar extraction (and their subsequent restoration with single crowns) is 82%.<sup>18</sup> According to the opinion of other authors,<sup>18,19</sup> the restoration of implants in a non-ideal position may cause potential difficulties maintaining plaque control and raises concerns related to the off-angle forces applying to the implant during function and/or parafunction affecting the success of the treatment.

This article documents a modified technique introduced by Summers,<sup>20</sup> which helps facilitate implant placement in an ideal position at the time of maxillary molar extraction. This technique has a conservative therapeutic approach to sinus augmentation through the implant osteotomy site where, afterwards, autogenous or non-autogenous particulate regenerative material is placed before implant insertion. The modifications to this technique have been published by Fugazzotto.<sup>21</sup>

When compared to the Fugazzotto technique, the method we followed included differences such as: selection criteria of patients, surgical approach to flap design type of implant placed, and time of loading.

## MATERIALS AND METHODS

This research was conducted on a group of 94 eligible subjects of which only 68 were included in this study (37 men, 31 women, mean age  $29.19 \pm 3.62$ ) (Table 1). Of these 94 patients, 26 were excluded for different reasons: 10 of them had the septum fractured after the extraction; in 16 patients, the implant insertion torque was inferior to 20 Nmc.

Primary criteria of exclusion were periodontal disease and insufficient wide interradicular septum ( $>2.5$  mm) (Figs. 1, a and 2, a). Periodontal dis-



ease, in particular, affects severely the bone quality and determines high rates of implant's infection and failure. Furthermore, general exclusion criteria were acute myocardial infarction within the past 6 months, uncontrolled coagulation disorders, uncontrolled metabolic diseases (diabetes mellitus, bone pathologies), patients treated with radiotherapy to the head/neck district within the past 24 months, patients treated with intravenous bisphosphonates, patients with psychological or psychiatric problems, heavy smokers (>10 cigarettes/day), and bruxism.

All implants were placed exclusively in the first permanent molar socket between September 2004 and September 2005 in the Department of Oral and Maxillofacial Surgery of the University of Florence.

#### Clinical and Surgical Approach

A thorough intraoral examination was executed in all patients with the help of panoramic and periapical radiographs to assess the periodontal/endodontic status of the tooth. Before initiating the therapy, comprehensive treatment plans were agreed among the treating clinicians and laboratory technicians.

After administration of local anesthesia, a sulcular buccal incision was made around the tooth to be extracted (periotomy). The tooth to be removed was, then, trisected and each root was removed individually, unless 3 distinct roots were not clearly visible. In this case, roots were separated and, after, removed. Debridement of the socket followed to remove any visible granulation tissue and periapical lesions.

A round bur was used at 600 rpm under copious irrigation with sterile saline solution to make a notch in the crestal section of the residual interradicular bone. A tapered-end osteotome with a maximum diameter of 2.2 mm was used to compress and implode the interradicular bone beneath the tip of the osteotome and to spread the interradicular bone lateral to the osteotome. Then, a 2.8-mm wide tapered osteotome was used in the same manner as was a subsequent 3.5-mm wide osteotome increasing diameters, which corresponded to the drilling se-

quence for the implant to be placed (Figs. 1, b and 2, b, c).

If additional length was required to place the implant at the desired position, the osteotome was malleted to the appropriate depth, lifting the floor of the sinus. In no instances did the osteotome extend beyond the original floor of the sinus for a distance >2 mm. The localized sinus lift allowed for the engagement of the sinus floor with the apical part of the implants thus enhancing primary stability.

The implant used in this study was Astra Tech Osseospeed (Astra Tech, Molndal, Sweden). Osseospeed is a further development of the moderately roughened (grit blasted with titanium dioxide particles) titanium surface TioBlast (Astra Tech). Osseospeed gains its additional surface characteristics via a chemical (fluoride) treatment and a slight topographic modification of the TioBlast surface.<sup>22</sup> The implant diameter used in this study was 4.0 mm with 13 length mm ( $n = 29$  or 42.64%) and 4 mm with length 11 mm ( $n = 39$  or 57.35%), for all of implants the insertion torque was from 20 to 25 Nmc (Figs. 1, c and 2, d).

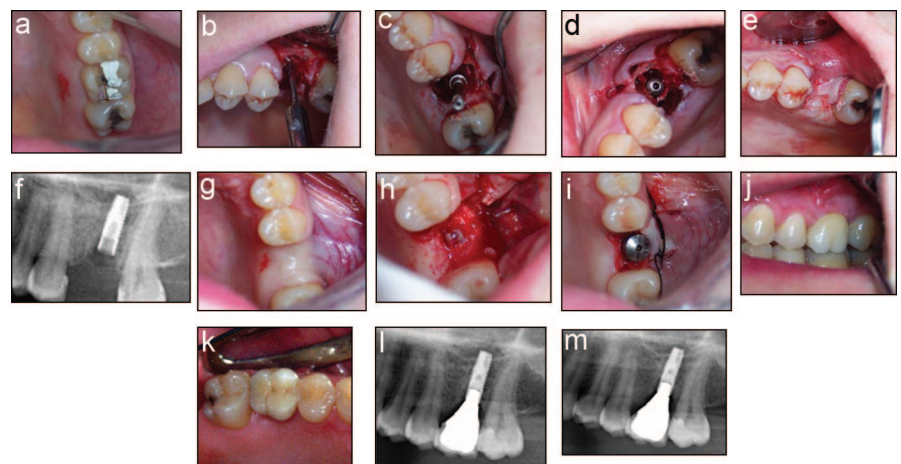
Implants were positioned just after maxillary molar extraction and, if

necessary, regeneration of sockets was carried out with BioOss (Osteohealth Co., Shirley, NY) contemporarily.

Particulate graft material was placed in the residual extraction socket defect surrounding the implant except when the dimension of the horizontal defect between the outer part of the implant and the surrounding alveolar bone did not exceed 3 mm.

No covering membrane was used, mucoperiosteal flaps were mobilized and sutured without tension with absorbable 4-0 suture (Vicryl, Ethicon, Johnson & Johnson Roma, Italy) in order to obtain primary wound closure (Fig. 2, e).

In some cases, extraction was not executed with the elevation of a mucoperiosteal flap in order to maximize the flow of blood in the implant site and when regenerative therapy was not necessary (Fig. 1, b and c). Concerning flap design, a full-thickness mucoperiosteal buccal flap was reflected, mesial vertical releasing incision was placed on the mesial aspect of the tooth mesial to the tooth to be removed, and a distal vertical releasing incision was placed on the distal aspect of the tooth distal to the tooth to be removed. No palatal flap was ele-



**Fig. 2.** (a) clinical aspect of first molar with a vertical fracture; (b) surgical step, after elevation of a mucoperiosteal flap, with tapered-end osteotome to compress and implode the interradicular bone; (c) drill in the socket which corresponded at the last tapered osteotome used before implant placement; (d) implant placed in the interradicular bone; (e) suture of the mucoperiosteal flaps without tension with absorbable 4-0 suture in any cases where we used the graft material; (f) radiograph after surgical procedure; (g) particular aspect of healing time of soft tissue after 3 months; (h) second surgical step (we can observed bone tissue all around the fixture); (i) second surgical step: we performed a rolling-flap to maintain a strip of keratinized mucosa; (j) clinical aspect of the metal ceramic crown; (l) radiograph at 24 months; (m) radiograph at 36 months.

AQ: 3

vated in order to maximize the flow of blood from the palate.

Postoperatively, all patients were prescribed 10-day antibiotic therapy with amoxicillin 1000 mg twice a day (Zimox, Pfizer, Latina, Italy), ibuprofen (Brufen; Abbott SpA, Campoverde (Lt), Italy) anti-inflammatory/analgesic drug, 600 mg twice a day for 1 to 3 days after surgery, and mouthwash with chlorhexidine 0.2% (Curasept; Curaden Health Care Srl, Milano, Italy), twice a day for 2 to 3 weeks.

## RESULTS

A total of 68 implants were inserted into 68 subjects. Regenerative therapy was performed at the time of implant placement in 48 sites with localized sinus augmentation. Twenty sites did not require regenerative therapy because the residual extraction socket had been obliterated by the implant that was placed or the horizontal

defect dimension between the implant and extraction socket wall was  $<3.0$  mm in all directions.

Before implant uncovering, panoramic and periapical radiographs were taken to assess bone regeneration status and its maturity. After implant uncovering, all implants demonstrated to be clinically immobile and seemed on course to fulfill the clinical definition of osseointegration (Figs. 1, d, e and 2, f).

Primary soft tissue closure was maintained until after 3 months from implant uncovering in 14 of 68 sites (Fig. 2, g-i). The sites that exhibited loss of primary closure showed partial exposure of the implant healing screws. All implants were restored with single metal ceramic crowns (VitaVM13, Milan, Italy) (Figs. 1, f, g and 2, j, k), and all implants were monitored for 36 months (Figs. 1, h and 2, l, m).

As a result of our assessment, 1 implant failed 4 weeks after operation. The patient presented with a fistula around the implant and noticeable implant mobility. Hence, the implant was removed and the socket was grafted. A new implant was placed and restored, although it was not included in our statistics because it was not placed at the time of maxillary molar extraction. Furthermore, 2 implants on 2 different patients appeared mobile at the time of implant loading 10 months after insertion.

A breakdown of implant survival and failure rate is listed in Table 2. CSR was 97.96% (Graph 1).

## DISCUSSION

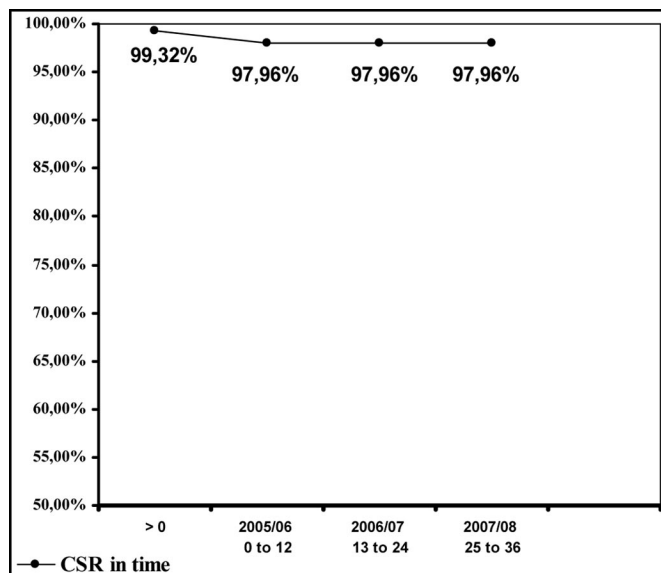
Immediate dental implant placement is a recent procedure in oral rehabilitation. It has demonstrated to have several advantages, such as a smaller number of surgical procedures, lower cost, and reduction of the edentulism period, compared with the conventional technique. During the past 10 years, numerous clinical studies have shown that immediate dental implant placement is successful when sites are carefully selected. Alveolar ridge resorption after tooth extraction may considerably reduce the residual bone volume and compromise the favorable positioning of implants required for optimal restoration.<sup>23-25</sup>

Immediate implant placement after tooth extraction has been advocated as it preserves the dimensions of the alveolar ridge regardless of the mode of tooth failure.<sup>4,26</sup> On the other hand, these findings are not confirmed by other authors.<sup>10,27</sup> Implant placement failed to preserve the hard tissue dimension of the ridge following tooth extraction. The buccal, as well as the lingual bone walls, were resorbed. At the buccal aspect, this resulted in some marginal loss of osseointegration. Apicocoronal crestal bone height reduction of 0.7 to 1.5 mm have been reported after 4 to 6 months.<sup>27,28</sup>

The treatment approach described in this article offers a number of advantages including the less invasive nature of the surgical procedure and a shorter course of therapy. Summers' technique allows for the execution of such a local-

**Table 2.** Comparison of Time of Loading With Implants Failure and Cumulative Survival Rate (CSR)

Assessment Period	Number of Implants Survive	Implants Failures	Interval of Failure Rate (%)	Cumulative Survival Rate (%)
Before abutment connection	67	1	0.68	99.32
0 to 12 (Loading)	65	2	2.04	97.96
13 to 24 (Loading)	65	0	2.04	97.96
25 to 36 (Loading)	65	0	2.04	97.96



**Graph 1.** Expression in percent of cumulative survival rate (CSR) during 36 months.

ized augmentation at the time of maxillary molar extraction and has previously been demonstrated that it secure a high degree of predictability.<sup>17</sup>

Modification to this technique has been presented that permits for the placement of implants in ideal prosthetic positions at the time of the removal of maxillary molars, with or without localized sinus augmentation therapy as required.

To be considered a viable treatment option at the time of maxillary molar extraction, immediately placed implants must demonstrate predictability of osseointegration. Clinical reports have suggested that patients with periodontal or endodontic infections represent risk cases for implant infection and failure.<sup>29,30</sup> In fact, endosseous dental implants at infected sites are to be considered as a contraindication for immediate implantation.

For this reason, the protocol of our study included a strict selection of patients and a correct debridement of dentoalveolar sockets, thus obtaining a CSR of 97.96%.

Using the outlined treatment approach helps eliminate many clinical compromises often encountered when placing implants at the time of maxillary molar extraction. These compromises include nonideal implant positioning in 1 of the 3 extraction sockets and a loss of ideal alveolar ridge morphology in an effort to attain soft tissue closure during healing time.

The development of new clinical dental implant protocols help reduction of treatment time and of patient discomfort, achievement of high predictability, and excellent aesthetic outcomes, according with exclusion criteria universally accepted in implant surgery.<sup>31</sup>

In this work, the results reported with the use of a modification of the Summers' technique demonstrate a high degree of predictability in the placement of implants in ideal prosthetic positions at the time of the removal of maxillary molars. Key success factors of this technique, even in case of thin interdental septum are primary stability of the fixture inserted engaging the sinus floor and a correct flap design to obtain passive primary closure associated with

ridge augmentation therapy when necessary.

## CONCLUSION

Accurate diagnosis, appropriate treatment planning, selection criteria of patients, and meticulous implant site development, at the time of maxillary molar removal, are essential in achieving predictable treatment modality for implant restoration.

Through the use of the technique described here, all such therapeutic compromises may, at worst, be significantly minimized and, at best, be predictably avoided. The information provided in this study might help clinicians to improve their decision making with the aim of enhancing implant success. However, randomized controlled clinical trials are needed to further validate and refine this implant surgical approach.

## Disclosure

The authors claim to have no financial interest, directly or indirectly, in any entity that is commercially related to the products mentioned in this article.

## REFERENCES

1. Liu CL. The impact of osseointegrated implants as an adjunct and alternative to conventional periodontal prosthesis. *Compend Contin Educ Dent*. 2005;26:653-654.
2. Sammartino G, Marenzi G, di Lauro AE, et al. Aesthetics in oral implantology: Biological, clinical, surgical, and prosthetic aspects. *Implant Dent*. 2007;16:54-65.
3. Lazzara RJ. Immediate implant placement into extraction sites: Surgical and restorative advantages. *Int J Periodontics Restorative Dent*. 1989;9:332-343.
4. Rosenquist B, Grenthe B. Immediate placement of implants into extraction sockets: Implant survival. *Int J Oral Maxillofac Implants*. 1996;11:205-209.
5. Schwartz-Arad D, Chaushu G. Placement of implants into fresh extraction sites: 4 to 7 years retrospective evaluation of 95 immediate implants. *J Periodontol*. 1997;68:1110-1116.
6. Schwartz-Arad D, Chaushu G. The ways and wherefores of immediate placement of implants into fresh extraction sites: A literature review. *J Periodontol*. 1997;68:915-923.

7. Schropp L, Isidor F, Kostopoulos L, et al. Interproximal papilla levels following early versus delayed placement of single-tooth implants: A controlled clinical trial. *Int J Oral Maxillofac Implants*. 2005;20:753-761.

8. Castellon P, Yukna RA. Immediate dental implant placement in sockets augmented with HTR synthetic bone. *Implant Dent*. 2004;13:42-48.

9. Schropp L, Wenzel A, Kostopoulos L, et al. Bone healing and soft tissue contour changes following single-tooth extraction: A clinical and radiographic 12-month prospective study. *Int J Periodontics Restorative Dent*. 2003;23:313-323.

10. Botticelli D, Berglundh T, Linde J. Hard-tissue alterations following immediate implant placement in extraction sites. *J Clin Periodontol*. 2004;31:820-828.

11. Belser U, Buser D, Higginbottom F. Consensus statements and recommended clinical procedures regarding esthetics in implant dentistry. *Int J Oral Maxillofac Implants*. 2004;19 (Suppl):73-74.

12. Covani U, Cornelini R, Barone A. Vertical crestal bone changes around implants placed into fresh extraction sockets. *J Periodontol*. 2007;78:810-815.

13. Barone A, Rispoli L, Vozza I, et al. Immediate restoration of single implants placed immediately after tooth extraction. *J Periodontol*. 2006;77:1914-1920.

14. Nevins M, Mellonig JT. Enhancement of the damaged edentulous ridge to receive dental implants: A combination of allograft and a Gore-Tex membrane. *Int J Periodontics Restorative Dent*. 1992;12:96-111.

15. Lekovic V, Camargo PM, Klokkevoel PR, et al. Preservation of alveolar bone in extraction sockets using bioabsorbable membranes. *J Periodontol*. 1998;69:1044-1049.

16. Fugazzotto PA. Treatment options following single rooted tooth removal: A literature review and proposed hierarchy of treatment selection. *J Periodontol*. 2005;76:821-831.

17. Fugazzotto PA. Sinus floor augmentation at the time of maxillary molar extraction: Technique and report of preliminary results. *Erratum* 1999;14:902. *Int J Oral Maxillofac Implants*. 1999;14:536-542.

18. Schwartz-Arad D, Grossman Y, Chaushu G. The clinical effectiveness of implants placed immediately into fresh extraction sites of molar teeth. *J Periodontol*. 2000;71:839-844.

19. Hsu M-L, Chen F-C, Kao H-C, et al. Influence of off-axis loading of an anterior maxillary implant: A 3-dimensional finite element analysis. *Int J Oral Maxillofac Implants*. 2007;22:301-309.

20. Summers RB. A new concept in maxillary implant surgery: The osteotome technique. *Compendium*. 1994;15:152, 154-156, 158 passim; quiz 162.

AQ:2



21. Fugazzotto PA. Maintaining primary closure after guided bone regeneration procedures: Introduction of a new flap design and preliminary results. *J Periodontol*. 2006;77:1452-1457.

22. Ellingsen JE, Johansson CB, Wennerberg A, et al. Improved retention and bone-to-implant contact with fluoride-modified titanium implants. *Int J Oral Maxillofac Implants*. 2004;19:659-666.

23. Bartee BK. Extraction site reconstruction for alveolar ridge preservation. Part 1: Rationale and materials selection. *J Oral Implantol*. 2001;27:187-193.

24. Kan JY, Shiotsu G, Rungcharas-aeng K, et al. Maintaining and attenuating periodontal tissues for aesthetic

implant placement. *J Oral Implantol*. 2000;26:35-41.

25. Huys LW. Replacement therapy and the immediate post-extraction dental implant. *Implant Dent*. 2001;10:93-102.

26. Lazzara RJ. Use of osseointegrated implants for replacement of single teeth. *Compendium*. 1989;10:550-554.

27. Araújo MG, Sukekava F, Wennström JL, et al. Tissue modeling following implant placement in fresh extraction sockets. *Clin Oral Implants Res*. 2006;17:615-624.

28. Lops D, Chiapasco M, Rossi A, et al. Incidence of inter-proximal papilla between a tooth and an adjacent immediate implant placed into a fresh extraction socket: 1-year prospective study. *Clin Oral Implants Res*. 2008;19:1135-140.

29. Ayangco L, Sheridan PJ. Development and treatment of retrograde peri-implantitis involving a site with a history of failed endodontic and apicoectomy procedures: A series of reports. *Int J Oral Maxillofac Implants*. 2001;16:412-417.

30. Polizzi G, Grunder U, Goené R, et al. Immediate and delayed implant placement into extraction sockets: A 5-year report. *Clin Implant Dent Relat Res*. 2000;2:93-99.

31. Misch CE, Perel ML, Wang HL, et al. Implant success, survival, and failure: The International Congress of Oral Implantologists (ICOI) Pisa Consensus Conference. *Implant Dent*. 2008;17:5-15.



## Abstract Translations

### GERMAN / DEUTSCH

**AUTOR(EN):** Alessandro Acocella, DDS, Roberto Bertolai, MD, DMD, Roberto Sacco, DDS

**Veränderte Technik zur Einsetzung von unmittelbaren Implantaten in frische Extraktionshöhlen im Bereich der ersten Backenzähne: eine über drei Jahre geführte Prospektivstudie**

**ZUSAMMENFASSUNG: Hintergrund:** Die unmittelbare Implantatsetzung nach Zahnextraktion ist eine vorhersagbar zuverlässige Lösung in verschiedenen klinischen Szenarien. Diese Studie zielte darauf ab, die Vorhersagbarkeit einer Behandlung zu beurteilen, und dies inklusive der Einpflanzung von Implantaten, wobei eine veränderte Methode zur Einsetzung zum Zeitpunkt der Extraktion der Backenzähne im Oberkiefer vorgenommen wurde. **Materialien und Methoden:** 68 Patienten mit insgesamt 68 zur Extraktion vorgesehenen Zähnen und einer sofortigen Implantatsetzung nahmen an der Studie teil. Die Implantate wurden direkt nach der Entfernung der Zähne eingesetzt. Sofern erforderlich wurde zugleich eine regenerative Therapie vorgenommen. Nach einer Heilungszeit von 3 Monaten wurden die Implantate mittels festen Prothesen mit Einzelkronen wiederhergestellt. **Ergebnisse:** Alle mit Einzelkronen wiederhergestellten Implantate wurden über einen Zeitraum von 35 Monaten beobachtet; nur 3 Implantate versagten innerhalb einer kumulativen Überlebensrate (KÜR) von 97,96%. **Schlussfolgerung:** Die Kombination von atraumatischer Extraktion der Backenzähne im Oberkiefer, ausreichendem verbleibendem interradikulärem Knochengewebe und der Verwendung des geeigneten regenerativen Materials zum Zeitpunkt der Implantierung stellt eine vorhersagbar gute langfristige Behandlungsvariante dar.

**SCHLÜSSELWÖRTER:** Zahnimplantate, unmittelbare Implantateinpflanzung, Oberkieferbereich, Bereiche nach Extraktion

### SPANISH / ESPAÑOL

**AUTOR(ES):** Alessandro Acocella, DDS, Roberto Bertolai, MD, DMD, Roberto Sacco, DDS

**Técnica de inserción modificada para la colocación inmediata de un implante en una cavidad fresca de extracción en los primeros molares maxilares: Estudio prospectivo de tres años**

**ABSTRACTO: Antecedentes:** La colocación inmediata del implante luego de la extracción de un diente es una solución previsible en varias situaciones clínicas. El propósito de este estudio fue evaluar la previsibilidad de un tratamiento, que incluye la colocación de implantes, usando una técnica de inserción modificada en el momento de la extracción de una muela maxilar. **Materiales y Métodos:** Sesenta y ocho pacientes con un total de 68 dientes programados para su extracción y colocación inmediata de un implante en las cavidades frescas participaron en el estudio. Los implantes fueron colocados luego de la extracción del diente y, en caso de necesidad, se realizó una terapia regenerativa al mismo tiempo. Después de un período de curación de 3 meses, se restauraron los implantes con prótesis fijas simples con coronas. **Resultados:** Todos los implantes restaurados con coronas simples fueron observados durante 36 meses; solamente 3 implantes fallaron con una tasa acumulativa de supervivencia (CSR por sus siglas en inglés) del 97,96%. **Conclusión:** La combinación de extracción sin trauma de molares maxilares, suficiente hueso residual entre las raíces y el uso de un material regenerativo apropiado en el momento de la colocación del implante, representa un tratamiento predecible de largo plazo.

**PALABRAS CLAVES:** implantes dentales, colocación inmediata del implante, zona maxilar, lugares postextracción

## PORTUGUESE / PORTUGUÊS

**AUTOR(ES):** Alessandro Acocella, Cirurgião-Dentista, Roberto Bertolai, Médico, Doutor em Medicina Dentária, Roberto Sacco, Cirurgião-Dentista

**Técnica de inserção modificada para colocação imediata de implante em alvéolo de extração recente nos locais do primeiro molar maxilar: estudo em perspectiva de três anos**

**RESUMO:** *Antecedentes:* a colocação imediata de implante após a extração do dente é uma solução previsível em diversas situações clínicas. O propósito deste estudo era avaliar a previsibilidade de um tratamento, incluindo a colocação de implantes, usando uma técnica de inserção modificada no momento da extração do molar maxilar. *Materiais e Métodos:* sessenta e oito pacientes com um total de 68 dentes com horário marcado para extração de dentes e imediata colocação de implante em alvéolos recentes foram incluídos no estudo. Os implantes foram posicionados logo após a remoção dos dentes e, em caso de necessidade, uma terapia regenerativa foi realizada ao mesmo tempo. Após um período de cura de 3 meses, os implantes foram restaurados com próteses fixas com uma única coroa. *Resultados:* todos os implantes restaurados com coroas únicas foram monitorados durante 36 meses; apenas 3 implantes falharam, com uma taxa de sobrevivência cumulativa de 97,96%. *Conclusão:* a combinação de extração atraumática de molares maxilares, osso interradicular residual suficiente e o uso de material regenerativo apropriado no momento da inserção do implante representam um tratamento previsível de longo prazo.

**PALAVRAS-CHAVE:** implantes dentários, colocação imediata de implante, área maxilar, locais de pós-extração

## RUSSIAN / РУССКИЙ

**АВТОРЫ:** Alessandro Acocella, доктор хирургической стоматологии, Roberto Bertolai, доктор медицины, доктор стоматологии, Roberto Sacco, доктор хирургической стоматологии.

**Измененная методика немедленной установки имплантата в свежую лунку непосредственно после удаления верхнечелюстного моляра: трехлетнее проспективное исследование**

**РЕЗЮМЕ.** *Предварительные данные:* установка имплантата непосредственно после удаления зуба является прогнозируемым решением во многих ситуациях клинической практики. Целью данного исследования являлась оценка прогнозируемости лечения, включая установку имплантатов, с использованием измененной методики установки имплантата сразу после удаления моляра в верхней челюсти. *Материалы и методы.* В

исследовании участвовали шестьдесят восемь пациентов, у которых должны были удалить зуб (в общей сложности – 68 зубов) и которым проводилась немедленная установка имплантатов в свежие лунки после удаления зуба. Имплантаты устанавливались непосредственно после удаления зуба. В случае необходимости одновременно проводилась регенеративная терапия. После 3-месячного периода заживления на имплантаты были установлены несъемные протезы в виде одиночной коронки. **Результаты.** Все имплантаты, на которые были установлены протезы в виде одиночной коронки, наблюдались в течение 36 месяцев. Не прижилось только 3 имплантата. В итоге общий процент степени приживаемости имплантатов (CSR) составил 97,96%. **Вывод.** Сочетание атравматичного удаления верхнечелюстных моляров, достаточного количества остаточной межкорневой костной перегородки и использования соответствующего материала для регенеративной терапии в момент установки имплантата представляет собой лечение с прогнозируемым длительным результатом.

**КЛЮЧЕВЫЕ СЛОВА:** зубные имплантаты, немедленная установка имплантата, область верхней челюсти, лунки после удаления зуба

## TURKISH / TÜRKÇE

**YAZARLAR:** Alessandro Acocella, DDS, Roberto Bertolai, MD, DMD, Roberto Sacco, DDS

**Birinci maksiller molar taze çekim yerlerinde hemen implant yükleme için değiştirilmiş yerleştirme tekniği: Üç yıllık prospektif bir çalışma**

**ÖZET: Bilgi:** Diş çekiminden hemen sonra implant yükleme, çeşitli klinik durumlarda tahmin edilen sonuçlar veren bir çözüm yoludur. Bu çalışmanın amacı, maksiller molar çekiminde modifiye yerleştirme tekniği kullanılarak yapılan implant yükleme tedavisinin ne derece tahmin edilebilir sonuçlar verdiğini değerlendirmektir. **Gereç ve Yöntem:** Bu çalışmaya, toplam 68 diş çekilen ve taze çekim yerlerine hemen implant yüklenen 68 hasta dahil edildi. İmplantlar hemen diş çekimi yapıldıktan sonra konumlandırıldı ve gerektiğinde, aynı zamanda rejeneratif terapi de yapıldı. Üç aylık bir iyileşme döneminden sonra implantlara tek kronlu sabit protezlerle restorasyon uygulandı. **Bulgular:** Tek kron ile restore edilen tüm implantlar 36 ay boyunca izlendi; sadece 3 implant başarısız oldu ve kümülatif sağkalım oranı %97.96 olarak bulundu. **Sonuç:** Travma olmadan maksiller molar dişlerin çekimi, yeterli rezidüel interradiküler kemik varlığı ve implantın yerleştirildiği zaman uygun rejeneratif materyalin kullanılması uzun vadeli tedavide önceden tahmin edilebilir sonuçların alınmasını sağlar.

**ANAHTAR KELİMELELER:** dental implantlar, hemen implant yükleme, maksiller alan, çekim sonrası yer



## JAPANESE / 日本語

## 上顎第一大臼歯部位抜歯窩への即時インプラント埋入更新技術:3年間前向き研究

共同研究者氏名: アレサンドロ・アコセラ (Alessandro Acocella) DDS, ロベルト・バートライ (Roberto Bertolai) MD, DMD, ロベルト・サッコ (Roberto Sacco) DDS

## 研究概要:

背景: さまざまな臨床条件において抜歯直後の即時インプラント埋入は予知性を備えた処置である。当研究は上顎臼歯抜歯時点で更新技術を用いるインプラント埋入を範囲内に入れた治療法の予知性評価を目指した。

素材と方法: 総計68本抜歯後、抜歯窩へ即時インプラント埋入予定の患者68名を当研究の対象とした。インプラントは抜歯直後に埋入し、必要に応じ同時点で再生治療を施行した。3ヶ月の治療期間を経て、インプラントに固定式シングルクラウンを装着し機能回復した。

結果: シングルクラウン装着で補綴したインプラントを36ヶ月にわたり調査した; 失敗症例は3本のみで累積生存率(CSR)は97.96%という結果を示した。

結論: 上顎臼歯非侵襲的抜歯処置と十分な残存根間骨組織に加え、インプラント埋入時点の適切な再生素材応用の組合せが予知性を備えた長期治療の成果につながる

キーワード: デンタルインプラント、即時インプラント埋入、上顎骨部位、抜歯窩部位

## CHINESE / 中国語

## 植體立即植入上顎第一臼歯部位之新拔牙齒槽窩的改良插入技術: 3 年前瞻性研究

作者: Alessandro Acocella, DDS, Roberto Bertolai, MD, DMD, Roberto Sacco, DDS

## 摘要:

背景: 拔牙後立即植體植入是各種臨床情況中可預測的解決方案。本研究的目的是評估在上顎臼齒拔牙時使用改良的插入技術治療的可預測性, 包括植入植體。

資料與方法: 研究包含 68 名患者, 預定合計拔除 68 顆牙齒並立即植入植體於新的齒窩槽。植體於拔牙後立即植入定位, 並在必要時同時進行再生治療。經過 3 個月的治疗後, 以單一齒冠固定假牙修復植體。

結果: 監測以單一齒冠修復的所有植體 36 個月; 只有 3 例種植失敗, 累積存活率 (CSR) 為 97.96%。

結論: 結合無創傷性的上顎臼齒拔牙、足夠的剩餘根間骨以及在植體插入時使用適當的再生材料, 是一可預測的長期治療方式。

關鍵字: 牙科植體、立即植體植入、上頷區、拔牙後部位。

**KOREAN / 한국어****제 1 대구치 발치 부위에서의 임플란트 즉시 식립을 위한 변형 삽입 기법: 3년의 전향적**

**저자:** 알레산드로 아코첼라 (Alessandro Acocella), DDS, 로베르토 베르톨레 (Roberto Bertolai), MD, DMD, 로베르토 사코 (Roberto Sacco), DDS

**요약:**

**배경:** 발치 후 즉시 식립은 다양한 임상 상황에서 사용될 수 있는 예측 가능한 해법이다. 본 연구의 목적은 상악 대구치 발치 시점에서 변형된 삽입기법을 사용하여, 임플란트의 식립을 포함하여 치료의 예측 가능성을 평가하는 것이었다.

**재료 및 방법:** 본 연구에는 총 68개의 치아 발치와 발치공예의 임플란트 즉시 식립이 예정된 68명의 환자들이 포함되었다. 발치 후 임플란트를 즉시 식립하였고, 필요한 경우 재생치료요법을 동시에 수행하였다. 치유기간 3개월 이후, 단일 크라운(crown) 고정 보철물로 임플란트를 수복하였다.

**결과:** 단일 크라운으로 수복된 모든 임플란트를 36개월 동안 모니터한 결과, 누적 생존률(CSR)은 97.96%이었고, 3개의 임플란트만이 실패하였다.

**결론:** 상악 대구치의 비외상성 발치, 충분한 잔존 치근간 골 및 임플란트 삽입 시점에서의 적절한 재생 물질 사용의 조합은 예측 가능한 장기 치료를 나타낸다.

**키워드:** 치과 임플란트, 임플란트 즉시 식립, 상악 부위, 발치 후 부위

## AUTHOR QUERIES

### AUTHOR PLEASE ANSWER ALL QUERIES

1

AQ1— Kindly check whether the minor edit made to the title is OK.

AQ2— Please note Ref. 27 is the duplicate of Ref. 4, hence Ref. 27 has been deleted and renumbered. Kindly check whether it is OK.

AQ3— Please define label 'k' in figure 2 caption.

---