UNIVERSITÀ DEGLI STUDI FIRENZE

FLORE
Repository istituzionale dell'Università degli Studi di Firenze

Incidental and metastatic adrenal masses

Questa è la Versione finale referata (Post print/Accepted manuscript) della seguente pubblicazione:

Original Citation:

Incidental and metastatic adrenal masses / M.Mannelli; S.Colagrande; A.Valeri; G.Parenti. - In: SEMINARS IN ONCOLOGY. - ISSN 0093-7754. - STAMPA. - 37:(2010), pp. 649-661. [10.1053/j.seminoncol.2010.10.018]

Availability:

This version is available at: 2158/402151 since:

Published version:

DOI: 10.1053/j.seminoncol.2010.10.018

Terms of use:

Open Access

La pubblicazione è resa disponibile sotto le norme e i termini della licenza di deposito, secondo quanto stabilito dalla Policy per l'accesso aperto dell'Università degli Studi di Firenze (https://www.sba.unifi.it/upload/policy-oa-2016-1.pdf)

Publisher copyright claim:

(Article begins on next page)

12 October 2024

Provided for non-commercial research and education use.
Not for reproduction, distribution or commercial use.



This article appeared in a journal published by Elsevier. The attached copy is furnished to the author for internal non-commercial research and education use, including for instruction at the authors institution and sharing with colleagues.

Other uses, including reproduction and distribution, or selling or licensing copies, or posting to personal, institutional or third party websites are prohibited.

In most cases authors are permitted to post their version of the article (e.g. in Word or Tex form) to their personal website or institutional repository. Authors requiring further information regarding Elsevier's archiving and manuscript policies are encouraged to visit:

http://www.elsevier.com/copyright

Author's personal copy

Incidental and Metastatic Adrenal Masses

Massimo Mannelli,[a,b] Stefano Colagrande,[c] Andrea Valeri,[d] and Gabriele Parenti[e]

In the last decades discoveries of adrenal masses incidentally during the course of diagnostic procedures for unrelated disorders (incidentalomas) have become progressively more frequent. The clinician in this position must answer two main questions: Is the mass benign or malignant?, and To what extent is the adrenal secretion altered? To come to a clinical decision, several diagnostic tools need to be engaged, starting with an accurate and correct radiological evaluation and a hormonal assessment of the adrenal function. When necessary, other diagnostic procedures such as functional imaging and fine-needle biopsy (FNB) can be considered in selected cases. Surgical removal is recommended for clinically relevant hypersecretory masses, as well as for masses suspected to be malignant. Most frequently, adrenal incidentalomas (AIs) are represented by benign cortical adenomas, a subset of which causes a mild hypercortisolism, known as subclinical Cushing's syndrome (SCS). The criteria to define this syndrome, as well as its treatment, are still debated and controversial. AIs that are not surgically removed should be re-examined in time to exclude a supervening increase in size or function. Follow-up criteria have not been established. Laparoscopic surgery is the recommended procedure to remove benign masses. The surgical procedure for adrenal malignancies is still debated.
Semin Oncol 37:649-661. © 2010 Published by Elsevier Inc.

The widespread use of abdominal radiological examinations, such as ultrasonography (US), computed tomography (CT), and magnetic resonance imaging (MRI), has caused the serendipitous discovery of adrenal masses called incidentalomas (AIs).[1,2] In autopsy studies, the mean incidence of adrenal masses was found to be approximately 6%.[3] This finding seems to be confirmed by the 4% incidence of adrenal masses detected at CT.[4] Similarly to the thyroid gland, human adrenals have been shown to develop adrenal nodules with increasing age, so that after 70 years the probability of developing an adrenal nodule is about 7%.[2,3] As a consequence, in the last two decades, clinicians have faced a new epidemic, represented by the AIs. The biological nature and the clinical relevance can be very different among AIs (Table 1).

As AIs are, by definition, discovered during radiological examinations performed for signs or symptoms unrelated to adrenal diseases,[5] the clinical picture is generally of little or no help in suggesting the nature of the lesion[6-8] and the diagnostic pathway starts from the study of the radiological image.[9] Therefore, an expert radiologist and a technically updated radiological apparatus (CT or MRI) are recommended for a correct approach. Nonetheless, clinicians need to collect an accurate medical history and to perform a meticulous clinical examination of the patient in search of very mild symptoms or signs that might suggest a slight, initial derangement of the adrenal function (Table 2). The task is not easy, especially because the signs and symptoms of a mild adrenal disorder are undistinguishable from those largely present in the general middle-aged or older population, such as obesity, fatigue, osteoporosis, hypertension, glucose intolerance, and diabetes, which are generally related to the so-called metabolic syndrome.[10-15]

The clinician must answer two main questions: Is the mass dangerous (benign or malignant)?; and, Is the mass responsible for a clinically relevant disorder of the adrenal function? The final decision of whether to surgically remove the AI or not depends on the answers to these two questions.

[a]Department of Clinical Pathophysiology, Endocrinology Unit, University of Florence, Florence, Italy.
[b]Istituto Toscano Tumori, Florence, Italy.
[c]Department of Clinical Pathophysiology, Radiodiagnostic Unit, University of Florence, Florence, Italy.
[d]Chirurgia Generale, d'Urgenza e Mini-invasiva, Azienda Ospedaliera Universitaria Careggi, Florence, Italy.
[e]Endocrine Unit, Azienda Ospedaliers Careggi, Florence, Italy.
This paper was supported in part by Istituto Toscano Tumori, Florence, Italy.
The authors declare no conflicts of interest.
Address correspondence to Massimo Mannelli, MD, Department of Clinical Pathophysiology, Endocrinology Unit, Viale Pieraccini 6, 50139, Florence, Italy. E-mail: m.mannelli@dfc.unifi.it
0270-9295/ - see front matter
© 2010 Published by Elsevier Inc.
doi:10.1053/j.seminoncol.2010.10.018

Author's personal copy

Table 1. Nature of Incidental Adrenal Masses

Common incidental adrenal masses
Non-hypersecreting adenomas (benign, clinically silent)
Cortisol-secreting adenomas (benign, subclinical Cushing's syndrome)
Aldosterone-secreting adenomas (benign, hypertension)
Carcinoma (malignant, nonsecreting or steroi-secreting; sometimes flank pain, weight loss)
Pheochromocytoma (mostly catecholamine-secreting, mostly benign, mostly with hypertension)
Metastasis (sometimes bilateral, possible cause of adrenal insufficiency)
Myelolipoma (benign, generally clinically silent)
Cysts (benign, clinically silent)
Hematomas (benign, possible transient flank pain)
Uncommon incidental adrenal masses
Lipoma, ganglioneuroma, ganglioneuroblastoma, neurofibroma, schwannoma, lymphoma, tubercolosis, histoplasmosis
Pseudoadrenal masses
Gastric diverticulum, renal cyst, renal tumor, splenic lobulation, splenic aneurisma, pancreatic mass

IMAGING

AIs are generally discovered at US or CT examinations. CT easily depicts normal glands and can accurately detect and characterize adrenal nodules. When CT characterization is unsatisfactory, MRI may be of help due to its great contrast resolution and its capability to distinguish normal and pathological tissues, as well as cyst, edema, necrosis, hemorrhage, vascularity, and cellular density.

Radiological criteria include size, morphology, CT density, MRI signal characteristics, and enhancement after administration of iodinated or gadolinium chelates contrast agents (CAs).

Table 2. Correlation Between Type of Adrenal Hypersecretion and Clinical Signs

Glucocorticoids	Obesitiy
	Impaired glucose tolerance/diabetes
	Hypertension
	Osteoporosis
Mineralcorticoids	Hypertension
	Impaired glucose tolerance/diabetes
Catecholamines	Hypertension
	Impaired glucose tolerance/diabetes
Androgens	Oligo-amenorrhea
	Hirsutism
Estrogens	Erectile dysfunction
	Gynecomastia
	Irregular menses

At first assessment, CT and MRI allow the diagnosis and classification of benign lesions, such as myelolipomas, cysts, bilateral hyperplasia, and, in most cases, hematomas (Table 3).

Myelolipoma

Myelolipoma is typically a nonfunctional, unilateral, asymptomatic, benign lesion with variable content of myeloid and fat tissue, whose presence (<-30 Hounsfield units [HU]) is diagnostic[16-18] (Figure 1). Depending on the vascularization of the myeloid portion, sometimes an enhancement can be found at CT or MRI examination; focal calcifications are detectable in approximately 25% of cases; In large myelolipomas, hemorrhages may occur and blood (heme) catabolites are usually recognizable.[19,20]

Cyst and Pseudocyst

Adrenal cysts are uncommon. Pseudocysts and endothelial (lymphangiomatous) cysts are more common than true epithelial cysts, which are rare, accounting for less than 15%.[21,22] Endothelial and simple cysts are easily recognizable for subtle, non-enhancing walls, fluid content, and infrequent, slight, peripheral calcifications.[17,22-24] Sometimes pseudocysts have thick walls with internal septa and calcifications.[17] Their content usually shows a low density but a higher density may be caused by hemorrhages or protein debris. When they are large and composed by a complex tissue mass, the differential diagnosis with malignancies or a chronic abscess can be difficult.[19]

Hyperplasia

The adrenal glands are generally both enlarged and usually maintain their normal shape, with smooth sur-

Author's personal copy

Table 3. Proposed Flowchart for the Radiological First Approach Evaluation of an Adrenal Incidentaloma

First rule out of easily recognizable (characterizable) adrenal masses	**Cyst and pseudocyst** **Hyperplasia** **Myelolipoma** **Acute and sub-acute hematoma**
If mass shows all the following criteria: **(< cm 3, oval shape, regular margins, lipid content, mild/none enhancement)**	**Adenoma**
If only one of the above reported criteria is absent (**> cm 3/round/irregular margins/no lipid content/various enhancement**), the adrenal mass may not be an adenoma and needs further clinical examination, in the suspect of:	
If round, bright T2, strong enhancement, (hypertension)	**Pheocromocytoma**
If round, irregular, heterogeneous, hypo-T1/hyper-T2, peripheral enhancement, sometimes bilateral	**Metastasis**
If round, regular, homogeneous, hypo-T1/hyper-T2, mild enhancement, frequently bilateral with lymph node involvement:	**Lymphoma**
If round, irregular, heterogeneous, hypo-T1/hyper-T2, peripheral enhancement (hypercortisolism/virilization):	**Adrenocortical cancer**
If round, irregular, heterogeneous, hypo-T1/hyper-T2, peripheral enhancement (calcification/hemorrhage/necrosis young children)	**Neuroblastoma**

face, although sometimes a unilateral nodular enlargement may occur.[25]

Hematoma

Adrenal hematomas are caused by traumatic and nontraumatic events, including sepsis, burns, hypotension crises, neonatal stress, coagulation disorders, and adrenal tumors, such as pheochromocytoma (most common cause of bleeding), myelolipoma, and adrenocortical carcinoma. Hemorrhages in metastases and in adenomas are uncommon.[20] Adrenal hemorrhage may be clinically silent, with spontaneous resolution; however, it can evolve in a pseudocyst.[26] With the exception of patients with coagulopathies,[27] most hemorrhages are unilateral, usually on the right site due to the drainage of the right adrenal vein into the inferior vena cava.[26] CT can be used to detect and characterize an acute hematoma because of the high density of bleeding clot. Conversely, subacute and chronic hematomas are recognizable on MRI. In the subacute phase (roughly from 7 to 45 days after onset), hematomas are hyperintense on T1- and T2-weighted images due to the presence of meta-hemoglobin, a natural paramagnetic agent that improves T1 signal intensity. In the chronic phase, a hypointense rim can be detected on T1- and T2-weighted acquisitions as a consequence of hemosiderin deposition, a natural super-paramagnetic agent that decreases T2 signal intensity. It should be underscored that hematoma is frequently multilocular, and each locule may have different signal intensities because of the differing evolution of the heme.

The radiologist and the clinician must be aware that the hematoma may be the consequence of the bleeding of a malignancy, hidden by the strong dishomogeneity and signal intensity of the heme collection.

Adenoma

The above-described pathological entities are usually confidently recognizable, but also relatively rare on imaging studies, where the most frequent finding is a cortical adenoma, which represents up to 80% of the adrenal masses detected at US, CT, and MRI.[8]

Adrenal adenomas are usually small (<3 cm), oval, with smooth, well-defined margins and lipid content (Figure 2). Calcifications, necrosis, and hemorrhage are atypical, although they can occur, particularly in larger lesions.[19] As a general rule, roughly 80% to 90% of adrenal nodules smaller than 3 cm are benign, while, conversely, the rate of malignancies increases with larger sizes.

As size cannot per se discriminate between benign and malignant masses, additional criteria have to be adopted, among which the lipid content is of the most value, due to the typical high intracellular lipid content

Author's personal copy

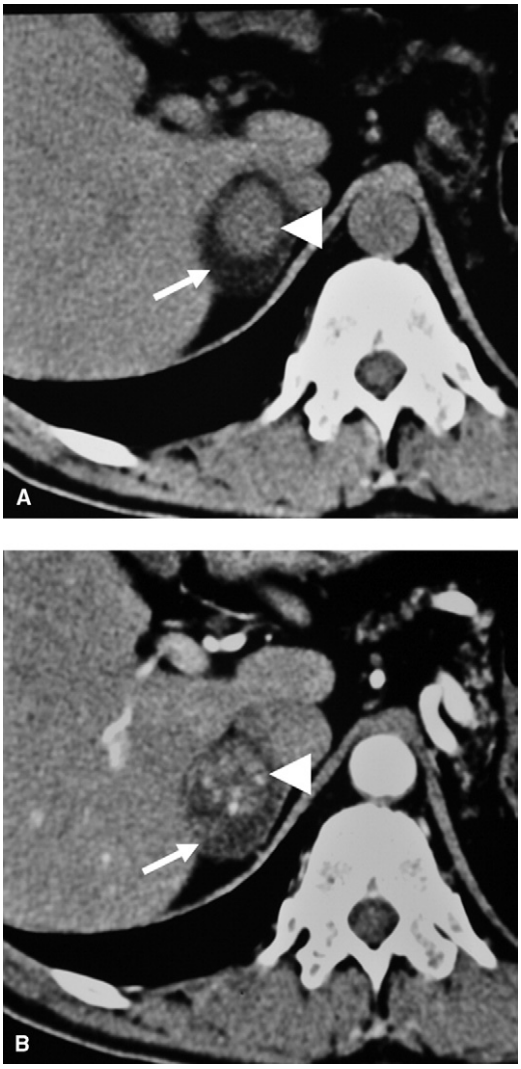

Figure 1. Right adrenal myelolipoma. Unenhanced (A) and enhanced (B) CT study. The tumor is well visible (A, B) as a very low-density mass (white arrow) due to the fat tissue content, whose presence is diagnostic. Within the mass, a more dense nodule is recognizable (white arrowhead), referable to the myeloid portion, with some enhancement after iodinated CA administration.

of adrenal adenomas. Several criteria have been proposed to detect and measure the lipid content of adrenal masses.[28] On unenhanced CT, density measurement seems to be simple, accurate, and reliable: if the mass has a density <10 HU, diagnosis of adenoma has a 74% sensitivity and 96% specificity.[16,23] On enhanced CT, the density measurement 30 minutes after CA administration yields 100% specificity and sensitivity (adenomas <37 HU; non-adenomas >41 HU).[29] Nevertheless, other cut-off values have been proposed.[28]

The lipid content of an AI also can be detected by MRI, using a technique based on the chemical shift phenomenon. This technique allows the acquisition of two sequential images, with and without fat/lipid signal suppression, respectively. If the nodule has a high fat/lipid content, as in the majority of adenomas, a signal drop is evidenced between two sequential images. In the case of metastases or nodules other than adenomas, because of their poor lipid content, signal drop is irrelevant.[30,31]

Therefore, in the absence of a history of malignancy, a small, oval, homogeneous, lipid-containing mass, with regular margins showing mild or no enhancement can be confidently diagnosed as adenoma (benign incidentaloma) and might not require additional radiological investigation. If the lipid content of the mass is slight or absent, a 6- to 12-month imaging follow-up is generally considered sufficient to diagnose a "not-evolving" (or steady) adrenal lesion. Alternatively, ^{131}I-6-β-iodomethyl-19-norcholesterol (NP-59) scintigraphy may be performed (see below).

Signs to be considered suspicious for primary or secondary malignancy (metastasis, lymphoma, adrenocortical carcinoma) or pheochromocytoma include size larger than 3 cm, no lipid content, heterogeneous internal density/signal intensity, and strong/irregular enhancement after CA administration. In such cases, investigations in addition to hormonal assessment are recommended.

Metastasis

The adrenal glands represent a common site of metastatic disease, because of their high vascularity. Common tumors, including carcinomas of the breast, lung, kidney, colon, esophagus, pancreas, liver, and stomach, as well as melanoma, may metastasize to the adrenal gland.[6,7] The prevalence of adrenal metastases in patients with extra-adrenal cancers ranges from 32% to 73% in different series.[7,10,16]

When affecting both adrenals, metastases may cause adrenal failure. Metastases appear, on average, as large, heterogeneous, poorly defined masses with a thick enhancing rim on contrasted studies.[32] On MRI, metastases have nonspecific low T1/high T2 signal intensity, without drop signal on opposed phase (Figure 3). Hemorrhages and calcifications are rare.

When small, metastatic lesions can appear homogeneous, well-defined, and with low density. The diagnosis is difficult in these cases.

It should be emphasized that benign adrenal lesions cannot be differentiated from malignancies using the newest MRI techniques, such as diffusion-weighted imaging. This technique is based on the assumption that in malignancies free diffusion of water molecules is restricted due to abnormal vascularity and increased tissue cellular density. Unfortunately, free water diffusion is not different between malignant and benign adrenal lesions. Therefore, diffusion-weighted imaging cannot be used to classify adrenal masses and chemical shift imaging is still required using MRI to differentiate adrenal adenomas from metastases.[33,34]

Author's personal copy

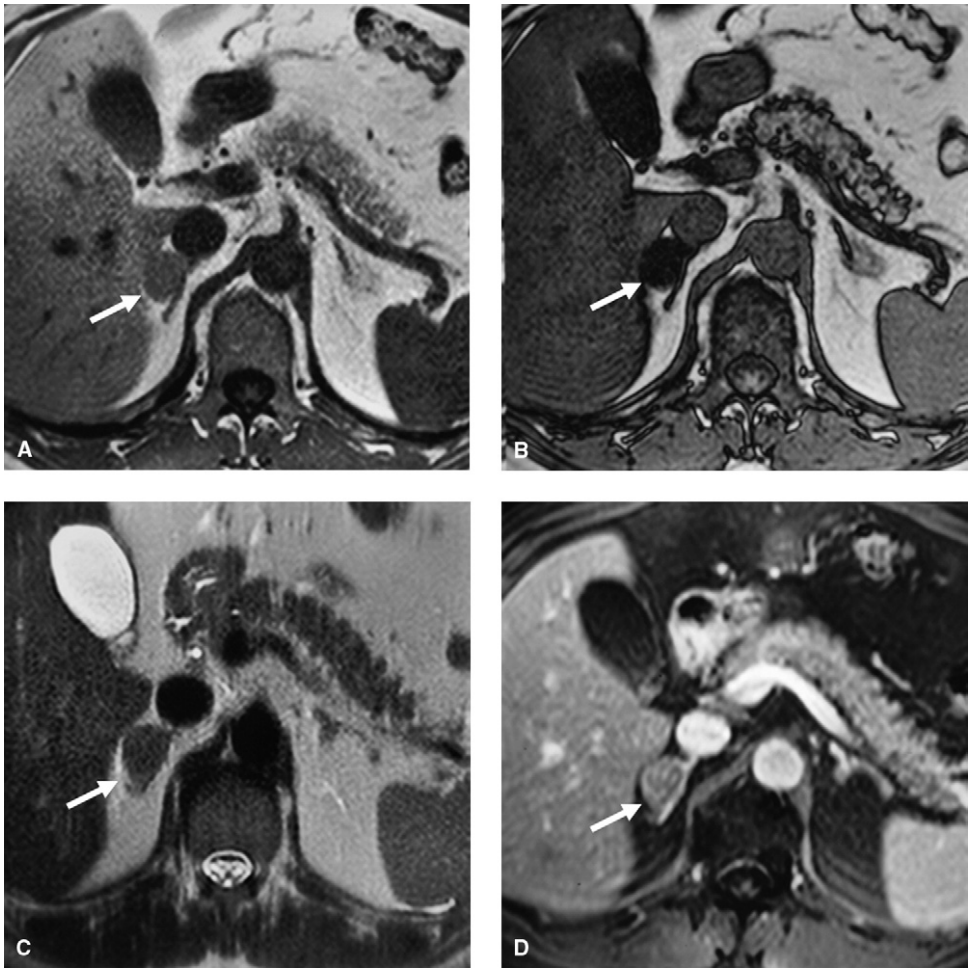

Figure 2. Right adrenal adenoma. Unenhanced T1-weighted in-phase (A) and out-phase (B), T2-weighted (C), and enhanced T1-weighted (D) MRI axial acquisitions. A small (diameter ~1.5 cm), oval mass with smooth, well-defined margins (white arrow) is detectable (A–D). The nodule has low density due to its lipid content. In fact, in the sequences based on the chemical shift phenomenon (A, B), the nodule shows an evident signal drop between in-phase (A) and out-phase (B) acquisitions. The cellular density and water content is poor as evidenced by low signal intensity on T2-weighted acquisition (C). Mild enhancement is demonstrable after gadolinium chelates CA administration, due to low vascularization (D).

Patients with a history of extra-adrenal malignancy and the presence of an adrenal mass should undergo the same diagnostic procedure as patients with an AI (biochemical and radiological evaluation). Nevertheless, in patients with clinical and radiological suspicions of adrenal metastases, a fine-needle biopsy (FNB) (see below) and a positron-emission tomography (PET) with ^{18}F-fluorodeoxyglucose (^{18}F-FDG) may be helpful before considering a surgical approach.

Adrenocortical Carcinoma

Primary adrenal carcinoma is a rare lesion. Similarly to metastases, it can rarely be represented by a small, homogeneous lesion, but in the vast majority of cases, the first imaging presentation is constituted by a great, inhomogeneous mass, with necrosis, hemorrhages, and calcifications.[35] In any case, even when presenting as a small nodule, on unenhanced MRI it displays a heterogeneous nonspecific low T1/high T2 signal intensity and a peripheral irregular enhancement after CA administration on both CT and MRI (Figure 4).[36]

Neuroblastoma

Neuroblastomas are mostly located in the adrenal glands and are the most common adrenal lesions in children.[19] Neuroblastomas commonly contain calcifications, necrosis, or hemorrhage. On MRI they appear as heterogeneous nonspecific low T1/high T2 signal intensity nodules.[37] After CA administration they present an intense enhancement, mainly at the periphery or where necrosis is absent.

Pheochromocytoma

Pheochromocytomas are highly vascular masses, with a high intracellular water content and frequent

Author's personal copy

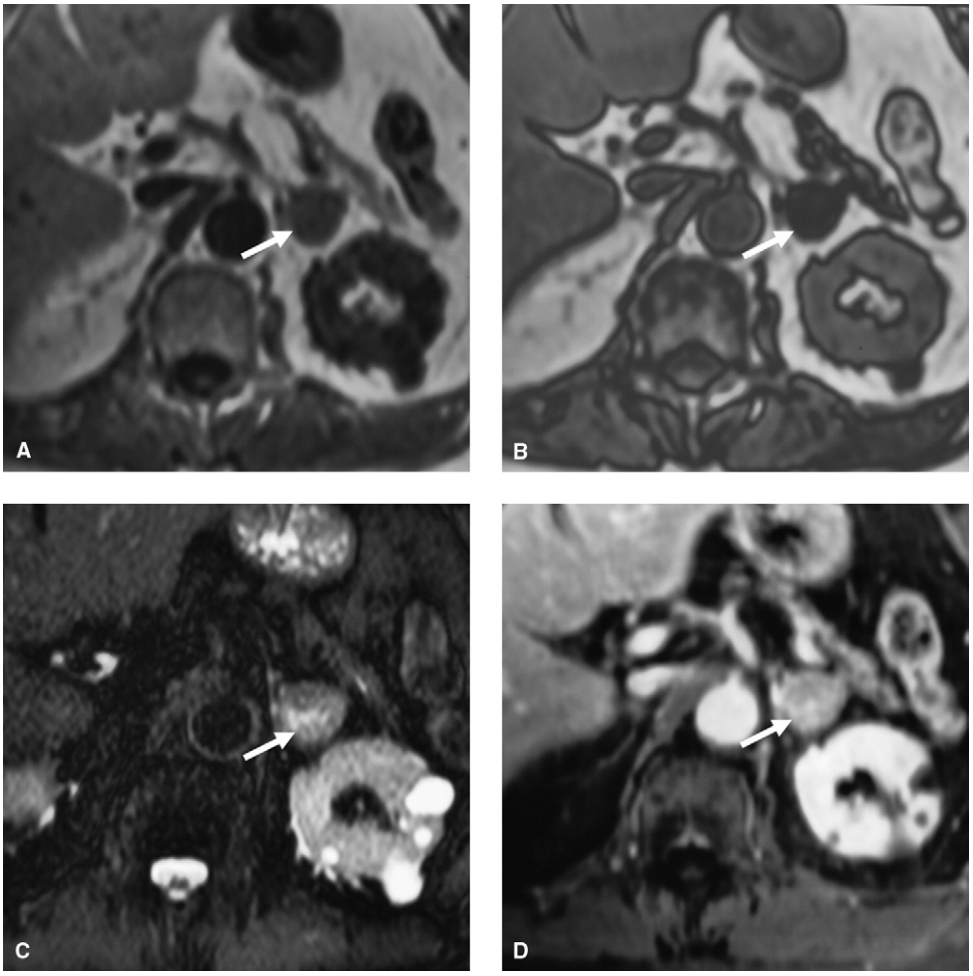

Figure 3. Left adrenal metastasis from lung carcinoma. Unenhanced T1-weighted in-phase (A) and out-phase (B), fat suppressed T2-weighted (C), and enhanced T1-weighted (D) MRI axial acquisitions. A 2-cm, round mass with well-defined margins (white arrow) is evident (A–D). The nodule has low signal intensity and, in the sequences based on the chemical shift phenomenon (A, B), it does not show an apparent signal change between in-phase (A) and out-phase (B) acquisitions. The cellular density, water content, and vascularization are evidenced by medium–high signal intensity on T2-weighted acquisition (C) and by clear enhancement after gadolinium chelates CA administration (D).

intratumoral cystic lesions.[38] These characteristics account for their typical but nonpathognomonic high signal on T2-weighted imaging and strong enhancement after CA administration. Reduced T2 signal intensity can result from internal hemorrhages.[39]

Small pheochromocytomas may appear homogeneous but usually they are greater than 3 cm and present internal areas of necrosis or hemorrhage (Figure 5), sometimes with fluid–fluid levels.[40,41]

Similarly to other nonionic iodinated CAs,[42] gadolinium chelates do not cause catecholamine release from the tumor, and can be administered to patients with pheochromocytoma without requiring adrenergic blockade before scanning.

HORMONAL EVALUATION

The majority of AIs are non-hypersecreting adrenal masses. In a large multicentric study including 1,004 AIs, 85% could be classified as non-hyperfunctioning; among the hyperfunctioning AIs, 9.2% were classified as causing subclinical Cushing's syndrome (SCS), 4.2% as pheochromocytomas, and 1.6% as aldosterone-producing adrenal masses.[8] By definition, many patients with AI are asymptomatic or present only with nonspecific signs or symptoms. Table 2 shows the possible link between signs or symptoms and hormonal hypersecretion. Because of the uninformative clinical picture, the secretory activity of the incidental adrenal masses has to be assessed by hormone measurements in plasma, urine, or saliva.

Glucocorticoid Secretion

It is now widely accepted that patients with SCS can be diagnosed by the finding of two or more abnormal results in tests evaluating the hypothalamus-pituitary-adrenal axis.[8] The biochemical evaluation of glucorti-

Author's personal copy

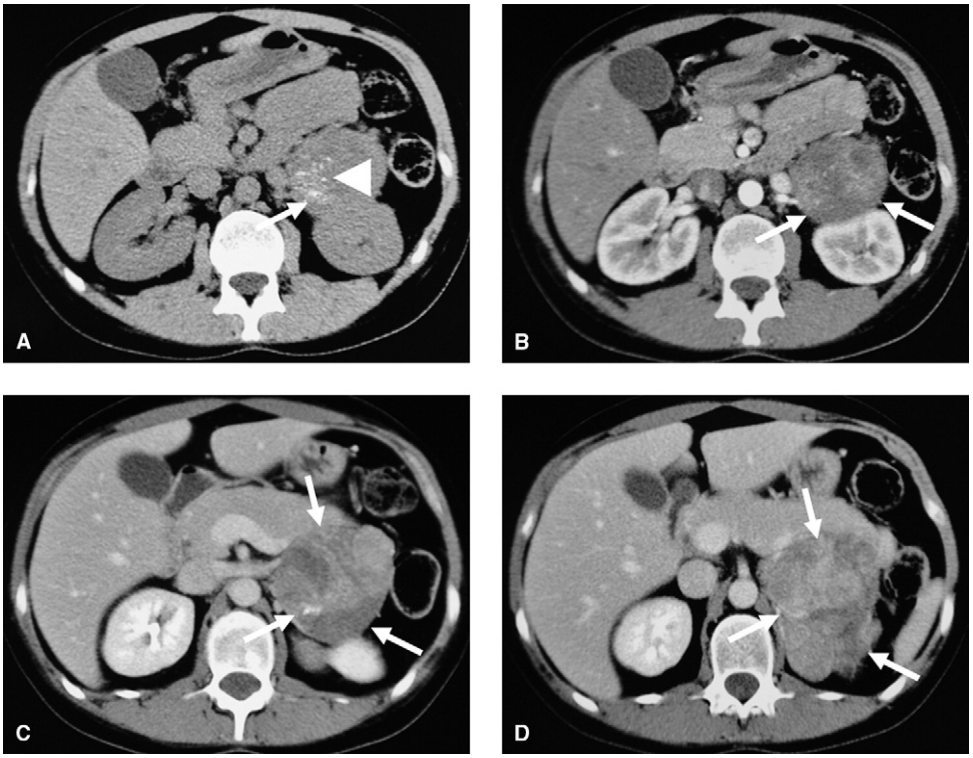

Figure 4. Left adrenal carcinoma. Unenhanced (A) and enhanced CT study in arterial (B) and venous (C, D) phases. A large mass with irregular shape and borders (white arrows) is shown (A–D). Some calcifications (white arrowhead) are detectable on unenhanced examination (A). After administration of iodinated CA, the mass demonstrates uneven enhancement due to heterogeneous content and pathological vascularization (B–D).

coid function can be performed by one of the following tests: urinary free cortisol (UFC), 1 mg overnight dexamethasone suppression test (DST), or midnight salivary cortisol. To detect the presence of hypercortisolism, each test (alone or variably associated) can be performed as a first-line diagnostic approach. UFC levels are not affected by changes in corticosteroid-binding globulin and thus represent an integrated measure of unbound circulating cortisol over 24 hours. Normal UFC values exclude chronic hypercortisolism with high probability, while a fourfold increase is diagnostic of Cushing's syndrome.[43] The 1-mg DST is performed by administration of 1 mg of dexamethasone late in the evening (11 PM) followed by measurement of serum cortisol at 8 AM on the following day. The optimal cut-off of cortisol after a 1-mg DST is still debated: a value >5 μg/dL (138 nmol/L) is considered diagnostic for glucocorticoid hypersecretion,[44] but a threshold of 1.8 μg/dL (50 nmol/L) has been suggested[45] to increase diagnostic sensitivity. This lower cut-off is particularly useful in detecting more subtle autonomous cortisol hypersecretion, or SCS. Midnight salivary cortisol represents the most recent test used in the screening of hypercortisolism and is performed by collecting a saliva sample late in the evening (between 11 PM and midnight) on two different occasions. Salivary cortisol is highly correlated with unbound plasma cortisol levels. The normal reference values are assay-dependent and should be established for each laboratory.[46] Some investigators have shown that elevated midnight salivary cortisol levels are a useful and simple screening test for hypercortisolism, with a sensitivity and specificity reaching 90% to 95%.[47] In patients without clearly diagnostic laboratory results, a classical DST (Liddle test: 2 mg/d oral dexamethasone for 2 days) may be performed.

ACTH assay represents a second-line diagnostic approach: when hypercortisolism, either overt or subclinical, has been established, low or suppressed ACTH levels will confirm the adrenal origin of hypercortisolism. In patients with SCS, cortisol secretion is, by definition, only slightly increased, Nonetheless, an association between SCS and an increased risk of obesity, diabetes, hypertension, and osteoporosis cannot be excluded.[48–52] Although an Italian multicentric study performed in patients with AI did not demonstrate a significant association between SCS and increased morbidity,[8] long-term follow-up in a large number of patients with SCS is necessary to establish the real clinical impact of this mild hormonal alteration.

In patients undergoing surgery for an AI, the demonstration of a subtle cortisol hypersecretion is also important to avoid an acute adrenal insufficiency cri-

Author's personal copy

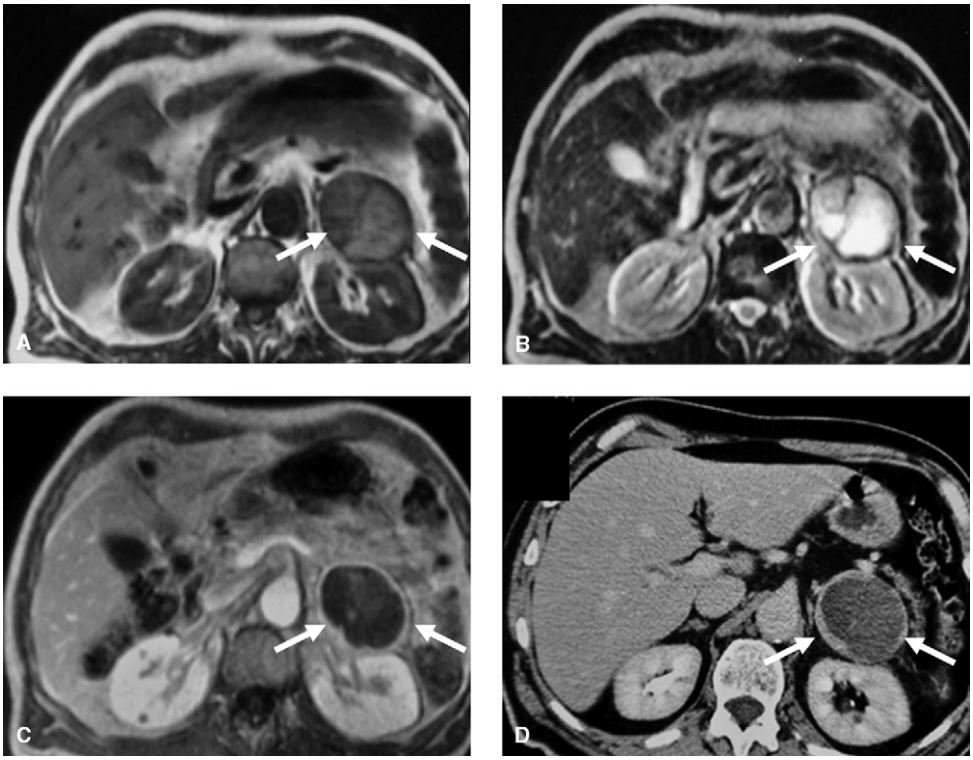

Figure 5. Left adrenal pheochromocytoma. Unenhanced T1-weighted (A), T2-weighted (B), and enhanced T1-weighted (C) MRI axial acquisitions; enhanced CT study in late venous phase (D). A large, oval mass with regular margins (white arrows) is shown (A–D). Previous internal subacute hemorrhage explains medium–high signal intensity on T1-weighted acquisition (white arrowheads) due to the presence of meta-hemoglobin, a natural paramagnetic agent. The colliquative, hydrated necrosis consequent to the hemorrhage is also demonstrated by the high signal intensity on T2-weighted image (B), by the absence of internal enhancement after gadolinium chelates CA administration (C), and by the same pattern on enhanced CT study (D).

sis[53] possibly caused by the removal of an unrecognized "pre-toxic" nodule.

Although rare, progression from a non-hypersecreting to a hypersecreting adrenal adenoma is always possible. Therefore, there is general agreement that a hormonal evaluation should be performed annually for 4 years in patients diagnosed with an adrenal adenoma.[5,54,55]

Mineralocorticoid Secretion

Current evidences suggest that the prevalence of primary aldosteronism (PA) is higher than previously thought, accounting for up to 12% of hypertensive patients.[56] The introduction of the serum aldosterone (SA)/plasma renin activity (PRA) ratio (ARR) as a screening test among hypertensive patients probably accounts for this consistent increase. The use of ARR is considered more convenient than separate determination of PRA and plasma and/or urinary aldosterone. In fact, a normal or normal/high value of plasma aldosterone can be inappropriately high in the presence of a suppressed renin-angiotensin system, thus suggesting a PA even in its milder forms and/or in the absence of hypokalemia. The optimal cut-off of ARR is still debated and ranges from 20 to 50 when SA and PRA are expressed in ng/dL and ng/mL/h, respectively.[57] The evaluation of ARR should be performed in the absence of antihypertensive therapy, but if a medical treatment is mandatory, calcium channel blockers and/or alfa-blockers can be permitted.

It is generally agreed that a high ARR is not diagnostic of PA and that a confirmatory test is needed for a final diagnosis. The most widely recommended suppression tests are those using oral fludrocortisone, oral captopril, or intravenous as well as oral saline load.

Sexual Steroid Secretion

Sex hormone–secreting adrenal masses are rare. However, dehydroepiandrosterone sulfate (DHEAS) measurement is recommended in patients with AI. The production of androgens is more frequent in adrenocortical cancer than in adrenal adenoma, so sex steroid hypersecretion should be possibly considered as a biochemical index of malignancy. When suspecting an adrenocortical cancer, as well as in the presence of hirsutism or virilization, testosterone and delta-4-androstenedione should be measured as well.

In SCS a low level of DHEAS is frequently found, but

Author's personal copy

its diagnostic value is poor because of its physiological decrease with age.[58]

An exaggerated 17OH-progesterone (17OHP) response to ACTH stimulation is commonly observed in patients with AI, but the clinical significance of this biochemical response is not clear. It has been hypothesized that a latent 21-hydroxylase deficiency might cause adrenal growth, predisposing to adenoma formation,[57] but it has to be considered that the enhanced 17OHP response also might depend on an altered intratumoral steroidogenesis.[59] Therefore, basal and stimulated 17OHP measurements should be restricted to patients with bilateral adrenal masses.

Measurement of 17β-estradiol is very rarely indicated and should be reserved to male patients with an AI associated with gynecomastia and/or erectile dysfunction.

Catecholamine Secretion

The diagnosis of pheochromocytoma (or secreting paraganglioma) is based on laboratory data demonstrating an increase of catecholamines or of their metabolites in plasma or urine. Until recently, the recommended initial test for the diagnosis of pheochromocytoma was 24-hour urine-free catecholamines (adrenaline and noradrenaline).[60] In the last two decades, many investigators have agreed that plasma free metanephrines or urine deconjugated differential metanephrines should be recommended as the biochemical tests for pheochromocytoma screening.[61] The validity of metanephrines as the preferred analytes has been supported by several large case control studies demonstrating their higher sensitivity in comparison to catecholamines or vanilmandelic acid.[62,63] The higher sensitivity is mainly due to the longer half-life of metanephrines and to their nonepisodic production by the tumor where catecholamines are continuously converted to metanephrines by the high methyltransferase activity of the chromaffin tissue.[64] Due to the very low number of false negative results, a normal value in plasma or urinary metanephrines makes the diagnosis of pheochromocytoma highly unlikely, thus avoiding additional costly investigations.

NUCLEAR MEDICINE EVALUATION

In a very limited number of cases, when radiology is not able to reasonably classify/characterize an adrenal mass as benign or malignant, functional imaging can be of help.

^{131}I-6-β-iodomethyl-19-norcholesterol (NP-59) scintigraphy has a high positive predictive value for the detection of adenoma, thus classifying the incidentaloma as benign. In fact, other adrenal lesions, including adrenocortical carcinoma, do not concentrate the tracer.[65] Nevertheless, its use should be limited to very select cases; false positive results in case of secreting adrenal cancer are possible.

^{18}F-FDG-PET is another functional imaging modality used to differentiate benign from malignant adrenal lesions. In fact, ^{18}F-FDG is trapped by metabolically active malignant lesions, whereas most benign lesions fail to concentrate the isotope.[65–67] Therefore, ^{18}F-FDG-PET will be positive for primary or secondary adrenal malignancies, although false negative results can be found and, conversely, an increased radiotracer uptake can be registered in pheochromocytomas, which are, for the vast majority, benign lesions.

Scintigraphy using ^{123}I-metaiodobenzylguanidine (MIBG) is the most widely used tool to localize a pheochromocytoma/paraganglioma after a biochemical diagnosis or to search for chromaffin metastatic lesions.[68] PET with ^{18}F-fluorodopamine, ^{18}F-fluorodopa, or ^{11}C-hydroxyephedrine are more expensive functional imaging methods that may be used as alternatives to ^{123}I-MIBG.[69–72]

ADRENAL BIOPSY

The accuracy of the available imaging techniques in characterizing AI greatly reduces the necessity for adrenal FNB. Its use is limited to distinguishing an adrenal metastasis from an extra-adrenal malignancy. This procedure does not allow differentiation of a benign adrenal adenoma from an adrenal adrenocortical carcinoma and must not be performed before having excluded the possibility of a pheochromocytoma.

Image-guide FNB is rather safe with a complication rate of less than 3%.[6] The most common complications include hematoma, abdominal pain, hematuria, pancreatitis, and pneumothorax. The possibility of a diffusion of cancer cells along the needle track also should be considered.[2,73,74]

FINAL DECISION

The decision on whether to suggest the surgical removal of the AI depends on the results of the aforementioned diagnostic procedures (Figure 6). Surgery is recommended for hypersecreting and/or malignant (or suspected malignant) adrenal masses. For AI classified by the radiologist as benign adrenocortical adenomas, the decision depends on the laboratory results. Very often the associated functional derangement is minimal and the choice between surgery or medical treatment is difficult, especially in elderly people where an accurate evaluation of the risk/benefit ratio is mandatory.

The size of the AI is generally considered of upmost value in the final decision, as there is a positive correlation between mass diameter and malignancy and a diameter of 4 cm or more is considered an index of suspicion. Nonetheless, in the authors' opinion, size cannot be considered an index of absolute value. In

Author's personal copy

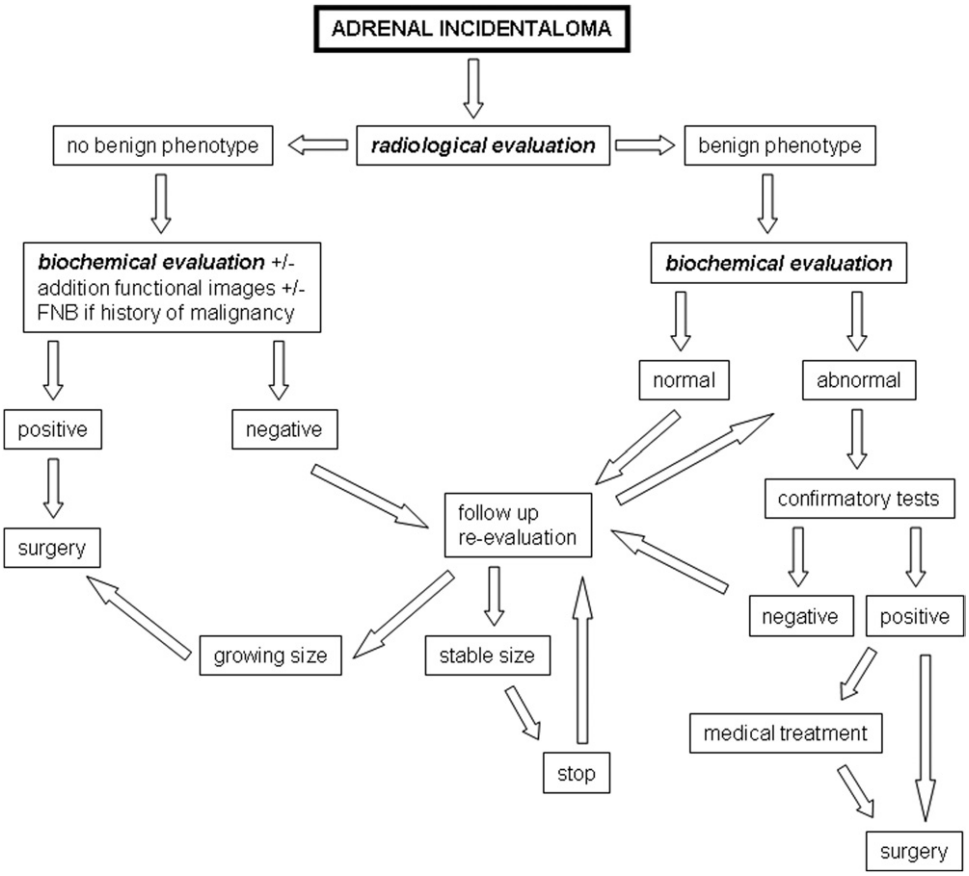

Figure 6. Suggested simplified flow-chart for the clinical management of incidental adrenal masses. FNB, fine-needle biopsy.

fact, several AI, radiologically classified as benign, like myelolipomas, cysts, and hematomas, may be larger than 4 cm. Moreover, there is no doubt that a solid AI showing an increased diameter at follow-up should be removed, independent of its size. A summary of the adrenal masses to be or not to be surgically removed is reported in Table 4.

In conclusion, the final decision on whether to pro-

Table 4. Suggested Criteria for Surgical Therapy of Adrenal Masses

Indications	Contraindications
Hypersecreting	**Not functioning**
- Aldosterone-secreting adenoma (Conn's syndrome.)	- Benign, small not growing
- Cortisol-secreting adenoma	- Not functioning stage IV adrenocortical carcinoma
- Bilateral adrenocortical hyperplasia (otherwise incurable ACTH-dependent Cushing's syndrome)	**Metastases**
- Pheochromocytoma	-Bilateral
	- Multiple (also extra-adrenal)
Adrenocortical carcinoma	
- Stage I-III	
- Stage IV if functioning for debulking	
Metastases	
- Solitary	
- Monolateral	
Other suspected malignancies	
(for size or radiological characteristics)	

Author's personal copy

ceed to surgery or not stems on several independent criteria like the radiological characteristics of the mass, the results of the hormonal screening, the results of additional diagnostic procedures such as functional images and/or FNB, and evidence of a stable or a growing diameter. All of these criteria also should be considered in the light of other influencing clinical parameters like age, general condition, and comorbidities to correctly evaluate the risk/benefit ratio of the therapeutic decision.

SURGICAL APPROACH

In the last decades, technological developments in instrumentation and improvements in surgical techniques have greatly modified adrenal surgery. At present, the less invasive laparoscopic technique is recommended as the first choice approach to adrenal surgery.[75,76]

Different laparoscopic surgical approaches have been proposed to perform adrenalectomy. The lateral trans-peritoneal approach is the most frequently performed procedure for unilateral adrenalectomy, since it permits easy access to the retroperitoneal space[77] and a better exposition of the retroperitoneal surgical field once the patient is positioned on the controlateral flank. The retroperitoneal approach is a more recently proposed alternative procedure that allows direct access to the adrenal gland, without mobilizing other organs. It is indicated for bilateral adrenalectomy because it may significantly reduce the operative times by avoiding repositioning of the patient. The trans-abdominal anterior approach is very seldom used and is reserved for bilateral adrenalectomy.

Laparoscopic surgery is recommended to remove any adrenal mass up to about 10 cm in size, with the size limit depending on the experience of the surgical team. The use of laparoscopic surgery to remove adrenocortical cancer is still debated. Nonetheless, in the authors' opinion, its use should be permitted to remove suspected adrenal cancers that, at radiology, do not present infiltration of the surrounding organs. The laparoscopic technique is indicated also for sparing adrenocortical tissue[78] and thus avoiding chronic adrenal insufficiency in case of bilateral adrenalectomy.

FOLLOW-UP

In patients with AI not surgically removed, clinical follow-up evaluation, aimed at excluding interval changes in tumor size or the development of hormone overproduction, is recommended.[79] There are no established guidelines on the time schedule or method of serial imaging and hormonal evaluation. There is general agreement that at least one CT imaging study should be performed 6 to 12 months after the discovery of AI.[79] In case of a stable mass, there are no data supporting continued radiological evaluation, in view of the extremely low risk of developing adrenal cortical carcinoma as supported by longitudinal studies. When serial radiological control evaluations are performed, we prefer, if possible, US to CT to avoid radiation exposure.[80] Hormonal hypersecretion may develop over time in about 20% of patients; it is generally represented by cortisol hypersecretion, but it rarely occurs in patients with AIs smaller than 3 cm. As the risk of developing hypersecretion seems to plateau after 4 years, no laboratory tests are recommended after this period.

Finally, in patients undergoing surgery for SCS, perioperative glucocorticoid treatment should be ensured to avoid postsurgical hypoadrenalism and should be stopped only after functional recovery of the hypothalamic-pituitary-adrenal axis.

REFERENCES

1. Aron DC. The adrenal incidentaloma: disease of modern technology and public health problem. Rev Endocr Metab Disord. 2001;2:335–42.
2. Young WF Jr. Management approaches to adrenal incidentalomas: a view from Rochester, Minnesota. Endocrinol Metab Clin North Am. 2000;29:159–85.
3. Kloos RT, Gross MD, Francis IR, Korobkin M, Shapiro B. Incidentally discovered adrenal masses. Endocr Rev. 1995;16:460–84.
4. Bovio S, Cataldi A, Reimondo G, et al. Prevalence of adrenal incidentaloma in a contemporary computerized tomography series. J Endocrinol Invest. 2006;29:298–302.
5. Grumbach MM, Biller BM, Braunstein GD, et al. Management of the clinically inapparent adrenal mass ("incidentaloma"). Ann Intern Med. 2003;138:424–9.
6. Young WF. The incidentally discovered adrenal mass. N Engl J Med. 2007;356:601–10.
7. Terzolo M, Bovio S, Pia A, Reimondo G, Angeli. Management of adrenal incidentaloma. Best Pract Res Clin Endocrinol Metab. 2009;23:233–43.
8. Mantero F, Terzolo M, Arnaldi G, et al. A survey on adrenal incidentaloma in Italy. Study Group on Adrenal Tumors of the Italian Society of Endocrinology. J Clin Endocrinol Metab. 2000;85:637–44.
9. Boland GW, Blake MA, Hahn PF, Mayo-Smith WW. Incidental adrenal lesions: principles, techniques, and algorithms for imaging characterization. Radiology. 2008;249:756–75.
10. Terzolo M, Pia A, Alì A, et al. Adrenal incidentaloma: a new cause of the metabolic syndrome? Clin Endocrinol Metab. 2002;87:998–1003.
11. Fernández-Real JM, Engel WR, Simó R, Salinas I, Webb SM. Study of glucose tolerance in consecutive patients harbouring incidental adrenal tumours. Clin Endocrinol (Oxf). 1998;49:53–61.
12. Garrapa GG, Pantanetti P, Arnaldi G, Mantero F, Faloia E. Body composition and metabolic features in women with adrenal incidentaloma or Cushing's syndrome. J Clin Endocrinol Metab. 2001;86:5301–6.
13. Tauchmanova L, Rossi R, Biondi B, et al. Patients with

Author's personal copy

subclinical Cushing's syndrome due to adrenal adenoma have increased cardiovascular risk. J Clin Endocrinol Metab. 2002;87:4872–8.
14. Reincke M, Fassnacht M, Väth S, Mora P, Allolio B. Adrenal incidentalomas: a manifestation of the metabolic syndrome? Endocr Res. 1996;22:757–61.
15. Chiodini I, Tauchmanova L, Torlontano M, et al. Bone involvement in eugonadal male patients with adrenal incidentaloma and subclinical hypercortisolism. J Clin Endocrinol Metab. 2002;87:5491–4.
16. Korobkin M, Francis IR. Imaging of adrenal masses. Urol Clin North Am. 1997;24:603–22.
17. Cirillo RL, Bennett WF, Vitellas KM, Poulos AG, Bova JO. Pathology of the adrenal gland: imaging features. Am J Roentgenol. 1998;170:429–35.
18. Kenney PJ, Wagner BJ, Rao P, Heffess CS. Myelolipoma: CT and pathologic features. Radiology 1998;208:87–95.
19. Udelsman R, Fishman EK. Radiology of the adrenal. Endocrinol Metab Clin North Am. 2000;29:27–42.
20. Rao P, Kenney PJ, Wagner BJ, Davidson AJ. Imaging and pathologic features of myelolipoma. Radiographics. 1997; 17:1373–85.
21. Dunnick NR. Adrenal imaging: current status. Am J Roentgenol. 1990;154:927–36.
22. Francis IR, Korobkin M. Incidentally discovered adrenal masses. Magn Reson Imaging Clin North Am. 1997;5: 147–64.
23. Sohaib SA, Hanson JA, Newell-Price JD, et al. CT appearance of the adrenal glands in adrenocorticotrophic hormone-dependent Cushing's syndrome. Am J Roentgenol. 1999;172:997–1002.
24. Rozenbit A, Morehouse HT, Amis ES Jr. Cystic adrenal lesions: CT features. Radiology. 1996;201:541–8.
25. Hamrahian AH, Ioachimescu AG, Remer EM, et al. Clinical utility of noncontrast computed tomography attenuation value (Hounsfield units) to differentiate adrenal adenomas/hyperplasias from nonadenomas. Cleveland Clinic experience. J Clin Endocrinol Metab. 2005;90: 871–7.
26. Peppercorn PD, Reznek RH. State-of-the-art CT and MRI of the adrenal gland. Eur Radiol 1997;7:822–36.
27. Ames DE, Asherson RA, Ayres B, Cassar J, Hughes RV. Bilateral adrenal infarction, hypoadrenalism and splinter hemorrhages in the primary' antiphospholipid syndrome. Br J Rheumatol. 1992;31:117–20.
28. Heinz-Peera G, Memarsadeghia M, Niederleb B. Imaging of adrenal masses. Curr Opin Urol. 2007;17:32–8.
29. Szolar DH, Kammerhuber F. Quantitative CT evaluation of adrenal gland masses: a step forward in the differentiation between adenomas and nonadenomas. Radiology. 1997;202:517–21.
30. Korobkin M, Giordano TJ, Brodeur FJ, et al. Adrenal adenomas: relationship between histologic lipid and CT and MR findings. Radiology. 1996;200:743–7.
31. Outwater EK, Siegelman ES, Huang AB, Birnbaum BA. Adrenal masses: correlation between CT attenuation value and chemical shift ratio at MR imaging with in-phase and opposed-phase sequences. Radiology. 1996; 200:749–52.
32. Lockhart ME, Smith JK, Kenney PJ. Imaging of adrenal masses. Eur J Radiol. 2002;42:95–112.
33. Miller FH, Wang Y, McCarthy RJ, et al. Utility of diffusion-weighted MRI in characterization of adrenal lesions. AJR. 2009;194:179–85.
34. Tsushima Y, Takahashi-Taketomi A, Endo K. Diagnostic utility of diffusion-weighted MR imaging and apparent diffusion coefficient value for the diagnosis of adrenal tumors. J Magn Reson Imaging. 2009;29:112–7.
35. Lyon SM, Lee MJ. Imaging the non-hyperfunctioning adrenal mass. Imaging. 2002;14:137–46.
36. Krebs TL, Wagner BJ. The adrenal gland: radiologic-pathologic correlation. Magn Reson Imaging Clin North Am. 1997;5:127–46.
37. Guo YK, Yang ZG, Li Y, Ma ES, Deng YP, Min PQ, et al. Uncommon adrenal masses: CT and MRI features with histopathologic correlation. Eur J Radiol. 2007;62: 359–70.
38. Krebs TL, Wagner BJ. MR imaging of the adrenal gland: radiologic-pathologic correlation. Radiographics. 1998; 18:1425–40.
39. Francis IR, Korobkin M. Pheochromocytoma. Radiol Clin North Am. 1996;34:1101–12.
40. Arora S, Vargo S, Lupetin AR. Computed tomography appearance of spontaneous adrenal hemorrhage in a pheochromocytoma. Clin Imaging. 2009;33:314–7.
41. Rha SE, Byun JY, Jung SE, Chun HJ, Lee HG, Lee JM. Neurogenic tumors in the abdomen:tumor types and imaging characteristics. Radiographics. 2003;23:29–43.
42. Mukherjee JJ, Peppercorn PD, Reznek RH, et al. Pheochromocytoma: effect of nonionic contrast medium in CT on circulating catecholamine levels. Radiology. 1997; 202:227–31.
43. Arnaldi G, Angeli A, Atkinson AB, et al. Diagnosis and complications of Cushing's syndrome: a consensus statement. J Clin Endocrinol Metab. 2003;88:5593–602.
44. Nugent CA, Nichols T, Tyler FH. Diagnosis of Cushing syndrome: single dose dexamethasone suppression test. Arch Intern Med. 1965;116:172–6.
45. Mansmann G, Lau J, Balk E, Rothberg M, Miyachi Y, Bornstein SR.The clinically inapparent adrenal mass: update in diagnosis and management. Endocr Rev. 2004; 25:309–40.
46. Vilar L, Freitas Mda C, Faria M, Montenegro R, Casulari LA, Naves L, Bruno OD. Pitfalls in the diagnosis of Cushing's syndrome. Arq Bras Endocrinol Metabol. 2007;51: 1207–16.
47. Findling JW, Raff H. Cushing's syndrome: important issues in diagnosis and management. J Clin Endocrinol Metab. 2006;91:3746–53.
48. Reincke M, Nieke J, Krestin GP, Saeger W, Allolio B, Winkelman W. Preclinical Cushing's syndrome in adrenal "incidentalomas." Comparison with adrenal Cushing's syndrome. J Clin Endocrinol Metab. 1992; 75:826–32.
49. Russi S, Blumenthal HT, Gray SH. Small adenomas of the adrenal cortex in hypertension and diabetes. Arch Intern Med. 1945;76:284–91.
50. Leibowitz G, Tsur A, Chayen SD, et al. Pre-clinical Cushing's syndrome. An unexpected frequent cause of poor glycaemic control in obese diabetic patients. Clin Endocrinol (Oxf). 1996;44:717–22.
51. Osella G, Terzolo M, Reimondo G, et al. Serum markers of bone and collagen turnover in patients with Cushing's

Author's personal copy

syndrome and in subjects with adrenal incidentalomas. J Clin Endocrinol Metab. 1997;82:3303–7.
52. Sartorio A, Conti A, Ferrero S, et al. Evaluation of markers of bone and collagen turnover in patients with active and preclinical Cushing's syndrome and in patients with adrenal incidentaloma. Eur J Endocrinol. 1998;138:146–52.
53. Bertherat J, Mosnier-Pudar HH, Bertagna X. Adrenal incidentalomas. Curr Opin Oncol. 2002;14:58–63.
54. Barzon L, Fallo F, Sonino N, Boscaro M. development of overt Cushing's syndrome in patients with adrenal incidentaloma. Eur J Endocrinol. 2002;146:61–6.
55. Libè R, dall'Asta C, Barbetta L, Baccarelli A, Beck-Peccoz P, Ambrosi B. Long-term follow-up study of patients with adrenal incidentalomas. Eur J Endocrinol. 2002;147: 489–94.
56. Gordon RD, Ziesak MD, Tunny TJ, Stowasser M, Klemm SA. Evidence that primary aldosteronism may be not uncommon: 12% incidence among antihypertensive drug trial volunteers. Clin Exp Pharmacol Physiol. 1993; 20:296–8.
57. Cicala MV, Sartorato P, Mantero F. Incidentally discovered masses in hypertensive patients. Best Pract Res Clin Endocrinol Metab. 2006;20:451–66.
58. Lavoie H, Lacroix A. Partially autonomous cortisol secretion by incidentally discovered adrenal adenomas. Trends Endocrinol Metab. 1995;6:191–4.
59. Arnaldi G, Masini AM, Giacchetti G, Taccaliti A, Faloia E, Mantero F. Adrenal incidentaloma. Braz J Med Biol Res. 2000;33:1177–89.
60. Bravo EL, Tarazi RC, Gifford RW, Stewart BH. Circulating and urinary catecholamines in pheochromocytoma. Diagnostic and pathophysiologic implications. N Engl J Med. 1979; 301:682–6.
61. Grossman A, Pacak K, Sawka A, et al. Biochemical diagnosis and localization of pheochromocytoma: can we reach a consensus? Ann N Y Acad Sci. 2006;1073: 332–47.
62. Lenders JW, Pacak K, Walther MM, et al. Biochemical diagnosis of pheochromocytoma: which test is best? 2002;287:1427–34.
63. Davidson DF. Phaeochromocytoma with normal urinary catecholamines: the potential value of urinary free metadrenalines. Ann Clin Biochem. 2002;39:557–66.
64. Eisenhofer G, Keiser H, Friberg P, et al. Plasma metanephrines are markers of pheochromocytoma produced by catechol-O-methyltransferase within tumors. J Clin Endocrinol Metab. 1998;83:2175–85.
65. Maurea S, Klain M, Mainolfi C, Ziviello M, Salvatore M. The diagnostic role of radionuclide imaging in evaluation of patients with nonhypersecreting adrenal masses. J Nucl Med. 2001;42:884–92.
66. Boland GW, Goldberg MA, Lee MJ, et al. Indeterminate adrenal mass in patients with cancer: evaluation at PET with 2-[F-18]-fluoro-2-deoxy-D-glucose. Radiology. 1995; 194:131–4.
67. Maurea S, Mainolfi C, Bazzicalupo L, et al. Imaging of adrenal tumors using FDG PET: comparison of benign and malignant lesions. AJR Am J Roentgenol. 1999;173: 25–9.
68. Shapiro B, Copp JE, Sisson JC, Eyre PL, Wallis J, Beierwaltes WH. Iodine-131 metaiodobenzylguanidine for the locating of suspected pheochromocytoma: experience in 400 cases. J Nucl Med. 1985;26:576–85.
69. Shulkin BL, Thompson NW, Shapiro B, Francis IR, Sisson JC. Pheochromocytomas: imaging with 2-[fluorine-18] fluoro-2-deoxy-D-glucose PET. Radiology. 1999;212: 35–41.
70. Hoegerle S, Nitzsche E, Altehoefer C, et al. Pheochromocytomas: detection with ^{18}F DOPA whole body PET–initial results. Radiology. 2002;222:507–12.
71. Trampal C, Engler H, Juhlin C, Bergström M, Långström B. Pheochromocytomas: detection with 11C hydroxyephedrine PET. Radiology. 2004;230:423–8.
72. Pacak K, Eisenhofer G, Goldstein DS. Functional imaging of endocrine tumors: role of positron emission tomography. Endocr Rev. 2004;25:568–80.
73. Arellano RS, Harisinghani MG, Gervais DA, Hahn PF, Mueller PR. Image guided percutaneous biopsy of the adrenal gland: review of indications, technique, and complications. Curr Probl Diagn Radiol. 2003;32:3–10.
74. Welch TJ, Sheedy PF II, Stephens DH, Johnson CM, Swensen SJ. Percutaneous adrenal biopsy: review of a 10-year experience. Radiology. 1994;193:341–4.
75. Smith CD, Weber CJ, Amerson JR. Laparoscopic adrenalectomy: new gold standard. World J Surg. 1999;23: 389–96.
76. Valeri A, Borrelli A, Presenti L, et al. The influence of new technologies on laparoscopic adrenalectomy: our personal experience with 91 patients. Surg Endosc. 2002;16:1274–9.
77. Gagner M, Lacroix A, Bolte E, Pomp A. Laparoscopic adrenalectomy. The importance of a flank approach in the lateral decubitus position. Surg Endosc. 1994;8: 135–8.
78. Cheng SP, Saunders BD, Gauger PG, Doherty GM. Laparoscopic partial adrenalectomy for bilateral pheochromocytomas. Ann Surg Oncol. 2008;15:2506–8.
79. NIH. State-of-the-science statement on management of the clinically inapparent adrenal mass ('incidentaloma'). NIH Consensus and State-of-the-Science Statements. 2002;19:1–25.
80. Cawood TJ, Hunt PJ, O'Shea D, Cole D, Soule S. Recommended evaluation of adrenal incidentalomas is costly, has high false-positive rates and confers a risk of fatal cancer that is similar to the risk of the adrenal lesion becoming malignant; time for a rethink? Eur J Endocrinol. 2009;161:513–27.