



UNIVERSITÀ
DEGLI STUDI
FIRENZE

FLORE

Repository istituzionale dell'Università degli Studi di Firenze

Crown-root reattachment of severe subgingival tooth fracture: a 15-month periodontal evaluation

Questa è la Versione finale referata (Post print/Accepted manuscript) della seguente pubblicazione:

Original Citation:

Crown-root reattachment of severe subgingival tooth fracture: a 15-month periodontal evaluation / L. Giachetti; F. Bertini; R. Rotundo. - In: THE INTERNATIONAL JOURNAL OF PERIODONTICS & RESTORATIVE DENTISTRY. - ISSN 0198-7569. - STAMPA. - 30:(2010), pp. 393-399.

Availability:

This version is available at: 2158/373562 since:

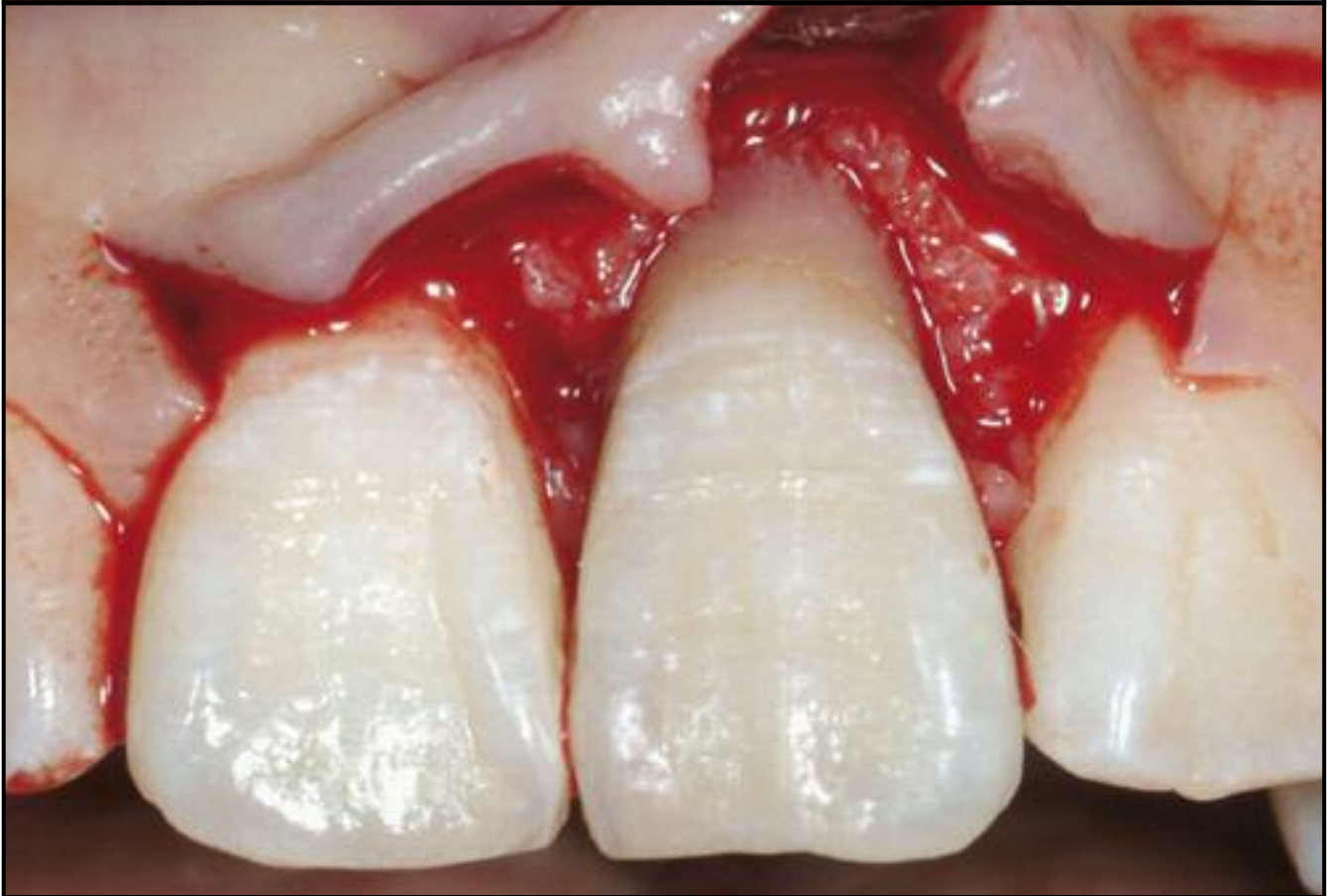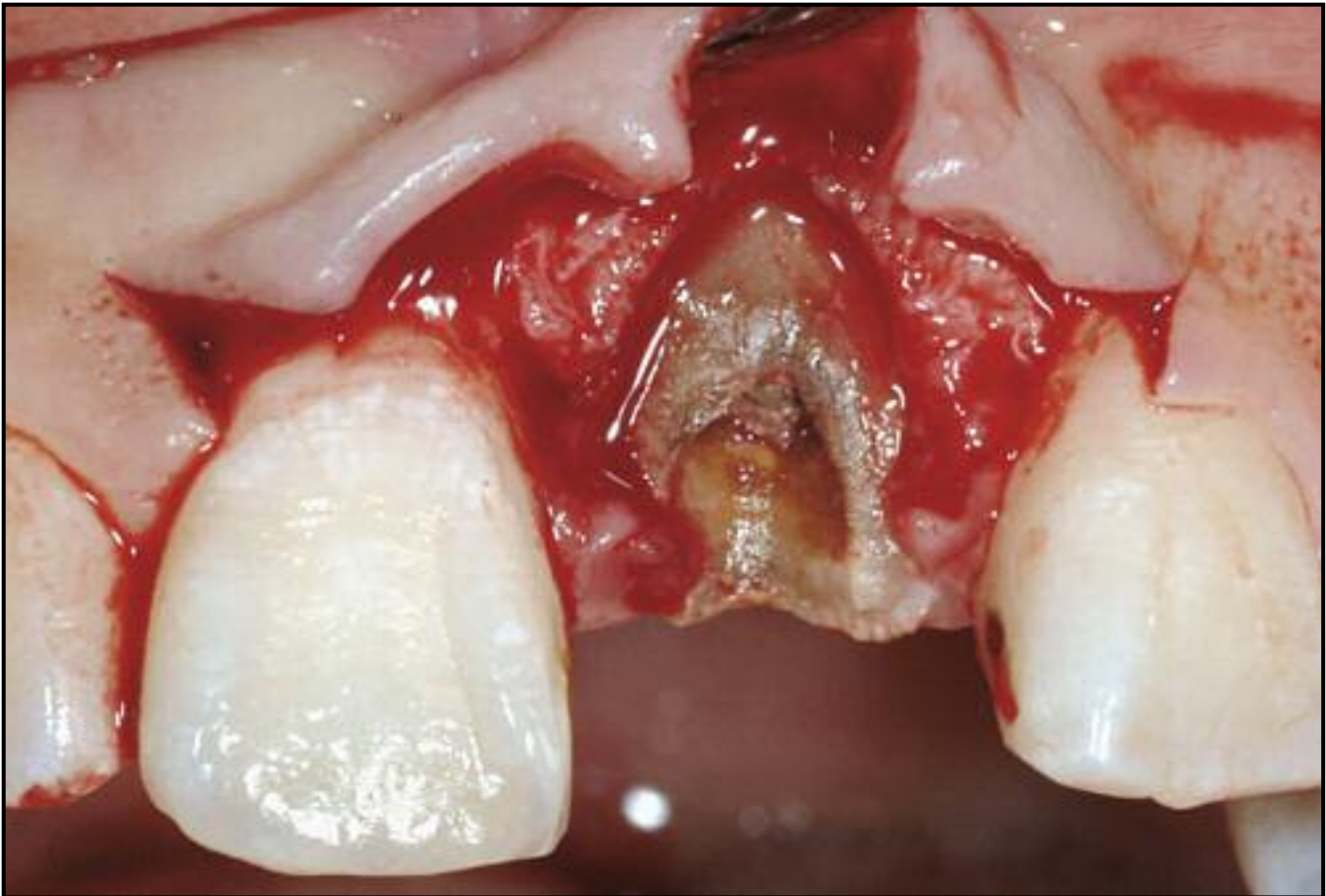
Terms of use:

Open Access

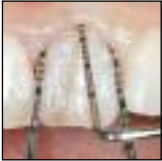La pubblicazione è resa disponibile sotto le norme e i termini della licenza di deposito, secondo quanto stabilito dalla Policy per l'accesso aperto dell'Università degli Studi di Firenze (<https://www.sba.unifi.it/upload/policy-oa-2016-1.pdf>)

Publisher copyright claim:

(Article begins on next page)



Crown-Root Reattachment of a Severe Subgingival Tooth Fracture: A 15-Month Periodontal Evaluation



Luca Giachetti, MD, DMD*
 Fabio Bertini, MD, DMD**
 Roberto Rotundo, DDS***

Traumatic tooth fractures represent an intriguing challenge for clinicians, particularly when they involve the anterior region of the maxilla. In such situations, esthetic, psychosocial, functional, and therapeutic problems may have a negative effect on the patient's quality of life. In addition, fractures that involve the biologic width of the periodontium are even more difficult to treat. An interdisciplinary approach based on crown lengthening with or without orthodontic extrusion and the definitive prosthetic rehabilitation represent the standard modality of treatment for these conditions to restore the appropriate biologic dimension and to reduce the damage esthetically. However, if the margins of the fragment and the tooth show perfect juxtaposition with no interfragmentary space, an adhesive technique may be indicated. The aim of this case report is to describe the treatment of a severe subgingival tooth fracture by means of adhesive reattachment of the fragment followed by a periodontal evaluation over a 15-month period. (Int J Periodontics Restorative Dent 2010;30:393–399.)

*Assistant Professor and Chair of Dental Materials, Department of Dentistry, University of Florence, Florence, Italy.

**Research Fellow, Department of Dentistry, University of Florence, Florence, Italy.

***Research Fellow, Department of Periodontology, University of Florence, Florence, Italy.

Correspondence to: Dr Luca Giachetti, Department of Dentistry (Dipartimento di Odontostomatologia), Viale Morgagni 85, 50134 Firenze, Italy; fax: +39055411798; email: l.giachetti@odonto.unifi.it.

The prevalence of traumatic dental injuries varies among different populations and ages,¹ and they can frequently lead to tooth lesions, affecting both the supporting dental structures and hard tissues.² Particularly when the trauma affects the anterior teeth, esthetic, psychosocial, functional, and therapeutic problems adversely affect the individual's quality of life.³ Reattachment techniques have been described in demanding clinical situations^{4–6} and show differing success rates. Andreasen et al⁷ reported that 50% of reattached fragments were lost within the first year when only enamel bonding was used, while 3 years had elapsed before 50% of fragments were lost when dentin bonding was carried out. Other authors^{8,9} reported up to an 80% success rate at 5 years and suggested that reattachment regimens may be used for longer-term restorations.

A severe crown-root fracture involving the biologic width, the dimension of the soft tissue that is attached to the portion of the tooth coronal to the crest of the alveolar bone, needs to be approached carefully.¹⁰ Its dimensions may vary among individuals, as reported in different

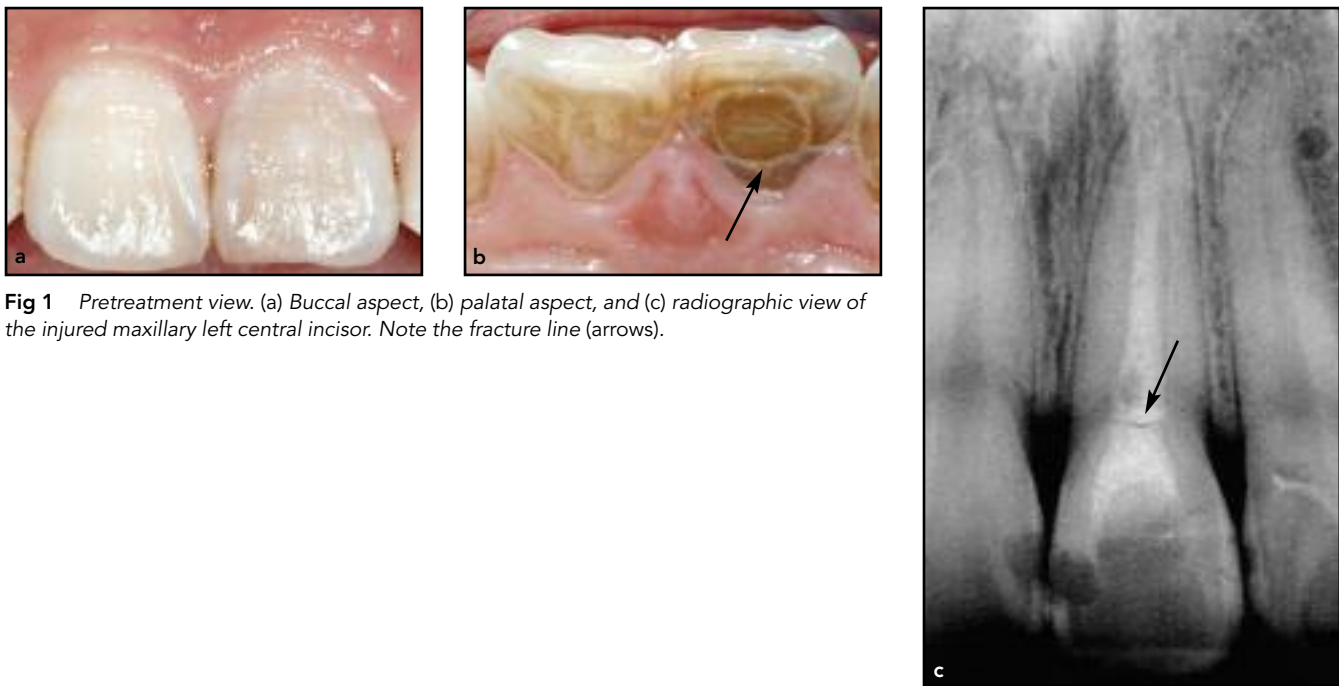


Fig 1 Pretreatment view. (a) Buccal aspect, (b) palatal aspect, and (c) radiographic view of the injured maxillary left central incisor. Note the fracture line (arrows).

studies. Gargiulo et al¹⁰ reported a mean sulcus depth of 0.69 mm, a mean epithelial attachment of 0.97 mm, and a mean connective tissue attachment of 1.07 mm. Based on these dimensions, the biologic width is a mean of 2.04 mm, representing the sum of the epithelial and connective tissue. In 1994, Vacek et al¹¹ reported a similar biologic width dimension of 1.91 mm, with a mean sulcus depth of 1.34 mm, a mean epithelial attachment of 1.14 mm, and a mean connective tissue attachment of 0.77 mm. More recently, Xie et al¹² reported that the mean biologic width calculated in a Chinese population was 2.17 mm, confirming previous observational studies.

Generally, placing restorative margins within the biologic width frequently determines gingival inflammation, clinical attachment loss, and bone loss.¹³ This may be attributed to the destructive inflammatory response

to microbial plaque located apical to the restorative margins. For this reason, Ingber et al¹⁴ suggested that a minimum of 3 mm was required from the restorative margin to the alveolar crest to permit adequate healing and restoration of the tooth.

From a therapeutic point of view, this is achieved by means of an interdisciplinary approach that combines periodontal surgery, with or without orthodontics, and prosthetic restoration. However, in the case of tooth fractures where a juxtaposition of the fragment with the tooth shows that the margins of each fit well against one another and no interfragmentary space is present, an adhesive technique may be considered as an alternative approach. This conservative technique should permit a quick resolution with low biologic and economic costs. The aim of this paper is to report on a clinical case of a severe

subgingival tooth fracture restored by means of adhesive reattachment of the fragment followed by a periodontal evaluation over a 15-month period.

Clinical report

A 26-year-old woman presented at a private dental practice in April 2006 with increased mobility of the maxillary left central incisor. The patient reported an accidental trauma that had occurred 6 hours earlier. No signs of tissue inflammation were observed and no pain was reported. A linear fracture was evident on the palatal aspect of the tooth (Figs 1a and 1b).

Upon radiographic examination (Fig 1c), it was noted that the tooth had been previously treated endodontically and a horizontal linear fracture was observed, which was situated approximately at the cemento-enamel

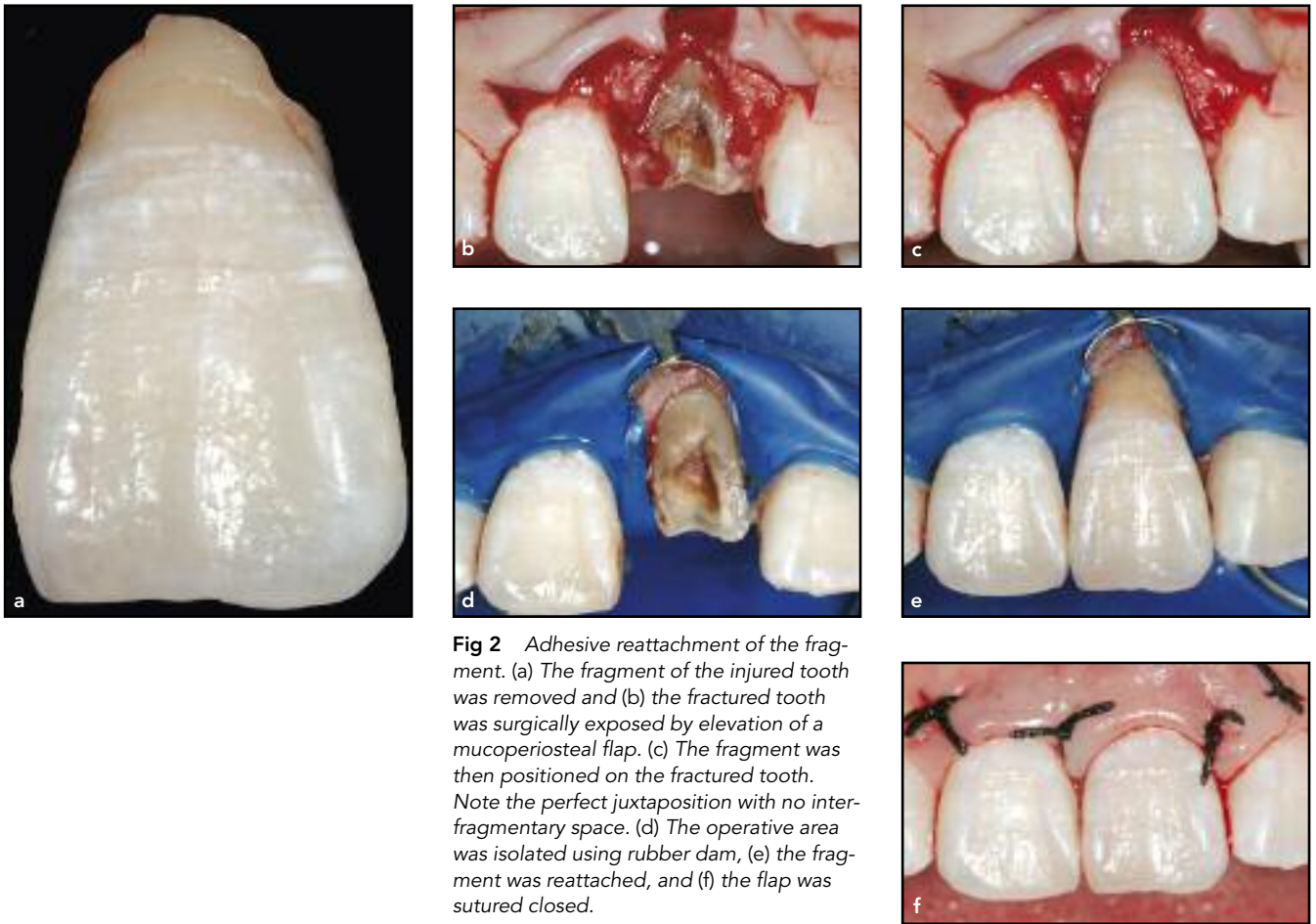


Fig 2 Adhesive reattachment of the fragment. (a) The fragment of the injured tooth was removed and (b) the fractured tooth was surgically exposed by elevation of a mucoperiosteal flap. (c) The fragment was then positioned on the fractured tooth. Note the perfect juxtaposition with no interfragmentary space. (d) The operative area was isolated using rubber dam, (e) the fragment was reattached, and (f) the flap was sutured closed.

junction. At that point it was decided to remove the coronal fragment of the tooth (Fig 2a). Because of the emergency nature of the situation as well as the desire of the patient to avoid extraction, a reattachment procedure was chosen.

After local anesthesia administered via injection, a mucoperiosteal flap was elevated, exposing the fracture line close to the buccal bone crest (Fig 2b). Juxtaposition of the fragment with the tooth showed that the margins of each fit well against one another and no interfragmentary space was present (Fig 2c). Rubber dam was then

positioned to isolate the operative area (Fig 2d). The fractured surfaces of the tooth and the fragment were treated with self-etching primer (Clearfil SE Primer, Kuraray). The primer was allowed to remain undisturbed for 20 seconds, the surfaces were gently air dried, and the adhesive (Clearfil SE Bond) was applied to both surfaces and subsequently thinned with air. A thin layer of heated nanofilled composite resin was applied to the fractured surface of the fragment. The fragment was placed in its original position and the excess composite resin was removed. The resin was then

light cured for 120 seconds at 580 mW/cm² (Demetron Optilux 500, Kerr) from various directions. Silicone-based polishing points (Composite Polishing Kit, Shofu Dental) and polishing disks (Soflex Pop-On 1981M-1981F, 3M ESPE) of decreasing coarseness were used to polish marginal areas while finishing strips (Soflex 1954N-1956, 3M ESPE) were used in interproximal areas (Fig 2e).

The flap was sutured using 4-0 silk sutures (Hu-Friedy) and no periodontal dressing was applied (Fig 2f). During the first week postsurgery, the patient was instructed to use chlorhexidine

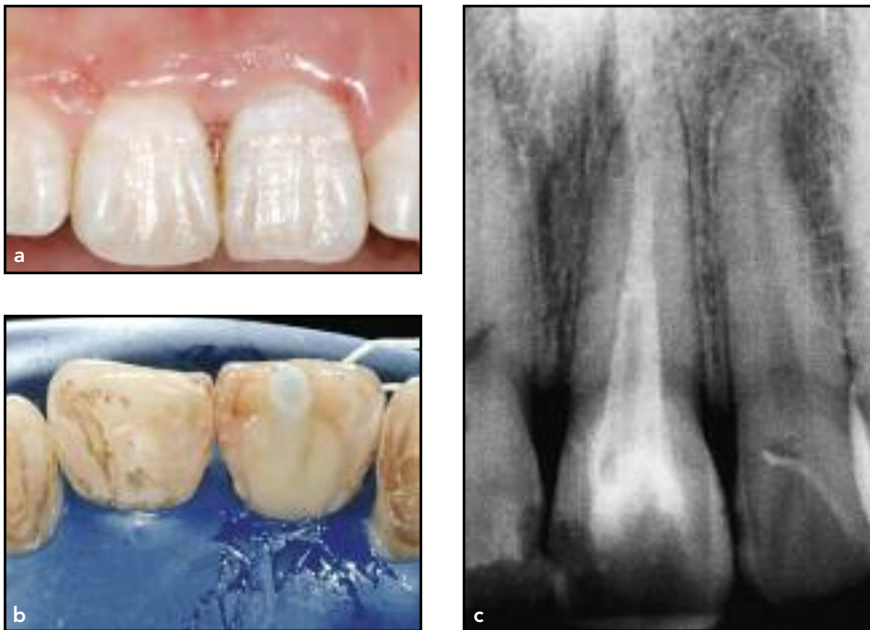


Fig 3 One week postoperative. (a) The sutures were removed and (b) a fiber-reinforced post was inserted to reinforce the reattached fragments. (c) The treatment method was checked radiographically.

digluconate 0.12% mouthwash twice a day and to discontinue tooth brushing to avoid trauma to the treated area.

After 1 week, the sutures were removed and a fiber-reinforced post (Postec, Ivoclar Vivadent) was applied to enhance the union between the two bonded fragments (Figs 3a to 3c). Although this procedure seems to make sense mechanically, the evidence for it is not available specifically.

Follow-up

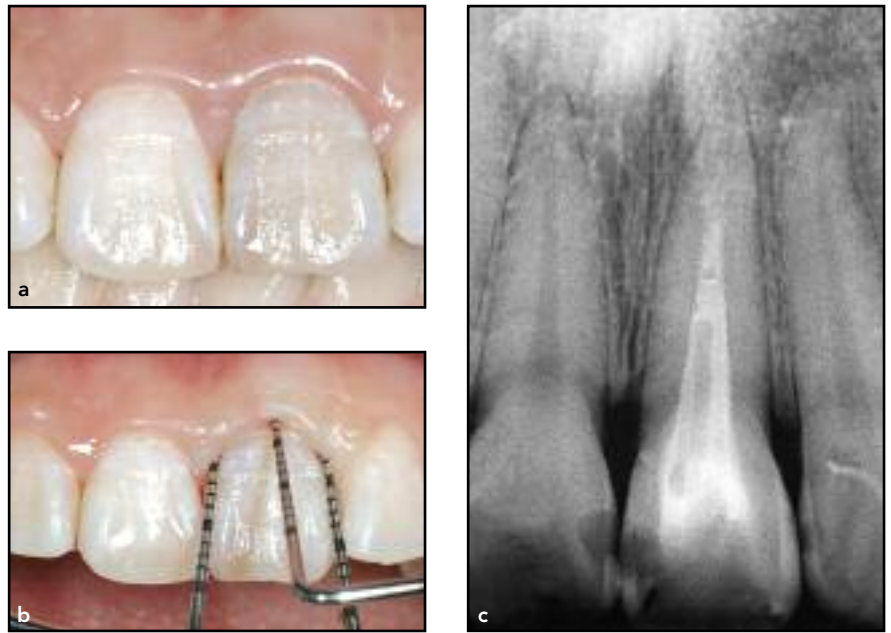The patient was recalled for periodontal maintenance, diagnostic evaluation (periodontal probing, assessment of gingival inflammation, and plaque accumulation), and professional oral hygiene every 3 months. Fifteen

months posttreatment there were no signs of inflammation, deep probing depth, or gingival recession (Figs 4a to 4c). The radiographic evaluation showed an absence of bone loss in relation to the treated tooth.

Discussion

The conventional approaches to the rehabilitation of fractured anterior teeth include composite restorations and post-core-supported prosthetic restorations.¹⁵⁻¹⁷ For fractures extending beyond the biologic width, the literature reports several different treatments, ranging from a definitive crown after orthodontic or surgical extrusion or crown lengthening^{18,19} to extraction of the residual tooth

Fig 4 (a) Clinical aspect, (b) periodontal evaluation, and (c) radiographic view of the repaired tooth at 15 months postoperative.



followed by immediate or delayed implant surgery¹⁹⁻²¹ or a fixed partial denture.²²

Recently, it has become possible to preserve and use the tooth fragment as either a provisional or definitive crown^{19,23,24} by means of the reattachment technique. This technique can be applied to both fractures, which include simple enamel-dentin portions, and to more complex situations in which the pulp²⁵ and periodontium are involved.⁴ The advantage of the reattachment technique is that once the original fragment is reattached, the natural appearance will be restored instantly. Composite resin, which is applied to the fractured surfaces, may remain resistant for a long period of time when compared with

conventional composite restorations. Using the fractured fragment will minimize the amount of material used in the required restoration.

Good short-term⁴ and medium-term²⁶ results of this technique have been demonstrated, whereas long-term results are still unknown. However, it has been reported that if the restorative margins are placed within the biologic width, this may cause gingival inflammation, clinical attachment loss, and bone loss.¹³ This case report presents good esthetics and functional outcomes over a 15-month period, hypothesizing a reattachment of the periodontal apparatus on the restored tooth surface. A longer period of follow-up is necessary to observe the outcome of the reattachment technique in other clinical cases.

Conclusion

The reattachment of a tooth fragment following deep subgingival fracture by means of an adhesive procedure resulted in a successful periodontal and radiographic result at the 15-month follow-up.

References

- Dearing SG. Overbite, overjet, lip-drape and incisor tooth fracture in children. *N Z Dent J* 1984;80:50–52.
- Andreasen JO. Etiology and pathogenesis of traumatic dental injuries. A clinical study of 1,298 cases. *Scand J Dent Res* 1970;78:329–342.
- Baldava P, Anup N. Risk factors for traumatic dental injuries in an adolescent male population in India. *J Contemp Dent Pract* 2007;8:35–42.
- Baratieri LN, Monteiro S Jr, Caldeira de Andrada MA. Tooth fracture reattachment: Case reports. *Quintessence Int* 1990;21:261–270.
- Burke FJT. Reattachment of a fractured central incisor tooth fragment. *Br Dent J* 1991;170:223–225.
- DiAngelis AJ, Jungbluth MA. Reattaching fractured tooth segments: An esthetic alternative. *J Am Dent Assoc* 1992;123:58–63.
- Andreasen FM, Norén JG, Andreasen JO, Engelhardt S, Lindh-Strömberg U. Long-term survival of fragment bonding in the treatment of fractured crowns: A multicenter clinical study. *Quintessence Int* 1995;26:669–681.
- Cavalleri G, Zerman N. Traumatic crown fractures in permanent incisors with immature roots: A follow-up study. *Endod Dent Traumatol* 1995;11:294–296.
- Vijayakumaran V. Evaluation of crown restoration of fractured anterior teeth using original tooth fragment [abstract 520]. *J Dent Res* 1998;77(special issue B):696.
- Gargiulo AW, Wentz F, Orban B. Dimensions and relation of the dentogingival junction in humans. *J Periodontol* 1961;32:261–267.
- Vacek JS, Gehr ME, Asad DA, Richardson AC, Giambarresi LI. The dimensions of the human dentogingival junction. *Int J Periodontics Restorative Dent* 1994;14:154–165.
- Xie GY, Chen JH, Wang H, Wang YJ. Morphological measurement of biologic width in Chinese people. *J Oral Sci* 2007;49:197–200.
- Pama-Benfenati S, Fugazzotto PA, Ferreira PM, Ruben MP, Kramer GM. The effect of restorative margins on the postsurgical development and nature of the periodontium. Part II. Anatomical considerations. *Int J Periodontics Restorative Dent* 1986;6:64–75.
- Ingber JS, Rose LF, Coslet JG. The "biologic width"—A concept in periodontics and restorative dentistry. *Alpha Omegan* 1977;70:62–65.
- Buonocore MG, Davilla J. Restoration of fractured anterior teeth with ultraviolet-light-polymerized bonding materials: A new technique. *J Am Dent Assoc* 1973;86:1349–1354.
- Santos JFF, Bianchi J. Restoration of severely damaged teeth with resin bonding systems: Case reports. *Quintessence Int* 1991;22:611–615.
- Simonsen RJ. Traumatic fracture restoration: An alternative use of the acid etch technique. *Quintessence Int Dent Dig* 1979;2:15–22.
- Holan G, Shmueli Y. Knowledge of physicians in hospital emergency rooms in Israel on their role in cases of avulsion of permanent incisors. *Int J Paediatr Dent* 2003;13:13–19.
- Villat C, Machtou P, Naulin-Ifi C. Multidisciplinary approach to the immediate esthetic repair and long-term treatment of an oblique crown-root fracture. *Dent Traumatol* 2004;20:56–60.
- Trushkowsky RD. Esthetic, biologic and restorative considerations in coronal segment reattachment for a fractured tooth: A clinical report. *J Prosthet Dent* 1998;79:115–119.

21. Leroy RLRG, Asp JKM, Raes FM, Martens LC, De Boever JA. A multidisciplinary treatment approach to a complicated maxillary dental trauma: A case report. *Endod Dent Traumatol* 2000;16:138–142.
22. Meiers JC, Freilich MA. Chairside prefabricated fiber-reinforced resin composite fixed partial dentures. *Quintessence Int* 2001;32:99–104.
23. Koparal E, Ilgenli T. Reattachment of a subgingivally fractured central incisor tooth fragment: Report of a case. *J Clin Pediatr Dent* 1999;23:113–115.
24. Baratieri LN, Monteiro Júnior S, Cardoso AC, de Melo Filho JC. Coronal fracture with invasion of the biologic width: A case report. *Quintessence Int* 1993;24:85–91.
25. Liew VP. Re-attachment of original tooth fragment to a fractured crown. Case report. *Aust Dent J* 1988;33:47–50.
26. Oz IA, Haytaç MC, Toroglu MS. Multidisciplinary approach to the rehabilitation of a crown-root fracture with original fragment for immediate esthetics: A case report with 4-year follow-up. *Dent Traumatol* 2006;22:48–52.