



UNIVERSITÀ
DEGLI STUDI
FIRENZE

FLORE

Repository istituzionale dell'Università degli Studi di Firenze

Single-incision laparoscopic colectomy: technical aspects and short-term results.

Questa è la Versione finale referata (Post print/Accepted manuscript) della seguente pubblicazione:

Original Citation:

Single-incision laparoscopic colectomy: technical aspects and short-term results / F.Cianchi; E.Qirici; G.Trallori; B.Mallardi; B.Badii; G. Perigli. - In: UPDATES IN SURGERY. - ISSN 2038-131X. - STAMPA. - 64:(2012), pp. 19-23.

Availability:

This version is available at: 2158/607199 since:

Terms of use:

Open Access

La pubblicazione è resa disponibile sotto le norme e i termini della licenza di deposito, secondo quanto stabilito dalla Policy per l'accesso aperto dell'Università degli Studi di Firenze (<https://www.sba.unifi.it/upload/policy-oa-2016-1.pdf>)

Publisher copyright claim:

(Article begins on next page)

Single-incision laparoscopic colectomy: technical aspects and short-term results

Fabio Cianchi · Etleva Qirici · Giacomo Trallori ·
Beatrice Mallardi · Benedetta Badii ·
Giuliano Perigli

Received: 30 August 2011 / Accepted: 16 September 2011
© Springer-Verlag 2011

Abstract Single-incision laparoscopic surgery (SILS) is currently regarded as the next major advance in the progress of minimally invasive techniques in colorectal surgery. We describe our initial experience using SILS for the management of colorectal disease and present preliminary short-term results. Between February 2010 and April 2011, 7 patients (4 females and 3 males, mean age 55 years, range 32–74) underwent SILS for either benign or malignant colorectal disease. Preoperative diagnosis was diverticular disease of the sigmoid colon in two patients, malignant polyps of the sigmoid colon in two other patients and large villous tumor of the right colon in three patients. Surgical procedures, 4 anterior resections of the rectum and 3 right hemicolectomies, were performed through a 3 cm single umbilical incision using a SILS multi port device with conventional or articulated laparoscopic instruments. There were no intraoperative complications or conversions in the standard laparoscopic procedure. The mean operative time for anterior resections was 160.0 ± 10.6 min, whereas it was 160.6 ± 20 for right hemicolectomies. Blood loss was minimal. No postoperative complications were reported in any of the patients. The overall mean hospital stay was 4.8 ± 0.2 days (range 4–5). For the

subset of patients with malignant or pre-malignant disease, the mean number of retrieved lymph nodes was 15.6 ± 4.4 (range 6–31). Cosmetic results were considered excellent by all the patients after 15 days. In conclusion, our preliminary experience shows that SILS for colorectal disease is feasible and safe with potential reproducible oncologic results.

Keywords Single port laparoscopic surgery · Colectomy · Miniinvasive surgery · Colorectal cancer

Introduction

Laparoscopic technique has been enthusiastically applied to the resection of colorectal cancer for more than 15 years [1]. There is an evidence that laparoscopy for colorectal cancer offers the opportunity for a meticulous dissection of the mesocolon and mesorectum under direct vision while facilitating a true no-touch technique [2]. Additional benefits, such as less postoperative pain, reduced need for postoperative analgesia, less ileus, shorter hospital stay, less blood loss, and a better cosmesis are also well documented [3, 4].

In recent years, a great effort has been made to minimize parietal trauma for cosmetic reasons, and to further reduce surgery related pain and morbidity. New techniques, such as natural orifice transluminal endoscopic surgery (NOTESTM) [5] and single-incision laparoscopic surgery (SILS) [6] have been developed in order to reach the goal of “scarless” surgery. Although the NOTES may not be fully suitable or safe for advanced procedures, such as colectomies, SILS is currently regarded as the next major advance in minimally invasive surgical approaches to colorectal disease which is more feasible in generalized use [7–9]. The small incision

F. Cianchi (✉) · E. Qirici · B. Badii · G. Perigli
Department of Medical and Surgical Critical Care,
Medical School, University of Florence, Largo
Brambilla 3, 50134 Florence, Italy
e-mail: fabio.cianchi@unifi.it

G. Trallori
Unit of Gastroenterology, Azienda Ospedaliero-Universitaria
Careggi, Florence, Italy

B. Mallardi
Istituto Scientifico Prevenzione Oncologica (ISPO),
Florence, Italy

through the umbilicus allows the surgeons to use familiar standard laparoscopic instruments, thus performing complex procedures which require extraction of large surgical specimens or intestinal anastomosis.

However, SILS raises a number of specific new challenges compared with the conventional laparoscopic approach. A reduced capacity for triangulation is the most outstanding issue, with its imposed need to operate sometimes with crossed hands [10]. Furthermore, the repeated conflicts between the shafts of the instruments and the difficulty of achieving a correct exposure and the necessary traction to tissues without a supplementary instrument are also the major problems [10]. The use of this new approach for complex colorectal procedures might understandably be viewed as difficult to implement, especially for oncological cases. However, since 2008, a total of 29 articles and 2 systematic reviews have been published on single-access laparoscopic colorectal surgery, with a total of 149 patients reported [11].

The present study describes our preliminary short-term results using SILS in a series of seven patients who underwent colectomy for various colorectal pathologies.

Patients and methods

Between February 2010 and April 2011, 7 patients (4 females and 3 males, mean age 55 years, range 32–74) underwent SILS for either benign or pre-malignant colorectal disease. Preoperative diagnosis was diverticular disease of the sigmoid colon in two patients, malignant polyps (previously treated by not radical endoscopic polypectomy) of the sigmoid colon in two patients, tumor of the cecum in one patient and large villous polyps (non-suitable for endoscopic removal) of the ascending colon in two patients. Demographic data including patient's age, gender, and body mass index (BMI) were tabulated together with the history of prior abdominal surgery. Intraoperative parameters including umbilical incision length, operative time, estimated blood loss, and intraoperative complications were analyzed. Pathologic characteristics such as specimen length and lymph node retrieval were reviewed, and postoperative outcomes including length of stay in hospital and complication rate were collected.

All the procedures were performed by the same surgeon (F.C.) who has had extensive experience in standard laparoscopic colorectal resection. All of the patients underwent bowel preparation with polyethylene glycol electrolyte solution 2 days before the operation. Surgical procedures, 4 anterior resections of the rectum, and 3 right hemicolectomies, were performed through a 3 cm single umbilical incision using a SILS multi-port device (SILS™ port, Covidien Ltd, Norwalk, CT, USA) that allows three

additional trocars (two 5 mm and one 10–12 mm) to be inserted and has a CO₂ connection for insufflations (Fig. 1). A 50 cm, extra-long, 5 mm 30° laparoscope (Karl Storz Endoscopy, Tuttlingen, Germany), and either conventional or articulated laparoscopic instruments (31 cm Roticulator; Covidien) were used.

Operations were performed using a surgical technique similar to the standard laparoscopic (medial-to-lateral) approach. In the anterior resections, we preserved the trunk of both inferior mesenteric artery and vein while sigmoid vessels were divided using the Ligasure vessel sealing system (Covidien) (Fig. 2). Colon suspension was obtained by means of external stitches. Subsequently, medial-to-lateral mobilization was performed to mobilize the left colon and the splenic flexure. The mid rectum was transected with one or two intracorporeal applications of Endopath 45 (Ethicon, Endo-surgery, Cincinnati, OH, USA) through the 10 mm port. The fascial incision was extended to about 4–5 cm and a wound protector was inserted for retrieval of the specimen. The anvil of 29 mm circular stapler (Ethicon) was placed outside the abdomen and an intracorporeal anastomosis was performed with the circular stapler inserted through the anus under direct vision (Fig. 3). In the right hemicolectomies, the ileocolic vessels were divided at the level of the duodenum using one application of Endopath 45 (Ethicon) (Fig. 4), whereas the right colic vessels were divided using 5 mm clips. An ultrasonic dissector (Ultracision ACE™, Ethicon) was used to mobilize the proximal colon and the hepatic flexure. The ileum was transected with one intracorporeal application of Endopath 45 (Ethicon). Similar to the anterior resection, the fascial incision was extended and a wound protector was inserted for extraction and resection of the transverse colon. A side-to-side stapled ileocolic anastomosis was performed extracorporeally (Fig. 5).

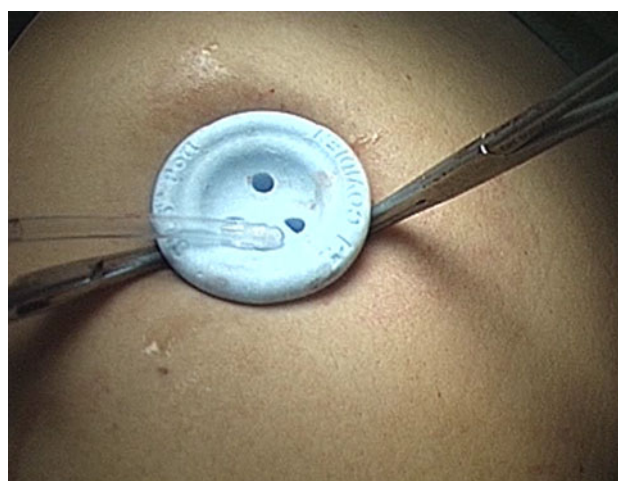


Fig. 1 Single-incision laparoscopic surgery (SILS™) port

In both procedures, one drain was inserted through the single incision and placed at the anastomotic site (Fig. 6). The fascia was then closed with interrupted absorbable sutures.

Results

The clinical data of the seven patients are summarized in Table 1.

Patients were carefully selected with a mean BMI of 25.8 (range 20–39). Only one patient has had previous laparotomy for appendectomy. There were no intraoperative complications or need for conversion to the standard laparoscopic procedure or laparotomy. The mean operative times were 160.0 ± 10.6 min for anterior resections and 160.6 ± 20 min for right hemicolectomies. Blood loss was <100 cc in all procedures.

In all patients postoperative pain was well managed by intravenous (i.v.) paracetamol (3 g/day for the first 3 days) and i.v. ketorolac at the patient's request. No postoperative complications were reported in any of the patients. The first flatus was recorded between second and third postoperative day and all patients received oral fluid on postoperative day 2 and a low residual diet between the third and fifth postoperative days. The overall mean hospital stay was 4.8 ± 0.2 days (range 4–5 days). No postoperative complications were observed.

For the two patients with malignant polyps not radically removed by endoscopy, no residual tumor tissue was demonstrated upon histopathological examination of the specimens. The mean length of surgical specimens was 19.7 cm (range 18.2–21.5) and the mean number of retrieved lymph nodes was 10.5 ± 5.5 (range 6–16). In the patients who had undergone right hemicolectomy,

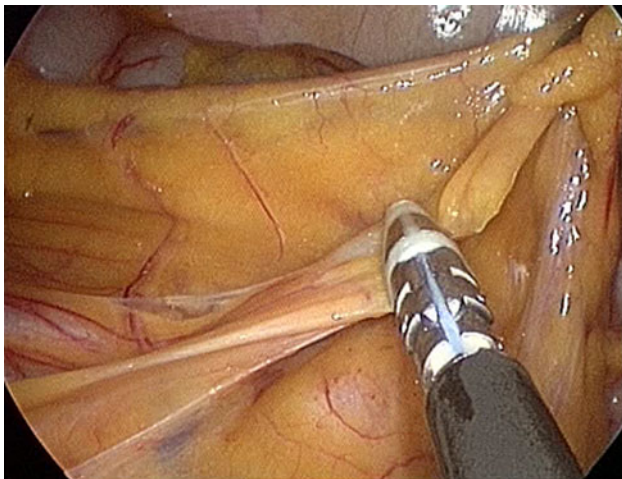


Fig. 2 Division of the sigmoid vessels using the Ligasure vessel sealing

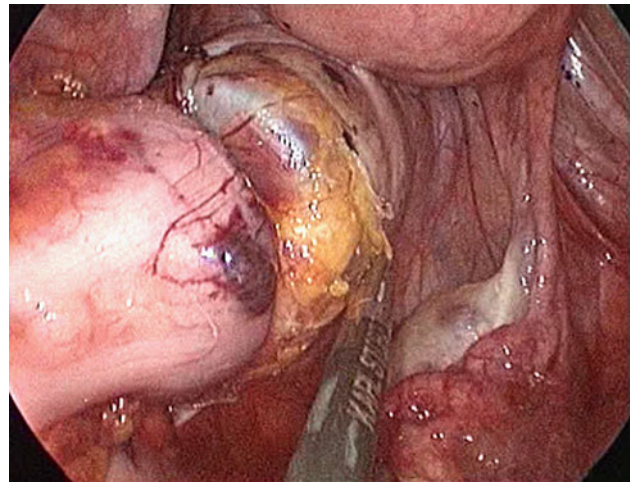


Fig. 3 Intracorporeal colorectal anastomosis with a circular stapler

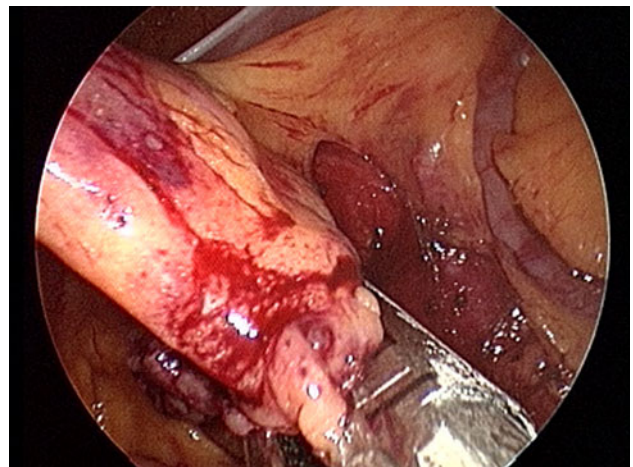


Fig. 4 Division of the ileocolic vessels using one application of a linear stapler

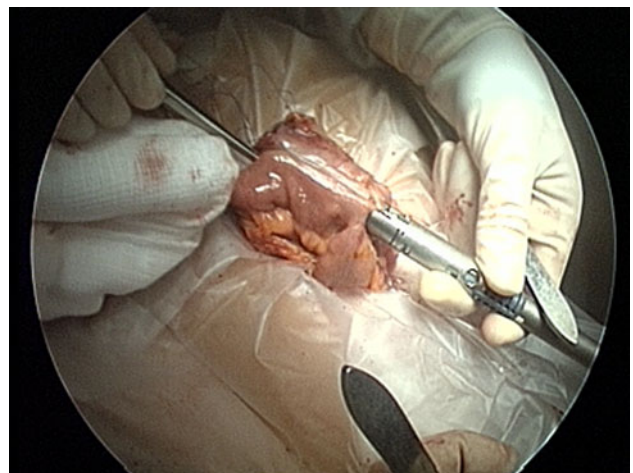


Fig. 5 Extracorporeal side-to-side stapled ileocolic anastomosis

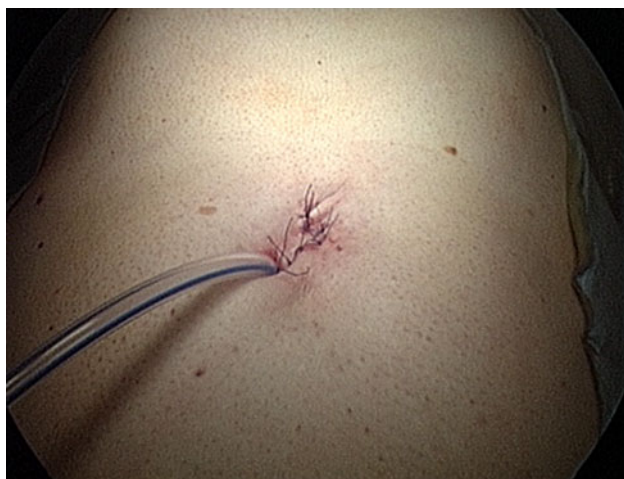

Fig. 6 Postoperative view of SILS

Table 1 Patient demographics

Patients	<i>N</i> = 7
Age (years)	
Mean (range)	55 (32–74)
Sex	
Male	3
Female	4
BMI	
Mean (range)	25.8 (20–39)
Prior abdominal surgery	
Yes	1
No	6
Preoperative diagnosis	
Diverticular disease	2
Malignancy	3
Polyps	2
Surgical procedures	
Right hemicolectomy	3
Anterior resection of the rectum	4

pathological diagnosis was adenocarcinoma (pT₁N₀M₀) in one case and villous adenoma in the other two. For these three patients, the mean length of the surgical specimens was 17.5 cm (range 16.0–18.5) and the mean number of retrieved lymph nodes was 19.3 ± 6.3 (range 9–31).

The mean length of umbilical incision was 3.1 ± 0.4 cm (range 3.0–3.3) and cosmetic result was considered excellent by all patients on postoperative day 15.

Discussion

During the last few years, several attempts to introduce “ultra” minimally invasive surgical technique, such as

NOTES or SILS, have been made. NOTES is based on the principle of using natural orifices, such as the stomach, vagina or others to introduce the scope and instruments to accomplish a number of surgical procedures [5]. Although this is a true “scarless” technique, the procedure is significantly more difficult than the standard laparoscopy and often requires a multidisciplinary team in the operating room. In particular, the use of NOTES for more advanced oncological procedures seems to be impractical in the clinic. On the other hand, SILS has some significant advantages over NOTES, especially with the possibility of using all common laparoscopic instruments, such as laparoscopes, straight or articulated instruments, and the full-range of commercially available energy-based dissecting devices [12]. The fundamental and novel idea of SILS is to have all of the laparoscopic working ports entering the abdominal wall through the same incision. The reduction in the number of ports decreases the postoperative wound pain and the risk of incisional hernias. Moreover, it improves cosmesis and hence overall patient satisfaction.

However, the major drawback to such a surgical approach is that the concept of “triangulation” to which laparoscopic surgeons have grown accustomed in terms of both the instruments and scope is lacking [6, 10]. This dogmatic principle of laparoscopic surgery is necessary for appropriate operative exposure and entails an ergonomically favorable position for the surgeon and assistants. The inherent technical challenge arising from SILS is that the visual axis becomes more axial or in-line. In this condition, a movement of the camera often results in an inadvertent movement of an adjacent instrument, thus increasing the difficulty of performing even relatively simple tasks. Although angled or flexible scopes can minimize this problem to some extent, there remains the issue of the limitation in external working space. The multiple instruments and laparoscopes required for a procedure are competing for the same space at the fulcrum of the entry port, causing hand collisions externally and difficulty with instrument tip manipulation internally [6]. To reduce external clashing of instruments, we used an extra-long, 5 mm laparoscope which allowed us to place the camera on a different plane from the other instruments. The only drawback of a long laparoscope is the decrease in the amount of light returned to the image capture chip and thus the decrease in the brilliance of the image when compared with the standard laparoscopy.

All seven colectomies were performed using the SILSTM port. This device, made from an elastic polymer, is a cylindrical soft molded port that is easily placed and provides a relatively good seal with adequate pneumoperitoneum during both right- and left-sided resections and even after the extension of fascial incision for retrieval of the specimens. In our experience, the compressibility of the elastic polymer helped to ameliorate the crowding effect and the limited mobility of the instruments at the fulcrum of the entry port. In

addition, the SILS™ port facilitated the easy exchange of 5 and 12 mm ports during the procedure.

In an attempt to recreate the critical triangulation, we also used articulating instruments, a grasper and a dissector, with 0°–80° articulation at their distal ends. The articulating devices were useful in providing adequate exposure of the operative field, especially in mobilization of flexures and in the removal of adhesions. However, the articulation of instruments often compels the surgeon to awkwardly cross them in order to avoid external collision. Moreover, to improve the exposure of work space and traction of the colon during dissection and placement of staplers, we suspended either the ascending or descending colon with external stitches.

Operative times for both anterior resections and right hemicolectomies in our experience are comparable with those reported in other previously published studies [13–16]. In terms of pathological results, and especially lymph node harvest, we cannot provide definitive results given the limited number of our oncological cases. However, a mean of 19.3 lymph nodes was found after right hemicolectomy and 10.5 after anterior resection performed for oncological indications. These numbers are adequate and comparable with those reported in large multicenter randomized laparoscopic trials (range 10–14 lymph nodes) [17, 18].

Conclusion

SILS for colectomy seems to be safe and effective with potential reproducible oncologic results. In addition to improved cosmesis, the other benefits of reduced pain, fewer complications and improved patient satisfaction of SILS will require robust randomized clinical trials to confirm our preliminary results. The very concept of “minimization” of the surgical approach has created an entirely new laparoscopic technique that requires the application of several new devices and technical principles. Inattention to these concepts can lead to a poor operative exposure and an instrument manipulation that prolong the operation and can compromise safety.

Acknowledgments This study was supported by grants from the Italian Ministry of University, Scientific and Technological Research and the Ente Cassa di Risparmio di Firenze.

Conflict of interest None.

References

- Jacob BP, Salky B (2005) Laparoscopic colectomy for colon adenocarcinoma: an 11-year retrospective review with 5-year survival. *Surg Endosc* 19:643–649
- Lujan HJ, Plasencia G, Jacobs M, Viamonte M 3rd, Hartmann RF (2002) Long-term survival after laparoscopic colon resection for cancer: complete five-year follow-up. *Dis Colon Rectum* 45:491–501
- Guillou PJ, Quirke P, Thorpe H, Walker J, Jayne DG, Smith AM, Heath RM, Brown JM, MRC CLASICC trial group (2005) Short-term end points of conventional versus laparoscopic-assisted surgery in patients with colorectal cancer (MRC CLASSICC trial): multicentre, randomized controlled trial. *Lancet* 365:1718–1726
- Clinical outcomes of surgical therapy (COST) study group (2004) A comparison of laparoscopically assisted and open colectomy for colon cancer. *N Engl J Med* 350:2050–2059
- Gumbs AA, Fowler D, Milone L, Evanko JC, Ude AO, Stevens P, Bessler M (2009) Transvaginal natural orifice transluminal endoscopic surgery cholecystectomy: early evolution of the technique. *Ann Surg* 249:908–912
- Romanelli JR, Earle DB (2009) Single-port laparoscopic surgery: an overview. *Surg Endosc* 23:1419–1427
- Remzi FH, Kirat HT, Kaouk JH, Geisler DP (2008) Single port laparoscopy in colorectal surgery. *Colorectal Dis* 10:823–826
- Bucher P, Pugin F, Morel P (2009) Transumbilical single incision laparoscopic sigmoidectomy for benign disease. *Colorectal Dis* 12:61–65
- Law W-L, Fan JKM, Poon JTC (2010) Single-incision laparoscopic colectomy: early experience. *Dis Colon Rectum* 53:284–288
- Islam A, Castellvi AO, Tesfay ST, Castellvi AD, Wright AS, Scott DJ (2011) Early surgeon impressions and technical difficulty associated with laparoendoscopic single-site surgery: a Society of American Gastrointestinal and Endoscopic Surgeons learning center study. *Surg Endosc* 25:2597–2603
- Diana M, Dhumane P, Cahill RA, Mortensen N, Leroy J, Marescaux J (2011) Minimal invasive single-site surgery in colorectal procedures: current state of art. *J Minim Access Surg* 7:52–60
- Dhumane P, Diana M, Leroy J, Marescaux J (2011) Minimally invasive single-site surgery for the digestive system: a technological review. *J Minim Access Surg* 7:40–51
- Boni L, Dionigi G, Cassinotti E, Di Giuseppe M, Diurni M, Rauser S, Cantore F, Dionigi R (2010) Single incision laparoscopic right colectomy. *Surg Endosc* 24:3233–3236
- Ross H, Steele S, Whiteford M, Lee S, Albert M, Mutch M, Rivadeneira D, Marcello P (2011) Early multi-institution experience with single-incision laparoscopic colectomy. *Dis Colon Rectum* 54:187–192
- Chew MH, Wong MT, Lim BY, Ng KH, Eu KW (2011) Evaluation of current device in single-incision laparoscopic colorectal surgery: a preliminary experience in 32 consecutive cases. *World J Surg* 35:873–880
- Pietrasanta D, Romano N, Prosperi V, Lorenzetti L, Basili G, Goletti O (2010) Single-incision laparoscopic right colectomy for cancer: a single-centre preliminary experience. *Updates Surg* 62:111–115
- Jayne DG, Guillou PJ, Thorpe H, Quirke P, Copeland J, Smith AM, Heath RM, Brown JM, UK MRC CLASICC Trial Group (2007) Randomized trial of laparoscopic-assisted resection of colorectal carcinoma: 3-year results of the UK MRC CLASSICC Trial Group. *J Clin Oncol* 25:3061–3068
- Buunen M, Veldkamp R, Hop WC, Kuhry E, Jeekel J, Haglind E, Pahlman L, Cuesta MA, Msika S, Morino M, Lacy A, Bonjer HJ, The Colon Cancer Laparoscopic or Open Resection Study Group (2009) Survival after laparoscopic surgery versus open surgery for colon cancer: long-term outcome of a randomized clinical trial. *Lancet Oncol* 10:44–52