UNIVERSITÀ DEGLI STUDI FIRENZE

FLORE
Repository istituzionale dell'Università degli Studi di Firenze

Aortic type B dissection with acute expansion of iliac artery aneurysm in previous endovascular repair with iliac branched graft

Questa è la Versione finale referata (Post print/Accepted manuscript) della seguente pubblicazione:

Original Citation:

Aortic type B dissection with acute expansion of iliac artery aneurysm in previous endovascular repair with iliac branched graft / R. Pulli; A. Fargion; G. Pratesi; W. Dorigo; D. Angiletta; C. Pratesi. - In: JOURNAL OF VASCULAR SURGERY. - ISSN 0741-5214. - STAMPA. - 54:(2011), pp. 1788-1791.

Availability:

This version is available at: 2158/605855 since:

Terms of use:

Open Access

La pubblicazione è resa disponibile sotto le norme e i termini della licenza di deposito, secondo quanto stabilito dalla Policy per l'accesso aperto dell'Università degli Studi di Firenze (https://www.sba.unifi.it/upload/policy-oa-2016-1.pdf)

Publisher copyright claim:

(Article begins on next page)

12 October 2024

Provided for non-commercial research and education use.
Not for reproduction, distribution or commercial use.

This article appeared in a journal published by Elsevier. The attached copy is furnished to the author for internal non-commercial research and education use, including for instruction at the authors institution and sharing with colleagues.

Other uses, including reproduction and distribution, or selling or licensing copies, or posting to personal, institutional or third party websites are prohibited.

In most cases authors are permitted to post their version of the article (e.g. in Word or Tex form) to their personal website or institutional repository. Authors requiring further information regarding Elsevier's archiving and manuscript policies are encouraged to visit:

http://www.elsevier.com/copyright

Author's personal copy

Aortic type B dissection with acute expansion of iliac artery aneurysm in previous endovascular repair with iliac branched graft

Raffaele Pulli, MD,[a] Aaron Fargion, MD,[a] Giovanni Pratesi, MD,[b] Walter Dorigo, MD,[a] Domenico Angiletta, MD,[c] and **Carlo Pratesi, MD,[a]** *Florence, Rome, and Bari, Italy*

We report the case of a patient previously treated with an iliac branch endograft for isolated iliac artery aneurysm who developed, more than 2 years later, a type B aortic dissection resulting in the acute expansion of the previously excluded iliac aneurysm. Successful endovascular salvage is described. (J Vasc Surg 2011;54:1788-91.)

The development of an acute type B aortic dissection following endovascular aneurysm repair (EVAR) has been anecdotally reported.[1-3] We report the unique case of a patient previously treated with an iliac branch endograft for isolated iliac artery aneurysm who developed a type B aortic dissection resulting in the acute expansion of the previously excluded iliac aneurysm.

CASE REPORT

A 69-year-old male was referred to our department for a large right common iliac artery aneurysm (maximum diameter of 54 mm; Fig 1, *A*). No family history of aneurismal disease was present. The patient was normotensive and was a current smoker with significant chronic obstructive pulmonary disease. The aneurysm had been diagnosed during a computed tomography (CT) scan performed for the diagnostic assessment of a left colonic cancer. The abdominal aorta had a maximum diameter of 37 mm (Fig 1, *B*), while the diameter of the contralateral common iliac artery was 19 mm (Fig 1, *A*). The thoracic aorta had normal appearance and diameter. A staged treatment was planned, with the bowel resection following the repair of the aneurysm. A Zenith Z-BIS 12 × 45 × 41 (Cook Medical Inc, Bloomington, Ind) iliac branch device was deployed just above the right iliac bifurcation and then an ADVANTA V-12 (Atrium Medical Corporation, Hudson, NH) 10 × 59-mm covered stent was delivered in a classic cross-over technique to the right hypogastric artery. The procedure was completed with a Zenith FLEX (Cook Medical Inc) main body in an immediate infrarenal position (diameter 28 mm) and then with an iliac limb (diameter 18 mm × 54 mm) extending just above the left hypogastric origin. Completion angiography did not show any evidence of endoleak or dissection (Fig 1, *C*). The recovery was uneventful and the patient was discharged on the fifth postoperative day. A CT scan performed at 30 days demonstrated the correct placement of the graft, with the complete exclusion of the aneurysm. Three months postoperatively, the patient underwent left bowel resection followed by chemotherapy and radiotherapy. During follow-up, serial CT and Duplex scans showed the complete exclusion of the aneurysm with initial sac shrinkage (diameter 50 mm) and neither sign of endoleak nor recurrence of cancer. In January 2011, 27 months after EVAR, the patient was sent to the emergency department of our hospital for acute thoracic back pain. While waiting to perform an urgent CT-scan, the patient suddenly developed an acute abdominal pain, mainly located at the right pelvis. The CT-scan showed an aortic type B dissection with the proximal tear close to the origin of the left subclavian artery (Fig 2, *A*), with multiple re-entry sites at the visceral level and the false lumen progressing down beyond the abdominal graft and heading to the right iliac with signs of acute expansion of the aneurysm sac (maximum diameter increase to 65 mm) due to a re-entry site (Fig 2, *B* and *C*). The patient did not show any sign of malperfusion syndrome, the thoracic pain progressively decreased with adequate drug therapy (antihypertensive and pain drugs) while the abdominal one persisted. A staged procedure was planned. According to our policy for patients undergoing left subclavian artery coverage, a left carotid-left subclavian bypass without ligation of the proximal subclavian artery was performed and, after 12 hours, the patient underwent an endovascular procedure performed in the angiosuite and a cerebrospinal fluid (CSF) drainage catheter was placed prior to the treatment. A TX2 (Cook Medical Inc) thoracic stent graft proximal component (38 mm × 152 mm) was deployed just close to the ostium of the left common carotid artery to close the proximal tear of the dissection. Two dissection endovascular bare metal stents (Cook Medical Inc) were then deployed from the proximal graft down inside the abdominal graft (46 mm × 164 mm; 46 mm × 164 mm). At the completion angiography, the left renal artery, originating from the false lumen, was supposed to be in danger of malperfusion (Fig 3, *A*); the vessel was engaged with a 0.014-inch guidewire on a 6F-guiding catheter, and a Palmatz Blue (Cordis Corp, Bridgewater, NJ) bare metal stent (7 mm × 24 mm) was placed

From the Department of Vascular Surgery, University of Florence, Florence[a]; Department of Vascular Surgery, University of Rome Tor Vergata, Rome[b]; and Department of Vascular Surgery, University of Bari, Bari.[c]

Competition of interest: none.

Reprint requests: Walter Dorigo, MD, Department of Vascular Surgery, University of Florence, Viale Morgagni 85, 50134, Florence, Italy (e-mail: dorigow@unifi.it).

The editors and reviewers of this article have no relevant financial relationships to disclose per the JVS policy that requires reviewers to decline review of any manuscript for which they may have a competition of interest.

0741-5214/$36.00

Copyright © 2011 by the Society for Vascular Surgery.

doi:10.1016/j.jvs.2011.06.029

Author's personal copy

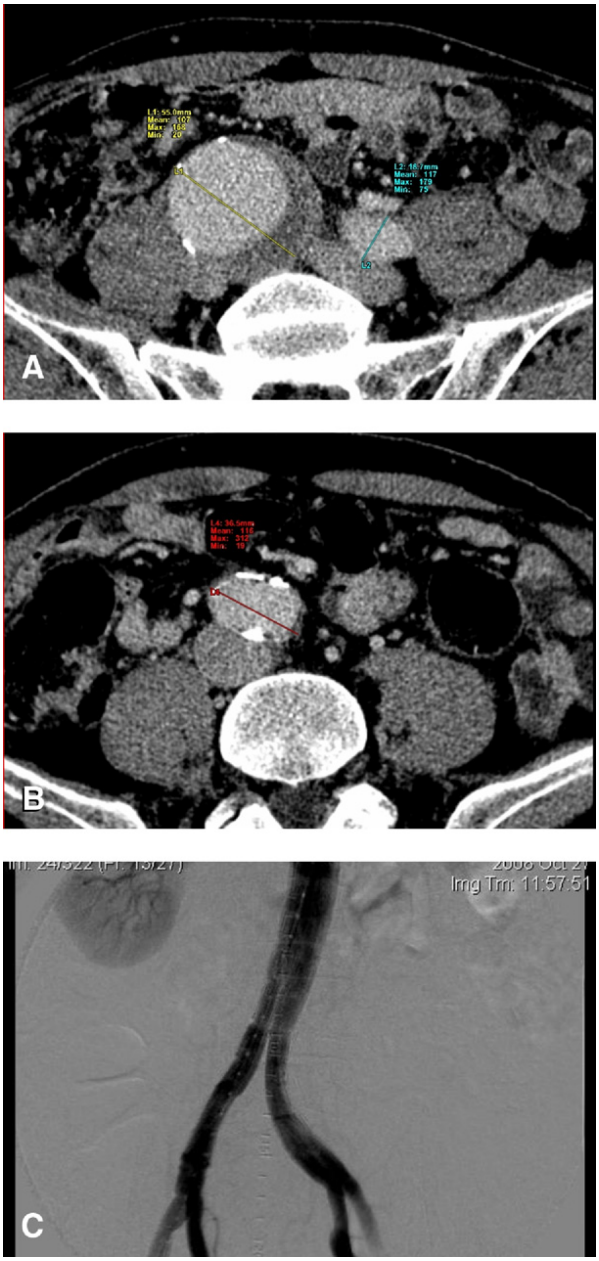

Fig 1. Computed tomography (CT) scan before the original endovascular aneurysm repair (EVAR) with iliac branched, showing the large iliac aneurysm **(A)**, the dilated aorta **(B)** and the completion angiography after endograft placement **(C)**.

through the interstices of the dissection stents to ensure the patency (Fig 3, *B*). Via left brachial access, an Amplatzer (St Jude Medical Inc, St Paul, Minn) vascular plug IV (8 mm) was placed at the origin of the left subclavian artery. The final angiography showed the exclusion of the proximal tear with a patent false lumen at the level of the visceral arteries, but no more contrast medium was present in the iliac aneurysm. After the procedure, the patient was transferred to the intensive care unit for 72 hours. After 48 hours, the patient did not show any neurologic complication and the CSF drainage was removed. No severe complication occurred during the hospital stay, and the renal function was normal. The patient underwent a CT scan before discharge on the 10th postoperative day, showing the occlusion of the proximal entry site (Fig 3, *C*), exclusion of the right iliac aneurysm and patency of all visceral vessels (Fig 3, *D*). At 3 months, an abdominal duplex scanning confirmed the complete exclusion of the iliac aneurysm without signs of endoleak.

DISCUSSION

Three cases of type B dissection following EVAR were reported in past years: one case occurred on the second postoperative day and caused the development of a type I thoracoabdominal aortic aneurysm,[1] while one case occurred 11 weeks after surgery and caused endograft collapse and severe visceral and peripheral malperfusion.[2] In the remaining case,[3] the patient, who had been operated on 6 months before, developed bilateral acute limb ischemia due to endograft thrombosis and died. This is the first reported case occurring after the placement of an iliac branch endograft. Several causes can be advocated in the development of post-EVAR type B dissection. Some technical and device-specific factors could have been taken into account if the dissection had occurred in the early postoperative period.[4-6] The delayed presentation of dissection with respect to the endovascular procedure could support the hypothesis of a spontaneous dissection beginning at the subclavian artery. In our case, the force of the dissection plane did not stop at the level of the proximal limit of the endovascular prosthesis, finding a way to progress across the left renal toward the iliac arteries. The explanation for this event is unclear; we suppose that the force of the dissection exceeded the radial expansion force of the endograft, probably due to its steel structure. No re-entry at the level of the iliac arteries occurred, thus resulting in a sudden rupture of the dissection flap inside the right iliac aneurysm sac, with the consequent acute expansion of the aneurismal sac. One can suppose that the branched configuration of the graft at the iliac level could have influenced the mechanism of progression of the dissection, preventing the graft collapse, as already reported in the literature with standard aortic endografts,[2] and leading to acute aneurismal pressurization. In our case, it was possible to treat the dissection with the coverage of the entry tear[7] and with the placement of two dissection-specific stents, allowing the reduction of pressurization of the iliac sac and the expansion of the true lumen distally, providing the maintenance of an adequate visceral perfusion. To minimize the risk of spinal cord ischemia, we are used to performing a surgical revascularization of the left subclavian artery prior to its coverage during endograft deployment. In this particular case, the relatively stable status of the patients allowed us to adopt a two-stage strategy.

Physicians treating aortic disease with an endovascular approach should be aware of the potential complications of type B dissection occurring in patients with implanted pros-

Author's personal copy

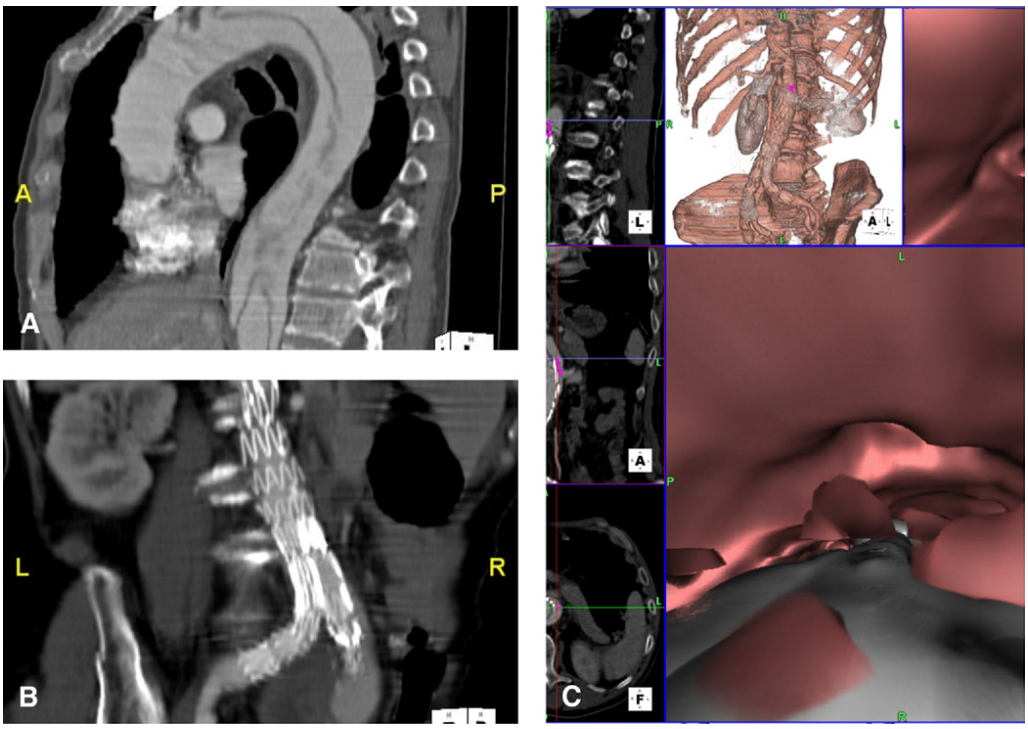

Fig 2. Preoperative computed tomography (CT) scan showing the origin of the dissection **(A)**, the extension to the right iliac artery (**B,** *posterior view*) and virtual angioscopy of the aortic dissection with the images of the false lumen at the level of proximal original endograft and the ostium of left renal artery arising from the false lumen **(C)**.

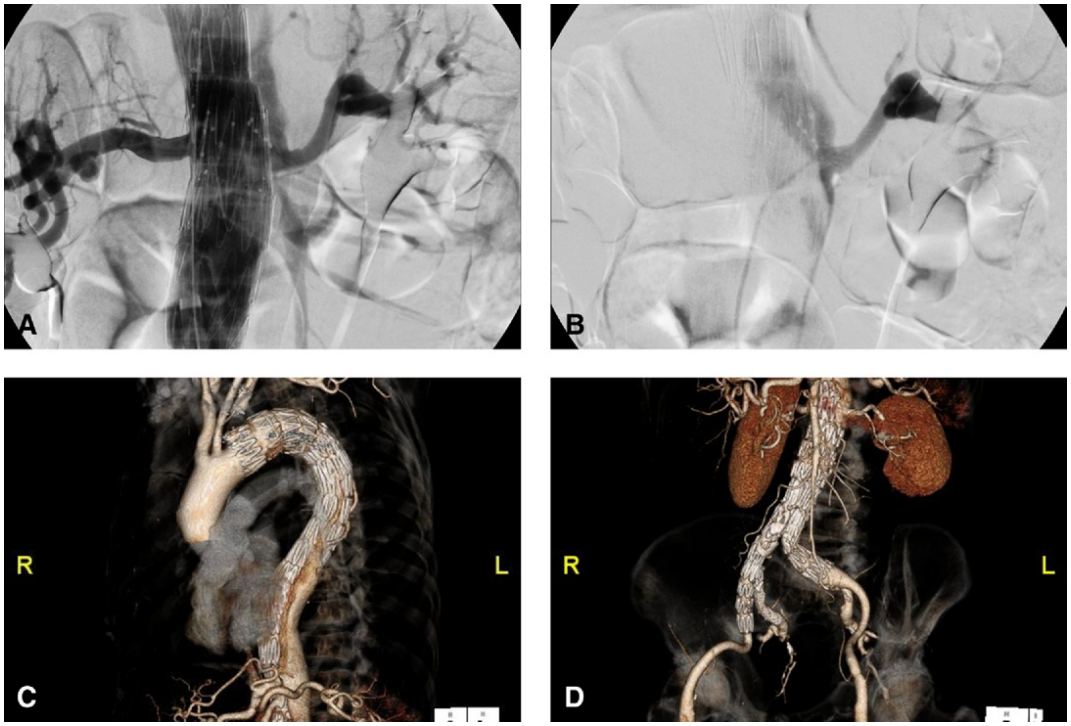

Fig 3. Intraprocedural angiogram that shows the supposed malperfusion of the left renal artery (LRA) arising from the false lumen after aortic stent placement **(A)** and LRA stented **(B)**. Computed tomography (CT) scan at 10 days showing the occlusion of the entry tear and the collapse of the false lumen **(C)** and the exclusion of iliac aneurysm **(D)**.

Author's personal copy

theses. The presence of a mechanical device that potentially limits re-entries can modify the behavior of dissection planes, leading to complications similar to the case we report.

REFERENCES

1. Girardi LN, Bush HL Jr. Type B aortic dissection and thoracoabdominal aneurysm formation after endoluminal stent repair of abdominal aortic aneurysm. J Vasc Surg 1999;29:936-8.
2. Iyer V, Rigby M, Vrabec G Sr. Type B aortic dissection after endovascular abdominal aortic aneurysm repair causing endograft collapse and severe malperfusion. J Vasc Surg 2009;50:413-6.
3. Haulon S, Greenberg RK, Khwaja J, Turc A, Srivastava SD, Eagleton M, et al. Aortic dissection in the setting of an infrarenal endoprosthesis: a fatal combination. J Vasc Surg 2003;38:1121-4.
4. Cisek PL, McKittrick JE. Retrograde aortic dissection after bilateral iliac artery stenting: a case report and review of the literature. Ann Vasc Surg 1995;9:280-4.
5. Beitzke A, Stein J-I, Gamillscheg A, Rigler B. Dissection of the descending aorta after balloon angioplasty of native coarctation. Pediatr Cardiol 1997;18:222-5.
6. Haesemeyer SW, Vedantham S, Braverman A. Renal artery stent placement complicated by development of a type B aortic dissection. Cardiovasc Intervent Radiol 2005;28:98-101.
7. Dake MD, Kato N, Mitchell RS, Semba CP, Razavi MK, Shimono T, et al. Endovascular stent graft placement for the treatment of acute aortic dissection. N Engl J Med 1999;340:1546-52.

Submitted Apr 6, 2011; accepted Jun 14, 2011.