



UNIVERSITÀ
DEGLI STUDI
FIRENZE

FLORE

Repository istituzionale dell'Università degli Studi di Firenze

Head-to-head comparison of exercise stress testing, pharmacologic stress echocardiography, and perfusion tomography as first-line

Questa è la Versione finale referata (Post print/Accepted manuscript) della seguente pubblicazione:

Original Citation:

Head-to-head comparison of exercise stress testing, pharmacologic stress echocardiography, and perfusion tomography as first-line examination for chest pain in patients without history of coronary artery disease / G.M. Santoro; R. Sciagrà; P. Buonamici; N. Consoli; V. Mazzone; F. Zeraushek; G. Bisi; P.F. Fazzini.. - In: JOURNAL OF NUCLEAR CARDIOLOGY. - ISSN 1071-3581. - STAMPA. - 5:(1998), pp. 19-27.

Availability:

This version is available at: 2158/771955 since:

Terms of use:

Open Access

La pubblicazione è resa disponibile sotto le norme e i termini della licenza di deposito, secondo quanto stabilito dalla Policy per l'accesso aperto dell'Università degli Studi di Firenze (<https://www.sba.unifi.it/upload/policy-oa-2016-1.pdf>)

Publisher copyright claim:

(Article begins on next page)

Head-to-head comparison of exercise stress testing, pharmacologic stress echocardiography, and perfusion tomography as first-line examination for chest pain in patients without history of coronary artery disease

Giovanni M. Santoro, MD, FESC, Roberto Sciagrà, MD,
Piergiorgio Buonamici, MD, Nicola Consoli, MD, Vincenzo Mazzoni, MD,
Francesca Zeraushek, MD, Gianni Bisi, MD, and Pier Filippo Fazzini, MD

Background. To overcome the relatively low accuracy of exercise stress testing (EST) in detecting coronary artery disease (CAD), both echocardiography and perfusion scintigraphy have been evaluated in conjunction with pharmacologic stress, but there is still uncertainty of the relative value of these tests as possible first-line examinations for suspected CAD. This study evaluated the accuracy of EST, dipyridamole and dobutamine stress echocardiography (DIP-ECHO, DOB-ECHO), and dipyridamole and dobutamine technetium 99m sestamibi tomography (DIP-MIBI, DOB-MIBI) for the detection of CAD in patients evaluated for the first time because of chest pain.

Methods and results. Sixty patients underwent EST, DIP-ECHO, DOB-ECHO, DIP-MIBI, and DOB-MIBI. Echocardiographic images were acquired simultaneously with sestamibi injections, and the scintigraphic images were collected 1 hour later. Coronary angiography was performed within 15 days. Out of 33 patients with significant (>70%) coronary stenoses, 19 (58%) were correctly identified by EST, 18 (55%) by DIP-ECHO, 20 (61%) by DOB-ECHO, 32 (97%) by DIP-MIBI, and 30 (91%) by DOB-MIBI ($p < 0.005$ for MIBI vs EST and ECHO). The specificity of EST was 67% ($p < 0.05$ vs ECHO and MIBI), 96%, 96%, 89%, and 81%, respectively. Of the 62 stenotic coronary arteries, 20 (32%) were correctly identified by DIP-ECHO, 24 (39%) by DOB-ECHO, 48 (77%) by DIP-MIBI, and 45 (73%) by DOB-MIBI. The sensitivity of the imaging techniques in predicting the presence of multivessel disease was 14% and 29% for DIP and DOB-ECHO compared with 48% and 57% for DIP and DOB-MIBI.

Conclusions. Our results confirm the limited reliability of EST in detecting CAD and the good diagnostic value of DIP and DOB-MIBI. Conversely, the lower sensitivity and the poorer capability to recognize multivessel CAD do not support the role of either DIP or DOB-ECHO as first-line examination for suspected CAD. (J Nucl Cardiol 1998;5:19-27.)

Key words: exercise stress testing • stress echocardiography • SPECT • coronary artery disease

Pharmacologic stress testing is usually associated with imaging techniques. Both echocardiography and perfusion scintigraphy with thallium-201 have been performed in conjunction with dipyridamole or dobutamine

infusion and have been shown to be reliable for detecting coronary artery disease (CAD).¹⁻¹⁸ More recently technetium 99m-labeled perfusion agents such as technetium 99m sestamibi have been introduced.^{19,20} Because of the absence of significant redistribution, technetium 99m sestamibi may be injected during stress echocardiography, and the scintigraphy acquisition may be delayed. Therefore it is possible to compare directly the results of echocardiography and perfusion scintigraphy in combination with a single stress test.

So far, the diagnostic accuracy of stress echocardiography and stress scintigraphy has been mainly evaluated in patient populations with high pretest probability of disease or with known CAD. Only limited data

From the Division of Cardiology, Careggi Hospital, Florence, and the Nuclear Medicine Unit, Department of Clinical Pathophysiology, University of Florence.

Received for publication May 27, 1997; revision accepted Sept. 3, 1997.

Reprint requests: Giovanni Maria Santoro, MD, FESC, Division of Cardiology, Careggi Hospital, Viale Morgagni 85, 50134 Firenze, Italy; carddept@tin.it.

Copyright © 1998 by American Society of Nuclear Cardiology.
1071-3581/98/\$5.00 + 0 43/1/85833

concerning the reliability of these tests in an unselected population of patients without a history of CAD who seek medical counseling for the first time because of chest pain are available.²¹⁻²³ It is still uncertain what the relative value of these tests is as a possible first-line examination for suspected CAD.

We therefore prospectively performed a head-to-head comparison of the diagnostic accuracy of exercise stress testing (EST), dipyridamole and dobutamine echocardiography (DIP-ECHO, DOB-ECHO), and dipyridamole and dobutamine technetium 99m sestamibi tomography (DIP-MIBI, DOB-MIBI) in a group of patients who were examined for the first time because of chest pain and who had no history of previous clinical manifestations of CAD.

METHODS

Patient Population

Among the patients referred to the Division of Cardiology of Careggi Hospital for evaluation of chest pain of suspected coronary cause, 60 patients were prospectively enrolled for the study. Chest pain was typical for angina pectoris in 10 (17%) patients and atypical in 50. Patients with documented CAD, known angina pectoris, previous myocardial infarction, or other cardiac disease including rhythm disturbances, valvular heart disease, and cardiomyopathy were excluded; patients with abnormal baseline electrocardiograms (such as those with nonisoelectric rest ST segment), abnormal baseline echocardiograms (such as those with left ventricular hypertrophy or segmental wall motion abnormalities), inability to exercise adequately, contraindications to exercise or dipyridamole or dobutamine administration, and poor acoustic window were also excluded.

The pretest likelihood of CAD, expressed as mean \pm standard error of percentage, was calculated with the use of probability analysis based on age, sex, and symptoms.²⁴ Thirty-two patients had intermediate (20% to 80%) pretest probability, whereas 18 had low (<20%) and 10 had high (>80%) pretest probability of CAD.

Study Protocol

All patients underwent EST, DIP-ECHO and DOB-ECHO, DIP-MIBI and DOB-MIBI, resting technetium 99m sestamibi tomography, and coronary angiography. EST was usually the first test performed. Dipyridamole and dobutamine stresses were performed in random order on the following 2 days. Echocardiographic images were continuously acquired throughout the test. The images at peak stress were acquired simultaneously with technetium 99m sestamibi injection, and the scintigraphic images were collected approximately 1 hour later. On the fourth day resting technetium 99m sestamibi tomography was performed. Coronary angiography was performed according to the study protocol within 15 days of exercise testing. At the time of the entry in the study no patient was receiving cardioactive drugs or drugs containing xanthine.

The clinical conditions of all patients remained stable for the whole study.

The study protocol was approved by the local Ethics Committee on Human Research. All patients gave informed consent to participate in the study.

Exercise Stress Testing

All patients underwent a symptom-limited upright bicycle exercise test with a stepwise increment of 30 W every 3 minutes. Twelve-lead electrocardiography and arterial blood pressure were continuously monitored and recorded at baseline and at 1-minute intervals during exercise and recovery. The ST segment level was calculated by averaging the signal with a computer-assisted system (Marquette Case 21) and was visually reviewed by an experienced observer. End points of the test were severe chest pain, ischemic ST-depression (horizontal or downsloping ST segment ≥ 0.1 mV at 80 msec after the J point), fatigue, hypertensive response (systolic blood pressure of >230 mm Hg, diastolic blood pressure >120 mm Hg), hypotension (pressure drop >20 mm Hg), or maximal predicted heart rate in the absence of other criteria for interrupting the test. An ischemic response was defined as a 0.1 mV horizontal or downsloping ST segment depression persisting 80 msec after the J point. The presence and nature of limiting symptoms were recorded.

Dipyridamole Test

Patients were instructed to avoid beverages containing xanthine for at least 12 hours before the test. Dipyridamole was infused in a dose of 0.56 mg/kg over a 4-minute period followed by a 4-minute interval and then by a second dose of 0.28 mg/kg over a 2-minute period. Thus the cumulative dose was 0.84 mg/kg over a 10-minute period. Infusion was interrupted at achievement of peak dose, at onset of ischemia (indicated by chest pain associated with horizontal or downsloping ST segment depression 0.1 mV at 80 msec after the J point or development of wall motion abnormalities), or at the occurrence of remarkable side effects (dyspnea, ventricular arrhythmias, systolic blood pressure drop >20 mm Hg). Twelve-lead electrocardiography and arterial blood pressure were recorded at baseline and at 1-minute intervals during the infusion and in the 10 minutes after the end of dipyridamole administration. Echocardiography was performed at baseline and continuously throughout drug infusion and up to 8 minutes after the end of dipyridamole administration. Technetium 99m sestamibi (740 MBq, 20 mCi) was injected 2 minutes after the completion of the second dose or earlier if ischemia or side effects requiring the early termination of the test occurred. Aminophylline (120 mg) was routinely administered intravenously at least 8 minutes after tracer injection.

Dobutamine Test

Dobutamine was infused intravenously with a mechanical pump at incremental doses of 10, 20, 30, and 40 μ g/kg/min every 3 minutes; the maximal rate (40 μ g/kg/min) was maintained for 5 minutes. End points of the test were the achieve-

ment of the peak dose, the development of ischemia (as previously defined for the dipyridamole test), or the occurrence of severe side effects (dyspnea, supraventricular or ventricular arrhythmias, systolic blood pressure >230 mm Hg or diastolic >120 mm Hg, systolic blood pressure drop >20 mm Hg). Atropine (0.5 to 1 mg intravenously) was injected in patients in whom at 40 $\mu\text{m}/\text{kg}/\text{min}$ the heart rate was persistently <85% of the age-predicted maximal value. Twelve-lead electrocardiography and arterial blood pressure were recorded before the infusion was started and at 1-minute intervals throughout the dobutamine administration and until the heart rate returned to <100 beats/min. Echocardiography was performed at baseline and continuously throughout drug infusion and until the heart rate returned to <100 beats/min. Technetium 99m sestamibi (740 MBq, 20 mCi) was injected after 1 minute of the predetermined maximal infusion rate, and the drug infusion was subsequently continued for 5 minutes. The tracer injection took place earlier in case of the occurrence of one of the criteria requiring the premature termination of the test. When atropine was used, technetium 99m sestamibi was injected after 3 minutes. Atenolol (up to 2.5 mg in 5 ml) was available to treat side effects, but in no case was the drug used before 8 minutes after tracer injection.

Two-dimensional Echocardiography

Commercially available equipment (Aloka SSD 870; 2.5 to 3.5 MHz transducers) was used. The images were recorded on VHS videotape. In the baseline and stress studies parasternal long- and short-axis and apical four- and two-chamber views were obtained. The videotapes were independently analyzed by two experienced cardiologists; only the one who performed the test had knowledge of the clinical data and of the electrocardiographic response. Both were blind to the angiographic results. In case of disagreement the tape was reviewed, and the final decision was reached by consensus. The left ventricle was divided into 16 segments (at basal and mid-ventricular levels: anterior septal, anterior, lateral, posterolateral, inferior, posterior septal; at apical level: septal, anterior, lateral, inferior). Normal response to stress was defined as the preservation of the normal wall motion pattern present at rest or the development of homogeneous hyperkinesia. The response to stress was considered abnormal when segmental deterioration of thickening or wall motion (hypokinesia: reduced thickening and wall motion; akinesia: near or total absence of thickening and wall motion; dyskinesia: endocardial excursion away from the lumen and systolic thinning) developed. The criteria proposed by Marwick et al.²³ were used to identify the coronary vessels involved.

Technetium 99m Sestamibi Tomography

Tomography was collected 60 minutes after technetium 99m sestamibi injection. An Elscint Apex SP4 gamma camera equipped with an ultrahigh resolution collimator with a 20% window centered at the 140 keV photopeak of technetium 99m was used. Sixty projections of 20 seconds each were acquired in step and shoot mode over a 180-degree arc on 64 \times 64 matrixes with a zooming factor of 1.4. The image reconstruc-

tion was performed with filtered back-projection with a Wiener resolution recovery filter. No attenuation or scatter correction was used. The transaxial slices were realigned along the heart axis, and short-axis, vertical, and horizontal long-axis slices were obtained. Each patient study was submitted for evaluation to two independent and experienced observers who were unaware of any patient data and of the image acquisition parameters. Tracer uptake was evaluated with a 4-point scoring scheme (from 0 = normal uptake through 3 = absent uptake) after the left ventricular wall was divided into 20 segments, which were assigned to the three coronary territories as already described.^{19,25} An uptake score ≥ 2 in at least two segments in the baseline single photon emission computed tomography was considered indicative of necrosis in that territory.²⁵ The increase of the stress uptake score in at least two segments compared with the baseline value was regarded as the sign of stress-induced hypoperfusion.²⁵ In case of disagreement the data were reviewed, and consensus agreement was reached.

Coronary Angiography

Selective coronary angiography was performed in multiple views with Judkins or Sones techniques. The degree of lumen narrowing was visually estimated with the aid of calipers. Stenoses were graded as follows: not significant (<70%), moderate (70% to 89%), and severe (>90%). Multivessel CAD was recognized when at least two main coronary arteries (or their primary branches) were affected by significant stenosis. Left main CAD was considered equivalent to two-vessel disease with left anterior descending and left circumflex artery involvement. The angiographic score according to Gensini et al.²⁶ was calculated for each patient with at least one significant stenosis of any of the three main coronary arteries or of their primary branches.

Statistical Analysis

Continuous variables were expressed as mean value \pm SD and were compared with the use of analysis of variance for repeated measures with the Tukey test for post hoc comparison. Discrete variables were compared with the chi-squared or the Fisher exact test depending on sample size. The agreement among the different tests was assessed with the kappa statistic and its standard error. The sensitivity, specificity, and positive and negative predictive values were calculated in the usual fashion. A *p* value < 0.05 was considered significant.

RESULTS

Coronary Angiographic Findings

Thirty-three (55%) patients had significant CAD: 12 (36%) single-vessel disease, 13 (40%) two-vessel disease, and 8 (24%) three-vessel disease. Two patients had left main CAD. Twenty-one stenoses involved the left anterior descending artery or its major branches, 16 the left circumflex or marginal branches, and 25 the right coronary artery. Stenoses were classified as moderate in

Table 1. Hemodynamic responses to exercise, dipyridamole, and dobutamine stress

	Exercise	Dipyridamole	Dobutamine
Resting heart rate (beats/min)	71 ± 10	70 ± 9	69 ± 11
Peak heart rate (beats/min)	135 ± 21*	90 ± 12†	133 ± 18
Resting SBP (mm Hg)	141 ± 21	145 ± 21	143 ± 19
Peak SBP (mm Hg)	197 ± 22‡	132 ± 15†	150 ± 19
Resting RPP (×10 ³)	10 ± 2.4	10.1 ± 2.4	10.3 ± 2.5
Peak RPP (×10 ³)	26.6 ± 5.4‡	11.8 ± 2.2†	19.8 ± 3.4

Data are expressed as mean ± SD.
SBP, systolic blood pressure; RPP, heart-rate × pressure product.
**p* < 0.0005 vs dipyridamole.
†*p* < 0.0005 vs dobutamine.
‡*p* < 0.0005 vs dipyridamole and dobutamine.

23 cases and severe in 39. At least one severe stenosis was observed in 16 patients. Twenty-seven patients had no significant coronary stenosis.

Exercise and Pharmacologic Stress Hemodynamics and Safety

The hemodynamic responses to exercise stress test and dipyridamole and dobutamine infusions are summarized in Table 1. The peak rate-pressure product was significantly higher during exercise than during dipyridamole or dobutamine testing; the difference between dipyridamole and dobutamine was statistically significant as well. Anginal chest pain occurred in 43% of patients during the exercise stress test, in 25% during dipyridamole infusion, and in 35% during dobutamine infusion (none significant). ST segment depression ≥0.1 mV was recorded in 47%, 25%, and 17% of patients during exercise, dipyridamole, and dobutamine testing, respectively. In three patients dipyridamole infusion had to be terminated prematurely because of severe ischemia. No major adverse effects were recorded. Dobutamine administration was terminated before peak dose in eight patients because of frequent ventricular ectopic beats (two cases), ventricular tachycardia (one case), vomiting and hypotension (one case), or achievement of the maximal heart rate (four cases). In 22 patients atropine was injected at dobutamine peak dose to increase heart rate; despite atropine, 5 patients did not achieve a heart rate >85% of the maximal age-predicted value.

Reproducibility of Imaging Techniques

The echocardiographic and scintigraphic images were of good quality and could be analyzed in all patients. When echocardiographic stress examinations were reviewed, there was complete agreement between the two observers in 110 (92%) of 120 tests, whereas in the remaining 10 studies a consensus was reached. Intraobserver variability was assessed by one reader; 95% of the tests were reproducibly interpreted. Similarly, interobserver and intraobserver variability was assessed for technetium 99m sestamibi tomography. The two observers agreed in evaluating 94% of the tests. Intraobserver agreement, evaluated by one reader, was 95%.

Detection of Coronary Artery Disease

Ischemic ST segment changes during EST occurred in 28 patients (19 with CAD and 9 without CAD). An abnormal response during DIP-ECHO was detected in 19 cases (hypokinesia in 6, akinesia in 13); of these, 18 had CAD on coronary angiography. DOB-ECHO recognized an abnormal response in 21 patients (hypokinesia in 7, akinesia in 13, dyskinesia in 1); of these, 20 had CAD. Reversible perfusion defects were observed in 35 patients with DIP-MIBI; 32 had CAD and 3 no significant coronary stenosis. Finally, 35 patients (30 with and 5 without CAD) showed reversible perfusion defects in DOB-MIBI. Sensitivity, specificity, and overall accuracy of the five diagnostic methods are reported in Table 2. The sensitivities of EST, DIP-ECHO, and DOB-ECHO were all significantly lower than those of perfusion imaging. The specificity of EST was lower than that of the other methods with the exclusion of DOB-MIBI. The overall accuracy of EST, DIP-ECHO, and DOB-ECHO was similar and significantly lower than that obtained with dipyridamole tomography; the accuracy of EST was also significantly lower than that of DOB-MIBI.

Taking into account that dobutamine and dipyridamole are the two most commonly used pharmacologic stressors, respectively, in combination with echocardiography and perfusion tomography, we also evaluated the agreement between DOB-ECHO and DIP-MIBI in the detection of CAD, which resulted in being only fair, with a *k* value of 0.43 ± 0.11.

Influence of the Extent of Coronary Artery Disease

Figure 1 shows the sensitivity of the five tests in patients with one-vessel CAD versus that in patients with multivessel CAD. The sensitivity of each stress test in patients with multivessel disease exceeded its performance in single-vessel disease, even though these differences did not reach statistical significance.

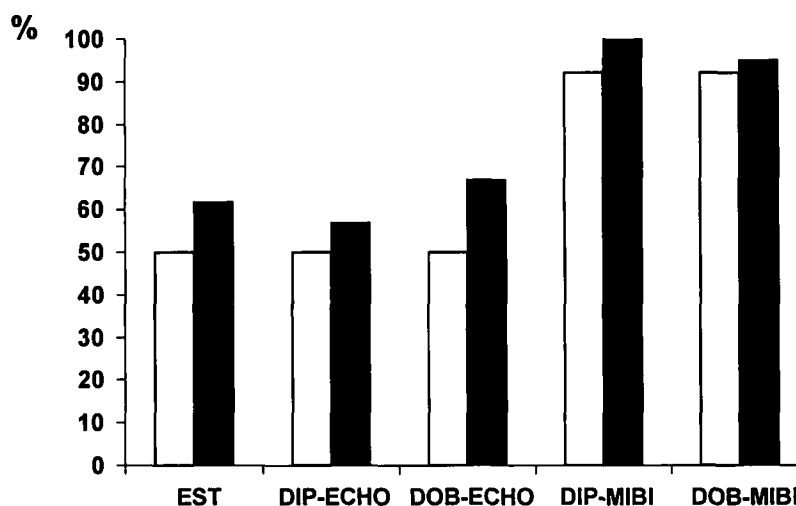


Figure 1. Sensitivity of exercise electrocardiography and imaging techniques for diagnosis of coronary artery disease in patients with single-vessel (*open bars*) and multivessel (*solid bars*) disease. *EST*, Exercise stress testing; *DIP-ECHO*, dipyridamole echocardiography; *DOB-ECHO*, dobutamine echocardiography; *DIP-MIBI*, dipyridamole technetium 99m tomography; *DOB-MIBI*, dobutamine technetium 99m tomography.

Table 2. Results of the diagnostic tests

	Sensitivity			Specificity			Overall accuracy		
	No points	%	CI	No points	%	CI	No points	%	CI
EST	19/33	58	40-75	18/27	67	49-85	37/60	62	49-85
DIP-ECHO	18/33	55	38-72	26/27	96§	88-100	44/60	73	62-84
DOB-ECHO	20/33	61	44-79	26/27	96§	88-100	46/60	77	66-88
DIP-MIBI	32/33	97*†‡	91-100	24/27	89	77-100	56/60	93*¶°	86-100
DOB-MIBI	30/33	91*†‡	81-100	22/27	81	66-96	52/60	87*	78-96

CI, 95% Confidence intervals.

* $p < 0.005$ vs EST.

† $p < 0.005$ vs DIP-ECHO.

‡ $p < 0.005$ vs DOB-ECHO.

§ $p < 0.01$ vs EST.

|| $p = 0.05$ vs EST.

¶ $p < 0.03$ vs DOB-ECHO.

° $p < 0.01$ vs DIP-ECHO.

Regarding the influence of stenosis severity, no significant difference in sensitivity was observed with any of the five diagnostic methods when the patients with at least one severe stenosis were compared with the other subjects. The trend to higher sensitivity observed with all methods appeared more marked for DIP-ECHO (69% in patients with severe stenosis vs 41% in those without) (Figure 2).

Taking into account the CAD extent score, a higher value was observed in the patients with a true-positive response to DIP-ECHO than in those with a false-negative test (21.8 vs 16.2, $p = 0.16$, not significant) and

in the true-positive cases of DOB-ECHO compared with the false-negative responders (23 vs 13.4, $p < 0.03$).

A separate aspect relates to the ability of each stress-imaging combination to predict the presence of multivessel disease as such (by the presence of wall motion or perfusion defects in more than one coronary territory). In this respect DIP-ECHO and DOB-ECHO were less sensitive, predicting 14% and 29% of patients with multivessel disease, respectively, compared with 48% predicted by DOB-MIBI ($p < 0.03$ vs DIP-ECHO) and 57% with DIP-MIBI ($p < 0.01$ vs DIP-ECHO). Specificity was 100% for DIP-ECHO and DOB-ECHO

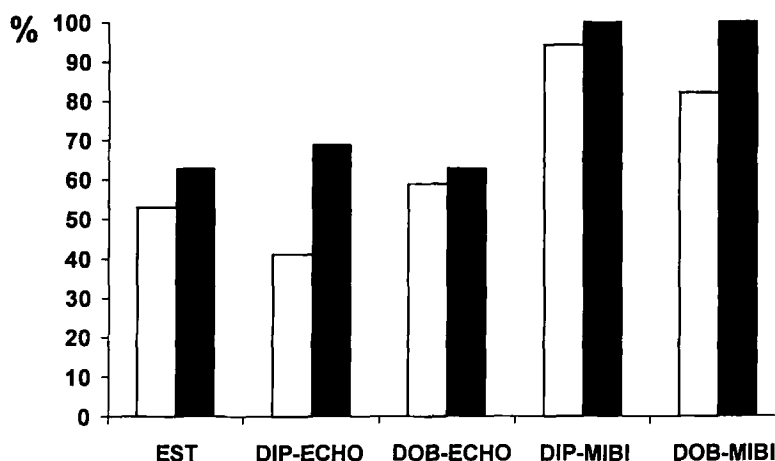


Figure 2. Sensitivity of exercise electrocardiography and imaging techniques for diagnosis of coronary artery disease in patient with (closed bars) or without (open bars) at least one coronary stenosis >90%. Abbreviations as in Figure 1.

Table 3. Sensitivity of the imaging tests in the detection of individual vessel involvement

	LAD (n = 21) (%)	LCX (n = 16) (%)	RCA (n = 25) (%)
DIP-ECHO	24	25	44
DOB-ECHO	33	31	48
DIP-MIBI	76*	69‡	84¶
DOB-MIBI	71†	63§	80†

LAD, Left anterior descending artery; LCX, left circumflex artery; RCA, right coronary artery.

* $p < 0.01$ vs ECHO.

† $p < 0.03$ vs ECHO.

‡ $p < 0.05$ vs ECHO.

§ $p < 0.05$ vs DIP-ECHO.

¶ $p < 0.02$ vs ECHO.

and for DIP-MIBI and 92% for DOB-MIBI (all not significant).

Of the 62 stenotic coronary arteries, 20 (32%) were correctly identified by DIP-ECHO, 24 (39%) by DOB-ECHO, 48 (77%) by DIP-MIBI ($p < 0.00001$ vs echocardiography), and 45 (73%) by DOB-MIBI ($p < 0.0005$ vs echocardiography). Table 3 depicts the sensitivity of the four imaging methods in the detection of the individual vessel involvement.

DISCUSSION

Our results confirm the limited reliability of EST in detecting patients with CAD, with sensitivity and specificity values in the range of previous studies.²⁷

According to other studies^{1-5,8-12,28} DIP-ECHO had a sensitivity similar to that of EST and a significantly

higher specificity. The sensitivity of DIP-MIBI was significantly higher than that of DIP-ECHO, whereas the specificity was identical. The flow heterogeneity produced by dipyridamole does not necessarily imply ischemia in the territories with hypoperfusion. Thus, in accordance with the experimental data by Fung et al.²⁹ and with the results of other clinical studies,^{30,31} the sensitivity of perfusion imaging was significantly higher than that of echocardiography.

DOB-ECHO had a sensitivity and a specificity similar to those of DIP-ECHO; specificity was significantly better compared with that of EST. The sensitivity of DOB-MIBI was significantly higher than that of DOB-ECHO, whereas the specificity of tomography was not significantly lower. No significant difference in sensitivity and specificity was observed between dipyridamole and dobutamine perfusion imaging.

In previous studies the reported sensitivity of DOB-ECHO was higher than that in our study,^{6-12,21-22,32-38} although an overlap of the confidence intervals can be observed. This result may be explained by the different patient selection criteria. Several studies included patients with ascertained angina or previous myocardial infarction or patients who had undergone previous coronary surgery.^{9,11,34,36,38} Even studies excluding patients with previous myocardial infarction had patient populations that were only apparently similar to ours; only patients referred for cardiac catheterization were included.^{22,23,34} Typical angina was present in 65% to 77% of cases,^{23,34} and up to 85% of the patients had been receiving antianginal therapy.²² In our study patients referred for first-line evaluation of chest pain were enrolled; typical angina was present in only 17% of cases, and no patient had had previous antianginal therapy. In other studies not all the patients underwent

coronary angiography⁶; therefore a postreferral bias may have been introduced.

In previous comparative studies the sensitivity of DOB-ECHO and perfusion tomography was found to be similar, or only a slightly higher sensitivity of perfusion imaging was reported.^{21-23,32-35} Our data suggest that perfusion heterogeneity and ischemia may be dissociated in a significant proportion of patients who undergo dobutamine stress testing. This phenomenon occurred in 30% of our patients. Recently Elhendy et al.³⁷ reported dobutamine-induced hypoperfusion detected by technetium 99m sestamibi tomography without transient wall motion abnormalities at echocardiography in 26% of patients. The reduced sensitivity of echocardiography compared with that of perfusion imaging has been related to a submaximal dobutamine stress test response³⁷ and milder CAD.²³ In our study a high dose of dobutamine combined with additional atropine was used to achieve heart rate >85% of the age-predicted maximal value; nevertheless, five patients (all with CAD) could not reach the target heart rate. Three of these five patients had a false-negative DOB-ECHO response, whereas all had a true-positive dobutamine tomography response. CAD extent and severity have been reported to influence the results of DOB-ECHO.²³ This relation has also been described with exercise echocardiography.³⁹ In our study the sensitivity of DOB-ECHO increased in patients with multivessel disease. False-negative DOB-ECHO results correlated with a significantly lower CAD extent score compared with patients with true-positive tests.

Compared with EST, noninvasive imaging techniques might offer information to predict disease extent and severity as well. DIP-MIBI and DOB-MIBI were superior to the echocardiographic tests in detecting the extent of CAD in terms of one-vessel or multivessel involvement, although statistical significance was not reached when compared with DOB-ECHO. Dipyridamole and dobutamine infusions were stopped at the first development of wall motion abnormalities; in this setting perfusion scintigraphy may have an advantage, because flow distribution heterogeneity may precede the development of wall motion abnormalities. Both scintigraphic techniques were superior for the correct identification of stenotic coronary arteries without a significant difference in the involved territories.

Study Limitations

The number of patients studied was relatively small. Stress echocardiography and scintigraphy were used as routine diagnostic tools and not for research purposes; therefore qualitative evaluation of echocardiographic and scintigraphic images was used. The lack of quantitative analysis and, for DOB-ECHO, of a computer-assisted

analysis on a quad screen format could have affected the results. However, qualitative evaluation of echocardiography and perfusion scintigraphy is still the routinely used method in most clinical laboratories. Regarding the second problem, because of the limited availability of this technical adjunct, the trend to consider a quad screen digital display as mandatory for DOB-ECHO would heavily limit the use of this imaging technique in clinical practice, particularly in community hospitals, where first-line evaluation of suspect chest pain is frequently performed. The degree of coronary artery stenosis was based on a visual estimate. Although this is still the method that is routinely used, its limitations are well known. Exercise stress perfusion tomography was not included in our protocol. It is clear that exercise stress is advantageous because it allows us to examine the functional response to physical activity. However, in patients who are still not recognized as affected by CAD, the importance of this information is poorly defined. Finally, prognostic information was not considered. The study evaluates only the diagnostic application of the tests; however, their relative prognostic strengths may be different.

Clinical Implications

Noninvasive diagnostic techniques have large application as screening tests in patients with chest pain. The features of the ideal test should be limited cost, wide availability, and accuracy. EST is inexpensive and physiologic, but, as confirmed by our results, it has low diagnostic accuracy, and its application in a population with generally low to intermediate pretest probability of disease is problematic. The diagnostic accuracy of stress echocardiography and stress scintigraphy is higher, but only the former approach has the cost and availability features required for a first-line examination. Unfortunately, our data suggest that independent of the pharmacologic agent adopted, echocardiography achieves a rather modest sensitivity, although its specificity is high. Therefore wide use of pharmacologic stress echocardiography as first-line examination in patients without a history of CAD but with suspect chest pain could be hazardous. Conversely, perfusion imaging is confirmed as highly effective for making the diagnosis of CAD and even for obtaining a reliable evaluation of disease extent. However, availability and economic problems remain major obstacles to its general use.

References

1. Picano E, Distanti A, Masini M, Morales MA, Lattanzi F, L'Abbate A. Dipyridamole-echocardiography test in effort angina pectoris. *Am J Cardiol* 1985;56:452-6.

2. Picano E, Simonetti I, Masini M, et al. Transient myocardial dysfunction during pharmacologic vasodilatation as an index of reduced coronary reserve: a coronary hemodynamic and echocardiographic study. *J Am Coll Cardiol* 1986;8:84-90.
3. Cohen JL, Greene TO, Alston JR, Wilchfort SD, Kim CS. Usefulness of oral dipyridamole digital echocardiography for detecting coronary artery disease. *Am J Cardiol* 1989;64:385-6.
4. Mazeika P, Nihoyannopoulos P, Joshi J, Oakley CM. Uses and limitations of high-dose dipyridamole stress echocardiography for evaluation of coronary artery disease. *Br Heart J* 1992;67:144-9.
5. Margonato A, Chierchia S, Cianflone D, et al. Limitations of dipyridamole-echocardiography in effort angina pectoris. *Am J Cardiol* 1987;59:225-31.
6. Sawada SG, Segar DS, Ryan T, et al. Echocardiographic detection of coronary artery disease during dobutamine infusion. *Circulation* 1991;83:1601-14.
7. Marcovitz PA, Armstrong WF. Accuracy of dobutamine stress echocardiography in detecting coronary artery disease. *Am J Cardiol* 1992;69:1269-73.
8. Previtalli M, Lanzarini L, Ferrario M, Tortorici M, Mussini A, Montemartini C. Dobutamine versus dipyridamole echocardiography in coronary artery disease. *Circulation* 1991;83(suppl III):27-31.
9. Salustri A, Fioretti PM, McNeill AJ, Pozzoli MMA, Roelandt JRTC. Pharmacological stress echocardiography in the diagnosis of coronary artery disease and myocardial ischaemia: a comparison between dobutamine and dipyridamole. *Eur Heart J* 1992;13:1356-62.
10. Martin TW, Seaworth JF, Johns JP, Pupa LE, Condos WR. Comparison of adenosine, dipyridamole and dobutamine in stress echocardiography. *Ann Intern Med* 1992;116:190-6.
11. Beleslin BD, Ostojic M, Stepanovic J, et al. Stress echocardiography in the detection of myocardial ischemia. Head-to-head comparison of exercise, dobutamine and dipyridamole tests. *Circulation* 1994;90:1168-76.
12. Dagianti A, Penco M, Agati L, et al. Stress echocardiography: comparison of exercise, dipyridamole and dobutamine in detecting and predicting the extent of coronary artery disease. *J Am Coll Cardiol* 1995;26:18-25.
13. Leppo J, Boucher CA, Okada RD, Newell JB, Strauss HW, Pohost GM. Serial thallium-201 myocardial imaging after dipyridamole infusion: diagnostic utility in detecting coronary stenoses and relationship to regional wall motion. *Circulation* 1982;66:649-57.
14. Ruddy TD, Dighero HR, Newell JB, et al. Quantitative analysis of dipyridamole-thallium images for the detection of coronary artery disease. *J Am Coll Cardiol* 1987;10:142-9.
15. Kong BA, Shaw L, Miller DD, Chaitman BR. Comparison of accuracy for detecting coronary artery disease and side-effect profile of dipyridamole thallium-201 myocardial perfusion imaging in women versus men. *Am J Cardiol* 1992;70:168-73.
16. Mason JR, Palac RT, Freeman ML, et al. Thallium scintigraphy during dobutamine infusion: nonexercise-dependent screening test for coronary disease. *Am Heart J* 1984;107:481-5.
17. Pennell DJ, Underwood SR, Swanton RH, Walker JM, Ell PJ. Dobutamine thallium myocardial perfusion tomography. *J Am Coll Cardiol* 1991;18:1471-9.
18. Hays JT, Mahmariam JJ, Cochran AJ, Verani MS. Dobutamine thallium-201 tomography for evaluating patients with suspected coronary artery disease unable to undergo exercise or vasodilator pharmacologic stress test. *J Am Coll Cardiol* 1993;21:1583-90.
19. Kiat H, Maddahi J, Lynne TR, et al. Comparison of technetium 99 methoxyisobutylisonitride and thallium 201 for evaluation of coronary artery disease by planar and tomographic methods. *Am Heart J* 1989;117:1-11.
20. Iskandrian AS, Heo J, Hong B, Lyons E, Marsh S. Use of technetium 99m isonitride (RP-30A) in assessing left ventricular perfusion and function at rest and during exercise in coronary artery disease, and comparison with coronary arteriography and exercise thallium-201 SPECT imaging. *Am J Cardiol* 1989;64:270-5.
21. Hoffmann R, Lethen H, Kleinhaus E, et al. Comparative evaluation of bicycle and dobutamine stress echocardiography with perfusion scintigraphy and bicycle electrocardiogram for identification of coronary artery disease. *Am J Cardiol* 1993;72:555-9.
22. Marwick T, Willemart B, D'Hondt AM, et al. Selection of the optimal nonexercise stress for the evaluation of ischemic regional myocardial dysfunction and malperfusion. Comparison of dobutamine and adenosine using echocardiography and 99m Tc-MIBI single photon emission computed tomography. *Circulation* 1993;87:345-54.
23. Marwick T, D'Hondt AM, Baudhuin T, et al. Optimal use of dobutamine stress for the detection and evaluation of coronary artery disease: combination with echocardiography or scintigraphy, or both? *J Am Coll Cardiol* 1993;22:159-67.
24. Diamond GA, Forrester JS. Analysis of probability as an aid in the clinical diagnosis of coronary disease. *N Engl J Med* 1979;300:1350-8.
25. Bisi G, Sciagrà R, Santoro GM, Briganti V, Leoncini M, Fazzini PF. Evaluation of coronary artery disease extent using 99mTc-sestamibi: comparison of dipyridamole versus exercise and of planar versus tomographic imaging. *Nucl Med Commun* 1993;14:946-54.
26. Austen WG, Edwards JE, Frye RL, et al. A reporting system on patients evaluated for coronary artery disease: report of the Ad Hoc Committee for Grading of Coronary Artery Disease. Council on Cardiovascular Surgery, American Heart Association. *Circulation* 1975;51(suppl.51):5-40.
27. Froelicher VF. Use of the exercise electrocardiogram to identify latent coronary atherosclerotic heart disease. In: Amsterdam EA, Wilmore JH, DeMaria AN, editors. *Exercise in cardiovascular health and disease*. New York: York Medical Books; 1977. p. 189-208.
28. Verani MS. Myocardial perfusion imaging versus two-dimensional echocardiography: comparative value in the diagnosis of coronary artery disease. *J Nucl Cardiol* 1994;1:399-414.
29. Fung AJ, Gallagher KP, Buda A. The physiologic basis of dobutamine as compared with dipyridamole stress interventions in the assessment of critical coronary stenosis. *Circulation* 1987;76:943-51.
30. Nguyen T, Heo J, Ogilby JD, et al. Single-photon emission computed tomography with thallium-201 during adenosine-induced coronary hyperemia: correlation with coronary arteriography, exercise thallium imaging and two-dimensional echocardiography. *J Am Coll Cardiol* 1990;16:1375-83.
31. Amanullah AM, Bevegard S, Lindvall K, Aasa M. Assessment of left ventricular wall motion in angina pectoris by two-dimensional echocardiography and myocardial perfusion by technetium 99m sestamibi tomography during adenosine induced coronary vasodilatation and comparison with coronary angiography. *Am J Cardiol* 1993;72:983-9.
32. Geleijnse ML, Marwick TH, Boersma E, Deckers JW, Melin JA, Fioretti PM. Optimal pharmacological stress testing for the diagnosis of coronary artery disease: a probabilistic approach. *Eur Heart J* 1995;16(Suppl M):3-10.
33. Gunalp B, Dokumaci B, Uyan C, et al. Value of dobutamine

- technetium 99m-sestamibi SPECT and echocardiography in the detection of coronary artery disease compared with coronary angiography. *J Nucl Med* 1993;34:889-94.
34. Mairesse GH, Marwick TH, Vanoverschelde JJ, et al. How accurate is dobutamine stress electrocardiography for detection of coronary artery disease? Comparison with two-dimensional echocardiography and technetium 99m methoxy isobutyl isonitrile (Mibi) perfusion scintigraphy. *J Am Coll Cardiol* 1994;24:920-7.
 35. Kisacik HL, Ozdemir K, Altinyay, et al. Comparison of exercise stress testing with simultaneous dobutamine stress echocardiography and technetium 99m isonitrile single-photon emission computerized tomography for diagnosis of coronary artery disease. *Eur Heart J* 1996;17:113-9.
 36. Di Bello V, Bellina RC, Gori E, et al. Incremental diagnostic value of dobutamine stress echocardiography and dobutamine scintigraphy (technetium 99m-labeled sestamibi single-photon emission computed tomography) for assessment of presence and extent of coronary artery disease. *J Nucl Cardiol* 1996;3: 212-20.
 37. Elhendy A, Geleijnse ML, Roelandt JRTC, et al. Dobutamine-induced hypoperfusion without transient wall motion abnormalities: less severe ischemia or less severe stress? *J Am Coll Cardiol* 1996;27:323-9.
 38. Senior R, Sridara BS, Anagnostou E, Handler C, Raftery EB, Lahiri A. Synergistic value of simultaneous stress dobutamine sestamibi single-photon-emission computerized tomography and echocardiography in the detection of coronary artery disease. *Am Heart J* 1994;128:713-8.
 39. Armstrong WF, O'Donnel J, Ryan T, Feigenbaum H. Effect of prior myocardial infarction and extent and location of coronary disease on accuracy of exercise echocardiography. *J Am Coll Cardiol* 1987;10:531-8.