



UNIVERSITÀ
DEGLI STUDI
FIRENZE

FLORE

Repository istituzionale dell'Università degli Studi di Firenze

The inner diameter of human intracranial vertebral artery by color Doppler method.

Questa è la Versione finale referata (Post print/Accepted manuscript) della seguente pubblicazione:

Original Citation:

The inner diameter of human intracranial vertebral artery by color Doppler method / C.Macchi;F.Giannelli;F.Cecchi;M.Gulisano;P.Pacini;L.Corcos;C.Catini;E.Brizzi.. - In: ITALIAN JOURNAL OF ANATOMY AND EMBRYOLOGY. - ISSN 1122-6714. - STAMPA. - 101:(1996), pp. 81-87.

Availability:

This version is available at: 2158/681350 since:

Terms of use:

Open Access

La pubblicazione è resa disponibile sotto le norme e i termini della licenza di deposito, secondo quanto stabilito dalla Policy per l'accesso aperto dell'Università degli Studi di Firenze (<https://www.sba.unifi.it/upload/policy-oa-2016-1.pdf>)

Publisher copyright claim:

(Article begins on next page)

The inner diameter of human intracranial vertebral artery by color doppler method

Claudio Macchi */*** - Fabrizio Giannelli ** - Francesca Cecchi **
Massimo Gulisano * - Paolo Pacini * - Leonardo Corcos **
Claudio Catini and Enzo Brizzi*

* Department of Human Anatomy and Histology University of Florence, Italy

** Prosperius Institute, Florence, Italy

*** Fondazione Pro-Juventute Don C. Gnocchi, Pozzolatico, Florence, Italy

Key words: Vertebral Artery, Color doppler.

SUMMARY

In 50 healthy subjects the internal diameter of the intracranial vertebral artery were measured by echocolor doppler method. The diameter of left vertebral a. was greater than that of the right in most subjects (58%); the mean left/right difference was statistically significant ($p < 0,05$). Analyzing men and women separately, the difference remained significant only in women ($p < 0,05$). A significant correlation was found between vertebral a. diameter and sex ($p < 0,01$). The vertebral a. diameter had a tendency to increase with age, that reached significance only for the left vertebral one. No significant correlation was found between body surface area and vertebral a. diameter.

INTRODUCTION

The literature about the caliber of the vertebral arteries is mainly based on cadaveric studies. Although data are often discordant, many authors have reported greater caliber in the left compared to the right artery (Schellhas *et al.*, 1980; Gulisano *et al.*, 1982; Thiel *et al.*, 1991; Huang *et al.*, 1993; Mitchell and McKay, 1995).

Cadaveric studies have been shown to carry methodologic biases (Orlandini, 1968; Pacini, 1977). In fact, tissues undergo variable structural and morphological changes, partially depending on the absorption of fluids by the vessel wall, which causes a variation in the internal caliber of the arteries. Further, the determination

of the vessel caliber in the cadaver is indirect, requiring a transverse section of the artery and a measurement of its circumference.

Some recent reports suggest that Doppler ultrasonography studies in living subjects may at least partially overcome these drawbacks, measuring vessel caliber by a reproducible, non-invasive technique with an accuracy of tenths of millimeters (Hennerici and Neuerburg, 1991; Dautat *et al.*, 1986; Macchi *et al.*, 1994).

The issue of accurately determining vertebral caliber in the living subject has also important clinical implications: lower caliber is associated with a higher risk that compression and/or stretching of the artery, as it happens in cervical spine manipulations, may cause alterations in the blood flow (Bladin and Merory, 1975; Schellhas *et al.*, 1980; Thiel *et al.*, 1991). When the vertebral artery is hypoplastic, or simply small, extending the cervical spine to the extreme ranges of motion may compromise the blood flow through the vessel (Krueger and Okazaki, 1980; Ternan *et al.*, 1991; Frisoni and Anzola, 1991). A lower caliber is also associated with greater liability to alterations of the intima, and consequent thrombus formation in response to external mechanical stimuli (Beatty, 1977; Braun *et al.*, 1983; Frumkin and Baloh, 1990; Frisoni and Anzola, 1991). Many studies report that the area of the vertebral artery near the vertebrobasilar junction is that most often involved in thrombus formation as a consequence of vascular injury (Bladin and Merory, 1975; Okawara and Nybbeling, 1974; Schellhas *et al.*, 1980; Mas *et al.*, 1989; Frumkin and Baloh, 1990; Hinse *et al.*, 1991; Frisoni and Anzola, 1991). The measurement of the vertebral artery in this region in living subjects may allow identification of persons at risk of vertebrobasilar insufficiency, especially if submitted to mechanical stress such as in cervical spine manipulations. Precise determination of the physiological variations of vertebral artery caliber in normal subjects is preliminary to any clinical interpretation of caliber measurements.

The purpose of this study was to determine the caliber of the intracranial vertebral arteries in living healthy subjects. The calibers of the left and the right vertebral arteries were measured 1 cm before the vertebrobasilar junction using transcranial Color Doppler Ultrasonography. Mean left and right calibers have been compared and correlated with sex, age and body surface.

MATERIALS AND METHODS

We have examined 50 healthy subjects (25 men and 25 women; mean age: 43.7 ± 19.9 ; age range: 18 to 80 years). The subjects were selected from patients who had been referred to us with no history of hypertension or diabetes and were found free of vascular pathology. All the subjects gave their informed consent to participate in the research protocol.

Using transcranial Color doppler ultrasonography, the internal caliber of the intracranial vertebral arteries (1 cm before the vertebro-basilar junction) was measured. Ultrasonographic data have been correlated with sex, body surface, and

age, using the Correlation Coefficient; the mean values of vertebral caliber with regard to side (right vs left) have been compared using Student's "T" test.

A 2.0-MHz Acuson 128 Doppler ultrasound system was used to measure the arterial calibers.

RESULTS

The characteristics of the study population (sex, age, body surface, left and right vertebral artery caliber) are shown in *Table 1*. The mean left vertebral caliber was 1.72 for men and 1.85 for women. As to the right vertebral artery, mean caliber was 1.63 in men and 1.79 in women.

The caliber of the left vertebral artery was greater than that of the right in most subjects (58%) as shown in *Figure 1*; the mean left/right difference was statistically significant ($p < 0.05$). Analyzing men and women separately, the difference remained significant only in women ($p < 0.05$) (*Table 2*). A significant correlation was found between vertebral caliber (both for right and left vertebral artery) and sex ($p < 0.01$); vertebral caliber had a tendency to increase with age, that reached significance only for the left vertebral artery, but not for the right. No significant correlation was found between body surface and either left or right vertebral caliber in the sample as a whole and analyzing men and women separately ($p = ns$).

DISCUSSION

Although it is difficult to compare studies that apply different methods, our results are in accord with most reports in current literature (Schellhas *et al.*, 1980; Gulisano *et al.*, 1982; Thiel *et al.*, 1991; Mokri *et al.*, 1990; Macchi *et al.*, 1993; Huang *et al.*, 1993; Macchi *et al.*, 1995; Mitchell and McKay, 1995).

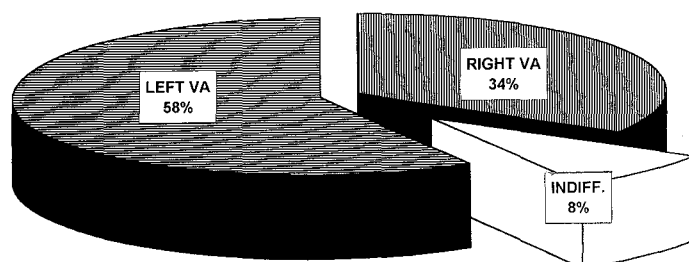


Fig. 1 — The intracranial vertebral a. calibre in all subjects; right and left VA = right and left Vertebral Artery; Indiff. = indifferent.

TABLE 1 — Total of cases: bsa = body surface area (m²); right and left v. = right and left intracranial vertebral artery (mm).

n°	sex	age	weight	height	bsa	right v.	left v.	n°	sex	age	weight	height	bsa	right v.	left v.
1	M	18	66,3	176	1,81	1,4	1,5	26	F	20	63	164	1,69	1,4	1,5
2	M	21	60	164	1,65	1,6	1,5	27	F	22	48	155	1,44	1,3	1,4
3	M	22	75,6	177	1,93	1,6	1,7	28	F	25	64,9	169	1,74	1,7	1,9
5	M	23	63,9	166	1,71	1,4	1,6	29	F	26	57,4	163	1,61	2	1,9
4	M	23	76	181	1,96	1,5	1,5	30	F	29	57	166	1,63	1,6	1,8
6	M	24	85	185	2,09	1,8	1,9	31	F	32	63	160	1,66	1,7	1,8
7	M	25	77,9	178	1,96	1,5	1,6	32	F	35	55,2	155	1,53	2	2
8	M	28	72,3	175	1,87	1,9	1,9	33	F	38	66,3	157	1,67	1,8	1,9
9	M	29	75	175	1,90	1,5	1,6	34	F	41	65	172	1,77	1,7	1,9
10	M	33	77	180	1,96	1,5	1,7	35	F	43	57,8	164	1,63	2,1	2,1
11	M	34	84	178	2,02	1,7	1,6	36	F	45	85	165	1,92	1,8	1,9
12	M	37	72,3	172	1,85	1,9	1,8	37	F	49	64	174	1,77	2	1,9
13	M	40	69,6	159	1,72	1,6	1,6	38	F	52	68,3	160	1,71	1,5	1,4
14	M	41	77	180	1,96	1,7	2	39	F	56	65,9	164	1,72	1,6	1,9
15	M	43	73	188	1,98	1,5	1,5	40	F	59	58	170	1,67	2,1	2
16	M	48	77,2	173	1,91	1,5	1,6	41	F	60	67,3	161	1,71	1,9	2
17	M	53	58,4	164	1,63	1,7	1,5	42	F	63	51	161	1,52	1,9	1,8
18	M	57	78,5	178	1,96	1,5	1,8	43	F	65	89,4	174	2,04	1,7	1,5
19	M	64	57	166	1,63	1,9	2	44	F	66	56	164	1,60	1,6	1,7
20	M	65	58,4	159	1,60	1,8	1,7	45	F	68	75,2	167	1,84	1,7	1,9
21	M	66	77	176	1,93	1,7	2	46	F	70	80	175	1,96	1,7	1,8
22	M	68	85	177	2,02	1,5	1,6	47	F	73	86,4	167	1,95	1,9	1,8
23	M	75	89,3	184	2,13	1,4	1,9	48	F	76	68,2	159	1,71	2	2,2
24	M	77	85,5	179	2,05	1,8	1,9	49	F	79	58	162	1,61	1,9	2
25	M	78	74,2	164	1,81	1,8	2	50	F	80	74,2	165	1,82	2,1	2,2
MEAN		43,68	73,82	174,16	1,88	1,63	1,72	MEAN		50,88	65,78	164,52	1,72	1,79	1,85
SD±		19,87	9,01	7,96	0,15	0,16	0,18	SD±		19,04	10,85	5,61	0,14	0,22	0,21

Measurement (mm)	Left (Mean ± S.D.)	Right (Mean ± S.D.)	Significance
Male	1,72 ± 0,18	1,63 ± 0,16	NS
Female	1,85 ± 0,21	1,79 ± 0,22	p<0,05

Earlier reports of mean caliber of the extracranial vertebral artery are extremely discordant. Vierordt (1906) and Versari (1932) have reported a mean diameter of 6.1 mm, Romiti (1890) of 4.5 mm. Cavatorti (1908) has reported that the mean caliber varied as much as 1 to 8 mm. For the intracranial vertebral artery a mean caliber of 1.74 mm has been reported by Mas et al (1989) and of 0.9 mm by Lang (1990); Mitchell and McKay have reported a mean internal caliber of the vertebral artery 1 cm before the vertebro-basilar junction of 2.04 for the left and of 2.03 for the right vertebral artery. Methodological differences may partially explain the discordance in cadaveric reports, such as different fixing and dissecting procedures, choice of including or excluding the tunica adventitia in the measurement; besides, and most important, choice of the anatomical region where to take the measurement

which influences the results obtained by whatever technique. In fact, results may be very different if one choose to average vertebral internal caliber taken at different levels from its origin, or to take the measurement at the point where the artery maintains an invariable caliber along the longest trajectory, as applied in other studies (Macchi *et al.*, 1993); we chose to measure the vertebral artery caliber 1 cm before the vertebrobasilar junction because this region has been shown to be particularly vulnerable to thrombus formation as a consequence of mechanical stress; a reduction of caliber in this area is then of particular clinical value in identifying subjects at higher risk of vertebrobasilar insufficiency.

The statistically significant difference between left and right vertebral artery only in the female group is in accord with our previous findings on the extracranial vertebral arteries (Macchi *et al.*, 1993, Macchi *et al.*, 1995), as well as with the works of Mas *et al.*, (1989), Mokri *et al.*, (1990) Hinse *et al.*, (1991) and with the recent report on intracranial vertebral diameters by Mitchell and McKay (1995), all with measures obtained from cadavers. The last Authors suggest that, because of these consistent findings, white females should be considered as a high risk group as regards vascular accidents following manipulations of the cervical spine, especially if the right vertebral artery is involved. The reproduction of their findings by a different method gives strong support to this hypothesis.

The significant difference in caliber for both left and right vertebral artery between men and women is also in accord with our previous findings on the extracranial vertebral arteries, obtained by MRI and Color Doppler (Macchi *et al.*, 1995), although a previous study on the branches of the aortic arch had failed to demonstrate a significant difference in extracranial vertebral caliber (Macchi *et al.*, 1993). Data from reports based on cadaver studies are also contradictory, and no agreement has yet been reached in this issue of both anatomical and clinical value (Schellhas *et al.*, 1980; Gulisano *et al.*, 1982; Thiel *et al.*, 1991; Mas *et al.*, 1989; Huang *et al.*, 1993; Mitchell and McKay, 1995).

The absence of correlation between vertebral caliber and body surface was expected, as no correlation had been found in a previous study between extracranial vertebral caliber and height, body weight or body index (Macchi *et al.*, 1993; Macchi *et al.*, 1995). On the opposite, the relationship between arterial caliber and age is a very controversial issue (Orlandini, 1970; Gulisano *et al.*, 1982; Macchi and Catini, 1994); in our findings, age has been found to be significantly associated with greater left, but not right, vertebral artery caliber. In a previous study on the extracranial vertebral arteries by MRI and Color Doppler, we did not find a significant correlation between vertebral caliber and age, although there was a tendency of the values to increase with age (Macchi *et al.*, 1995). Further research is needed to verify whether vessel caliber increases with age, as our results seem to suggest.

Our findings, obtained in the living subject by means of a reproducible, non-invasive, low-cost technique, suggest that the mean right and left vertebral artery caliber is smaller in women; women present also an asymmetry of caliber, with the

right vertebral artery being consistently smaller than the left; longitudinal prospective and retrospective clinical studies are needed to confirm the hypothesis that this anatomical characteristics are associated with increased risk of vertebrobasilar insufficiency, especially when the right vertebral artery is exposed to mechanical stress such as it may happen with cervical spine manipulations.

Arrived 5/3/96. Accepted 11/3/96.

REFERENCES

- Beatty RA. 1977. Dissecting hematoma of the internal carotid artery following chiropractic cervical manipulation. *J Trauma*, 17(3): 248-249.
- Bladin PF, Merory J. 1975. Mechanisms in cerebral lesions in trauma to high cervical portion of the vertebral artery - rotational injury. *Proc Aust Assoc Neurol*, 12: 35-41.
- Braun IF, Pinto RS, De Filippo GJ, Liebermann A, Pasternack P, Zimmermann RD. 1983. Brain stem infarction due to chiropractic manipulation of the cervical spine. *South Med J*, 76(9): 1199-1201.
- Cavatorti P. 1908. Il tipo normale e le variazioni delle arterie della base dell'encefalo. *Monit Zool ital*, 19: 248-258.
- Dauzat M, Laroche JP, De Bray JM, Juhel P, Becker F, Cesari JB, Jonnart L, Domergue A, Davauferrier L, Heyden D, Maugin D, Vongouthy S, Davinroy M. 1986. *Pratique de l'ultrasonographie vasculaire (Doppler echographie)*. Vigot, Paris.
- Frisoni GB, Anzola GP. 1991. Vertebrobasilar ischemia after neck motion. *Stroke*, 22(11): 1452-1460.
- Frumkin LR, Baloh RW. 1990. Wallemberg's syndrome following neck manipulation. *Neurology*, 40:611-615.
- Gulisano M, Zecchi S, Pacini P, Orlandini GE. 1982. The behaviour of some human arteries as regards the corrected circumference. A statistical research. *Anat Anz, Jena*, 152: 341-357.
- Hennerici M, Neuerberg HD. 1991. *Diagnostica vascolare con ultrasuoni*. Il Pensiero Scientifico Editore, Roma.
- Hinse P, Thie A, Lachemayer L. 1991. Dissection of the extracranial vertebral artery: report of four cases and review of the literature. *J Neurol Neurosurg Psychiatry*, 54 (863-869).
- Huang MH, Huang CC, Ryu SJ, Chu NS. 1993. Sudden bilateral hearing impairment in vertebrobasilar occlusive disease. *Stroke*, 24(1): 132-137.
- Krueger BR, Okazaki H. 1980. Vertebral-basilar distribution infarction following chiropractic cervical manipulation. *Mayo Clin Proc*, 55: 322-332.
- Lang J. 1990. About a very rare variation of the course and width of the vertebral arteries and the hypoglossal nerve. *Acta Neurochirur (Wien)*, 106(1-2): 73-77.
- Macchi C, Catini C, Gulisano M, Pacini P, Brizzi E, Bigazzi P. 1995. The anatomical variations of the human extracranial vertebral arteries: a statistical investigation of 90 living subjects using MRI and Color Doppler method. *It J Anat Embryol*, 100(1): 53-59.
- Macchi C, Giannelli F, Catini C. 1993. The measurement of the calibers of the branches of the aortic arch: a statistical investigation of 430 living subjects using ultrasonic tomography. *It J Anat Embryol*, 98(2): 69-79.
- Macchi C, Gulisano M, Giannelli F, Catini C, Pacini P, Brizzi E. 1994. The calibers of the common femoral, popliteal, and posterior tibialis arteries: a statistical investigation in 100 healthy subjects by Color Doppler ultrasonography. *It J Anat Embryol*, 99(3): 157-170.
- Mas JL, Henin D, Bousser MG, Chain F, Hauw JJ. 1989. Dissecting aneurysm of the vertebral artery and cervical manipulation: a case report with autopsy. *Neurology*, 39(4): 512-515.

- Mitchell J, McKay A. 1995. Comparison of left and right vertebral artery intracranial diameters. *The Anatomical Record*, 242: 350-354.
- Mokri B, Houser OW, Sandok BA, Piepgras DG. Spontaneous dissections of the vertebral arteries. *Neurology*, 38(6): 880-885.
- Okawara S, Nibbelink D. 1974. Vertebral artery occlusion following hyperextension and rotation of the head. *Stroke*, 5: 640-642.
- Orlandini GE. 1968. La circonferenza rettificata delle arterie coronarie. *Ricerca statistica su 200 casi umani. Mal Cardiovasc*, 9: 331-361.
- Orlandini GE. 1970. La circonferenza rettificata delle principali arterie della base dell'encefalo: ricerca statistica su 100 casi umani. *Arch Ital Anat Embriol*, 75: 49-79.
- Pacini P, Orlandini GE, Gulisano M. 1977. Sulla circonferenza rettificata delle arterie iliache nell'uomo. ricerca statistica su 100 casi. *Arch Ital Anat Embriol*, 82: 121-129.
- Romiti G. 1890. *Trattato di anatomia dell'uomo, I*, Vallardi, Milano, 803-928.
- Schellhas KP, Latchaw RE, Wendling RL, Gold LHA. 1980. Vertebrobasilar injuries following cervical manipulation. *JAMA*, 244(13): 1450-1453.
- Temam AJ, Winterkorn JS, Lowell DM, 1991. Traumatic thrombosis of a vertebral artery in a hypoplastic vertebro-basilar system: protective effect of collateral circulation. *NY State J Med*, 91(7): 314-315.
- Terret AG. 1987. Vascular accidents from cervical spine manipulation: report on 107 cases. *J Aust Chiropractor's Assoc*, 17(1): 15-24.
- Thiel W. 1991. Gross morphology and pathoanatomy of the vertebral arteries, *J Manipulative Physiol Ther*, 14(2): 133-141.
- Versari R. 1932. *Trattato di anatomia umana, II*. Vallardi, Milano, 393-398.
- Vierordt H. 1906. *Anatomische, physiologische, und physikalische Daten und Tabellen*. Fischer, Jena, 172-177.

Address for correspondence:

Dott. CLAUDIO MACCHI
Dip. Anatomia Umana Normale e Istologia,
Policlinico di Careggi,
50134 - Firenze, Italia