



UNIVERSITÀ
DEGLI STUDI
FIRENZE

FLORE

Repository istituzionale dell'Università degli Studi di Firenze

The anatomy and clinical importance of the collateral circle between the external carotid arteries through an anastomosis between the

Questa è la Versione finale referata (Post print/Accepted manuscript) della seguente pubblicazione:

Original Citation:

The anatomy and clinical importance of the collateral circle between the external carotid arteries through an anastomosis between the superior thyroid arteries / C.Macchi;C.Catini. - In: ITALIAN JOURNAL OF ANATOMY AND EMBRYOLOGY. - ISSN 1122-6714. - STAMPA. - 98:(1993), pp. 197-205.

Availability:

This version is available at: 2158/681365 since:

Terms of use:

Open Access

La pubblicazione è resa disponibile sotto le norme e i termini della licenza di deposito, secondo quanto stabilito dalla Policy per l'accesso aperto dell'Università degli Studi di Firenze (<https://www.sba.unifi.it/upload/policy-oa-2016-1.pdf>)

Publisher copyright claim:

(Article begins on next page)

University of Florence, Italy

* Institute of Gerontology and Geriatric Medicine

** Department of Human Anatomy and Histology

The Anatomy and Clinical Importance of the Collateral Circle between the External Carotid Arteries through an Anastomosis between the Superior Thyroid Arteries

Claudio Macchi * - Claudio Catini **

Key words: superior thyroid arteries, anastomosis, clinical importance

SUMMARY

Three cases of obstruction of a single common carotid artery were incidentally discovered by Doppler ultrasonography. Interestingly, antegrade blood flow was demonstrable in the ipsilateral internal carotid artery (ICA), even though it was distal to the obstruction. Antegrade blood flow was also observed in the intracranial portion of the internal carotid artery and in its branches that were explored (the ophthalmic and middle cerebral arteries).

The blood flow was comparatively reduced and irregular with respect to that of the corresponding contralateral artery, but nonetheless antegrade. Further studies by color Doppler ultrasound revealed the presence of a collateral circle that passed through the superior thyroid arteries. The prominent blood flow in the ICA ipsilateral to the occlusion originated from the ipsilateral external carotid artery (ECA). In turn, the ECA was supplied by the contralateral ECA through a collateral circle that made use of an anastomosis between the superior thyroid arteries.

In summary, the blood flow followed the following path: from the contralateral ECA and superior thyroid artery, through an anastomosis with the ipsilateral ECA. From this point, the blood flow reached the ipsilateral ICA. Blood flowed from the thyroid artery to the ipsilateral ECA, then flowed in a retrograde fashion toward the carotid bifurcation and toward the ICA, since this vascular territory offered lower resistance to flow as compared to that encountered in the distal ECA.

All three patients examined, a 58-year-old woman and 2 men of 52 and 64 years, had presented with neurological deficits that subsequently almost completely regressed. The regression of symptomatology indicates the clinical importance of the collateral circle and explains the absence of serious neurological deficits in certain patients affected by a pathologic process as serious as the occlusion of a common carotid artery.

INTRODUCTION

Our study was prompted by the observation of three patients who had been referred by their primary physicians for Doppler ultrasonography of the carotid and vertebral arteries. Occlusion of the common carotid artery was incidentally observed at its origin. Contrary to expectations, blood flow was demonstrable in the ipsilateral internal carotid artery (ICA) immediately distal to the bifurcation. This flow, which is normally directed toward the brain, was also detectable in the intracranial portion of the ipsilateral ICA and in its branches that we explored (ophthalmic and middle cerebral arteries). All these arteries, which were explored using Doppler and color Doppler techniques, were found to have anterograde blood flow, albeit reduced and irregular with respect to that of the corresponding arteries on the other side.

The aim of this study is to exactly define the anatomy of the carotid arteries of the three patients; to correlate the presence of blood flow within the ICA ipsilateral to the CCA occlusion to the presence of one or more collateral circles; to identify the collateral circles; and to define their clinical significance.

MATERIALS AND METHODS

Our subjects were a 58-year-old woman and 2 men of 52 and 64 years. They had been referred to us by their primary physicians for Doppler ultrasound of the carotid and vertebral arteries. The woman had first presented 20 years earlier with left-sided hemiparesis from which she had complete neurological recovery. The 52-year-old man had presented with transient right-sided amaurosis 7 days prior to our examination. The 64-year-old man had presented with transient global amnesia 15 days before our evaluation.

In all three cases, the Doppler examination that was performed initially had demonstrated the occlusion of one CCA at its origin. Subsequently, carotid, vertebral, and transcranial color Doppler ultrasound examination were performed in all three patients. These were followed by digital subtraction angiography of the supraaortic vessels.

The following equipment was used: a bidirectional, continuous wave Meda Sonics D9 Doppler ultrasound unit, an Acuson 128XP color Doppler system, and a Philips VDI 2 digital subtraction system.

RESULTS

The three subjects initially underwent Doppler ultrasonography of the carotid and vertebral arteries. The 58-year-old woman, who had presented with hemiparesis 20 years previously, had no elicitable residual neurological deficit at the time of our examination; she had been referred to us as a diagnostic curiosity. We discovered an occlusion of the right common carotid artery at its origin.

However, contrary to expectations, anterograde (though reduced and irregular

in comparison with the contralateral ICA) blood flow was detected. There was also a qualitatively and quantitatively normal flow of blood in the branches of the ophthalmic artery. In contrast, there was retrograde (that is, directed toward the carotid bifurcation) blood flow in the ipsilateral ECA, which was detectable only in the first half centimeter of the vessel (see *Fig. 1, Frame 1*).

These unexpected findings led us to perform further, diagnostic studies using carotid, vertebral, and transcranial color Doppler techniques. Examination of the carotid arteries with color Doppler ultrasound was performed on the same day as the initial examination. This demonstrated thrombosis of the right CCA, which extended from the point of origin of the vessel to 1 centimeter proximal to the bifurcation. What is more, there was retrograde flow of blood in the ipsilateral ECA originating from the superior thyroid artery. This was clearly demonstrated by color enhancement (see *Fig. 2*).

Compression of the contralateral ECA at the level of the carotid bifurcation was performed using the index finger of the examiner after it had been ascertained that this vascular region was unaffected by atherosclerosis. The retrograde blood flow in the ipsilateral ECA ceased during compression. This maneuver confirmed that the blood flow observed in the right ECA originated in the contralateral ECA by means of a collateral circle, which was later proved to make use of the superior thyroid artery.

The subsequent exploration of cerebral blood flow by means of transcranial color Doppler ultrasound demonstrated the presence of antegrade blood flow in the middle cerebral artery ipsilateral to the occlusion. It was reduced and irregular with respect to that of the corresponding contralateral artery (see *Fig. 1, Frame 2*). Digital subtraction angiography of the supra-aortic vessels was performed the next day. This confirmed the Doppler ultrasound findings (see *Fig. 3*).

The second patient was a 52-year-old man. He had presented 7 days prior to our examination with symptoms of transient right-sided amaurosis. The doppler, color Doppler, and digital subtraction angiographic studies demonstrated a vascular picture that was completely identical to that of the first patient. In this case, the dynamic compression test also confirmed that the compensatory blood flow passed through the superior thyroid arteries. The third patient, a 64-year-old man, had presented 15 days prior to our examination with transient global amnesia. In this case, we observed occlusion of the left common carotid artery. Consequently, the collateral circle that connected the two ECAs through the anastomosis between the two superior thyroid arteries flowed from right to left, rather than the reverse.

Figure 1 semi-schematically summarizes the Doppler velocimetry of the supra-aortic and the direction of the blood flow in the collateral circle. *Figure 4* schematically illustrates the anatomy of the collateral circles between the superior thyroid arteries through the «supra-isthmic», «infra-isthmic», and «retrolobar longitudinal» anastomoses. In our study, the collateral circle was formed by the «supra-isthmic» anastomosis (labelled «A» in the figure), as confirmed by the angiographic investigation (see *Fig. 3*).

DISCUSSION AND CONCLUSIONS

Our study has demonstrated how arteries that are apparently independent of the cerebral circulation may constitute a functional collateral circle under special conditions. As a consequence of occlusion of the common carotid artery, the superior thyroid artery can assume a determinant significance in guaranteeing an adequate supply of blood to the brain through the external carotids.

Several investigators have already described analogous cases of obstruction of the common carotid artery in which a compensatory blood flow was established through the thyroid arteries (Franceschi, 1980; Dauzat, 1986), while other have demonstrated the wide variability of neurological deficits caused by the same type of occlusion of the carotid bed (Fazio, 1969; Pastore, *et al.*, 1972; Stebbens, 1972). However, the latter failed to precisely define the anastomosis between the superior thyroid arteries that we have described by a comparison between color Doppler ultrasonographic (extra- and transcranial) and angiographic findings.

Furthermore, the anatomic importance of the thyroid arteries was already well-known in the relationship between the vascular bed and thyroid parenchyma (Rindone, 1926; Fazzari, 1926). However, it was difficult to demonstrate that these arteries could function as a temporary collateral circle in the event of carotid obstruction.

With the assistance of ultrasonographic instruments such as color Doppler, we have demonstrated that this hypothesis is not improbable. The superior thyroid arteries are small-caliber vessels; 1 centimeter from their point of origin, their diameter is only 1.7 ± 0.3 mm. Nevertheless, this caliber permits the transit of a sufficient amount of blood to sustain cerebral perfusion in most cases (Hennerici, 1991; Franceschi, 1992).

For example, it is known that a stenosis of the internal carotid artery (whose mean diameter varies from 3.7 to 4.5 mm) of less than 80% is not hemodynamically significant (Planiol, *et al.*, 1972; Muller, 1972; Labauge, 1974; Franceschi, 1980).

This suggests that no possibility can be excluded *a priori*. Every artery, even the smallest and apparently insignificant, may constitute the only, critical temporary pathway in the event of obstruction of an important vessel, such as the common carotid artery.

Awareness of the collateral circles is of great help to the clinician, because their recognition and the definition of their hemodynamic importance is indispensable, not only for formulating a prognosis, but also and especially for selecting one therapeutic plan rather than another.

Arrived 10/3/93. Accepted 22/3/93.

REFERENCES

- Ackerman RH, LA Vigneault, DS Pryor, JM Taveras, 1979. Real-Time ultrasound scanning of the carotid artery as part of a battery of test for non-invasive diagnosis of carotid disease. *Acta neurol. scand.* (Supp. 72) 60, 464-465.

- Aaslud R (ed): *Transcranial doppler sonography*. Springer, Wien 1986.
- Bharadvai BK, RF Mabon, DP Giddens, 1982. Steady flow in a model of the human carotid bifurcation. Part I-Flow visualization. *J Biomech* 15: 349-362.
- Chiarugi G, Bucciante L, 1975. *Istituzioni di Anatomia dell'Uomo*, Vallardi, Milano.
- Dauzat M, Laroche JP, De Bray JM, Juhel P, Becker F, Cesari JB, Jonnart L, Domergue A, Crette J, Duvauferrier R, Heyden D, Maugin D, Vongouthi S, Davinroy M, 1986. *Pratique de l'ultrasonographie vasculaire (Doppler echographie)*, Vigot, Paris.
- Delouche A, P Peronneau, 1985. In vitro study modifications of blood flow patterns induced by a bifurcation. *Biorheology* 22: 55-71.
- Fazio C, 1969. Haemodynamic factors in the pathogenesis of brain infarct. *Europ Neurol*, 2: 76.
- Fazzari I, 1926. Contributo allo studio morfologico e statistico della ghiandola tiroide in Sicilia. *Endocr e Pat costituzionale*, settembre.
- Franceschi C, Luizy F, Jardin M, Martelli L, Tanitte M, 1980. La carotide externe sous-parotidienne: un point de compression méconnu mais de grande valeur diagnostique: *Ultrasons*, I: 295-298.
- Garth KE, Carroll BA, Summer EG, 1983. Duplex ultrasound scanning of the carotid arteries with velocity spectrum analysis. *Radiology* 147: 823-827.
- Gray's Anatomy, 1989. Longman Group LTD, London.
- Hass WK, Fields WS, North RR, Kricheff I, Chase NE, Bauer RB 1968. Joint study of extracranial arterial occlusion. II arteriography techniques sites and complications, *J Amer Med Ass* 203: 961-968.
- Hennerici M, Neuerburg HD, 1991. *Diagnostica vascolare con ultrasuoni*. Il Pensiero Scientifico Editore, Roma.
- Hennerici M, Hulsbomer HB, Hefter H, Lammerts D, Rautemberg W, 1987. Natural History of asymptomatic extracranial arterial disease. Results of a long-term prospective study. *Brain* 110: 777-791.
- Labauge R, Blard JM, Rachdi M, 1974. L'ultrasonographie directionnelle à effect doppler dans le diagnostic des occlusions et stenoses serrées de l'axe carotidien. Correlation avec les données de l'angiographie. *Colloque de SFAUMB*, novembre.
- La Rocca C, 1906. Ramo parasternale, non ancora descritto, dell'arteria tiroidea inferiore destra. *Arch di Anat Pat e scienze affini*, anno II, fasc II. Pr Stab Tipo-lito Andrea Brangi Palermo.
- Muller HR, 1972. Contribution au diagnostic différentiel des hémiplésiés vasculaires par les methodes ultrasoniques, *Méd et Hyg.* 30: 1812, 1813.
- Pastore E, Pistoiese G, Agnoli A, Citone G, Fiorani P, 1972. L'insufficienza cerebrovascolare da lesione dei vasi cerebrali nel tratto extracranico. *Min Anestesiol*, 30, 533.
- Planiol Th, et Pourcelot L, 1972. Etude des troubles de la circulation cérébrale par effect doppler. Communication à la Société Suisse d'Angéiologie, Genève.
- Pernkopf E, 1963. *Atlante di Anatomia Sistemica e Topografica dell'uomo*, Piccin Editore, Padova.
- Rindone A, 1929. Studio sulle arterie tiroidee e sulla ghiandola tiroide con particolare riguardo al rapporto tra diametro arterioso e sviluppo della ghiandola. *Arch it di Anat e di Embriologia*, vol XXVI, fasc 2 ED. Luigi Niccolai, Firenze.
- Sobotta J, Becher H, 1974. *Atlante di Anatomia dell'Uomo*, Uses, Firenze.
- Stebbens WE, 1972. *Patology of the cerebral blood vessels*. Mosby.
- Spalteholz W, Spanner R, 1977. *Atlante di Anatomia Umana*, Vallardi ed. Milano.
- Testut L, Jacob O, 1974. *Trattato di Anatomia Topografica*, UTET, Torino.
- Zülch KJ, 1969. Allgemeine prinzipien bei der entstehung der kollateralkreisläufe, *Der hirnarterien der radiologie* 9: 369-406.

FIGURE LEGEND

Fig. 1 — A semi-schematic representation of the Doppler velocimetry of the supra-aortic trunk of the 58-year-old patient who had presented with occlusion of the right common carotid artery. *A*: supra-isthmic anastomosis between the superior thyroid arteries; *SS*: subclavian arteries; *CC*: common carotid arteries; *TT*: superior thyroid arteries; *EE*: external carotid arteries; *II*: internal carotid arteries; *OO*: ophthalmic arteries; *MM*: middle cerebral arteries.

Frames 1 and 2: see references in text. *DX*: right; *SN*: left.

Fig. 2 — Carotid color Doppler of the 58-year-old patient (right view). Note the retrograde blood flow (blue) in the external carotid artery (*EC*), the flow of blood in the superior thyroid artery (arrow), and the anterograde blood flow (red) in the internal carotid artery (*IC*). There was no detectable blood flow in the common carotid artery (*CC*), since it was obstructed at its origin.

Fig. 3 — Digital subtraction angiography of the supra-aortic trunk of the 58-year-old patient. The right common carotid artery is obstructed, and there is anterograde blood flow in the ipsilateral internal carotid, which is supplied by the contralateral superior thyroid artery by means of the supra-isthmic anastomosis (arrow).

Fig. 4 — Anastomoses between the thyroid arteries. *A* supra-isthmic anastomosis; *CC*: common carotid arteries; *II*: internal carotid arteries; *EE*: external carotid arteries; *TT*: superior thyroid arteries.

Fig. 1

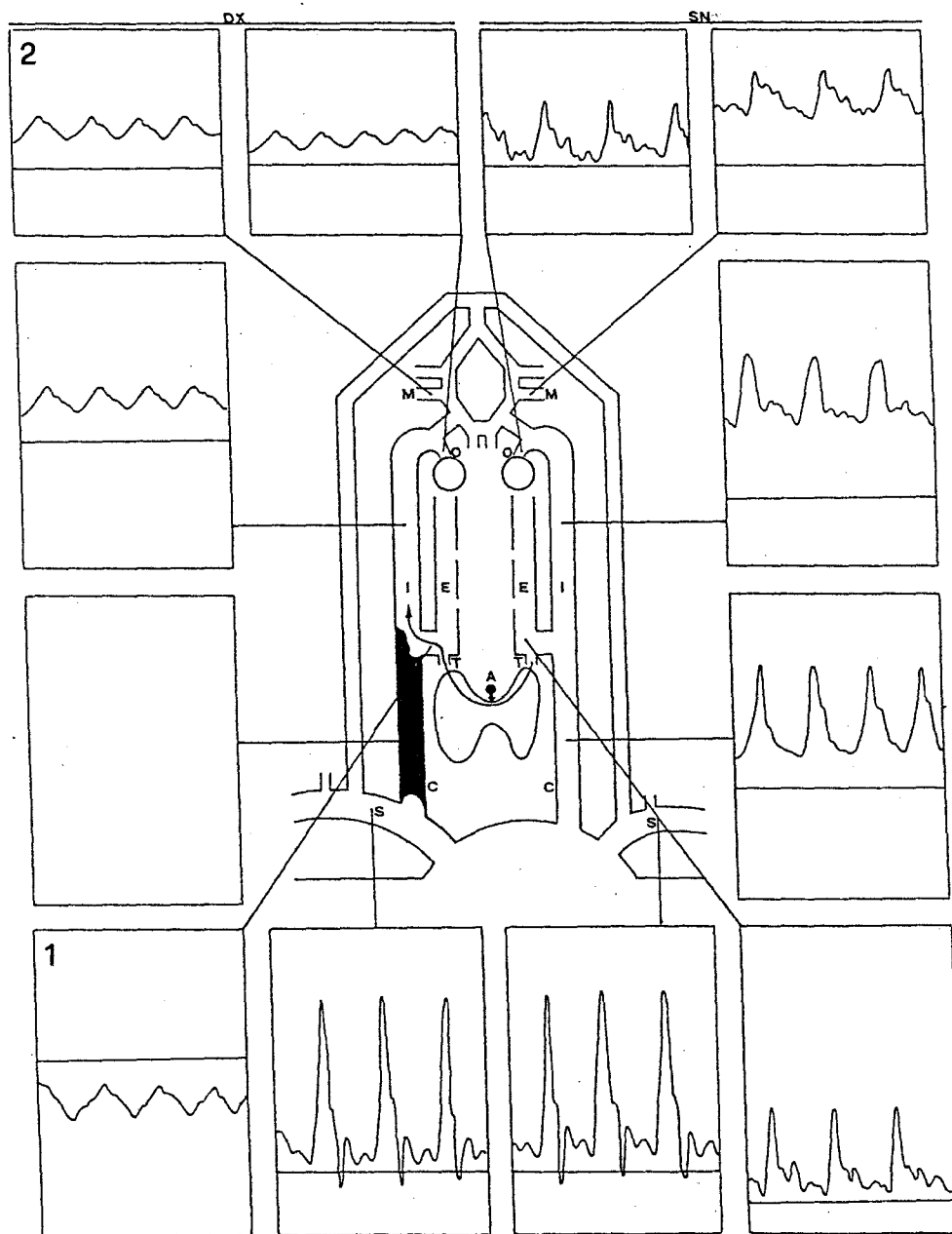


Fig. 2-3

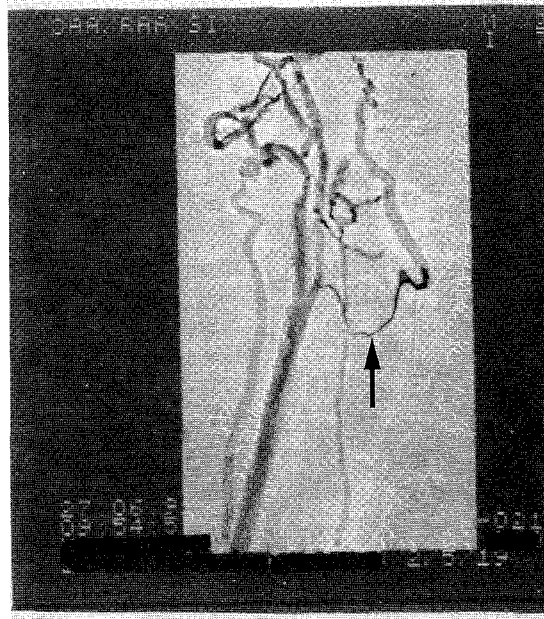
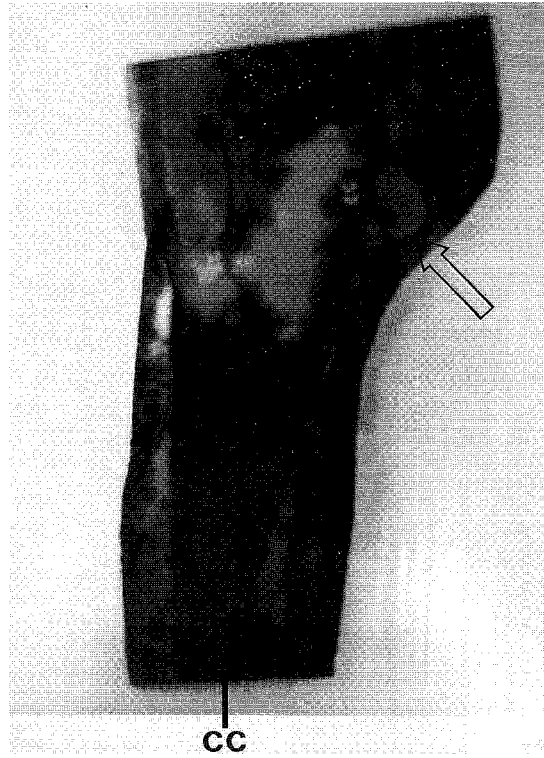


Fig. 4

