UNIVERSITÀ DEGLI STUDI FIRENZE

FLORE
Repository istituzionale dell'Università degli Studi di Firenze

Classification of dental surface defects in areas of gingival recession.

Questa è la Versione finale referata (Post print/Accepted manuscript) della seguente pubblicazione:

Original Citation:
Classification of dental surface defects in areas of gingival recession / Pini-Prato G;Franceschi D;Cairo F;Nieri M;Rotundo R. - In: JOURNAL OF PERIODONTOLOGY. - ISSN 0022-3492. - ELETTRONICO. - 81:(2010), pp. 885-890. [10.1902/jop.2010.090631]

Availability:
This version is available at: 2158/773993 since:

Published version:
DOI: 10.1902/jop.2010.090631

Terms of use:
Open Access
La pubblicazione è resa disponibile sotto le norme e i termini della licenza di deposito, secondo quanto stabilito dalla Policy per l'accesso aperto dell'Università degli Studi di Firenze (https://www.sba.unifi.it/upload/policy-oa-2016-1.pdf)

Publisher copyright claim:

(Article begins on next page)

12 October 2024

Classification of Dental Surface Defects in Areas of Gingival Recession

Giovanpaolo Pini-Prato,* Debora Franceschi,* Francesco Cairo,* Michele Nieri,* and Roberto Rotundo*

Background: A clinical classification of surface defects in gingival recession area is proposed.

Methods: Two factors were evaluated to set up a classification system: presence (A) or absence (B) of cemento-enamel junction (CEJ) and presence (+) or absence (–) of dental surface discrepancy caused by abrasion (step). Four classes (A+, A–, B+, and B–) were identified on the basis of these variables. To validate the classification three different calibrated examiners applied the proposed classification system to 46 gingival recessions and κ statistics were performed. The classification was used on 1,010 gingival recessions from 353 patients to examine the distribution of the four classes.

Results: The κ statistics for intrarater agreement ranged from 0.74 to 0.95 (almost perfect agreement), whereas interrater agreement ranged from 0.26 to 0.59 (moderate agreement). Out of 1,010 exposed root surfaces associated with gingival recession, 144 showed an identifiable CEJ associated with a root surface defect (Class A+, 14%); 469 an identifiable CEJ without any associated step (Class A–, 46%); 244 an unidentifiable CEJ with a step (Class B+, 24%); and 153 an unidentifiable CEJ without any associated step (Class B–, 15%).

Conclusion: The proposed classification describes the dental surface defects that are of paramount importance in diagnosing gingival recession areas. *J Periodontol 2010;81:885-890.*

KEY WORDS

Cemento-enamel junction; classification; dental enamel; diagnosis; gingival recession; tooth abrasion.

* Department of Periodontology, University of Florence, Florence, Italy.

The Glossary of the American Academy of Periodontology defines gingival recession as "the apical migration of the gingival margin beyond the cemento-enamel junction."[1] As a consequence, the damage to soft tissues leads to exposed root along with loss of attachment and bone loss. To categorize these defects, Miller[2] proposed four classes of marginal gingival recessions based on the degree of involvement of the periodontal tissues (mucogingival junction and underlying alveolar bone). This clinically useful classification evaluates different degrees of damage to periodontal tissues, but does not consider the condition of the exposed root surface: presence of an identifiable cemento-enamel junction (CEJ) and presence of root abrasion. Sometimes these lesions may be associated with enamel abrasion.

The CEJ serves as the reference point for the diagnosis and treatment of such defects. The anatomic and esthetic success of a procedure is based on a gingival margin located slightly more coronally to the CEJ after surgery[3-6] and in a good integration of the grafted gingival tissue with the adjacent teeth.[7] However, the CEJ is not identifiable in some cases because of dental abrasion caused by tooth brushing trauma or cervical caries.[3,8] In this situation, clinicians encounter difficulties in accurately measuring the depth and the width of recessions during the diagnostic phase. Other problems may arise during the surgical procedure because the lack of an identifiable CEJ does

doi: 10.1902/jop.2010.090631

not allow for the precise location of the gingival margin when suturing. Where does the clinician place the margin of the flap or graft? In fact, after surgery the coronal position of the gingival margin with respect to the CEJ is a fundamental requirement for obtaining complete root coverage using coronally advanced flap.[9,10]

More serious surgical problems may occur in the presence of a pronounced root surface discrepancy caused by traumatic abrasion and erosion of hard tissue (step). These conditions impair the proper positioning of the flap (coronally advanced flap) or the graft (connective tissue graft) on the dental surface.[8] In addition, the accurate evaluation of the clinical outcome of the root coverage procedure is difficult at the end of the treatment if the CEJ is lacking. In this situation, it is not possible to establish whether or not complete root coverage has been achieved. In many articles dealing with root coverage procedures, gingival recessions with no identifiable CEJ are excluded from the study as selection criteria.[10-12]

On the basis of these considerations, complete root coverage might not be obtained even in Miller Class I and II recession defects associated with root and crown abrasion. Therefore, an accurate evaluation of the dental hard tissues associated with Miller's[2] periodontal classification could be useful for a complete diagnosis of gingival recession areas.

The aim of this article is to propose a clinical classification of surface defects in gingival recession areas by evaluating two factors: presence or absence of CEJ, and presence or absence of dental surface discrepancy (step).

MATERIALS AND METHODS

The buccal aspect of the exposed root associated with gingival recessions was the object of this study.

Identification of Hard Tissue Variables and Classification

The evaluation was performed on both frontal and lateral views using a ×4 magnification lens, a periodontal probe (PCP UNC 15), and a dental explorer. Two variables were considered: CEJ and cervical discrepancies. Considering the presence of the CEJ on the buccal surface, two classes were identified: Class A, identifiable CEJ on the entire buccal surface; and Class B, unidentifiable CEJ totally or partially. Considering the presence of cervical discrepancies (step), measured with a periodontal probe perpendicular to the long axis of the tooth in the deepest point of the abrasion, two classes were identified: Class (+), presence of cervical step (>0.5 mm) involving the root or the crown and the root; and Class (–), absence of cervical step. Therefore, a working classification identifies four different conditions (Figs. 1 through 4 ; Table 1).

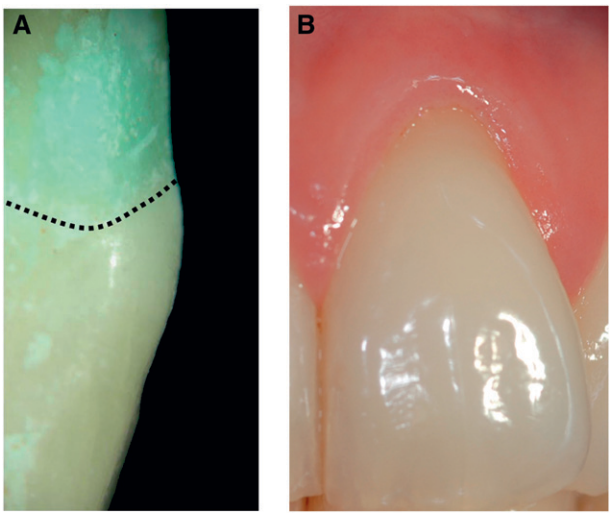

Figure 1.
*Gingival recession associated with an identifiable cemento-enamel junction without a surface discrepancy (step) (Class A–). Histologic **(A)** and clinical **(B)** views.*

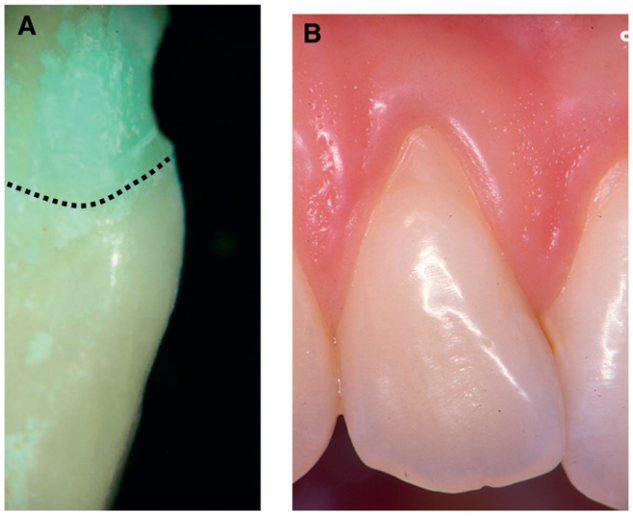

Figure 2.
*Gingival recession associated with an identifiable cemento-enamel junction and a surface discrepancy (step) (Class A+). Histologic **(A)** and clinical **(B)** views.*

Validation Session

Three periodontal examiners (GPP, RR, and FC), with >10 years of periodontal practice, were required to attend a calibration session on 46 recession defects aimed at the validation of the proposed classification. Under the guidance of one statistical operator (MN) the examiners twice evaluated, independently and blindly, the presence or absence of CEJ and of step after an interval of 1 hour. The considered variables were recorded directly by the statistician.

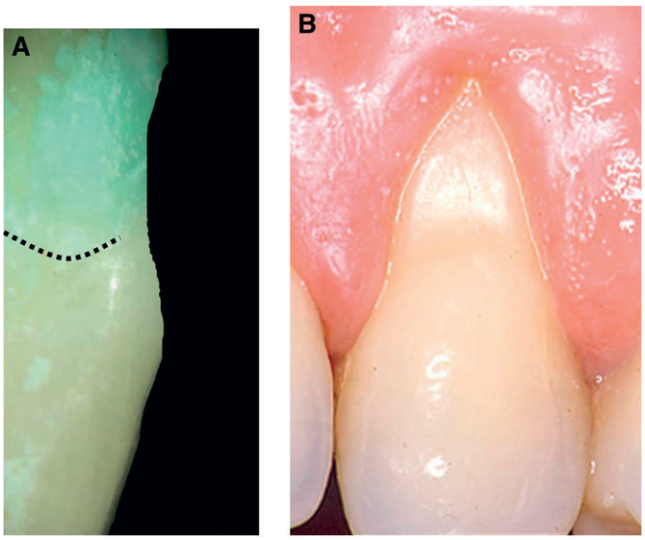

Figure 3.
*Gingival recession associated with an unidentifiable cemento-enamel junction without a surface discrepancy (Class B–). Histologic **(A)** and clinical **(B)** views.*

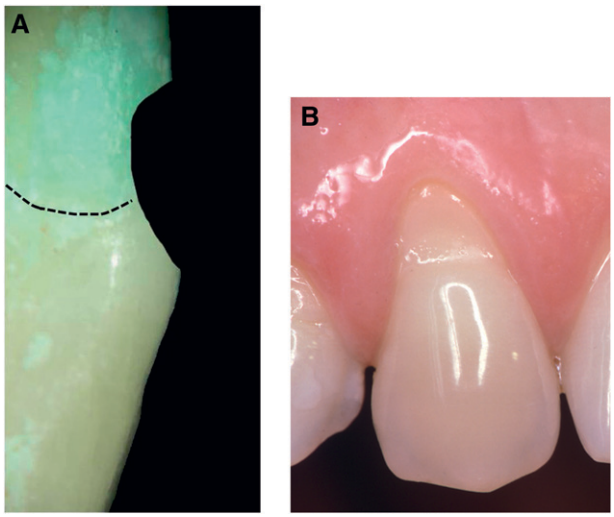

Figure 4.
*Gingival recession associated with an unidentifiable cemento-enamel junction with a surface discrepancy (Class B+). Histologic **(A)** and clinical **(B)** views.*

κ statistics were performed to analyze the intrarater and interrater agreement among the three examiners. The interrater agreement was calculated using the first measurement by each examiner, whereas intrarater agreement was assessed using both measurements. The training results were evaluated according to Landis and Koch.[13]

Distribution of Hard Tissue Defects

To observe the distribution of the four classes of the present classification, 359 patients presenting at least one gingival recession were examined between January 2008 and May 2009 at the Department of Periodontology, University of Florence, Florence, Italy. A sample of 1,010 consecutive maxillary and mandibular gingival recessions was included in the study. Informed written consent was obtained from all subjects who participated in the study. The principles set forth in the Helsinki Declaration on experimentation involving human subjects were fully respected in obtaining the informed consent and in the conduct of the study. A descriptive statistic analysis was also performed.

Table 1.

Classification System of Four Different Classes of Root Surface Discrepancies

CEJ	Step	Descriptions
Class A	–	CEJ visible, without step (Fig. 1)
Class A	+	CEJ visible, with step (Fig. 2)
Class B	–	CEJ not visible, without step (Fig. 3)
Class B	+	CEJ not visible, with step (Fig. 4)

RESULTS

Four classes of dental surface defects in areas of gingival recession were identified on the basis of the presence (Class A) or absence (Class B) of CEJ and of presence (Class+) or absence (Class–) of surface discrepancy (step).

The intrarater and interrater agreement (κ statistics) among the three examiners referring to the presence or absence of the CEJ and of the step is shown in Tables 2 and 3. The κ statistics for intrarater agreement ranged from 0.74 to 0.95 (almost perfect agreement), whereas interrater agreement ranged from 0.26 to 0.59 (moderate agreement) according to the guidelines proposed by Landis and Koch.[13]

The distribution of the four classes was observed within a population of 1,010 gingival recessions in 359 patients, 175 males and 184 females, between 10 and 64 years of age (33.7 ± 10.9). A total of 612 recessions were located in the maxillary arch and 398 in the lower jaw. A descriptive statistical analysis is given in Table 4. Out of 1,010 exposed root surfaces associated with gingival recession, 144 showed an identifiable CEJ associated with a root surface defect (Class A+, 14%); 469 an identifiable CEJ without any associated step (Class A–, 46%); 244 an unidentifiable CEJ with a step (Class B+, 24%); and 153 an unidentifiable CEJ without any associated step (Class B–, 15%).

DISCUSSION

The aim of this study is to propose a classification of surface defects in gingival recession areas. This classification is based on the evaluation of two clinical factors that may be observed on hard dental tissues following the occurrence of gingival recession: presence (Class A) or absence (Class B) of identifiable CEJ and presence (Class+) or absence (Class–) of dental surface discrepancy (step).

Miller's[2] classification for gingival recessions allows for identifying different conditions based on the amount of soft periodontal tissues around the affected teeth. However, a gingival recession is also characterized by an involvement of dental hard tissues with the exposure of the root surface and of the CEJ. The exposed root surface may be further damaged by traumatic tooth brushing or by root caries capable of causing a formation of surface discrepancies along with the disappearance of the original CEJ. During the daily practice routine, recording an identifiable CEJ or the presence of a tooth surface discrepancy is of paramount importance for measuring recession depth[1] and evaluating the outcome after treatment (i.e., partial or complete root coverage).[3] Therefore, a complete diagnosis of a gingival recession defect requires not only the evaluation of the periodontal tissues, according to Miller's[2] classification, but also the assessment of the hard dental tissue conditions. The condition of the exposed root surface may also be important for the prognostic evaluation of mucogingival surgery. For instance, in case of a Miller Class I or II associated with a deep surface abrasion the predictability of achieving 100% root coverage might not be ensured because of the difficulty in stabilizing the flap on the exposed root surface,

In this study the surface discrepancy (step) was measured with a periodontal probe perpendicular to the long axis of the tooth in the deepest point of the abrasion. The choice of a step >0.5 mm (Fig. 5) is justified by a clinical observation that flap thickness >0.8 mm is associated with complete root coverage.[14]

Table 2.

Cemento-Enamel Junction: Intrarater and Interrater Agreement (κ statistics)

Examiner	Examiner #1	Examiner #2	Examiner #3
Examiner #1	0.78 (0.09)	0.48 (0.12)	0.26 (0.14)
Examiner #2		0.95 (0.04)	0.52 (0.12)
Examiner #3			0.74 (0.10)

κ statistic (standard error)

Table 3.

Step: Intrarater and Interrater Agreement (κ statistics)

Examiner	Examiner #1	Examiner #2	Examiner #3
Examiner #1	0.85 (0.10)	0.53 (0.12)	0.29 (0.13)
Examiner #2		0.81 (0.09)	0.59 (0.12)
Examiner #3			0.86 (0.08)

κ statistic (standard error)

Table 4.

Distribution of the Four Classes Within a Population of 1,010 Gingival Recessions

Maxillary teeth	#2	#3	#4	#5	#6	#7	#8	#9	#10	#11	#12	#13	#14	#15
Class A+		3	4	8	13	8	4	8	15	12	10	7	4	
Class A–		4	22	30	27	28	35	41	35	20	21	11	4	
Class B+		3	8	14	18	6	2	6	9	32	26	13	1	1
Class B–	1	3	7	11	15	4	8	8	8	13	14	6	1	
Mandibular teeth	#31	#30	#29	#28	#27	#26	#25	#24	#23	#22	#21	#20	#19	#18
Class A+		2	2	6	3	5	6	4	6	6	5	1	2	
Class A–		3	10	12	15	17	30	38	23	21	12	8	2	
Class B+		2	9	13	10	5	9	10	6	15	16	9	1	
Class B–		1	7	7	3	1	4	3	2	7	11	8		

Figure 5.
Lateral view of a surface discrepancy (step) >0.5 mm measured with a periodontal probe.

In this case, a thick flap may fill the cervical root discrepancy at the end of its coronal position.

To validate the reliability of the classification, three different examiners applied it to a sample of gingival recessions showing κ statistics for intrarater agreement ranging from 0.74 to 0.95 (almost perfect) and an interrater agreement ranging from 0.26 to 0.59 (moderate). As to interrater agreement, the use of the first measurement was sufficient for assessing the agreement between raters; on the other hand, two measurements were necessary to evaluate the intrarater agreement. The κ statistics of the intrarater agreement are usually higher than interrater agreement as reported in clinical studies.[15-17] Regarding the "moderate" κ statistics values found for interrater agreement, these results are similar to those reported in the clinical evaluations of root coverage procedures.[17]

Following the validation of the system, a sample of 1,010 gingival recessions were collected to assess the distribution of the four classes of this classification. It should be noted that 46% of gingival recessions showed an identifiable CEJ without a surface discrepancy (Class A–), thus allowing for a precise diagnosis and for precise outcome assessment of the root coverage procedure after treatment. However, 39% of the cases did not show an identifiable CEJ (Class B+ and Class B–), indicating that a correct diagnosis and a proper outcome evaluation could not be adequate in these cases. In addition, the presence of a surface discrepancy (Class A+ and Class B+) was observed in 38% of the gingival recessions. In particular, in 14% of the cases (Class A+) the abrasion was localized only on the root surface, whereas in 24% (Class B+) it involved both the root and the crown. These different conditions should be taken into consideration and might require different treatment approaches.

CONCLUSION

The classification of dental surface defects in conjunction with the classification of periodontal tissues is useful for reaching a more precise diagnosis in areas of gingival recession.

ACKNOWLEDGMENT

The authors report no conflicts of interest related to this study.

REFERENCES

1. American Academy of Periodontology. *Glossary of Periodontal Terms*, 4th edition. Chicago, IL; 2001: 44.
2. Miller PD Jr. A classification of marginal tissue recession. *Int J Periodontics Restorative Dent* 1985;5:8-13.
3. Zucchelli G, Testori T, De Sanctis M. Clinical and anatomical factors limiting treatment outcomes of gingival recession: A new method to predetermine the line of root coverage. *J Periodontol* 2006;77:714-721.
4. Miller PD Jr. Root coverage with the free gingival graft. Factors associated with incomplete coverage. *J Periodontol* 1987;58:674-681.
5. Miller PD Jr. Root coverage grafting for regeneration and aesthetics. *Periodontol* 2000 1993;1:118-127.
6. Rotundo R, Nieri M, Mori M, Pini Prato G. Aesthetic perception after root coverage procedure. *J Clin Periodontol* 2008;35:705-712.
7. Cairo F, Rotundo R, Miller PD, Pini-Prato GP. Root coverage esthetic score: a system to evaluate the esthetic outcome of the treatment of gingival recession through evaluation of clinical cases. *J Periodontol* 2009;80:705-710.
8. Pini-Prato G, Baldi C, Rotundo R, Franceschi D, Muzzi L. The treatment of gingival recession associated with deep corono-radicular abrasions (CEJ step) – A case series. *Perio–Periodontal Practices Today* 2004;1:57-66. Available at: http://www.quintpub.com/journals/perio/archive_display_abstract.php3?journalArt=6947. Accessed April 14, 2010.
9. Pini-Prato G, Baldi C, Pagliaro U, et al. Coronally advanced flap procedure for root coverage. Treatment of root surface: Root planing versus polishing. *J Periodontol* 1999;70:1077-1084.
10. Pini-Prato GP, Baldi C, Nieri M, et al. Coronally advanced flap: The post-surgical position of the gingival margin is an important factor for achieving complete root coverage. *J Periodontol* 2005;76:713-722.
11. Cortellini P, Tonetti M, Baldi C, et al. Does placement of a connective tissue graft improve the outcomes of coronally advanced flap for coverage of single gingival recessions in upper anterior teeth? A multi-centre, randomized, double-blind, clinical trial. *J Clin Periodontol* 2009;36:68-79.
12. Zucchelli G, Mele M, Mazzotti C, Marzadori M, Montebugnoli L, De Sanctis M. Coronally advanced flap with and without vertical releasing incisions for the treatment of multiple gingival recessions: A comparative controlled randomized clinical trial. *J Periodontol* 2009;80:1083-1094.

13. Landis JR, Koch GG. The measurement of observer agreement for categorical data. *Biometrics* 1977;33: 159-174.
14. Baldi C, Pini-Prato G, Pagliaro U, et al. Coronally advanced flap procedure for root coverage. Is flap thickness a relevant predictor to achieve root coverage? A 19-case series. *J Periodontol* 1999;70:1077-1084.
15. Elison JM, Leggitt VL, Thomson M, Oyoyo U, Wycliffe ND. Influence of common orthodontic appliances on the diagnostic quality of cranial magnetic resonance images. *Am J Orthod Dentofacial Orthop* 2008;134: 563-572.
16. Spermon J, Spermon-Marijnen R, Scholten-Peeters W. Clinical classification of deformational plagiocephaly according to Argenta: A reliability study. *J Craniofac Surg* 2008;19:664-668.
17. Kerner S, Katsahian S, Sarfati A, et al. A comparison of methods of aesthetic assessment in root coverage procedures. *J Clin Periodontol* 2009;36:80-87.

Correspondence: Prof. Giovanpaolo Pini-Prato, Viale Matteotti 11, 50121 Florence, Italy. E-mail: gpinipr@tin.it.

Submitted November 12, 2009; accepted for publication January 25, 2010.