UNIVERSITÀ DEGLI STUDI FIRENZE

FLORE
Repository istituzionale dell'Università degli Studi di Firenze

Current diagnostic strategies for undifferentiated tumours of the nasal cavities and paranasal sinuses.

Questa è la Versione finale referata (Post print/Accepted manuscript) della seguente pubblicazione:

Original Citation:

Current diagnostic strategies for undifferentiated tumours of the nasal cavities and paranasal sinuses / Franchi A; Palomba A; Cardesa A.. - In: HISTOPATHOLOGY. - ISSN 0309-0167. - STAMPA. - 59:(2011), pp. 1034-1045..

Availability:

This version is available at: 2158/645738 since:

Terms of use:

Open Access

La pubblicazione è resa disponibile sotto le norme e i termini della licenza di deposito, secondo quanto stabilito dalla Policy per l'accesso aperto dell'Università degli Studi di Firenze (https://www.sba.unifi.it/upload/policy-oa-2016-1.pdf)

Publisher copyright claim:

(Article begins on next page)

12 October 2024

Histopathology 2011 DOI: 10.1111/j.1365-2559.2011.03813.x

REVIEW

Current diagnostic strategies for undifferentiated tumours of the nasal cavities and paranasal sinuses

Alessandro Franchi, Annarita Palomba[1] & Antonio Cardesa[2]

Division of Anatomic Pathology, Department of Critical Care Medicine and Surgery, University of Florence Medical School, [1]Division of Histopathology, Azienda Ospedaliera Universitaria Careggi, Florence, Italy, and [2]Anatomia Patologica, Facultat de Medicina, Hospital Clinic, Universitat de Barcelona, Institut D'Investigacions Biomediques August Pi i Sunyer (IDIBAPS), Barcelona, Spain

Franchi A, Palomba A & Cardesa A

(2011) *Histopathology*

Current diagnostic strategies for undifferentiated tumours of the nasal cavities and paranasal sinuses

Several malignant tumours occurring in the sinonasal tract may present with an undifferentiated morphology. Overall, these lesions pose significant diagnostic difficulties for the surgical pathologist, especially in limited biopsy material, but their correct classification is becoming increasingly important for an appropriate treatment strategy. This review deals with the criteria for differential diagnosis of these neoplasms, with emphasis on recent advances in immunohistochemistry and molecular biology, as well as with previous progress in electron microscopy. Through careful microscopic examination of haematoxylin and eosin-stained sections, in the light of clinical information and imaging data, a list of differential diagnoses can be made and an appropriate panel of antibodies can be chosen to further categorize the tumour. An initial panel including cytokeratins, synaptophysin, S100 protein, desmin and CD45 may allow the classification of most lesions or may help to narrow the list of differential diagnoses. Further refinement can be obtained through second-line markers, including *in-situ* hybridization for Epstein–Barr virus, other neuroendocrine markers, melanocytic markers, myogenin, CD99, other lymphocyte markers, and CD138 and light chains. Finally, molecular analysis can further assist in the recognition of specific entities such as nuclear protein in testis midline carcinoma, Ewing's sarcoma/peripheral neuroectodermal tumour, alveolar rhadbomyosarcoma, and poorly differentiated synovial sarcoma.

Keywords: diagnosis, electron microscopy, immunohistochemistry, molecular biology, nasal cavity, paranasal sinuses, undifferentiated tumours

Abbreviations: ACC, adenoid cystic carcinoma; BSCC, basaloid squamous cell carcinoma; CCC, cylindrical cell carcinoma; CK, cytokeratin; EBV, Epstein–Barr virus; EMA, epithelial membrane antigen; GFAP, glial fibrillary acidic protein; HPV, human papilloma virus; NK, natural killer; NMC, nuclear protein in testis midline carcinoma; NPTUC, nasopharyngeal-type undifferentiated carcinoma; NSE, neuron-specific enolase; NUT, nuclear protein in testis; ON, olfactory neuroblastoma; PNET, peripheral neuroectodermal tumour; RMS, rhabdomyosarcoma; SCC, squamous cell carcinoma; SCNEC, small-cell neuroendocrine carcinoma; SNUC, sinonasal undifferentiated carcinoma

Introduction

Malignant tumours of the nasal cavities and paranasal sinuses represent about 3.6% of all malignancies arising in the head and neck area.[1] Data from cancer registries indicate that approximately two-thirds of primary sinonasal malignancies are of epithelial origin, although there are significant differences in the distri-

Address for correspondence: A Franchi, MD, Division of Anatomical Pathology, Department of Critical Care Medicine and Surgery, University of Florence, Viale G.B. Morgagni 85, 50134 Firenze, Italy. e-mail: franchi@unifi.it

© 2011 Blackwell Publishing Limited.

bution of histological subtypes in different countries, possibly related to variable exposure to risk factors.[2]

Several of the malignant tumours occurring primarily in the sinonasal tract may present with an undifferentiated or poorly differentiated morphology, being composed of small to medium and large, round or polygonal atypical cells.[3–5] Overall, they pose significant diagnostic difficulties for the surgical pathologist, especially in limited biopsy material, but their correct classification by means of histology, immunohistochemistry or molecular biology is becoming increasingly important for choosing an appropriate treatment strategy.[6,7] In addition, poorly differentiated neoplasms may involve the sinonasal region through spread from local sites (oral cavity, nasopharynx, or skull base) or by metastasis from distant sites. Although these occurrences are exceedingly rare, the clinical history and the results of imaging studies should be available for an accurate differential diagnosis.

In recent years, the spectrum of primary sinonasal undifferentiated neoplasms has enlarged, because new entities specific to this region or initially described in other locations have been recognized. In addition, several new immunohistochemical and molecular markers have been tested on these neoplasms, and they facilitate, in combination with light and ultrastructural morphology, their correct classification. To follow a practical diagnostic approach, sinonasal undifferentiated neoplasms can be broadly divided into epithelial and non-epithelial neoplasms (Table 1). The first group primarily includes sinonasal undifferentiated carcinoma (SNUC), sinonasal nasopharyngeal-type undifferentiated carcinoma (NPTUC), small-cell neuroendocrine carcinoma (SCNEC), and nuclear protein in testis (NUT) midline carcinoma (NMC), but several other sinonasal carcinomas, such as squamous cell carcinoma (SCC) and its variants, as well as glandular neoplasms such as adenoid cystic carcinoma (ACC), may have a poorly differentiated histological aspect requiring differential diagnosis.

The group of non-epithelial malignancies includes: (i) neuroectodermal tumours (tumours with neuroectodermal differentiation) – olfactory neuroblastoma (ON), Ewing's sarcoma/peripheral neuroectodermal tumour (PNET), and malignant melanoma; (ii) sinonasal malignant haematological neoplasms – lymphomas, plasmacytoma, granulocytic sarcoma, and histiocytic sarcoma; and (iii) sarcomas – rhabdomyosarcoma (RMS), mesenchymal chondrosarcoma, poorly differentiated synovial sarcoma, and desmoplastic small round cell tumour.

The purpose of this review is to discuss the criteria for differential diagnosis of these neoplasms, with emphasis on recent advances in immunohistochemistry and molecular diagnostics, as well as previous progress in electron microscopy.

Table 1. Potential range of sinonasal tumours that may present with an 'undifferentiated' morphology

Epithelial		
	Sinonasal undifferentiated carcinoma	
	Nasopharyngeal-type undifferentiated carcinoma (lymphoepithelioma)	
	NUT midline carcinoma	
	Small-cell neuroendocrine carcinoma	
	Squamous cell carcinoma and variants	
Non-epithelial		
	Neuroectodermal tumours	
		Melanoma
		Olfactory neuroblastoma
		Ewing's sarcoma/PNET
	Haematolymphoid tumours	
		Non-Hodgkin lymphomas
		Extramedullary plasmacytoma
		Extramedullary myeloid sarcoma
	Mesenchymal tumours	
		Rhabdomyosarcoma
		Mesenchymal chondrosarcoma
		Synovial sarcoma
		Desmoplastic small round cell tumour

Epithelial neoplasms

SNUC

SNUC is a highly aggressive anaplastic epithelial neoplasm of the nasal cavity and paranasal sinuses that occurs in both sexes over a wide age range, with a median in the sixth decade of life.[8] It frequently originates from the ethmoid region as a large fungating mass with invasion of adjacent sinonasal structures, as well as the orbit, skull base, and brain. Microscopically, it is composed of sheets, nests or ribbons of small to medium-sized cells, lacking evidence of squamous or glandular differentiation.[9–15] These cells are polygonal in shape, showing round to ovoid, hyperchromatic or vesicular nuclei, with either inconspicuous or slightly

© 2011 Blackwell Publishing Ltd, *Histopathology*

prominent nucleoli, and moderate amounts of eosinophilic cytoplasm (Figure 1). There are numerous mitotic figures, and necrosis and vascular invasion are frequently present. Ultrastructural studies have demonstrated rare dense core granules, indicative of neuroendocrine differentiation, and poorly formed desmosomes. Immunohistochemically, SNUC is positive for epithelial markers, such as simple epithelia cytokeratins (CKs)[16] and epithelial membrane antigen (EMA). Variable reactivity can be seen with neuron-specific enolase (NSE), chromogranin, and synaptophysin. SNUC is typically negative for Epstein–Barr virus (EBV).[14,15]

The main differential diagnosis of SNUC is with high-grade ON, and this is clinically relevant, because SNUC has a much worse prognosis than ON. The two entities share clinical, light microscopic and ultrastructural features, but SNUC is consistently CK-positive and lacks the typical S100-positive cells around tumour nests, as seen in ON. Conversely, ON is only occasionally and focally positive for CKs, and it is consistently positive for neural markers.

In addition, SNUC needs to be distinguished from other primary sinonasal carcinomas, such as SCNEC, solid ACC, cylindrical cell carcinoma (CCC), and NPTUC, and from malignant melanoma.

PRIMARY SINONASAL NPTUC (LYMPHOEPITHELIOMA)

NPTUC may occur in the sinonasal tract, both as a primary lesion,[15] and by extension from a primary nasopharyngeal tumour. Owing to the undifferentiated appearance of neoplastic cells in NPTUC, examples of these lesions may be lumped together with SNUC if one is unaware of their occurrence.[14,15] Indeed, SNUC does not arise in the nasopharynx, but larger tumours may extend to involve this region. The distinction of these entities is important, because NPTUC has a better prognosis and is more responsive to radiation therapy than SNUC. The differential diagnosis between these tumours can generally be made on purely histological grounds, because, in NPTUC, neoplastic cells lack distinct borders, show a syncytial growth pattern, and have markedly vesicular nuclei with prominent nucleoli, and a lymphoplasmacytic cell infiltrate is seen in most cases (Figure 2). Immunohistochemistry and *in-situ* hybridization are of great help in difficult cases. Expression of CK5/6 and CK13 supports the diagnosis of NPTUC, whereas these markers are notably absent in SNUC.[16] Immunohistochemical staining for p63 can also assist in this differential diagnosis, as NPTUC shows strong and diffuse p63 expression, whereas this marker is only focally positive in cases of SNUC.[17,18] Finally, at variance with lymphoepithelioma-like undifferentiated carcinoma of the head and neck at 'ectopic' sites, which is EBV-negative,[19,20] sinonasal NPTUC is constantly positive, making this a useful test for the differential diagnosis with SNUC, which is negative.[14,15] Quite recently, lymphoepithelioma-like undifferentiated carcinoma of the oropharynx and nasopharynx has been shown to be p16-positive and

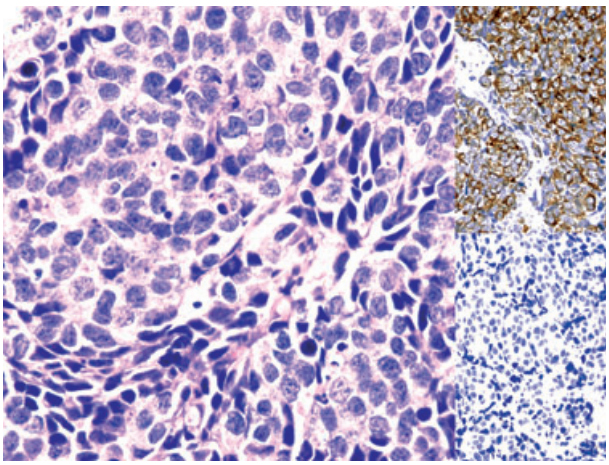

Figure 1. Sinonasal undifferentiated carcinoma. The tumour is composed of sheets and ribbons of undifferentiated round cells, with a high nuclear/cytoplasmic ratio. Tumour cells are positive for cytokeratin 8 (upper right) and negative for cytokeratin 5/6 (lower right).

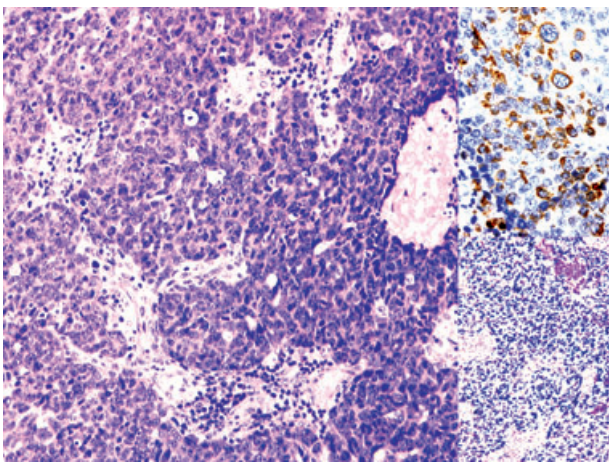

Figure 2. Nasopharyngeal-type undifferentiated carcinoma. The tumour has a syncitial growth pattern, with cells showing indistinct margins and round vesicular nuclei with prominent nucleoli. Numerous lymphocytes are associated with the neoplastic proliferation. Tumour cells are positive for cytokeratin 5/6 (upper right) and for Epstein–Barr virus (EBER-1, lower right).

© 2011 Blackwell Publishing Ltd, *Histopathology*

human papilloma virus (HPV)16-positive by *in-situ* hybridization.[21,22]

SCNEC

SCNEC occurs at various sites in the upper aerodigestive tract, but it quite rarely involves the sinonasal region. It is a highly aggressive tumour that occurs more often in adults.[6,23] Cases following radiation therapy for other head and neck malignancies have been reported in both adult and paediatric patients.[24–26]

Sinonasal SCNEC is histologically indistinguishable from its pulmonary counterpart, being composed of sheets or nests of closely packed cells with inconspicuous cytoplasm and round, oval or spindle nuclei with dense chromatin and absent nucleoli (Figure 3). However, there are lesions that do not fit this definition; these consist of larger cells with round nuclei containing finely dispersed chromatin with conspicuous or small nucleoli, but still showing immunohistochemical and/or ultrastructural evidence of diffuse neuroendocrine differentiation. These tumours have also been referred to as 'non-small-cell neuroendocrine carcinoma'.[27]

Immunohistochemically, SCNEC is positive for CKs (AE1/AE3 and CAM5.2) and neuroendocrine markers such as NSE, synaptophysin, and chromogranin, although with variable frequency.[4,24] Like SCNEC of other sites, sinonasal tumours express CD57.[4,28] These features allow the distinction from SNUC, malignant melanoma, ON, lymphoma, Ewing's sarcoma/PNET, and RMS.

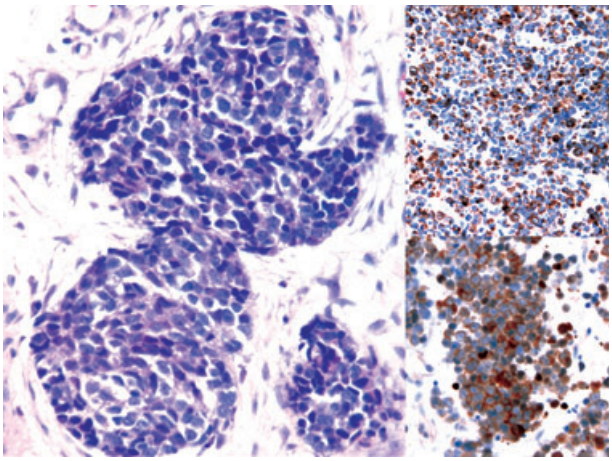

Figure 3. Sinonasal small-cell neuroendocrine carcinoma. The tumour has a nested architecture, and is composed of round cells with scant cytoplasm and round to oval nuclei with stippled chromatin. Dot-like paranuclear immunoreactivity for cytokeratins (upper right) and diffuse positivity for neuron-specific enolase (NSE) (lower right) is observed.

NMC

NMC is a rare, highly aggressive carcinoma that is defined by a translocation involving the *NUT* gene on chromosome 15q14 and, in most cases, the *BRD4* gene on chromosome 19p13.1.[29] The translocation results in a *BRD4–NUT* fusion gene, which encodes for a protein that is thought to be involved in a block of epithelial differentiation and squamous maturation.[30] Initially, cases were reported in young patients affected by intrathoracic carcinomas, but it is now well established that these tumours may occur in adults and involve other anatomical sites of the midline axis. The exact frequency of NMC is currently unknown, but in a recent study it represented 18% of poorly differentiated carcinomas of the upper aerodigestive tract.[31] So far, fewer than 10 cases have been described in the nasal cavity and paranasal sinuses.[29,31,32] These tumours affected young adults of both sexes and showed an aggressive clinical behaviour. However, there is increasing evidence that the distinction of NMC from other sinonasal carcinomas is of clinical relevance, in view of the favourable response to certain treatment regimens, including chemotherapy according to Ewing's sarcoma protocols or docetaxel and radiotherapy.[33,34]

Histologically, NMC is composed of undifferentiated basaloid cells with focal, often abrupt, squamous differentiation (Figure 4). In some instances, squamous differentiation may be more pronounced.[35] The diagnosis of NMC requires the demonstration of the NUT translocation, which can be obtained by karyotyping, reverse transcription polymerase chain reaction, and fluorescence *in-situ* hybridization. Recently, a monoclonal antibody to NUT for use in immunohistochemistry has been developed, and showed a sensitivity of 87%, a specificity of 100%, a negative predictive value of 99% and a positive predictive value of 100% when tested in a large panel of carcinoma tissues.[36] The use of this antibody may help to separate NMC from other poorly differentiated sinonasal carcinomas, thus contributing to their clinicopathological characterization. Other immunohistochemical markers that were found to be consistently positive in NMC are CKs and p63, whereas no immunoreactivity has been observed with muscle, neuroendocrine and melanocytic markers.[37] The presence of HPV and EBV infection has never been identified, by either immunohistochemistry, *in-situ* hybridization, or polymerase chain reaction.[37]

SCC AND VARIANTS

SCC is the most frequent epithelial neoplasm of the sinonasal tract, and occasionally can have a poorly

© 2011 Blackwell Publishing Ltd, *Histopathology*

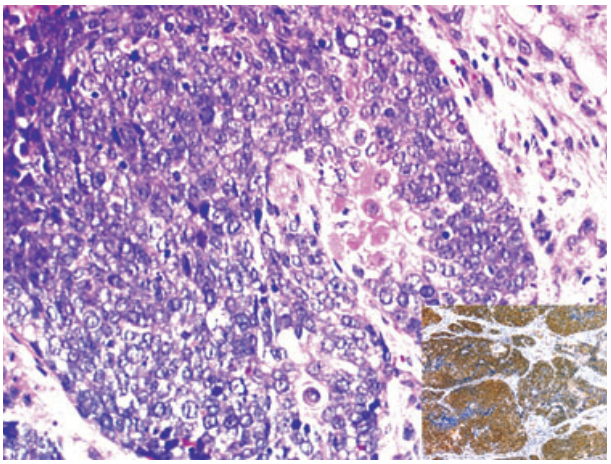

Figure 4. Nuclear protein in testis (NUT) midline carcinoma of the nasal cavity. The lesion is composed of nests of basaloid undifferentiated cells, with focal areas of abrupt keratinization. Diffuse nuclear immunoreactivity is observed with an anti-NUT monoclonal antibody (lower right).

differentiated appearance, with little or no evidence of keratinization in a small biopsy specimen, necessitating differential diagnosis from other carcinomas. Other variants of SCC occurring in the nasal cavities and paranasal sinuses that may have an 'undifferentiated' histological appearance are CCC and basaloid SCC (BSCC). Microscopically, CCC is composed of papillary fronds, thick ribbons and stratified masses of cells that quite often give rise to invaginations of the surface epithelium. The tumour cells are commonly cylindrical, and have a tendency to form palisade arrangements perpendicular to the underlying basement membrane. In poorly differentiated variants, neoplastic cells lose this ordered architecture, and the lesion is formed by ribbons and nests of large polygonal cells. Recent molecular and immunophenotypic studies support the concept that CCC is a distinct entity characterized by a high prevalence of high-risk HPV DNA, overexpression of p16 protein, a high Ki67 labelling index, and negative or low p53 reactivity, whereas conventional sinonasal keratinizing SCC is a tumour more frequently related to cigarette smoking, with a high frequency of p53 anomalies.[38,39]

BSCC is an aggressive SCC variant that rarely involves the sinonasal tract.[40] Histologically, it is characterized by lobules of highly atypical basaloid cells, often displaying peripheral palisading. Squamous differentiation is present, although it may not be readily apparent in small biopsy specimens, making the separation from other carcinomas difficult. Recently, it has been shown that a subset of BSCC of the upper aerodigestive tract is associated with HPV.[41,42] These tumours affect younger patients, have a more favourable outcome, and are strongly associated with immunohistochemical p16 positivity and p53 negativity.[41,42]

All SCC variants are CK-positive, allowing the distinction from non-epithelial neoplasms, and express CK subtypes (CK5/6, CK13, and CK19) that are not expressed by SNUC.[16] Expression of neuroendocrine markers has been reported in BSCC,[28] but distinction from SCNEC can be based on immunostaining for CK34βE12, which is positive in BSCC and negative in SCNEC.[28] P63 immunostaining may be a useful adjunct, as it is positive in SCC variants, but it is weakly or not expressed in SNUC and SCNEC.[17,18]

SCC variants, particularly BSCC, and SCNEC must also be differentiated from ACC with a predominantly solid growth pattern, and from the so-called 'dedifferentiated' variant of ACC.[43] ACC usually shows immunoreactivity for myoepithelial cell markers, including common muscle actin, S100 protein, and calponin. In addition, p63 is consistently expressed by both BSCC and ACC, but whereas immunostaining is diffuse in BSCC, ACC displays a consistently compartmentalized pattern within tumour nests.[44] Conversely, the dedifferentiated component of dedifferentiated ACC is characterized by loss of myoepithelial differentiation, and lacks immunoreactivity for myoepithelial markers.[43]

Non-epithelial neoplasms

SINONASAL MALIGNANT MELANOMA

Sinonasal melanoma represents between 0.5% and 1.5% of all melanomas and between 3% and 20% of sinonasal malignant neoplasms.[45–47] It most frequently develops after the fifth decade of life, and it probably originates from melanocytes present in the mucosa of the respiratory tract.[48] The majority of sinonasal malignant melanomas are pigmented, and diagnosis is usually straightforward. Those amelanotic lesions consisting of sheets or nests of small round to oval cells (Figure 5) may be difficult to distinguish from ON, Ewing's sarcoma/PNET, lymphomas, or undifferentiated carcinomas. Those lesions with epithelioid morphology should be differentiated from epithelioid malignant schwannoma.[49]

Sinonasal melanoma shows positivity for S100 protein and consistent expression of other melanocytic markers, including MART-1/melan-A, tyrosinase, HMB-45, and Mitf.[50] As a study of a large cohort of patients has shown that no marker has a 100% sensitivity, a panel of melanoma markers should be employed to avoid misdiagnosis in occasional cases.[51] In addition, the possibility of positive staining for other

© 2011 Blackwell Publishing Ltd, *Histopathology*

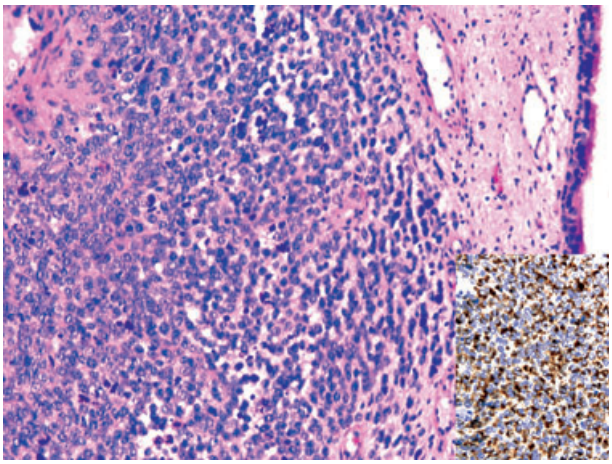

Figure 5. Malignant melanoma of the nasal cavity. A population of undifferentiated round cells, with few pigmented elements, diffusely infiltrates the mucosa. Neoplastic cells are positive for HMB45 (lower right).

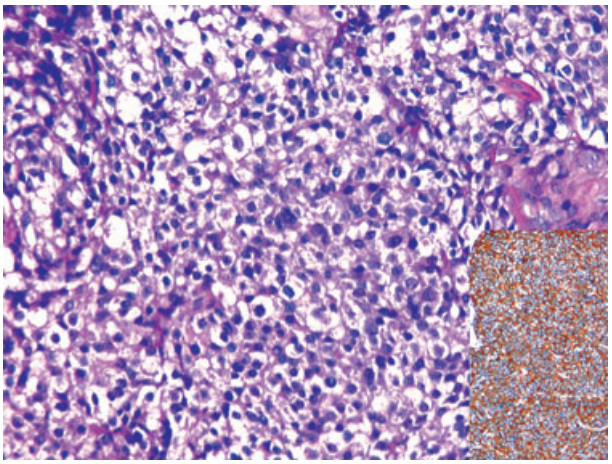

Figure 6. High-grade olfactory neuroblastoma. The tumour is composed of round cells, with mild pleomorphism, which show diffuse staining for synaptophysin (lower right).

markers such as synaptophysin, neurofilaments and CD99 should be kept in mind.[52–54] Ultrastructurally, diagnostic melanin granules can be found in all cases.[55]

ON

ON is an uncommon neoplasm that occurrs over a broad age range, and characteristically originates in the region of the cribriform plate from the olfactory mucosa.[56,57] A diagnosis of 'ectopic' ON, involving other sites of the sinonasal region, requires a critical differential diagnosis, mainly with SNUC, SCNEC, and Ewing's sarcoma/PNET. The correct identification of ON is clinically relevant, in view of the fact that there are excellent local and distant control rates with local therapy alone, whereas SNUC, SCNEC and Ewing's sarcoma/PNET pursue a more aggressive clinical course, requiring the use of combined-modality therapy.[6,58]

More frequently, the tumour grows in nests separated by fibrovascular septa, and the neoplastic cells typically have a uniform appearance, with small and round nuclei containing stippled chromatin, absent or small nucleoli, and scanty cytoplasm. They are embedded in a fibrillary background formed by cell processes. Homer–Wright-type rosettes, or more rarely Flexner rosettes, can be found.

Ancillary techniques are useful for the diagnosis, especially in poorly differentiated lesions (Hyams grade III and IV), in which neoplastic cells may be pleomorphic, mitotic figures may be numerous, there is necrosis, and the neurofibrillary background is absent (Figure 6). Immunohistochemically, ON shows diffuse positivity for NSE and synaptophysin, whereas chromogranin, glial fibrillary acidic protein (GFAP) and leu-7 are less often positive.[59] S100 protein stains sustentacular cells around neoplastic nests, but, in less differentiated tumours, there may be a few scattered S100 protein-positive cells. Neurofilament protein and other markers of neural differentiation are more often expressed in tumours with a diffuse, sheet-like pattern. CKs are generally negative, although, in ON with a nesting pattern, a few tumour cells may exhibit staining for low molecular weight CKs.[60] EMA is consistently negative, as are CD99, CD45, HMB-45 and muscle markers. Ultrastructural analysis shows evidence of neuroblastic differentiation, including the presence of dendritic processes containing dense core granules and neurotubules, and occasional synaptic junctions.[55] ON lacks the t(11; 22) translocation of Ewing's sarcoma/PNET.[61] In addition, ON also lacks the characteristic molecular genetic changes of classic neuroblastoma, which may be metastatic to the sinonasal region in children. In children, ON must also be distinguished from RMS.

EWING'S SARCOMA/PNET

Approximately 9% of cases of extraosseous Ewing's sarcoma/PNET arise in the head and neck region, this being mostly a tumour of children and young adults.[62–65] The great majority of these tumours will react strongly with antibodies against CD99 (MIC-2).[66] This marker is of considerable value but it is by no means specific, as a growing number of other neoplasms expressing this protein have been documented. Among them are lymphomas, melanoma, mesenchymal chondrosarcoma, SNUC, and SCNEC.[24] Other

© 2011 Blackwell Publishing Ltd, *Histopathology*

antibodies that may offer diagnostic support are FLI1 and caveolin 1.[67]

Focal immunoreactivity for CKs can also sometimes be detected. Other markers that may be expressed, according to the degree of neuroectodermal differentiation, are NSE, neurofilaments, synaptophysin, S100 protein, and GFAP. Ultrastructurally, Ewing's sarcoma/PNET may show rudimentary neural differentiation, as well as scanty microtubule formation. The main differential diagnosis is with ON, which is CD99-negative, and with other small round cell tumours, such as RMS and lymphoma. The detection of the standard translocations of Ewing's sarcoma/PNET is useful to confirm the diagnosis and exclude ON.[4,61]

SINONASAL HAEMATOLYMPHOID TUMOURS

Lymphomas

Malignant lymphomas are the most frequent non-epithelial malignancies of the sinonasal region, representing between 6% and 14% of all sinonasal malignancies.[68,69] In western countries, approximately 50% are B-cell lymphomas, and, in this group, diffuse large B-cell lymphoma is the most common.[70–72] The other 50% mostly show a natural killer (NK)/T-cell lineage. Conversely, in oriental populations, the majority of primary lymphomas of the nasal cavity and nasopharynx are of the NK/T-cell lineage.[73–75]

Sinonasal B-cell lymphomas infiltrate and expand the mucosa, and may extend into the underlying bone (Figure 7). They lack epitheliotropism, polymorphous cell infiltrate, angiocentricity, prominent necrosis, and fibrosis. They are usually positive for B-cell markers (CD20 and CD79a) and negative for NK/T-cell markers. Kappa light chain restriction is seen more often than restriction for lambda. EBV markers are negative.

In sinonasal NK/T-cell lymphomas, an angiocentric and angiodestructive infiltrate is frequently seen, composed of small, medium-sized, large or anaplastic cells, sometimes with a conspicuous admixture of inflammatory cells (Figure 8).[76,77] Pseudoepitheliomatous hyperplasia of the covering epithelium may occur, as well as destruction of the mucosal glands. NK/T-cell lymphoma is almost always associated with EBV positivity (EBER-1). The most typical immunophenotype is CD2-positive, CD56-positive, surface CD3-negative, and cytoplasmic CD3ϵ-positive.[77] Most cases are also positive for cytotoxic granule-associated proteins (granzyme B, TIA-1, and perforin). Other T/NK-cell-associated markers are usually negative. Sinonasal lymphomas demonstrating CD3ϵ positivity, CD56 negativity, cytotoxic molecule positivity and EBV positivity are also included within the NK/T-cell category. It should be noted that other non-lymphoid neoplasms of the sinonasal tract might be CD56-positive, including ON, Ewing's sarcoma/PNET, and RMS.[78] However, these entities can be distinguished on the basis of positivity to other markers.

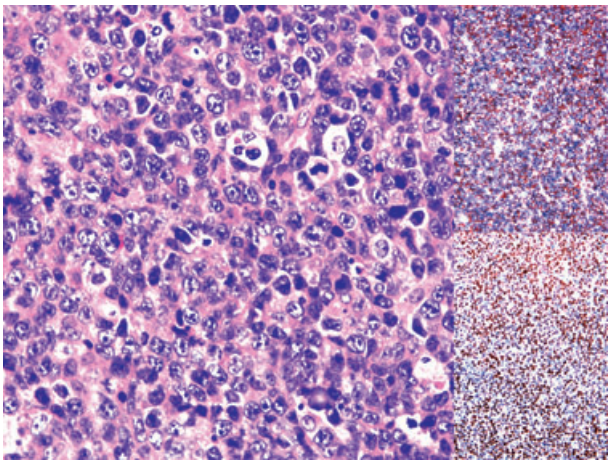

Figure 7. Sinonasal large B-cell lymphoma. The mucosa is infiltrated by a rather uniform population of large pleomorphic cells. The tumour is diffusely positive for CD20 (upper right) and for bcl-6 (lower right).

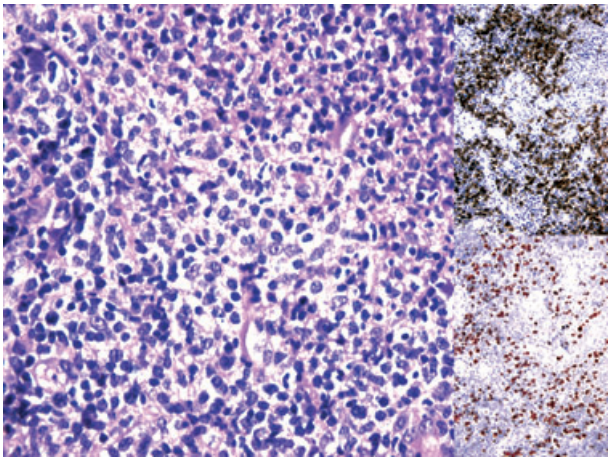

Figure 8. Sinonasal natural killer (NK)/T-cell lymphoma. The infiltrate is composed of lymphocytes of varying size. Some nuclei have an irregular outline. Neoplastic cells are positive for CD56 (upper right) and for Epstein–Barr virus (EBER-1, lower right).

Extramedullary plasmacytoma

Plasmacytoma of the sinonasal tract appears as a diffuse infiltration of neoplastic plasma cells of the mucosa. Occasionally, tumour cells are less differentiated, and the differential diagnosis with other sinonasal

© 2011 Blackwell Publishing Ltd, *Histopathology*

neoplasms may be difficult.[79–82] Immunohistochemical staining for CD38, CD138 and kappa and lambda chains are helpful for the diagnosis.[83]

Granulocytic sarcoma

This is a localized tumour of malignant myeloid cells that can rarely occur in the sinonasal tract.[84,85] It may develop prior to, concurrently with or following the presentation of acute myeloid leukaemia. The mucosa is infiltrated by diffuse sheets of primitive myeloid cells, and the diagnosis can be confirmed with a panel including chloroacetate esterase, myeloperoxidase, lysozyme, and CD43, together with other B-cell and T-cell lineage markers, in particular CD79a and CD3.[86,87] Leder staining for naphthol-AS-D chloroacetate esterase on paraffin sections can also be helpful.

Histiocytic sarcoma

Histiocytic sarcoma is a rare malignant neoplasm that can occasionally involve the nasal cavity.[88,89] Neoplastic cells are large and pleomorphic, with abundant eosinophilic cytoplasm, well-defined cell borders, and ovoid to irregular nuclei with large nucleoli. There is usually an accompanying inflammatory infiltrate, most often of neutrophils or lymphocytes. Neoplastic cells are positive for LCA, CD45RO, CD4, CD68 (KP1 and PG-M1), lysozyme, and CD31.[89]

SARCOMAS

Mesenchymal chondrosarcoma

Mesenchymal chondrosarcoma rarely originates in the sinonasal tract.[90] Microscopically, the lesion displays a small, blue, round cell morphological appearance with a haemangiopericytoma-like pattern. The diagnosis is based on the recognition of foci of cartilaginous matrix formation, which impart a biphasic appearance to the tumour. The pattern of growth and absence of cartilaginous matrix in biopsy material result in frequent misdiagnosis. Tumour cells may be positive for CD99, leading to confusion with other small-cell malignancies, particularly with Ewing's sarcoma/PNET. Recently, it has been shown that immunohistochemical positivity for the master regulator gene *Sox-9* is sensitive and specific for mesenchymal chondrosarcoma, and may be useful in the differential diagnosis with other small round blue cell tumours.[91,92]

RMS

RMS is the most common sinonasal malignancy among paediatric patients, but it is also observed in adults.[93–95] The most common histological subtypes are the embryonal and the alveolar. A clear cell variant has also been described.[96] The diagnosis of poorly differentiated forms requires immunohistochemical analysis for myogenin and desmin.[4] At the ultrastructural level, the diagnostic features are rudimentary sarcomeres and other markers of skeletal muscle differentiation, such as the ribosome–filaments complexes. Alveolar RMS has a characteristic translocation t(2;13)(q35;q14) fusing the *PAX3* and *FKHR* genes, which is particularly useful for distinguishing the solid variant from embryonal RMS.[4]

Poorly differentiated synovial sarcoma

Involvement of the sinonasal tract by synovial sarcoma is exceedingly rare, but this tumour can be considered in the differential diagnosis of undifferentiated primary neoplasms of this region, because it may assume a round cell Ewing-like morphology.[97,98] Detection of immunohistochemical positivity for CKs and EMA, which is usually focal in poorly differentiated lesions, and detection of the *SS18* gene rearrangement are necessary to confirm the diagnosis.[98]

Desmoplastic small round cell tumour

This is a tumour of uncertain histogenesis that most commonly occurs in the abdominal cavity, but sporadic cases have been reported in other locations, including the sinonasal region.[99] In this anatomical location, the differential diagnosis includes SNUC, ON, lymphoma, Ewing's sarcoma, and embryonal and alveolar RMS.[99] Desmoplastic small round cell tumour consistently shows a t(11;22) (p13;q12) translocation, involving the Wilms' tumour suppressor gene (*WT1*) and the Ewing's sarcoma gene (*EWS*). The lesion is composed of islands of round cells, separated by varying amounts of desmoplastic stroma. The immunophenotype is characteristic, with multidirectional differentiation resulting in coexpression of epithelial (keratins and EMA), mesenchymal (vimentin and desmin) and neural (NSE and CD56) markers. With antibodies against the C-terminus, nuclear positivity for *WT1* can be detected in tumour cells.

Summary and conclusions

The sinonasal region hosts a variety of tumours with a 'undifferentiated' light microscopic appearance, in which careful morphological study and the use of ancillary techniques is essential for an accurate diagnosis. Clinical data, including anatomical localization, and age and sex of the patient, may also provide relevant diagnostic information. For example, a diagnosis of ON is highly unlikely for a tumour occurring outside the cribriform plate area, whereas the differential diagnosis of a sinonasal undifferentiated

© 2011 Blackwell Publishing Ltd, *Histopathology*

malignancy in the paediatric age group mainly includes RMS and Ewing's sarcoma/PNET.

Immunohistochemistry has proven to be an extremely powerful tool in the analysis of undifferentiated sinonasal malignancies, and remains the main additional technique for the identification of specific tumour categories and for the classification of these neoplasms. Through careful microscopic examination of haematoxylin and eosin-stained sections in the light of clinical information, a list of differential diagnoses can be made and an appropriate panel of antibodies can be chosen to further categorize the tumour. An initial panel including CKs, synaptophysin, S100 protein, desmin and CD45 may allow the classification of most lesions or may help to narrow the list of differential diagnoses (Table 2). Further refinement can be obtained through second-line markers, including *in-situ* hybridization for EBV, other neuroendocrine markers, melanocytic markers, myogenin, CD99, other lymphocyte markers, and CD138 and light chains. The main limit of immunohistochemistry remains the lack of specificity of some markers.

The ultrastructural examination of neoplasms with undifferentiated morphology on light microscopy is always advisable and can furnish highly valuable data. Electron microscopy can complement the light microscopic diagnosis and the immunohistochemical findings or, in a significant number of cases, can allow the establishment of a definitive diagnosis identifying subcellular organelles, structures and/or products that are not otherwise recognizable. Distinctive filamentous structures (keratin filaments, myofilaments, and microtubules), deposits (glycogen), organelles (secretory or neurosecretory granules, melanosomes, and well-developed endoplasmic reticulum) and membrane specializations (desmosomes, microvilli, and basal lamina) are the features that help in the differential diagnosis at the ultrastructural level.

Table 2. Summary of markers useful in the differential diagnosis of selected histological subtypes of undifferentiated sinonasal neoplasm

	CK	SYN	S100	CD45	Desmin	EBV	Molecular diagnostics
Sinonasal undifferentiated carcinoma	7+, 8+, 5/6–, 13–	– (focal +)	–	–	–	–	–
Nasopharymgeal-type undifferentiated carcinoma	Pan+, 5/6+, 13+	–	–	–	–	+	–
Small-cell neuroendocrine carcinoma	Pan+, 5/6–	+	–	–	–	–	–
Basaloid squamous cell carcinoma	Pan+, 5/6+	–	–	–	–	–	–
NUT midline carcinoma	Pan+, 7+	–	–	–	–	–	t(15;19)
Olfactory neuroblastoma	– (rarely focal +)	+	Sustentacular cells	–	–	–	–
Melanoma	– (rarely focal +)	– (rarely +)	+	–	–	–	–
Lymphoma	–	–	–	+	–	+ in NK/T cell	–
Rhadomyosarcoma	– (rarely focal +)	–	–	–	+	–	t(2;13) alveolar
Ewing's sarcoma	– (rarely focal +)	– (focal +)	– (focal +)	–	–	–	t(11;22)

CK, Cytokeratin; EBV, Epstein–Barr virus; NK, natural killer; NUT, nuclear protein in testis; Pan, pancytokeratin; SYN, synaptophysin.

© 2011 Blackwell Publishing Ltd, *Histopathology*

Finally, molecular markers are becoming increasingly important for the correct diagnosis of selected undifferentiated sinonasal tumours, because they allow the identification of entities for which other diagnostic criteria may not be sufficiently specific, such as NMC, Ewing's sarcoma, alveolar RMS, poorly differentiated synovial sarcoma, and desmoplastic small round cell tumour.

References

1. Barnes L, Brandwein M, Som PM. Disease of the nasal cavities, paranasal sinuses and nasopharynx. In Barnes L ed. *Surgical pathology of the head and neck*, 2nd edn. New York: Marcel Dekker, 2001; 439–555.
2. Franchi A, Miligi L, Palomba A, Giovannetti L, Santucci M. Sinonasal carcinomas: recent advances in molecular and phenotypic characterization and their clinical implications. *Crit. Rev. Oncol. Hematol.* 2010; Epub ahead of print.
3. Mills SE, Fechner RE. 'Undifferentiated' neoplasms of the sinonasal region: differential diagnosis based on clinical, light microscopic, immunohistochemical, and ultrastructural features. *Semin. Diagn. Pathol.* 1989; **6;** 316–328.
4. Cordes B, Williams MD, Tirado Y *et al.* Molecular and phenotypic analysis of poorly differentiated sinonasal neoplasms: an integrated approach for early diagnosis and classification. *Hum. Pathol.* 2009; **40;** 283–292.
5. Wenig BM. Undifferentiated malignant neoplasms of the sinonasal tract. *Arch. Pathol. Lab. Med.* 2009; **133;** 699–712.
6. Rosenthal DI, Barker JL, El-Naggar AK *et al.* Sinonasal malignancies with neuroendocrine differentiation. Patterns of failure according to the histologic phenotype. *Cancer* 2004; **101;** 2567–2573.
7. Dulguerov P, Jacobsen MS, Allal AS, Lehmann W, Calcaterra T. Nasal and paranasal sinus carcinoma: are we making progress? A series of 220 patients and a systematic review. *Cancer* 2001; **92;** 3012–3029.
8. Lin EM, Sparano A, Spalding A *et al.* Sinonasal undifferentiated carcinoma: a 13-year experience at a single institution. *Skull Base* 2010; **20;** 61–67.
9. Frierson HF, Mills SE, Fechner RE, Taxy JB, Levine PA. Sinonasal undifferentiated carcinoma. An aggressive neoplasm derived from Schneiderian epithelium and distinct from olfactory neuroblastoma. *Am. J. Surg. Pathol.* 1986; **10;** 771–779.
10. Helliwell TR, Yeoh LH, Stell PM. Anaplastic carcinoma of the nose and paranasal sinuses. Light microscopy, immunohistochemistry, and clinical correlation. *Cancer* 1986; **58;** 2038–2045.
11. Stewart FM, Lazarus HM, Levine PA, Stewart KA, Tabbara IA, Spaulding CA. High-dose chemotherapy and autologous marrow transplantation for esthesioneuroblastoma and sinonasal undifferentiated carcinoma. *Am. J. Clin. Oncol.* 1989; **12;** 217–221.
12. Houston GD, Gillies E. Sinonasal undifferentiated carcinoma: a distinctive clinicopathologic entity. *Adv. Anat. Pathol.* 1999; **6;** 317–323.
13. Gorelick J, Ross D, Marentette L, Blaivas M. Sinonasal undifferentiated carcinoma: case series and review of the literature. *Neurosurgery* 2000; **47;** 750–754.
14. Cerilli LA, Holst VA, Brandwein MS, Stoler MH, Mills SE. Sinonasal undifferentiated carcinoma. Immunohistochemical profile and lack of EBV association. *Am. J. Surg. Pathol.* 2001; **25;** 156–163.
15. Jeng YM, Sung MT, Fang CL *et al.* Sinonasal undifferentiated carcinoma and nasopharyngeal-type undifferentiated carcinoma. Two clinically, biologically, and histopathologically distinct entities. *Am. J. Surg. Pathol.* 2002; **26;** 371–376.
16. Franchi A, Moroni M, Massi D, Paglierani M, Santucci M. Sinonasal undifferentiated carcinoma, nasopharyngeal-type undifferentiated carcinoma, and keratinizing and nonkeratinizing squamous cell carcinoma express different cytokeratin patterns. *Am. J. Surg. Pathol.* 2002; **26;** 1597–1604.
17. Bourne TD, Bellizzi AM, Stelow EB *et al.* p63 expression in olfactory neuroblastoma and other small cell tumors of the sinonasal tract. *Am. J. Clin. Pathol.* 2008; **130;** 213–218.
18. Chapman-Fredricks J, Jorda M, Gomez-Fernandez C. A limited immunohistochemical panel helps differentiate small cell epithelial malignancies of the sinonasal cavity and nasopharynx. *Appl. Immunohistochem. Mol. Morphol.* 2009; **17;** 207–210.
19. MacMillan C, Kapadia SB, Finkelstein SD *et al.* Lymphoepithelial carcinoma of the larynx and hypopharynx: study of eight cases with relationship to Epstein–Barr virus (EBV) and p53 gene alterations, and review of the literature. *Hum. Pathol.* 1996; **27;** 1172–1179.
20. Ferlito A, Weiss LM, Rinaldo A *et al.* Lymphoepithelial carcinoma of the larynx, hypopharynx, and trachea. *Ann. Otol. Rhinol. Laryngol.* 1997; **106;** 437–444.
21. Singhi AD, Stelow EB, Mills SE, Westra WH. Lymphoepithelial-like carcinoma of the oropharynx: a morphologic variant of HPV-related head and neck carcinoma. *Am. J. Surg. Pathol.* 2010; **34;** 800–805.
22. Maxwell JH, Kumar B, Feng FY *et al.* HPV-positive/p16-positive/EBV-negative nasopharyngeal carcinoma in white North Americans. *Head Neck* 2010; **32;** 562–567.
23. Perez-Ordonez B, Caruana SM, Huvos AG, Shah JP. Small cell neuroendocrine carcinoma of the nasal cavity and paranasal sinuses. *Hum. Pathol.* 1998; **29;** 826–832.
24. Chen CL, Hsu MM. Second primary epithelial malignancy of nasopharynx and nasal cavity after successful curative radiation therapy of nasopharyngeal carcinoma. *Hum. Pathol.* 2000; **31;** 227–232.
25. Wang CP, Hsieh CY, Chang YL *et al.* Postirradiated neuroendocrine carcinoma of the sinonasal tract. *Laryngoscope* 2008; **118;** 804–809.
26. Franchi A, Sardi I, Cetica V *et al.* Pediatric sinonasal neuroendocrine carcinoma after treatment of retinoblastoma. *Hum. Pathol.* 2009; **40;** 750–755.
27. Weinreb I, Perez-Ordonez B. Non-small cell neuroendocrine carcinoma of the sinonasal tract and nasopharynx. Report of 2 cases and review of the literature. *Head Neck Pathol.* 2007; **1;** 21–26.
28. Morice WG, Ferreiro JA. Distinction of basaloid squamous cell carcinoma from adenoid cystic and small cell undifferentiated carcinoma by immunohistochemistry. *Hum. Pathol.* 1998; **29;** 609–612.
29. French CA, Kutok JL, Faquin WC *et al.* Midline carcinoma of children and young adults with NUT rearrangement. *J. Clin. Oncol.* 2004; **22;** 4135–4139.
30. French CA, Ramirez CL, Kolmakova J *et al.* BRD-NUT oncoproteins: a family of closely related nuclear proteins that block epithelial differentiation and maintain the growth of carcinoma cells. *Oncogene* 2008; **27;** 2237–2242.
31. Stelow EB, Bellizzi AM, Taneja K *et al.* NUT rearrangement in undifferentiated carcinomas of the upper aerodigestive tract. *Am. J. Surg. Pathol.* 2008; **32;** 828–834.

© 2011 Blackwell Publishing Ltd, *Histopathology*

32. Hsieh MS, French CA, Liang CW, Hsiao CH. NUT midline carcinoma: case report and review of the literature. *Int. J. Surg. Pathol.* 2009; Epub ahead of print.
33. Mertens F, Wiebe T, Adlercreutz C, Mandahl N, French CA. Successful treatment of a child with t(15;19)-positive tumor. *Pediatr. Blood Cancer* 2007; **49;** 1015–1017.
34. Engleson J, Soller M, Panagopoulos I, Dahlén A, Dictor M, Jerkeman M. Midline carcinoma with t(15;19) and BRD4–NUT fusion oncogene in a 30-year-old female with response to docetaxel and radiotherapy. *BMC Cancer* 2006; **6;** 69.
35. French CA. Demystified molecular pathology of NUT midline carcinomas. *J. Clin. Pathol.* 2010; **63;** 492–496.
36. Haack H, Johnson LA, Fry CJ *et al.* Diagnosis of NUT midline carcinoma using a NUT-specific monoclonal antibody. *Am. J. Surg. Pathol.* 2009; **33;** 984–991.
37. Stelow EB, French CA. Carcinomas of the upper aerodigestive tract with rearrangement of the nuclear protein of the testis (NUT) gene (NUT midline carcinomas). *Adv. Anat. Pathol.* 2009; **16;** 92–96.
38. El-Mofty SK, Lu DW. Prevalence of high-risk human papillomavirus DNA in nonkeratinizing (cylindrical cell) carcinoma of the sinonasal tract: a distinct clinicopathologic and molecular disease entity. *Am. J. Surg. Pathol.* 2005; **29;** 1367–1372.
39. Alos L, Moyano S, Nadal A *et al.* Human papilloma viruses are identified in a subgroup of sinonasal squamous cell carcinomas with favorable outcome. *Cancer* 2009; **115;** 2701–2709.
40. Wieneke JA, Thompson LD, Wenig BM. Basaloid squamous cell carcinoma of the sinonasal tract. *Cancer* 1999; **85;** 841–854.
41. Begum S, Westra WH. Basaloid squamous cell carcinoma of the head and neck is a mixed variant that can be further resolved by HPV status. *Am. J. Surg. Pathol.* 2008; **32;** 1044–1050.
42. Chernock RD, Lewis JS Jr, Zhang Q, El-Mofty SK. Human papillomavirus-positive basaloid squamous cell carcinomas of the upper aerodigestive tract: a distinct clinicopathologic and molecular subtype of basaloid squamous cell carcinoma. *Hum. Pathol.* 2010; **41;** 1016–1023.
43. Nagao T, Gaffey TA, Serizawa H *et al.* Dedifferentiated adenoid cystic carcinoma: a clinicopathologic study of 6 cases. *Mod. Pathol.* 2003; **16;** 1265–1272.
44. Emanuel P, Wang B, Wu M, Burstein DE. p63 Immunohistochemistry in the distinction of adenoid cystic carcinoma from basaloid squamous cell carcinoma. *Mod. Pathol.* 2005; **18;** 645–650.
45. Batsakis JG, Regezi JA, Solomon AR, Rice DH. The pathology of head and neck tumors: mucosal melanomas. *Head Neck Surg.* 1982; **4;** 404–418.
46. Franquemont DW, Mills SE. Sinonasal malignant melanoma. A clinicopathologic and immunohistochemical study of 14 cases. *Am. J. Clin. Pathol.* 1991; **96;** 689–697.
47. Lund V. Malignant melanoma of the nasal cavity and paranasal sinuses. *J. Laryngol. Otol.* 1982; **96;** 347–355.
48. Zak FG, Lawson W. The presence of melanocytes in the nasal cavity. *Ann. Otol. Rhinol. Laryngol.* 1974; **83;** 515–519.
49. Fernandez PL, Cardesa A, Bombì JA, Palacin A, Traserra J. Malignant sinonasal epithelioid schwannoma. *Virchows Arch. A Pathol. Anat. Histopathol.* 1993; **423;** 401–405.
50. Prasad ML, Jungbluth AA, Iversen K, Huvos AG, Busam KJ. Expression of melanocytic differentiation markers in malignant melanomas of the oral and sinonasal mucosa. *Am. J. Surg. Pathol.* 2001; **25;** 782–787.
51. Thompson LD, Wieneke JA, Miettinen M. Sinonasal tract and nasopharyngeal melanomas: a clinicopathologic study of 115 cases with a proposed staging system. *Am. J. Surg. Pathol.* 2003; **27;** 594–611.
52. Coli A, Giacomini PG, Bigotti G *et al.* Aberrant neurofilament protein and synaptophysin expression in malignant melanoma of the nasal cavity. *Histopathology* 2004; **44;** 193–195.
53. Eyden B, Pandit D, Banerjee SS. Malignant melanoma with neuroendocrine differentiation: clinical, histological, immunohistochemical and ultrastructural features of three cases. *Histopathology* 2005; **47;** 402–409.
54. Lee H, Torres FX, McLean SA, Chen R, Lee MW. Immunophenotypic heterogeneity of primary sinonasal melanoma with aberrant expression of neuroendocrine markers and calponin. *Appl. Immunohistochem. Mol. Morphol.* 2011; **19;** 48–53.
55. Min KW. Usefulness of electron microscopy in the diagnosis of ''small'' round cell tumors of the sinonasal region. *Ultrastruct. Pathol.* 1995; **19;** 347–363.
56. Mills SE, Frierson HF. Olfactory neuroblastoma. A clinicopathologic study of 21 cases. *Am. J. Surg. Pathol.* 1985; **9;** 317–327.
57. Dulguerov P, Allal AS, Calcaterra TC. Esthesioneuroblastoma: a meta analysis and review. *Lancet Oncol.* 2001; **2;** 683–690.
58. Kane AJ, Sughrue ME, Rutkowski MJ *et al.* Posttreatment prognosis of patients with esthesioneuroblastoma. *J. Neurosurg.* 2010; **113;** 340–351.
59. Frierson HF, Ross GW, Mills SE, Frankfurter A. Olfactory neuroblastoma. Additional immunohistochemical characterization. *Am. J. Clin. Pathol.* 1990; **94;** 547–553.
60. Devaney K, Wenig BM, Abbondanzo SL. Olfactory neuroblastoma and other round cell lesions of the sinonasal region. *Mod. Pathol.* 1996; **9;** 658–663.
61. Argani P, Perez-Ordonez B, Xiao H, Caruana SM, Huvos AG, Ladanyi M. Olfactory neuroblastoma is not related to the Ewing family of tumours. Absence of EWS/FLI1 gene fusion and MIC2 expression. *Am. J. Surg. Pathol.* 1998; **22;** 391–398.
62. Allam A, El-Husseiny G, Khafaga Y *et al.* Ewing's sarcoma of the head and neck: a retrospective analysis of 24 cases. *Sarcoma* 1999; **3;** 11–15.
63. Raney RB, Asmar L, Vassilopoulou-Sellin R *et al.* Late complications of therapy in 213 children with localized, nonorbital soft-tissue sarcoma of the head and neck: a descriptive report from the Intergroup Rhabdomyosarcoma Studies (IRS)-II and –III. IRS Group of the Children's Cancer Group and the Pediatric Oncology Group. *Med. Pediatr. Oncol.* 1999; **33;** 362–371.
64. Windfuhr JP. Primitive neuroectodermal tumour of the head and neck: incidence, diagnosis and management. *Ann. Otol. Rhinol. Laryngol.* 2004; **113;** 533–543.
65. Whaley JT, Indelicato DJ, Morris CG *et al.* Ewing tumors of the head and neck. *Am. J. Clin. Oncol.* 2010; **33;** 321–326.
66. Weidner N, Tjoe J. Immunohistochemical profile of monoclonal antibody O13: antibody that recognizes glycoprotein p30/32MIC2 and is useful in diagnosing Ewing's sarcoma and peripheral neuroepithelioma. *Am. J. Surg. Pathol.* 1994; **18;** 486–494.
67. Llombart-Bosch A, Machado I, Navarro S *et al.* Histological heterogeneity of Ewing's sarcoma/PNET: an immunohistochemical analysis of 415 genetically confirmed cases with clinical support. *Virchows Arch.* 2009; **455;** 397–411.
68. Kapadia SB, Barnes L, Deutsch M. Non-Hodgkin's lymphoma of the nose and paranasal sinuses: a study of 17 cases. *Head Neck Surg.* 1981; **3;** 490–499.
69. Harbo G, Grau C, Bundgaard T *et al.* Cancer of the nasal cavity and paranasal sinuses. A clinico-pathological study of 277 patients. *Acta Oncol.* 1997; **36;** 45–50.
70. Abbondanzo SL, Wenig BM. Non-Hodgkin's lymphoma of the sinonasal tract. A clinicopathologic and immunophenotypic study of 120 cases. *Cancer* 1995; **75;** 1281–1291.

© 2011 Blackwell Publishing Ltd, *Histopathology*

71. Oprea C, Cainap C, Azoulay R *et al.* Primary diffuse large B-cell non-Hodgkin lymphoma of the paranasal sinuses: a report of 14 cases. *Br. J. Haematol.* 2005; **131;** 468–471.
72. Campo E, Cardesa A, Alos L *et al.* Non-Hodgkin's lymphomas of nasal cavity and paranasal sinuses. An immunohistochemical study. *Am. J. Clin. Pathol.* 1991; **96;** 184–190.
73. Chan JK. Natural killer cell neoplasms. *Anat. Pathol.* 1998; **3;** 77–145.
74. Cheung MM, Chan JK, Lau WH *et al.* Primary non-Hodgkin's lymphoma of the nose and nasopharynx: clinical features, tumor immunophenotype, and treatment outcome in 113 patients. *J. Clin. Oncol.* 1998; **16;** 70–77.
75. Siu LL, Chan V, Chan JK, Wong KF, Liang R, Kwong YL. Consistent patterns of allelic loss in natural killer cell lymphoma. *Am. J. Pathol.* 2000; **157;** 1803–1809.
76. Gaal K, Sun NCJ, Hernandez AM, Arber DA. Sinonasal NK/T-cell lymphomas in the United States. *Am. J. Surg. Pathol.* 2000; **24;** 1511–1517.
77. Harabuchi Y, Takahara M, Kishibe K, Moriai S, Nagato T, Ishii H. Nasal natural killer (NK)/T-cell lymphoma: clinical, histological, virological, and genetic features. *Int. J. Clin. Oncol.* 2009; **14;** 181–190.
78. Liu Q, Ohshima K, Sumie A, Suzushima H, Iwasaki H, Kikuchi M. Nasal CD56 positive small round cell tumors. Differential diagnosis of hematological, neurogenic, and myogenic neoplasms. *Virchows Arch.* 2001; **438;** 271–279.
79. Castro EB, Lewis JS, Strong EW. Plasmacytoma of paranasal sinuses and nasal cavity. *Arch. Otolaryngol.* 1973; **97;** 326–329.
80. Abemayor E, Canalis RF, Greenberg P, Wortham DG, Rowland JP, Sun NC. Plasma cell tumors of the head and neck. *J. Otolaryngol.* 1988; **17;** 376–381.
81. Navarrete ML, Quesada P, Pellicer M, Ruiz C. Extramedullary nasal plasmacytoma. *J. Laryngol. Otol.* 1991; **105;** 41–43.
82. Aguilera NS, Kapadia SB, Nalesnik MA, Swerdlow SH. Extramedullary plasmacytoma of the head and neck: use of paraffin sections to assess clonality with in situ hybridization, growth fraction, and the presence of Epstein–Barr virus. *Mod. Pathol.* 1995; **8;** 503–508.
83. Bachar G, Goldstein D, Brown D *et al.* Solitary extramedullary plasmacytoma of the head and neck—long-term outcome analysis of 68 cases. *Head Neck* 2008; **30;** 1012–1019.
84. Prades JM, Alaani A, Mosnier JF, Dumollard JM, Martin C. Granulocytic sarcoma of the nasal cavity. *Rhinology* 2002; **40;** 159–161.
85. Gorman M, Ahmed KA, Pallera A, Samant S. Granulocytic sarcoma of the nasal cavity: a case report. *Ear Nose Throat J.* 2009; **88;** 1210–1212.
86. Roth MJ, Medeiros LJ, Elenitoba-Johnson K, Kuchnio M, Jaffe ES, Stetler-Stevenson M. Extramedullary myeloid cell tumors. An immunohistochemical study of 29 cases using routinely fixed and processed paraffin-embedded tissue sections. *Arch. Pathol. Lab. Med.* 1995; **119;** 790–798.
87. Menasce LP, Banerjee SS, Beckett E, Harris M. Extra-medullary myeloid tumour (granulocytic sarcoma) is often misdiagnosed: a study of 26 cases. *Histopathology* 1999; **34;** 391–398.
88. Pileri SA, Grogan TM, Harris NL *et al.* Tumours of histiocytes and accessory dendritic cells: an immunohistochemical approach to classification from the International Lymphoma Study Group based on 61 cases. *Histopathology* 2002; **41;** 1–29.
89. Hornick JL, Jaffe ES, Fletcher CD. Extranodal histiocytic sarcoma: clinicopathologic analysis of 14 cases of a rare epithelioid malignancy. *Am. J. Surg. Pathol.* 2004; **28;** 1133–1144.
90. Knott PD, Gannon FH, Thompson LD. Mesenchymal chondrosarcoma of the sinonasal tract: a clinicopathological study of 13 cases with a review of the literature. *Laryngoscope* 2003; **113;** 783–790.
91. Wehrli BM, Huang W, De Crombrugghe B, Ayala AG, Czerniak B. Sox9, a master regulator of chondrogenesis, distinguishes mesenchymal chondrosarcoma from other small blue round cell tumors. *Hum. Pathol.* 2003; **34;** 263–269.
92. Fanburg-Smith JC, Auerbach A, Marwaha JS, Wang Z, Rushing EJ. Reappraisal of mesenchymal chondrosarcoma: novel morphologic observations of the hyaline cartilage and endochondral ossification and beta-catenin, Sox9, and osteocalcin immunostaining of 22 cases. *Hum. Pathol.* 2010; **41;** 653–662.
93. Callender TA, Weber RS, Janjan N *et al.* Rhabdomyosarcoma of the nose and paranasal sinuses in adults and children. *Otolaryngol. Head Neck Surg.* 1995; **112;** 252–257.
94. Herrmann BW, Sotelo-Avila C, Eisenbeis JF. Pediatric sinonasal rhabdomyosarcoma: three cases and a review of the literature. *Am. J. Otolaryngol.* 2003; **24;** 174–180.
95. Hicks J, Flaitz C. Rhabdomyosarcoma of the head and neck in children. *Oral Oncol.* 2002; **38;** 450–459.
96. Chan JK, Ng HK, Wan KY, Tsao SY, Leung TW, Tse KC. Clear cell rhabdomyosarcoma of the nasal cavity and paranasal sinuses. *Histopathology* 1989; **14;** 391–399.
97. Harb WJ, Luna MA, Patel SR, Ballo MT, Roberts DB, Sturgis EM. Survival in patients with synovial sarcoma of the head and neck: association with tumor location, size, and extension. *Head Neck* 2007; **29;** 731–740.
98. Al-Daraji W, Lasota J, Foss R, Miettinen M. Synovial sarcoma involving the head. Analysis of 36 cases with predilection to the parotid and temporal regions. *Am. J. Surg. Pathol.* 2009; **33;** 1494–1503.
99. Finke NM, Lae ME, Lloyd RV, Gehani SK, Nascimento AG. Sinonasal desmoplastic small round cell tumor: a case report. *Am. J. Surg. Pathol.* 2002; **26;** 799–803.

© 2011 Blackwell Publishing Ltd, *Histopathology*