



UNIVERSITÀ
DEGLI STUDI
FIRENZE

FLORE

Repository istituzionale dell'Università degli Studi di Firenze

The effect of the hormonal milieu of pregnancy on deep infiltrating endometriosis: serial ultrasound assessment of changes in size and

Questa è la Versione finale referata (Post print/Accepted manuscript) della seguente pubblicazione:

Original Citation:

The effect of the hormonal milieu of pregnancy on deep infiltrating endometriosis: serial ultrasound assessment of changes in size and pattern of deep endometriotic lesions / Coccia ME; Rizzello F; Palagiano A; Scarselli G. - In: EUROPEAN JOURNAL OF OBSTETRICS, GYNECOLOGY, AND REPRODUCTIVE BIOLOGY. - ISSN 0301-2115. - ELETTRONICO. - 160:(2012), pp. 35-39. [10.1016/j.ejogrb.2011.10.004]

Availability:

This version is available at: 2158/653396 since:

Published version:

DOI: 10.1016/j.ejogrb.2011.10.004

Terms of use:

Open Access

La pubblicazione è resa disponibile sotto le norme e i termini della licenza di deposito, secondo quanto stabilito dalla Policy per l'accesso aperto dell'Università degli Studi di Firenze (<https://www.sba.unifi.it/upload/policy-oa-2016-1.pdf>)

Publisher copyright claim:

(Article begins on next page)



The effect of the hormonal milieu of pregnancy on deep infiltrating endometriosis: serial ultrasound assessment of changes in size and pattern of deep endometriotic lesions

Maria Elisabetta Coccia^{a,*}, Francesca Rizzello^b, Antonio Palagiano^c, Gianfranco Scarselli^a

^a Department of Science for the Woman and Child's Health, University of Florence, via Ippolito Nievo, 2, 50100 Florence, Italy

^b Department of Medical Pathophysiology, Sapienza University of Rome, Rome, Italy

^c Department of Obstetrics, Gynecology, and Reproductive Sciences, Second University of Naples, Italy

ARTICLE INFO

Article history:

Received 31 May 2011

Received in revised form 28 August 2011

Accepted 12 October 2011

Keywords:

Deep infiltrating endometriosis (DIE)

Ultrasound

Pregnancy

Recto-vaginal endometriosis

ABSTRACT

Background: Deep infiltrating endometriosis (DIE) is associated with severe painful symptoms and represents a complex management challenge.

Objective: To analyse the effect of pregnancy on deep infiltrating lesions and related symptomatology. **Study design:** As part of a longitudinal study performed over the past 3 years to determine the efficacy of hormonal treatment in treating women with DIE, we identified three cases of advanced pelvic endometriosis, all with DIE (deep recto-vaginal and recto-sigmoid involvement) where patients achieved spontaneous pregnancies. They were followed up by transvaginal ultrasound (TV-US). The main outcome measures were analysis of the size and echographic pattern of deep infiltrating lesions of endometriosis and evaluation of clinical symptoms during pregnancy.

Results: We observed modifications in lesion size and pattern. In the two patients observed in the third trimester, the lesions were more homogeneous with less evident limits of nodules and band-like echoes, less fibrotic-like. All patients showed complete resolution of symptoms during pregnancy.

Conclusions: The hormonal environment produced by pregnancy might determine significant modifications of endometriotic lesions and reduce painful symptoms. As surgery for DIE is difficult, complex and can lead to major complications, the achievement of a pregnancy-specific hormonal state, through pregnancy or hormonal treatment, may be a valid option in selected cases.

© 2011 Elsevier Ireland Ltd. All rights reserved.

1. Introduction

Endometriosis is a very common disease affecting up to 10% of reproductive age women [1]. A higher prevalence of endometriosis is reported in infertile women, with estimates ranging from 25 to 50% [2]. Although endometriosis is one of the most studied conditions in gynaecology today, it still represents an enigmatic disease [3]. In addition, there are contradictory opinions about the overall clinical management.

Deep infiltrating endometriosis (DIE) is a particular form of endometriosis that penetrates into the retroperitoneal space or the wall of the pelvic organs to a depth of at least 5 mm, strongly associated with severe pelvic pain and deep dyspareunia [4]. Its distribution is typically multifocal and represents a complex management challenge.

The benefits of pregnancy on the progression and recurrence of endometriosis are widely recognized. Some evidence suggests that early pregnancy may be prophylactic against the development of

endometriosis and could actually reduce the risk of recurrence of such lesions [5]. Other reports show the potential occurrence of serious and unexpected complications of the disease during pregnancy [6]. The purpose of this study was to report the first series showing the effect of pregnancy on DIE lesions and related symptomatology.

2. Materials and methods

As part of a longitudinal study performed over the past 3 years to determine the efficacy of hormonal treatment in treating women with DIE, we identified three cases of advanced pelvic endometriosis, all with DIE (deep recto-vaginal and recto-sigmoid involvement) where patients achieved spontaneous pregnancies. They were followed up by transvaginal ultrasound (TV-US). The main outcome measures were analysis of the size and echographic pattern of deep infiltrating lesions of endometriosis and evaluation of clinical symptoms during pregnancy.

The maximum longitudinal, anteroposterior and transversal axes of the implants were measured. Painful symptoms were rated on the basis of a 10-cm visual analogue scale (VAS).

* Corresponding author. Tel.: +39 335 6346293; fax: +39 055 88431171.

E-mail address: cocciamet@tin.it (M.E. Coccia).

3. Results

3.1. Case 1

A 33-year-old Caucasian woman was referred to the Gynaecological Ultrasound Centre of the Department of Science for the Woman and Child's Health, University of Florence, with a complaint of severe painful symptomatology (dysmenorrhoea: VAS 9–10; dyspareunia: Biberoglu & Behrman Scale score 3; persistent dyschezia) with associated headaches. In her past medical history she reported appendectomy at the age of 24. From the age of 14–29 she took estroprogestins. She smoked 20 cigarettes per day and her intestinal habits were irregular.

A previous scan performed 7 months before in another centre had revealed a hydroureteronephrosis (II–III level) of the right kidney, and invasion of the lower ureteral junction and recto-sigmoid by deep endometriotic lesions was suspected. A ureteral stent had been placed in the right ureter and a 6-month treatment with GnRH agonists was suggested.

She came under our observation after six months of treatment with GnRH agonists reporting only a slight relief of painful symptoms and showing a desire for pregnancy. We performed a transvaginal ultrasound (TV-US) and observed an irregular hypoechoic mass attached to the recto-sigmoid wall and spreading down to the recto-vaginal septum measuring 30 mm × 20 mm, with thin band-like echoes departing from the lesion. The severe pain provoked during the TV-US examination induced the interruption of the TV-US scan. A trans-abdominal scan showed regression of the hydroureteronephrosis.

On the basis of her desire for pregnancy we suggested the patient the discontinuation of her hormonal treatment. Endocrine investigation performed two months later showed day 3 FSH (follicle-stimulating hormone), LH (luteinizing stimulating hormone) and estradiol of 6.7 IU/L, 4.6 IU/L, 29 pg/ml, respectively. Her partner's semen analysis was normal. Ultrasound monitoring of follicular growth during natural cycles was offered to optimise the chance of getting pregnant spontaneously in each cycle. Anti-inflammatory treatment was suggested for pelvic pain or dysmenorrhea.

Six months after the discontinuation of GnRH agonists, a spontaneous pregnancy occurred. A TV-US was performed at 5⁺⁴, 7⁺⁵, 14 and 24⁺⁴ weeks. We observed a progressive changing in size of the lesion, increasing in length and reducing in thickness (last scan 36 mm × 9 mm). After the end of the first trimester the plaque appeared less fibrotic with ill-defined contours. With pregnancy, pain was practically absent. Due to the risk of preterm delivery and living a long distance away, the patient could not attend the subsequent scans at our Centre. A caesarean section was performed at 36⁺⁵ weeks. During a scan performed 5 months after delivery, the lesion appeared longer and thinner, and moreover it divided into two parts (Figs. 1 and 2).

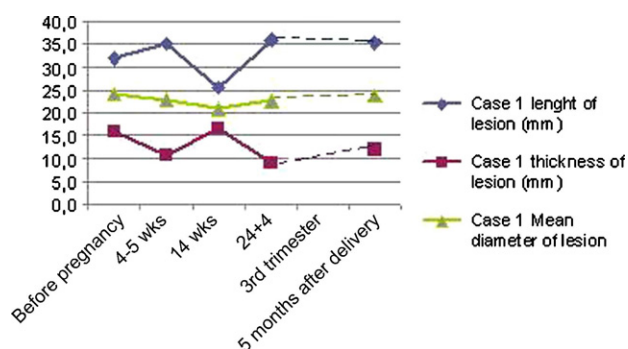


Fig. 1. Case 1. Length, thickness and mean diameter changes (in mm) during TV-US follow-up.

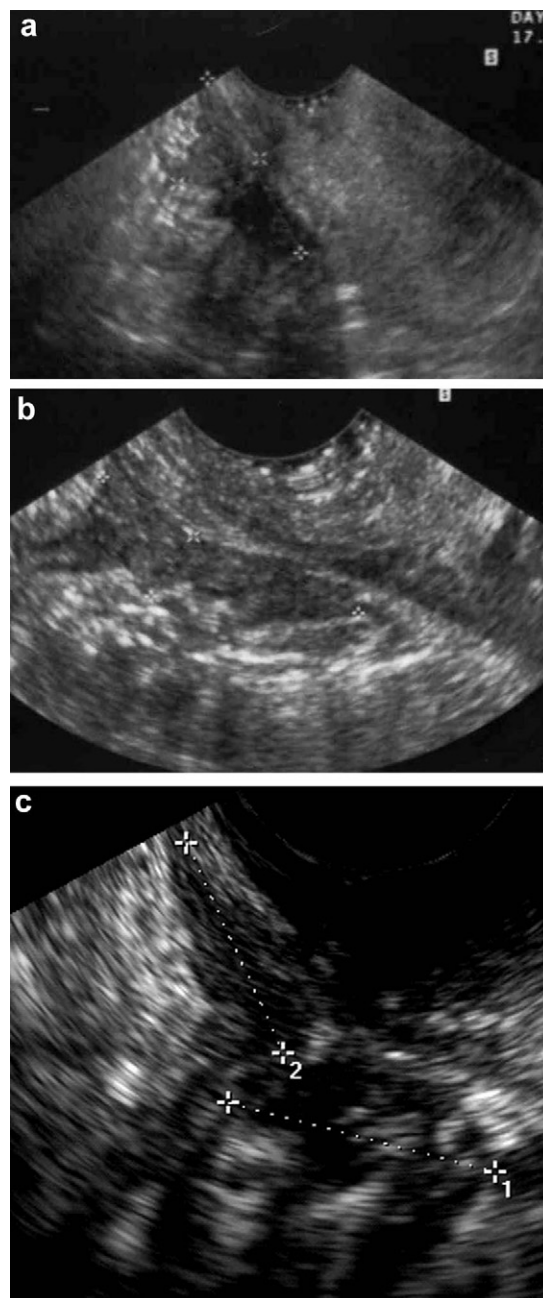


Fig. 2. (a) Before pregnancy: median recto-vaginal 'Indian Headdress'; (b) 24⁺⁴ weeks: longer, thinner, and less fibrotic; (c) 5 months after delivery. The lesion appeared doubled into two thin plaques with more fibrotic patterns.

3.2. Case 2

A 33-year-old Caucasian woman presented with severe dysmenorrhoea, dyschezia and hematochezia arising after the discontinuation of estroprogestins. Her past history included surgery for left pyeloureteral junction stenosis (renal calculi). When she came to our attention, her periods were regular and she had been trying for a pregnancy for 4 months. One year previously she had experienced a biochemical pregnancy.

TV-US showed a left ovarian endometrioma of 48 mm × 35 mm and plaque of deep recto-vaginal endometriosis measuring 44 mm × 12 mm with obliteration of rectal-uterine space. Colonoscopy revealed an inflammatory pattern of sigmoid-rectal mucosa. Histology of a biopsy sample demonstrated a non-specific inflammation. Abdominal magnetic resonance imaging (MRI), 22

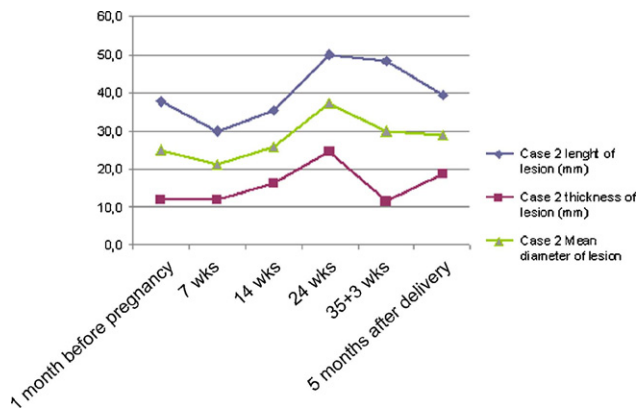


Fig. 3. Case 2. Length, thickness and mean diameter changes (in mm) during TV-US follow-up.

days later, confirmed the ovarian cyst and a fibrotic thickness on the left side of the rectal-uterine space with a complete obliteration of the same.

At laparoscopy one month later, the left endometrioma was completely excised with a stripping procedure, and after extensive pelvic adhesiolysis deep recto-sigmoid and recto-vaginal lesions were removed as much as possible, but not the entire lesion in order to avoid any bowel injuries. TV-US performed one month after the laparoscopy showed a residual lesion in the recto-vaginal septum measuring 37 mm × 12 mm. A pregnancy occurred two months after surgery and the patient was followed by TV-US.

During follow-up firstly we observed a reduction of the lesion, then a slight increase in the size with a maximum at 24 weeks. Then the lesion size reduced (Fig. 3). In this case too, the lesion pattern was less fibrotic and the margin appeared more regular. No painful symptoms were complained of throughout the pregnancy.

We observed the patient four months after delivery and found that the deep recto-vaginal lesion was thinner and divided into two plaques. No pain was aroused by compression with the probe and it appeared to be reduced in consistency (Fig. 4).

3.3. Case 3

A 34-year-old Caucasian woman was referred for outpatient care with a history of severe dysmenorrhoea for the last 2 years and primary infertility for the last 1.5 years. She had had her menarche at the age of 14. Thereafter she had irregular menstrual cycles. In her past medical history she reported a cystectomy for left ovarian endometrioma via a laparoscopic approach, two years previously.

TV-US revealed, on the left side, a retrocervical linear thickening of 15 mm × 10 mm with irregular contours like an 'Indian head dress', continuing with a supra-cervical nodule of 15 mm × 18 mm with rectosigmoid involvement. A colonoscopy was performed and excluded bowel involvement. On routine infertility evaluation, bilateral tubal patency and normal uterine cavity by hysterosalpingography were observed and male factor infertility was excluded. The patient was scheduled for an in vitro fertilization and embryo transfer (IVF-ET) programme.

During the waiting period before the start of IVF-ET, an ongoing pregnancy without any treatment occurred. The TV-US repeated at 7⁺⁴ weeks of gestational age revealed a reduction in the size of the lesions. The retrocervical linear thickening was 12 mm × 7 mm, and the nodule 20 mm × 7 mm. The patient reported complete resolution of symptoms since the first month of pregnancy. At 14⁺³ weeks both the lesions appeared distended. Probably due to the high localization, scans performed during the second and third trimester we were unable to detect the lesions.

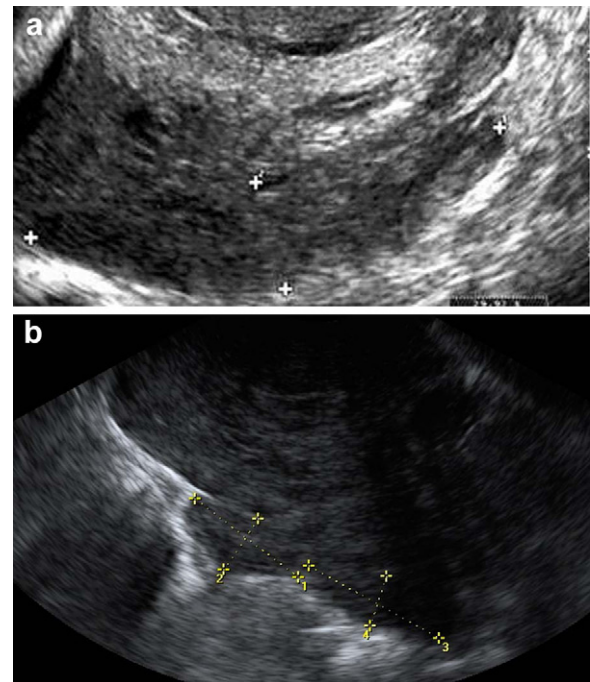


Fig. 4. Case 2. (a) 35⁺³ weeks of gestation, recto-vaginal endometriosis appeared as a homogeneous lesion, less fibrotic appearance and (b) after delivery the lesion appeared as divided into two plaques.

At 37 weeks, she delivered a healthy female infant by caesarean section for breech presentation. One month after delivery she was submitted to a further scan. Two retrocervical plaques were observed 10 mm × 5 mm and 15 mm × 7 mm and a hypoechoic nodule measured 21 mm × 19 mm.

4. Comment

Traditionally the treatment of first intention for DIE is considered to be surgical, and medical treatment is indicated in very few cases. Radical surgery for deep endometriosis is complex and often requires a multidisciplinary team approach including input from colorectal surgeons and urologists [7].

Even though operations are associated with pain relief, the risk of major complications and the recurrence, or persistence, rate are very high in these patients.

In cases of surgery for rectovaginal endometriosis, the incidence of rectovaginal fistula formation, anastomotic leakage, and postoperative ureteral fistula formation is in the range of 2–10%, 1–2% and 0.5–1%, respectively [7]. When colorectal resection is performed, post-operative complications include a higher rate of functional digestive and urinary outcomes [8]. In one series, major complications requiring further surgery occurred in 10.4% of patients and included: anastomotic leakage (4.7%), rectovaginal fistula (2.7%), anastomotic fistula (2%), perforation (0.5%), bowel obstruction (0.5%), uroperitoneum (1.5%), ureteral fistula (1%), bladder fistula (0.5%), pelvic abscess (0.5%), sepsis (0.5%), hemoperitoneum (2%), heterologous blood transfusion (6%), and, after 30 days, urinary retention (4.7%), constipation (2.6%) and peripheral sensory disturbance (1.5%) [9].

These issues can create a conflict between the radicality of excision and the patient's needs and desires (pregnancy and relieving painful symptoms). Therefore a major conservative approach, centred on the patient's symptoms and needs has been advocated for endometriosis in general, and for deep endometriosis in particular [8,10].

The concept expressed by Aboulghar about surgical treatment of ovarian endometrioma might be extended to DIE [11]. Surgery for deep infiltrating endometriosis should be performed only by highly experienced surgeons to reduce the risk of complications. They should avoid too-radical surgery in patients with the diagnosis of DIE who desire pregnancies [11].

Actually, decidualization with the resultant decrease in size of a transmural endometriotic nodule may lead to perforation, by weakening of the intestinal wall, mainly during the third trimester [6]. On the other hand, transmural bowel wall involvement is not so common, the intestinal mucosa usually remains intact, and perforation of the affected intestinal tract is a very rare complication [6].

In our case series we observed spontaneous pregnancies occurring in three patients. During TV-US follow-up we did not observe a worsening in endometriotic lesions. This finding confirms other previously published data [5,12].

The effect of surgery for DIE on fertility is controversial. Vercellini showed that excision of rectovaginal endometriosis did not improve the likelihood of pregnancy nor reduce the time to conception in women with endometriosis-associated infertility [13]. The reproductive outcome in operated patients appeared to be similar to that observed in women undergoing expectant management, with 15 pregnancies among 44 women (34.1%) in women who underwent resection of rectovaginal endometriosis by laparotomy compared with 22 pregnancies among 61 patients (36.1%) deciding on expectant management. The 12 month cumulative probability of conception was 20.5% in the former group and 34.7% in the latter ($p = 0.12$) [13].

In all patients we observed the complete resolution of painful symptomatology from the first weeks of pregnancy onwards. As size changes occurred in different ways in the patients, the beneficial effect of pregnancy on painful symptoms, such as deep dyspareunia and rectal tenesmus, may be due not only to a reduction in the size of DIE plaques and nodules but also most probably to a decrease in the intra- and peri-lesional inflammatory condition and to reduced production of prostaglandins and cytokines [8]. Amenorrhoea and the consequent reduction in cyclic bleeding at ectopic endometrial sites could also induce a regression of activity of the endometriotic implants.

The different changes in size with time might be explained by a number of factors: different location of the lesions, consequently a different effect on the lesion due to the variation of cervix and uterus size occurring in the course of pregnancy, mechanisms of oedema absorption, fibrosis retraction and decidualization.

TV-US allowed follow-up of the lesions during pregnancy. Many studies have validated the non-surgical diagnosis of endometriomas and deep endometriosis through TV-US [14–17]. The ultrasound pattern showed similar modification in all patients: DIE plaques and nodules appeared less fibrotic and more homogeneous, with ill-defined contours. Such common changes might be directly related to the effect of progesterone on the lesions. It has been proven that the action of progesterone on endometriotic implants could be based on a receptor-mediated effect that can reach lesions through the circulation or through direct diffusion from the producing organ [17]. During pregnancy, increasing amounts of progesterone are produced: at first, the source is the corpus luteum, and after the 8th week, production of progesterone shifts to the placenta. At term the placenta produces about 250 mg progesterone per day. The hormonal environment that characterises pregnancy might determine profound modifications of the sonographic appearance of lesions. The sonographic appearance of deep lesions depends on the degree of fibrosis. Thus, it might be argued that also the histopathology of the lesion is modified.

The present report confirmed the beneficial role of pregnancy on endometriosis-related symptomatology already reported by others [18–20]. Some evidence suggests that early pregnancy may

be prophylactic against the development of endometriosis and could actually cause regression of established lesions. The mechanisms postulated include production of anovulation and amenorrhea, decidual change and eventual necrosis induced within the lesions [21].

Endometriosis is a chronic disease. This complex illness impacts patients' lives in ways that cannot be quantified on a medical chart. Over the last few decades, new concepts have emerged and changed classical approaches to endometriosis. The decision-making processes changed from a 'disease centred' approach into a 'patient-centred' approach. This ensures that all patients receive a thorough and comprehensive evaluation, treatment and follow-up care taking into consideration their needs, symptoms, and expectations.

Our experience supports the 'patient-centred care model'. Each of our patients avoided the complication of surgery and obtained a spontaneous pregnancy that finally resulted in a positive effect on both symptomatology and endometriotic lesions. Previous authors have observed the sonographic characteristics of decidualized, hypervascularized endometriomas during pregnancy [22–27] but this is the first report on ultrasound pattern modification of DIE occurring during a spontaneous pregnancy.

References

- [1] Wheeler JM, Malinak LR. Recurrent endometriosis: incidence, management, and prognosis. *Am J Obstet Gynecol* 1983;146:247–53.
- [2] Practice Committee of the American Society for Reproductive Medicine. Endometriosis and infertility. *Fertil Steril* 2006;86(5 Suppl 1):S156–60.
- [3] Giudice LC, Kao LC. Endometriosis. *Lancet* 2004;364(9447):1789–99. 13–19.
- [4] Koninckx PR, Martin DC. Deep endometriosis: a consequence of infiltration or retraction or possibly adenomyosis externa? *Fertil Steril* 1992;58(5):924–8.
- [5] Coccia ME, Rizzello F, Palagiano A, Scarselli G. Long-term follow-up after laparoscopic treatment for endometriosis: multivariate analysis of predictive factors for recurrence of endometriotic lesions and pain. *Eur J Obstet Gynecol Reprod Biol* 2011;157(1):78–83.
- [6] Pisanu A, Deplano D, Angioni S, Ambu R, Uccheddu A. Rectal perforation from endometriosis in pregnancy: case report and literature review. *World J Gastroenterol* 2010;16(5):648–51.
- [7] Vercellini P, Somigliana E, Viganò P, Abbiati A, Barbara G, Crosignani PG. Surgery for endometriosis-associated infertility: a pragmatic approach. *Hum Reprod* 2009;24(2):254–69 [Epub 2008 October 23. PubMed PMID: 18948311].
- [8] Roman H, Vassiliev M, Gourcerol G, Savoye G, Leroi AM, Marpeau L, Michot F, Tuech JJ. Surgical management of deep infiltrating endometriosis of the rectum: pleading for a symptom-guided approach. *Hum Reprod* 2011;26:274–81.
- [9] Mereu L, Ruffo G, Landi S, Barbieri F, Zaccoletti R, Fiaccavento A, Stepniowska A, Pontrelli G, Minelli L. Laparoscopic treatment of deep endometriosis with segmental colorectal resection: short-term morbidity. *J Minim Invasive Gynecol* 2007;14(4):463–9.
- [10] Vercellini P, Crosignani PG, Abbiati A, Somigliana E, Viganò P, Fedele L. The effect of surgery for symptomatic endometriosis: the other side of the story. *Hum Reprod Update* 2009;15:177–88.
- [11] Aboulghar MA, Mansour RT, Serour GI, Al-Inany HG, Aboulghar MM. The outcome of in vitro fertilization in advanced endometriosis with previous surgery: a case-controlled study. *Am J Obstet Gynecol* 2003;188(2):371–5.
- [12] Coccia ME, Rizzello F, Gianfranco S. Does controlled ovarian hyperstimulation in women with a history of endometriosis influence recurrence rate? *J Womens Health (Larchmt)* 2010;19(11):2063–9.
- [13] Vercellini P, Pietropaolo G, De Giorgi O, Daguati R, Pasin R, Crosignani PG. Reproductive performance in infertile women with rectovaginal endometriosis: is surgery worthwhile? *Am J Obstet Gynecol* 2006;195(5):1303–10.
- [14] Bazot M, Malzy P, Cortez A, Roseau G, Amouyal P, Daraï E. Accuracy of transvaginal sonography and rectal endoscopic sonography in the diagnosis of deep infiltrating endometriosis. *Ultrasound Obstet Gynecol* 2007;30(7):994–1001.
- [15] Guerriero S, Ajossa S, Gerada M, Virgilio B, Angioni S, Melis GB. Diagnostic value of transvaginal 'tenderness-guided' ultrasonography for the prediction of location of deep endometriosis. *Hum Reprod* 2008;23(11):2452–7.
- [16] Hudelist G, English J, Thomas A, Tinelli A, Singer CF, Keckstein J. Diagnostic accuracy of transvaginal ultrasound for non-invasive diagnosis of bowel endometriosis—a systematic review and meta-analysis. *Ultrasound Obstet Gynecol* 2010. October 15 [Epub ahead of print].
- [17] Vercellini P, Crosignani PG, Somigliana E, Berlanda N, Barbara G, Fedele L. Medical treatment for rectovaginal endometriosis: what is the evidence? *Hum Reprod* 2009;24(10):2504–14.
- [18] Busacca M, Chiaffarino F, Candiani M, et al. Determinants of long-term clinically detected recurrence rates of deep, ovarian, and pelvic endometriosis. *Am J Obstet Gynecol* 2006;195(2):426–32.

- [19] Porpora MG, Pallante D, Ferro A, Crisafi B, Bellati F, Benedetti Panici P. Pain and ovarian endometrioma recurrence after laparoscopic treatment of endometriosis: a long-term prospective study. *Fertil Steril* 2010;93(3):716–21.
- [20] Koga K, Takemura Y, Osuga Y, et al. Recurrence of ovarian endometrioma after laparoscopic excision. *Hum Reprod* 2006;21:2171–4.
- [21] Bulletti C, De Ziegler D, Rossi S, et al. Abnormal uterine contractility in nonpregnant women. *Ann N Y Acad Sci* 1997;26(828):223–9.
- [22] Barbieri M, Somigliana E, Oneda S, Ossola MW, Acaia B, Fedele L. Decidualized ovarian endometriosis in pregnancy: a challenging diagnostic entity. *Hum Reprod* 2009;24(8):1818–24.
- [23] Poder L, Coakley FV, Rabban JT, Goldstein RB, Aziz S, Chen LM. Decidualized endometrioma during pregnancy: recognizing an imaging mimic of ovarian malignancy. *J Comput Assist Tomogr* 2008;32(4):555–8.
- [24] Guerriero S, Ajossa S, Piras S, Parodo G, Melis GB. Serial ultrasonographic evaluation of a decidualized endometrioma in pregnancy. *Ultrasound Obstet Gynecol* 2005;26(3):304–6.
- [25] Fruscella E, Testa AC, Ferrandina G, Manfredi R, Zannoni GF, Ludovisi M, Malaggesi M, Scambia G. Sonographic features of decidualized ovarian endometriosis suspicious for malignancy. *Ultrasound Obstet Gynecol* 2004;24(5):578–80.
- [26] Machida S, Matsubara S, Ohwada M, Ogoyama M, Kuwata T, Watanabe T, Izumi A, Suzuki M. Decidualization of ovarian endometriosis during pregnancy mimicking malignancy: report of three cases with a literature review. *Gynecol Obstet Invest* 2008;66(4):241–7.
- [27] Takeuchi M, Matsuzaki K, Nishitani H. Magnetic resonance manifestations of decidualized endometriomas during pregnancy. *J Comput Assist Tomogr* 2008;32(3):353–5.