



UNIVERSITÀ
DEGLI STUDI
FIRENZE

FLORE

Repository istituzionale dell'Università degli Studi di Firenze

Nitric oxide synthase and VIP distribution in enteric nervous system in idiopathic chronic constipation.

Questa è la Versione finale referata (Post print/Accepted manuscript) della seguente pubblicazione:

Original Citation:

Nitric oxide synthase and VIP distribution in enteric nervous system in idiopathic chronic constipation / Cortesini C; Cianchi F; Infantino A; Lise M.. - In: DIGESTIVE DISEASES AND SCIENCES. - ISSN 0163-2116. - STAMPA. - 40:(1995), pp. 2450-2455.

Availability:

This version is available at: 2158/770079 since:

Terms of use:

Open Access

La pubblicazione è resa disponibile sotto le norme e i termini della licenza di deposito, secondo quanto stabilito dalla Policy per l'accesso aperto dell'Università degli Studi di Firenze (<https://www.sba.unifi.it/upload/policy-oa-2016-1.pdf>)

Publisher copyright claim:

(Article begins on next page)

Nitric Oxide Synthase and VIP Distribution in Enteric Nervous System in Idiopathic Chronic Constipation

CAMILLO CORTESINI, MD, FABIO CIANCHI, MD, ALDO INFANTINO, MD,
and MARIO LISE, MD

Idiopathic chronic constipation has been correlated to neural abnormalities that consist of a reduced number of myenteric plexus neurons and a decreased concentration of VIP-positive nerve fibers within the circular muscle. Recent studies hypothesized the involvement of nitric oxide in motility disorders of the human gut. To date, no information is available on nitric oxide involvement in idiopathic chronic constipation. The density of VIP- and nitric oxide-producing neurons was evaluated by immunocytochemistry using anti-VIP and anti-nitric oxide synthase antibodies in five patients with idiopathic chronic constipation. A low total neuron density was found at the myenteric plexus. The density of VIP-positive neurons was low while that of nitric oxide synthase-positive neurons was high at both plexuses. Our data confirm that idiopathic slow-transit chronic constipation is due to abnormal neurogenic factors. The presence of numerous nitric oxide synthase-positive neurons, all along the colon and at both plexuses, supports the hypothesis that an excessive production of nitric oxide may cause the persistent inhibition of contractions.

KEY WORDS: constipation; myenteric plexus; submucous plexus; VIP; nitric oxide; histochemistry.

Idiopathic slow-transit chronic constipation (ICC) is a colonic motility disorder of unknown etiology. The delayed colonic transit (colonic inertia), which can result from dysfunction of the entire colon, is probably associated with a decrease in or loss of giant migrating contractions controlled by myogenic, neural, and hormonal mechanisms (1-4). Previous morphologic studies on ICC patients have implicated neural abnormalities consisting of a reduced number of the myenteric plexus neurons (5) and a decreased concentration of VIP (6, 7) and VIP-positive nerve fibers within the circular muscle (6).

Manuscript received February 23, 1995; revised manuscript received June 6, 1995; accepted June 29, 1995.

From the Clinica Chirurgica Generale, Università di Firenze, Florence, Italy; and Istituto di Clinica Chirurgica II, Università di Padova, Padova, Italy.

Supported by MURST University Funds.

Address for reprint requests: Dr. Camillo Cortesini, Clinica Chirurgica Generale, Viale G.B. Morgagni 85, 50134 Firenze, Italy.

Similarly to VIP, other muscle relaxant molecules are released by enteric neurons; among these is nitric oxide (NO), which has recently been described as a major inhibitory mediator in the gut musculature (8-11). NO seems to be involved in different afflictions of the human gut where the prominent feature is a defect in relaxation. In fact, a deficiency in its synthesizing enzyme, nitric oxide synthase (NOs), has been described in the pyloric circular muscle of infantile hypertrophic pyloric stenosis (12), in the gastroesophageal junction of patients with achalasia (13), and in both plexuses and the circular muscle of the aganglionic segments of Hirschsprung's disease (14). To date, no information is available on NO involvement in ICC.

The purpose of this study was to analyze: (1) the total neuron density as well as (2) the density of the VIP- and NOs-containing neurons in patients with

ICC, at both the myenteric and submucous plexuses of the right and left colon.

MATERIALS AND METHODS

The total neuron density and the density of VIP-positive and NOs-positive neurons were evaluated in five consecutive female patients (mean age 34.3) suffering from idiopathic slow-transit chronic constipation operated on for total colectomy and ileorectal anastomosis. The colon of these patients was normal in size, although their symptoms (spontaneous bowel frequency of less than once per week) had developed many years previously.

The segmental colonic transit time, evaluated according to Martelli et al (15), fell outside the normal range (Figure 1). Anorectal manometry (16) and defecography allowed us to exclude an impaired anorectal function. Radionuclide solid-meal gastric emptying studies were normal in four and delayed in one patient. Subjects with normal colonic transit time submitted to elective right or left colectomy for non-obstructive neoplasms represented the control group.

Before immersion in the fixative liquid, both the left and right colon were cut into small blocks, corresponding to the cecum, ascending and right transverse colon (right colon), and left transverse and descending colon (left colon), respectively.

Immunocytochemistry. Specimens were fixed in 4% paraformaldehyde-buffered solution (PBS 0.1 M, pH 7.4) for 6 hr and then paraffin embedded. Serial sections 6 μ m thick were picked up on slides precoated with poly-L-lysine (Sigma, Milan, Italy, 0.1% solution in distilled water) and oven-dried overnight at 37°C. Sections were deparaffinized and brought through graded alcohol to water. Then they were stained with an indirect immunohistochemical method in order to reveal the presence of nitric oxide synthase (NOs) and vasoactive intestinal polypeptide (VIP). Non-specific attachment of primary antibodies to the tissue sections was prevented by incubating each of them for 15 min, at room temperature, with bovine serum albumin (BSA) 0.1%, in PBS, 0.01 M, pH 7.4. The serum was drawn off with blotting paper.

For both fluorescence and bright field microscopy, sections were processed as follows: (1) For NOs immunostaining, sections were incubated in a humid chamber with polyclonal antibodies anti-cerebellar NOs (NOs type I antiserum), raised in rabbits (Affiniti, Nottingham, UK) against the purified neuronal enzyme extracted from porcine cerebellum, diluted 1:100, and applied overnight at room temperature. The specificity of the immunostaining for the NOs antiserum was checked by preabsorption with the purified enzyme (50–100 μ g/ml antiserum); (2) For VIP immunostaining, primary rabbit polyclonal antibodies anti-VIP (Amersham, Buckinghamshire, UK) were applied on the sections diluted 1:1000 and incubated at 4°C overnight. The antiserum to VIP was raised in rabbits using natural porcine VIP conjugated to keyhole limpet hemocyanin, using glutaraldehyde as a coupling agent.

All primary antibodies were diluted with Tris-buffered saline 0.01 M pH 7.4; 3% normal serum was added to anti-VIP and anti-NOs antibodies; 0.3% (v/v) Triton X-100 (BDH, Poole, England) was added to anti-NOs antibodies.

After incubating with primary antibody, sections were rinsed in three changes of PBS for 5 min each time. Sections were then incubated for 2 hr with anti-rabbit IgG (whole molecule)-fluorescein-isothiocyanate (FITC) conjugate (Sigma, Milan, Italy), raised in goats, and diluted 1:60 in PBS 0.01 M, pH 7.4. Fluorochrome-stained sections were rinsed in three changes of PBS, pH 7.2–7.6, for 5 min each time, mounted in glycerine buffer (9:1), and examined with a Zeiss Axioskop microscope equipped for epifluorescence. Immunopositive neurons were counted and photographed in order to determine VIP-positive and NOs-positive neuron densities.

After fluorescence microscope examination, the immunostained sections were further processed for bright-field microscopy with hematoxylin-eosin (H&E) to determine total neuron density.

All NOs- and VIP-immunostained neurons were counted in two consecutive sections of each specimen (by a single observer) and separate counts were made for the submucous plexus (SMP) and myenteric plexus (MP). Separate counts were for each available specimen; the data from each patient were then pooled for each hemicolon and plexus and subjected to statistical analysis. For each patient, the number of neuronal sections was analyzed for each region and plexus. In each specimen, the length of the submucosa and muscle coat on sections was measured along lines parallel to and midway between the inner and outer boundary of the submucosa and muscle coat, respectively. Hence, for each patient, the number of NOs-positive, VIP-positive, and H&E-stained neurons per unit section length (millimeters) of the submucosa and muscle coat was computed for each specimen. These data were then compared with those of H&E-stained, VIP- and NOs-positive neuron densities obtained in subjects with normal colonic transit. The density of NOs and VIP reactivity was then assessed visually, according to Vanderwinden et al (14), as follows: + + + +, very high; + + +, high; + +, moderate; +, weak; 0 absent.

RESULTS

Histology

At routine light microscope examination, the smooth muscle cells, muscle layers, connective stroma, and enteric plexuses showed apparently normal features. Neither Schwann cell hyperplasia nor inflammatory reactions were observed at either plexus.

Total Neuron Density

In ICC patients the MP neuron density was lower and the SMP neuron density was higher than the mean value of controls (Table 1).

Immunocytochemistry

In the immunostained sections of the colonic regions examined, both VIP- and NOs-positive neurons

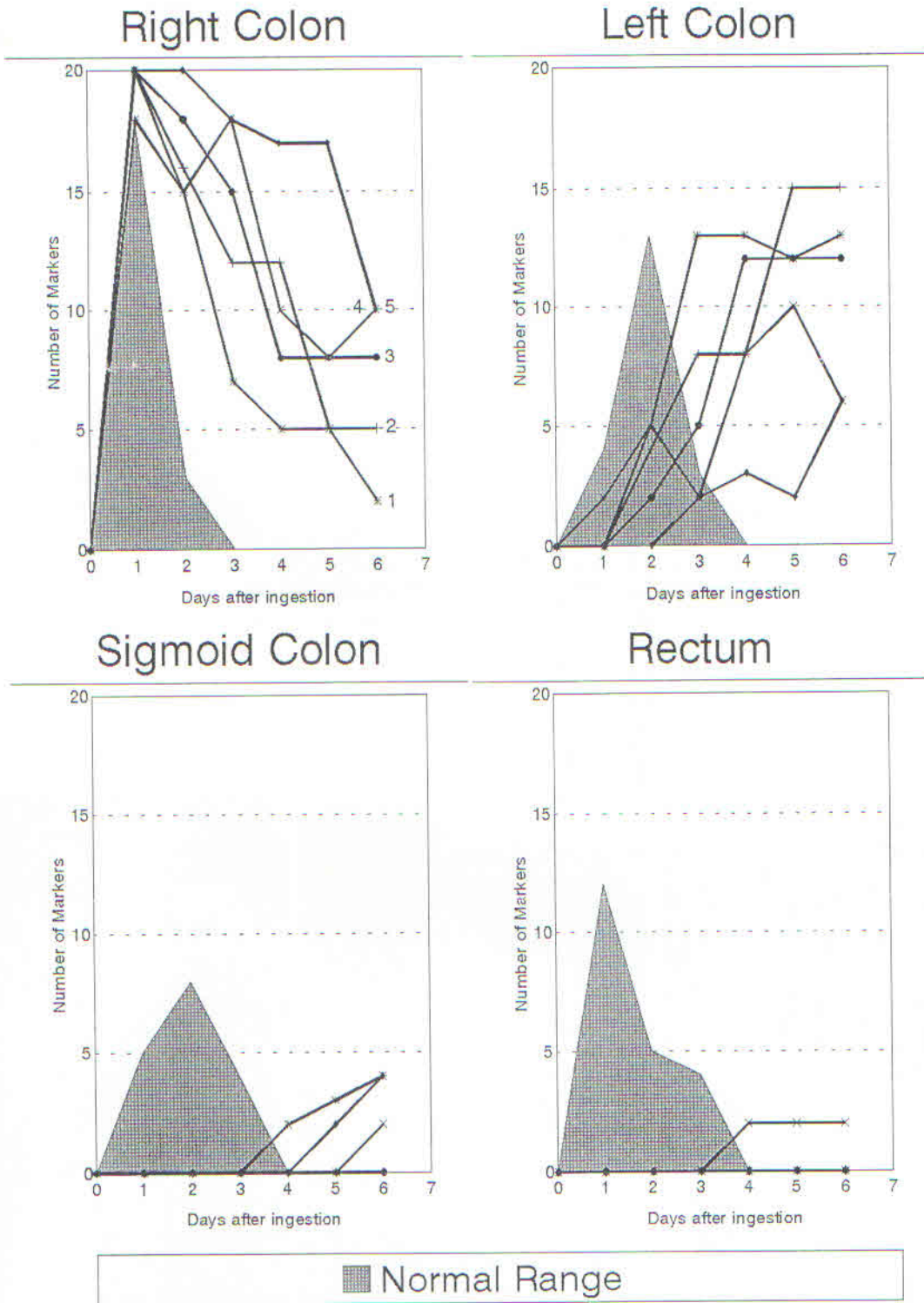


Fig 1. Idiopathic chronic constipation. Segmental colonic transit time. Delayed transit results from the persistence of radiopaque markers in a scattered distribution throughout the right and transverse colon six days after their ingestion.

NITRIC OXIDE IN IDIOPATHIC CHRONIC CONSTIPATION

TABLE 1. TOTAL NEURON DENSITY IN ENTERIC NERVOUS SYSTEM OF NORMAL COLON AND IN ICC

	Controls (N = 9) (mean value)	ICC (N = 5) (mean value)
Right colon		
Myenteric plexus	4.71 (2.1-10.1)	3.78 (2.6-7.1)
Submucous plexus	2.18 (0.9-5.1)	4.51 (4.1-4.9)
Left colon		
Myenteric plexus	9.64 (4.4-20.7)	8.19 (6.6-11.2)
Submucous plexus	4.49 (2.2-8.9)	7.06 (6.2-8.4)

and fibers were found in different quantities to those of control subjects.

VIP-Positive Neuron Density. At the colonic regions examined, VIP-positive neurons were found in a lower quantity than in control subjects (Figure 2a and b). In fact, the density of VIP-positive neurons of both plexuses at all regions examined was very much lower than the mean values of controls. This reduction was more marked at the SMP than at the MP. In contrast with the controls, at both the right and left colon (Figure 2c) the VIP-positive nerve fibers were more numerous within the inner, rather than the outer, portion of the circular muscle layer.

NOs-Positive Neuron Density. At the colonic regions examined, NOs-positive neurons were found in a higher quantity than in control subjects (Figure 3a and b). In both the left and right colon, an extremely high NOs-positive neuron density was found at both plexuses. As in control subjects, at all colonic regions, the inner portion of the circular muscle layer was devoid of NOs-positive nerve fibers. Results are summarized in Table 2.

DISCUSSION

Our results enable us to exclude the presence of a degenerative neuropathy in patients suffering from a severe motor dysfunction of the entire colon (ICC), since all ganglia and nerve fibers showed apparently normal features. Our observations, however, revealed that all along the entire colonic length, these patients possessed a total neuron number and a VIP- and NOs-positive neuron density different than those of control subjects.

The most striking features we found in ICC patients were that, especially in the right colon, as well as in the left, these patients had an extremely low number of VIP-positive neurons and a markedly high number of NOs-positive neurons at both plexuses when compared to control subjects.

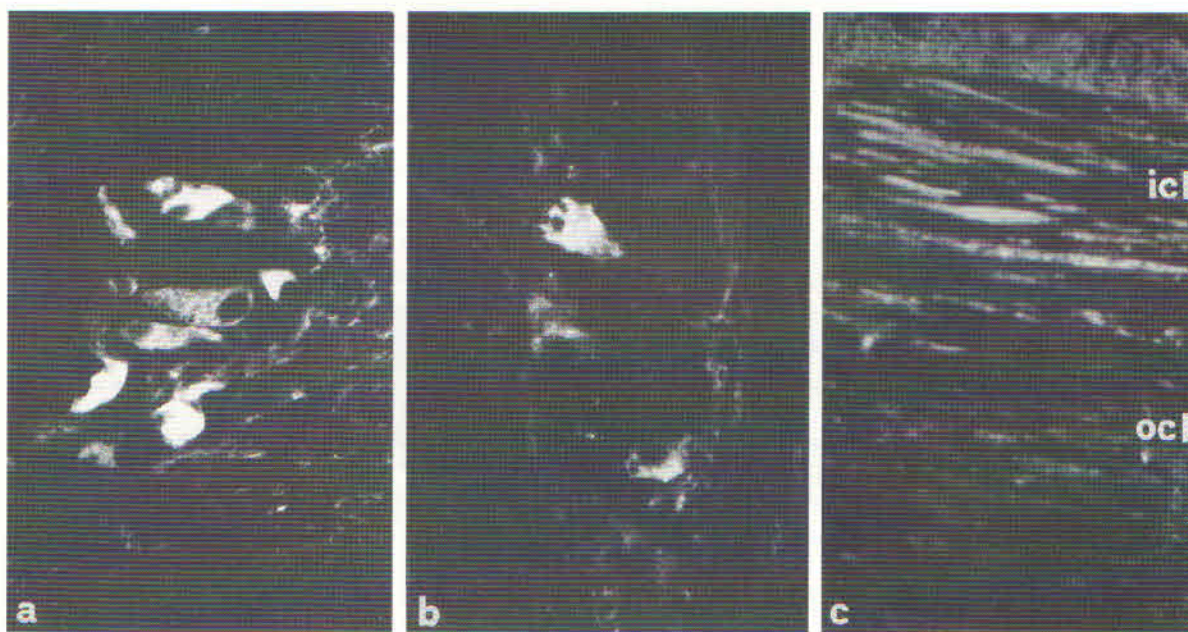


Fig 2. VIP distribution in the colonic muscularis externa. (a) Control subjects: colonic myenteric plexus; VIP-positive neurons (original magnification $\times 350$). (b) Idiopathic chronic constipation: colonic myenteric plexus; VIP-positive neurons are fewer than in controls (see A) (original magnification $\times 350$). (c) Idiopathic chronic constipation: the inner (icl) portion of the circular muscle layer is richer in VIP-positive nerve fibers than the outer (ocl) one (original magnification $\times 225$).

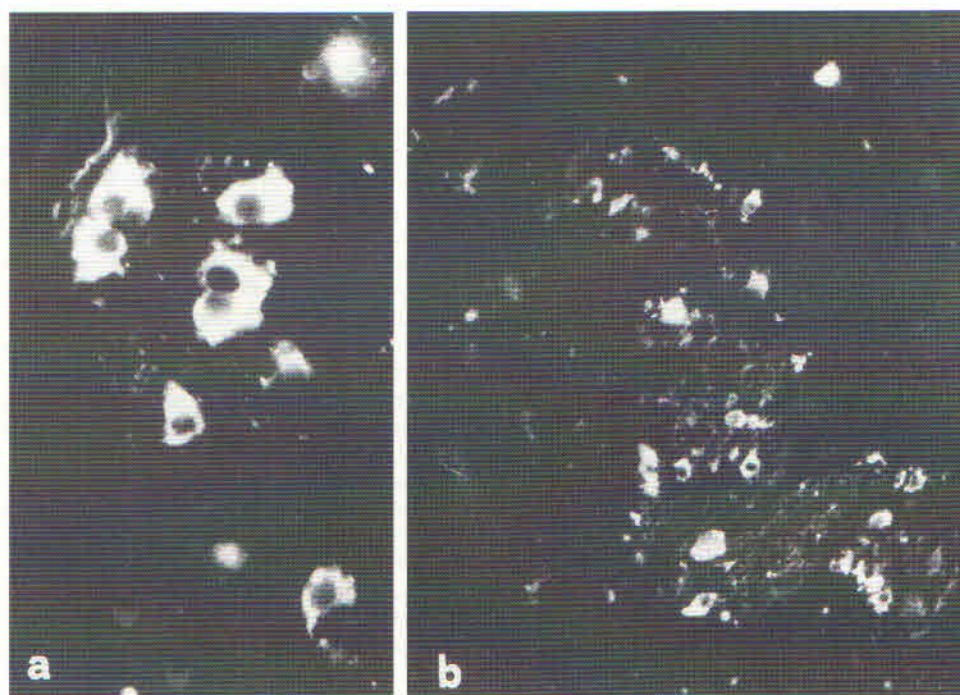


Fig 3. NOs distribution in the colonic muscularis externa. (a) Control subjects: colonic myenteric plexus; NOs-positive neurons (original magnification $\times 350$). (b) Idiopathic chronic constipation: colonic myenteric plexus; NOs-positive neurons are extremely numerous (original magnification $\times 175$).

A reduced VIPergic innervation has previously been described in the aganglionic segment of colon obtained from patients with Hirschsprung's disease (17). The lack of relaxation of this aganglionic segment, in addition to the absence of the rectoanal inhibitory reflex, has been correlated to a deficiency in VIPergic innervation.

A reduced concentration of VIP and VIPergic innervation also has been found within the circular muscle of the descending and sigmoid colon in ICC

TABLE 2. NEURON DENSITIES OF NORMAL COLON AND IN ICC

	Controls (N = 9) (mean value)	ICC (N = 5) (mean value)
NOs-positive		
Right colon		
Myenteric plexus	2.66 (++)	4.07 (++++)
Submucous plexus	0.40 (+)	2.72 (+++)
Left colon		
Myenteric plexus	5.76 (+++)	7.14 (++++)
Submucous plexus	0.89 (+)	1.62 (++)
VIP-positive		
Right colon		
Myenteric plexus	2.50 (++)	1.01 (+)
Submucous plexus	1.17 (++)	0.08 (0)
Left colon		
Myenteric plexus	4.47 (++++)	2.65 (++)
Submucous plexus	2.33 (+++)	0.30 (0)

patients (6, 7). Given that VIP is one of the NANC inhibitory neurotransmitters whose role is to produce descending inhibition ahead of the giant migrating contractions, which are essential to allow rapid propulsion of a large bolus, its absence could cause the colonic constrictions responsible for colonic obstructions in ICC patients. However, Koch et al (6) have never found such constrictions in ICC patients, and, therefore, have interpreted their absence as being due to the presence of reduced VIP quantities that cannot be visualized by immunocytochemistry but are measurable in extracts of the colonic muscularis externa. Our immunohistochemical data confirm this reduced VIPergic innervation in the colon of ICC patients. However, we found the inner portion of the circular muscle layer richer in VIP-positive nerve fibers than in controls. The presence of a rich VIPergic innervation in a portion (the inner one) of the circular muscle layer could support the quantitative data of Koch et al. Given the importance of an inhibitory innervation on the myogenic role presumably played by this portion of the colonic circular muscle (10, 18, 19), its increased VIPergic innervation might explain the absence of colonic obstructions in ICC patients.

Our hypothesis to explain the persistent inhibition

of contractions in the colon of ICC patients involves the role of NO, since this molecule is currently recognized as the major mediator in the relaxation induced by the NANC inhibitory motor neurons in the gastrointestinal tract (8–11). These NANC inhibitory motor neurons at sphincters are normally inactive (off) and turn active (on) to open the sphincter itself with appropriate timing for the passage of luminal contents (20). Thus, a deficiency in the NO-producing neurons, as has been shown in infantile hypertrophic pyloric stenosis (12), achalasia (13), and Hirschsprung's disease (14), may affect the physiological modulation of the sphincter relaxation. Instead, these NANC inhibitory motor neurons in nonsphincteric regions are continuously active (on), maintaining a state of persistent inhibition of the contractile activity (physiological ileus) (20). The presence of extremely numerous NOs-positive neurons at both plexuses, and especially at the right colon, together with the constant presence of the nitridergic nerve fibers supplying the outer (main) portion of the circular muscle layer found in ICC patients, may consequently lead to the inhibition of the giant migrating contractions.

It can therefore be proposed that an excess of NO may determine the chronic adynamic condition of the colon (colonic inertia) in ICC patients. In agreement with this hypothesis, recent data have shown that an increased production of NO by the colonic mucosa and its diffusion to the underlying muscle could contribute to the toxic colonic dilation that occurs in fulminant ulcerative colitis (21).

In conclusion, our data demonstrate the presence of a significant impairment of the neural tissue of the entire colon in ICC patients, thus confirming that idiopathic slow-transit chronic constipation is due to abnormal neurogenic factors. Moreover, it may be suggested that the inhibition of the propagating contractions in these patients is mainly dependent on an excess of NO.

ACKNOWLEDGMENTS

The authors thank Maria Simonetta Fausone Pellegrini (Dipartimento di Anatomia e Istologia, Università di Firenze) for the histological and immunocytochemical studies.

REFERENCES

- Bassotti G, Gaburri M, Imbimbo BP, Rossi L, Farroni F, Pelli MA, Morelli A: Colonic mass movements in idiopathic chronic constipation. *Gut* 29:1173–1179, 1988
- Preston DM, Butler MG, Smith B, Lennard-Jones JE: Neuro-pathology of slow transit constipation. *Gut* 24:A997, 1983
- Sarna SK: Physiology and pathophysiology of colonic motor activity. Part one of two. *Dig Dis Sci* 36:827–862, 1991
- Sarna SK: Physiology and pathophysiology of colonic motor activity. Part two of two. *Dig Dis Sci* 36:995–1018, 1991
- Krishnamurthy S, Schuffler MD, Rohrmann CA, Pope CE: Severe idiopathic constipation is associated with a distinctive abnormality of the colonic myenteric plexus. *Gastroenterology* 88:26–34, 1985
- Koch TR, Carney JA, Go L, Go VLW: Idiopathic chronic constipation is associated with decreased colonic vasoactive intestinal peptide. *Gastroenterology* 94:300–310, 1988
- Milner P, Lincoln J, Crowe R, Kamm M, Lennard-Jones JE, Burnstock G: Serotonin is increased and VIP decreased in the sigmoid colon in idiopathic constipation. *Gut* 30:A715, 1989
- Burleigh DE: Ng-nitro-L-arginine reduces nonadrenergic non-cholinergic relaxations of human gut. *Gastroenterology* 102:679–683, 1992
- Boeckxstaens GE, Pelckmans PA, Herman AG, Van Maercke YM: Involvement of nitric oxide in the inhibitory innervation of the human isolated colon. *Gastroenterology* 104:690–697, 1993
- Keef KD, Du C, Ward SM, McGregor B, Sanders KM: Enteric inhibitory neural regulation of human colonic circular muscle: Role of nitric oxide. *Gastroenterology* 105:1009–1016, 1993
- Stark ME, Szurszewsky JH: Role of nitric oxide in gastrointestinal and hepatic function and disease. *Gastroenterology* 103:1928–1949, 1992
- Vanderwinden JM, Mailleux P, Schiffmann SN, Vanderhaeghen JJ, De Laet MH: Nitric oxide synthase activity in infantile hypertrophic pyloric stenosis. *N Engl J Med* 327:511–515, 1992
- Mearin F, Mourelle M, Guarner F, Salas A, Moncada S, Malagelada JR: Absence of nitric oxide synthase in the gastro-esophageal junction of patients with achalasia. *Gastroenterology* 104:A550, 1993
- Vanderwinden JM, De Laet MH, Schiffmann SN, Mailleux P, Lowenstein CJ, Snyder SH, Vanderhaeghen JJ: Nitric oxide synthase distribution in the enteric nervous system of Hirschsprung's disease. *Gastroenterology* 105:969–973, 1993
- Martelli H, Devroede G, Arhan P, Duguay C, Dornic C, Faverdin C: Some parameters of large bowel motility in normal men. *Gastroenterology* 75:612–618, 1978
- Cortesini C: Anorectal reflex following sphincter-saving operation. *Dis Colon Rectum* 23:320–326, 1980
- Larson LT: Hirschsprung's disease. Immunohistochemical findings. *Histol Histopathol* 9:615–629, 1994
- Fausone-Pellegrini MS, Cortesini C, Pantalone D: Neuromuscular structures specific to the submucosal border of the human colonic circular muscle layer. *Can J Physiol Pharmacol* 68:1437–1446, 1990
- Fausone-Pellegrini MS, Bacci S, Pantalone D, Cortesini C: Distribution of VIP-immunoreactive nerve cells and fibers in the human ileocecal region. *Neurosci Lett* 157:135–139, 1993
- Wood JD: Physiology of the enteric nervous system. In *Physiology of the Gastrointestinal Tract*, Vol 1, 3rd ed. LR Johnson (ed). New York, Raven Press, 1994, pp 423–482
- Boughton-Smith NK, Evans SM, Cole AT, Whittle BJR, Hawkey CJ: Increased nitric oxide synthase activity in inflamed colon from ulcerative colitis patients. *Gut* 33:S11, 1992