

Ovarian surgery for bilateral endometriomas influences age at menopause

Maria Elisabetta Coccia^{1,*}, Francesca Rizzello², Giulia Mariani¹, Carlo Bulletti³, Antonio Palagiano⁴, and Gianfranco Scarselli¹

¹Department of Science for the Health of Woman and Child, University of Florence, Via Ippolito Nievo 2, 50129 Florence, Italy ²Department of Experimental Medicine, Section of Medical Physiopathology, University of Rome 'La Sapienza', Rome, Italy ³Unit of Physiopathology of Reproduction, Cattolica General Hospital and University of Bologna, Bologna, Italy ⁴Department of Obstetrics, Gynecology, and Reproductive Sciences, Second University of Naples, Naples, Italy

*Correspondence address. Tel: +39-335-6346293; Fax: +39-055-88431171; E-mail: cocciame@tin.it

Submitted on April 13, 2011; resubmitted on July 22, 2011; accepted on August 3, 2011

BACKGROUND: Questions remain as to whether surgical excision of ovarian endometriomas might cause damage to ovarian function. To test the hypothesis that ovarian surgery for endometrioma compromises ovarian function and accelerates ovarian failure.

METHODS: In a tertiary university Clinic, longitudinal prospective cohort study. Patients who underwent laparoscopy for endometriosis between March 1993 and November 2007 were assessed for inclusion in the study. A prospective follow-up at 3, 6 and 12 months then yearly was conducted. Evolution of menstrual pattern, symptoms and reproductive outcomes were investigated.

RESULTS: From over the 14-year period, 302 patients were included in the study. The mean age (\pm SD) of patients was 32.6 ± 5.6 years; the median duration of follow-up was 8.5 years (range 2–17 years). Menopause was documented in 43 women (14.3%) at a mean age of 45.3 ± 4.3 years (range 32–52 years). Women previously submitted to bilateral cystectomy were younger at menopause than those with monolateral endometrioma (42.1 ± 5.1 years versus 47.1 ± 3.5 years, $P = 0.003$). Premature ovarian failure (POF) was observed in 7 of 43 (16.3%) menopausal patients; the majority (4, 57.1%) after bilateral cystectomy. The relationship between the preoperative ovarian endometriomas total diameter and menopausal age was significant in case of surgery for bilateral endometriomas ($R^2 = 0.754$, $P = 0.002$).

CONCLUSIONS: Patients who had been operated on for bilateral endometriomas have an increased risk of POF. Ovarian parenchyma loss at the time of surgery seems related to cyst diameter. In the case of unilateral ovarian endometrioma, the contralateral intact ovary might adequately compensate.

Key words: endometriosis / endometrioma / premature ovarian failure / menopause / cystectomy

Introduction

Laparoscopic surgery has become the gold standard treatment for benign ovarian cysts (Daniell *et al.*, 1991; Donnez *et al.*, 1996; Sutton *et al.*, 1997; Canis *et al.*, 2002). It is a highly effective and safe procedure. Relief of pain following surgical treatment of endometriosis at 1-year follow-up ranges between 50 and 95% (Practice Committee of the American Society for Reproductive Medicine, 2006). Furthermore, a body of literature has provided evidence that the pregnancy rate after laparoscopic removal of ovarian cysts is satisfactory (Donnez *et al.*, 1996; Beretta *et al.*, 1998; Hemmings *et al.*, 1998).

However, questions remain as to whether surgical excision might cause damage to residual ovarian function. Even with surgeons experienced in laparoscopy for endometriosis, we are now aware that any

type of surgery could cause additional damage to already compromised ovarian function (Garcia-Velasco and Somigliana, 2009; de Ziegler *et al.*, 2010). This suggests that at least some of the adverse effects of endometriomas on fertility outcomes might derive from prior surgical interventions rather than the endometriosis itself (Taylor and Lebovic, 2009).

These complications are thought to be related to both removal of healthy ovarian tissue and vascular injury. It is common experience that a too aggressive bipolar coagulation or misuse of monopolar can produce ovarian damage; moreover some laparoscopists perform the cystectomy by removing ovarian cortex. These procedures contribute to further reducing healthy ovarian tissue.

Recently, some cases of ovarian failure following surgery for bilateral endometriomas have been described (Busacca *et al.*, 2006;

Di Prospero and Micucci, 2009). The frequency of this complication has been estimated to be 2.4% (Busacca et al., 2006) but this data warrant confirmation.

There are several publications showing modifications of the endocrine profile of the cycle and altered responsiveness to ovarian stimulation after laparoscopic cystectomy for endometriomas (Benaglia et al., 2010; Almog et al., 2011; Karita et al., 2011). Moreover, evidence from pathological specimens suggested that ovarian tissue is inadvertently excised together with the endometrioma wall in most cases with no significant influence of different surgical techniques (Muzii et al., 2005). On the other hand, ovarian tissue that was resected with the endometrioma walls primarily comprised tissue with no (Grade 0) or only primordial (Grade 1) follicles (Muzii et al., 2005; Alborzi et al. 2009).

The aim of the study was to assess whether laparoscopic cystectomy for ovarian endometriomas is associated with early age at menopause and increased probability of premature ovarian failure (POF).

Materials and Methods

Patients who consecutively underwent laparoscopy for endometriosis in the Department of Science for the Health of Woman and Child, University of Florence, Italy, between March 1993 and November 2007, were included in the study.

Exclusion criteria were:

- (i) presurgical menopause (both spontaneous and surgical);
- (ii) mono/bilateral adnexectomy performed during laparoscopy;
- (iii) surgical menopause (i.e. bilateral oophorectomy with or without hysterectomy who were premenopausal at the time of surgery);
- (iv) hysterectomy;
- (v) surgery for ovarian cysts other than ovarian endometrioma;
- (vi) treatments affecting ovarian reserve (radiotherapy, chemotherapy);
- (vii) impossible to contact patients at follow-up;
- (viii) patients' refusal to participate.

Laparoscopy

All surgeries were performed by two expert laparoscopists (M.E.C., G.S.) under general anaesthesia. After establishment of pneumoperitoneum, the laparoscope was introduced into the abdominal cavity through the umbilicus, and three accessory trocars were inserted suprapubically under direct vision. Adhesions were lysed using sharp dissection to restore normal anatomy. The stripping technique was used to remove the ovarian endometriomas. Complete excision of pelvic endometriotic lesions was performed using scissors or bipolar coagulation. In case of peritoneal lesions, destruction or removal of all visible endometriotic implants and the lysis of adhesions was achieved. Chromoperturbation with methylene blue dye was performed in patients of reproductive age. The disease stage was assigned according to the American Society for Reproductive Medicine classification system (American Society for Reproductive Medicine, 1997).

Follow-up

According to an internal protocol of our Department, all patients are followed up after surgery for endometriosis. A standard gynaecologic examination and a transvaginal ultrasound scan are performed before surgery and at 3, 6 and 12 months, then yearly after surgery. Patients who are not able to come to periodic visits are contacted by telephone and interviewed.

During the visit (or the telephone call), patients are interviewed using the same structured questionnaire about their general characteristics as age, height and weight. Further, data on evolution of menstrual pattern, symptoms, reproductive factors and oral contraceptive use are collected during follow-up.

The BMI (kg/m^2) was calculated using the height and weight measurements at the time of follow-up.

Tobacco smoking status was defined as current, former or never smoker. If the participants had ever smoked 'one or more cigarettes a day for a year or more' and 'smoked within the last 3 months', they were classified as current smokers. Previous smokers were those who had ever smoked 'one or more cigarettes a day for a year or more', but had not smoked during the past 3 months. Never smokers had never smoked 'one or more cigarettes a day for a year or more'.

Definitions

Women who reported 12 continuous months of amenorrhoea (according to World Health Organization criteria) (World Health Organization Scientific Group, 1981), without a hysterectomy or other procedure that would have stopped their menses, were classified as naturally menopausal. Age at natural menopause was defined as the age at last menstrual period.

Amenorrhoea, hypo-oestrogenism and elevated gonadotrophin levels in women under the age of 40 years was defined as POF.

Menopausal symptoms included hot flushes, night sweats and vaginal dryness (Woad et al., 2006).

Results were analyzed on the basis of surgery for ovarian endometrioma, cyst size, number of previous surgeries for endometriosis, pregnancy and previous treatment by oral contraceptives.

Age at menopause was compared with a reference population. We made use of a population, consisting of 31 834 women in spontaneous menopause, aged more than 55 years, attending a network of first-level outpatient menopause clinics in Italy, described in a previous paper (Pazzini et al., 2007).

Statistical analysis

Statistical analysis was performed using the Statistical Package for the Social Sciences software (SPSS 16, Chicago, IL, USA). Mean and SD values were calculated for continuous variables, and numbers and percentages for categorical variables. Comparisons of means between two independent groups for continuous variables were made with Student's *t*-test, and the paired *t*-test was used for comparison of means between two dependent groups. Comparison of categorical variables was made by χ^2 test. Simple linear regression analyses and the Pearson correlation were applied to analyze the correlation between the age at onset of menopause and the endometrioma diameters, with the age at menopause as the dependent parameter. A value of $P < 0.05$ was considered to be statistically significant.

Results

Between March 1993 and November 2007, 640 patients underwent laparoscopy for endometriosis.

A total of 355 (55.5%) women submitted to a laparoscopy for endometriosis and followed up during the interval surgery-end of follow-up (November 2010) were firstly included. Fifty-three of them did not satisfy the inclusion criteria: 8 were still following a medical treatment begun after laparoscopy, 8 were pregnant or breast-feeding, in 1 patient menopause occurred before laparoscopy, 21 underwent adnexectomy (bilaterally in 6, monolaterally in 15), in 1 patient a hysterectomy was performed during surgery for

endometriosis, 1 patient was taking chemotherapy, 13 were excluded as they were submitted to surgery for other ovarian cysts.

Three-hundred and two patients were included in the study. The mean (\pm SD) age of patients at the time of last surgery was 32.6 ± 5.6 years, and mean age at the time of last follow-up 41.7 ± 6.7 years. The median duration of follow-up was 8.5 years (mean duration 7.7 ± 4.6 years, minimum 2 years, maximum 17 years). Tables I and II show characteristics of the selected patients. During laparoscopy, 63 women (20.9%) were diagnosed with minimal-mild endometriosis (without endometriotic lesions affecting the ovary), in 239 patients (79%) ovarian surgery for endometriomas was performed. In 155 (51.3%) of them, endometriomas were localized on one ovary, and in 84 (27.8%), both ovaries were operated on for endometriomas.

During follow-up, menopause was documented in 43 women (14.2%). Mean age of menopause was 45.3 years (SD 4.3, range

32–52 years), which was significantly lower than age at menopause observed in the reference population (51.2 years, SD 3.8, range 45–56; $P = 0.0001$; Parazzini *et al.*, 2007). Another 18 patients showed premenopausal symptoms (irregular cycles, hot flushes, night sweats and vaginal dryness; Table III).

Ten patients in menopause (2 operated on for minimal-mild endometriosis, 2 bilateral ovarian endometriomas, 6 monolateral ovarian endometrioma) were older than 55 years at the time of follow-up. When comparing mean age of menopause in these women in our study with age at menopause in the reference Italian population of menopausal women (Parazzini *et al.*, 2007), the significant difference was confirmed with a mean age of 49.1 years, SD 2.6 ($P = 0.025$).

Among all 43 women in menopause, in 32 (74.4%) a laparoscopic cystectomy for ovarian endometrioma/s was performed. When stratifying results for type of ovarian surgery, women previously submitted to bilateral cystectomy were significantly younger at menopause than those with history of monolateral endometrioma (42.1 ± 5.1 years versus 47.1 ± 3.5 years, $P = 0.003$; Fig. 1). No difference was observed when comparing age of menopause in patients undergoing surgery for bilateral endometriomas with those not receiving any ovarian surgery (age at menopause 42.1 ± 5.1 years versus 45.1 ± 3 years, respectively; Table III). POF was observed in 7 of 43 (16.3%) menopausal patients, the majority of them, 4 (57.1%), were submitted to ovarian cystectomy for bilateral endometrioma (Table III). Among 199 women older than 40 years at follow-up, POF occurred in 3 cases (1.5%): 1 of 56 patients who never underwent ovarian surgery (1.8%), 1 of 103 patients after monolateral ovarian surgery (0.9%) and 1 of 40 women after surgery for bilateral ovarian endometriomas (2.5%).

When analyzing factors influencing age at menopause (menarche, BMI, smoking, menstrual cycle, oral contraceptive use, parity) between the premenopausal and menopausal women within groups receiving the same surgical treatment, no significant differences were observed (Table IV).

The relationship between total diameter of the preoperative ovarian endometriomas and age at menopause was significant in case of surgery for bilateral endometriomas ($R^2 = 0.754$, $P = 0.002$). Conversely, no relationship was found between age at onset of menopause and endometrioma diameter in case of unilateral ovarian endometrioma ($R^2 = 0.007$, $P = 0.738$; Figs 2 and 3).

Discussion

It has been demonstrated that surgery for ovarian endometrioma might damage healthy ovarian tissue; however, its impact on age at menopause has not been studied as well. In recent years, some authors have hypothesized surgery-related damage to menstrual function (Benaglia *et al.*, 2010). Reported menstrual cycle anomalies associated with ovarian endometrioma/s surgery include the entire spectrum of menstrual disorders, including POF (Busacca *et al.*, 2006).

Our data show that in women previously submitted to surgery for endometriosis, mean age at menopause is significantly lower than mean age of menopause observed in a reference population of Italian women (45.3 ± 4.3 years versus 51.2 ± 3.8 ; Parazzini, 2007). In patients with previous surgery for bilateral endometriomas, we observed a very young age at menopause (42.1 ± 5.1 years) and a high percentage of women with POF (36.4%) or lamenting

Table I Characteristics of 302 selected patients in study investigating if ovarian surgery for bilateral endometriomas influences age at menopause.

	Mean \pm SD/ Number (%)
Age, years (mean \pm SD) at the time of surgery	32.6 ± 5.6
Age, years (mean \pm SD) at the time of follow-up	41.7 ± 6.7
Menarche, years (mean \pm SD)	12.3 ± 1.5
BMI ($\text{kg}/\text{m}^2 \pm$ SD)	22.6 ± 3.4
Mean follow-up duration, years (mean \pm SD)	7.7 ± 4.6
Pain before surgery	229 (75.8%)
Dysmenorrhea	202 (66.9%)
Dyspareunia	78 (25.8%)
Chronic pelvic pain	129 (42.7%)
Infertility before surgery	144 (47.7%)
Duration of infertility, years (mean \pm SD) before surgery	3.2 ± 1.9
Pregnancies after surgery	145 (48.0%)
Spontaneous pregnancies	107
Pregnancy after ART	38
Women submitted to ART after surgery	55 (18.2%)
Recurrence of endometriosis	73 (24.2%)

ART, assisted reproduction technology.

Table II Characteristics of endometriosis in the 302 patients selected for the study.

	n (%) / mean \pm SD
No endometrioma	63 (20.9%)
Monolateral ovarian endometrioma	155 (51.3%)
Right endometrioma	65 (65/155, 41.9%)
Left endometrioma	90 (90/155, 58.1%)
Bilateral ovarian endometrioma	84 (27.8%)
Mean diameter of ovarian endometriomas (mm)	41.3 ± 18.7

Table III Frequency of patients with menopause, POF or lamenting menopausal symptoms (hot flushes, night sweats and vaginal dryness) after surgery for endometriosis.

	All patients	Peritoneal endometriosis, no ovarian endometrioma	Ovarian surgery	Monolateral endometrioma	Bilateral endometrioma
	302	63	239	155	84
Menopause, n (%)	43 (14.2%)	11 (17.5%)	32 (13.4%)	21 (13.5%)	11 (13.1%)
Mean age at menopause (years)	45.3 ± 4.3	45.1 ± 3 ^{a,b}	45.7 ± 4.5	47.1 ± 3.5 ^{a,c}	42.1 ± 5.1 ^{b,c}
POF (n)	7 (7/43, 16.3%)	2 ^{d,e} (2/11, 18.2%)	5 (5/32, 14.3%)	1 ^{d,f} (1/21, 4.8%)	4 ^{e,f} (4/11, 36.4%)
Menopausal symptoms (hot flushes, night sweats and vaginal dryness)	18 (18/259, 6.9%)	2 ^{g,h} (2/52, 3.8%)	16 (16/207, 7.7%)	7 ^{g,i} (7/134, 5.2%)	9 ^{h,i} (9/73, 12.3%)

Results are stratified according to the groups 'peritoneal endometriosis', 'monolateral endometrioma', 'bilateral endometriomas'. The mean age of menopause onset was calculated for each group.

^{a,b,c}Student t-test.

^P^a = 0.102; ^P^b = 0.117; ^P^c = 0.003.

^{d,e,f,g,h,i} χ^2 test.

^P^d = 0.266; ^P^e = 0.635; ^P^f = 0.037; ^P^g = 0.990; ^P^h = 0.184; ^Pⁱ = 0.120.

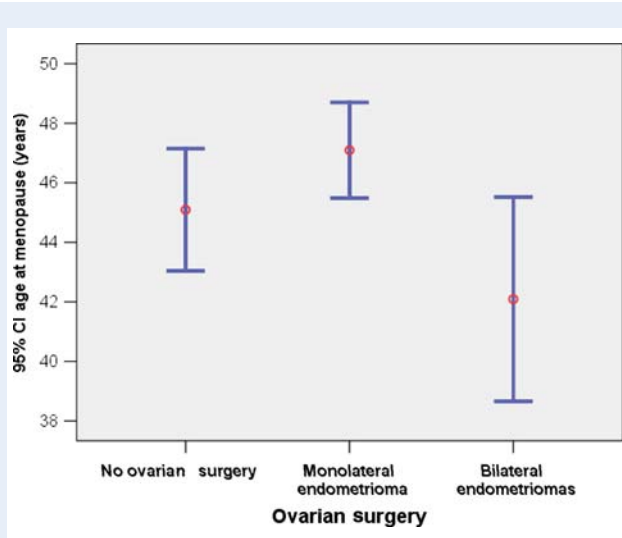


Figure 1 Chart showing the age of menopause onset for patients who do not receive any ovarian surgery, after surgery for monolateral ovarian endometrioma, after surgery for bilateral ovarian endometriomas. Mean age at menopause is shown (the mid-circles) and error bars represent the 95% confidence intervals (CIs). Data show a significantly younger age at menopause in the group submitted to surgery for bilateral ovarian endometriomas when compared with menopausal age after surgery for monolateral endometrioma (Mean menopausal age 42.1 ± 5.1 years in 'bilateral endometriomas group' versus 45.1 ± 3 years in 'no ovarian surgery group' and 47.1 ± 3.5 years in 'monolateral endometrioma group'). Student t-test: 'Bilateral endometriomas group' versus 'no ovarian surgery group': $P = 0.117$; 'Bilateral endometriomas group' versus 'monolateral endometrioma group': $P = 0.003$; 'Monolateral endometrioma group' versus 'no ovarian surgery group': $P = 0.102$.

menopausal symptoms (12.3%). Furthermore, no significant difference was found for any other factors affecting age at menopause between women of pre and post-menopausal age within the study groups.

Among women older than 40 years with previous surgery for bilateral endometriomas, we found 2.5% cases of POF, similar to Busacca's data (Busacca et al., 2006).

These results partially support other published data, and suggest a detrimental impact of surgery for bilateral endometriomas on ovarian function with consequent biological reproductive damage. Other authors observed a worse prognosis after IVF cycles in patients operated on for bilateral ovarian endometriomas (Esinler et al., 2006; Somigliana et al., 2008).

Surprisingly also in women with no history for ovarian surgery for endometriomas, we observed a very young age of menopause onset (45.1 years). It is not clear yet how endometriosis alone can influence the onset of the menopause.

Peritoneal endometriosis, implants on the surface of the peritoneum, seem to constitute an entity that is clinically and biologically distinct from ovarian endometriomas. They might be variants of the same pathologic process or they may be caused by different mechanisms (Nisolle and Donnez, 1997; Bulun, 2009).

Molecular studies suggest that women with minimal-mild endometriosis have an increased volume of peritoneal fluid containing more activated pro-inflammatory, chemotactic, angiogenic and oxidative stress factors (Podgaec et al., 2007; Mier-Cabrera et al., 2011). It seems reasonable that a hostile peritoneal environment might influence ovarian function.

Ding et al. (2010) observed that when oocytes and embryos were cultured in media with peritoneal fluid obtained from infertile women with mild endometriosis, the fertilization capability of oocytes and the development potential of embryos were decreased. They concluded that endometriotic peritoneal fluid may attenuate oocyte and embryo development by impairing the embryonic growth factor/receptor/signal transduction (Ding et al., 2010).

Recent studies on angiogenesis and the angiogenic factors associated with endometriotic lesions suggest that peritoneal endometriotic implants are lesions with a high potential for angiogenesis and invasion of extracellular matrix, while ovarian endometriomas are lesions with low capability of remodeling the surrounding tissue (Gilbert-Estellés

Table IV Comparison of factors influencing age at menopause (age at menarche, BMI, smoking, menstrual cycle, oral contraceptive use, parity) between the premenopausal and menopausal women within groups receiving the same surgical treatment.

Patients (n)	No endometrioma		Monolateral endometrioma		Bilateral endometrioma	
	52 no menopause	11 menopause	134 no menopause	21 menopause	73 no menopause	11 menopause
Age at menarche (years) (mean \pm SD)	12.2 \pm 1.5	12.4 \pm 0.9	12.4 \pm 1.3	12.5 \pm 1.9	12.1 \pm 1.6	13.1 \pm 1.5
BMI (kg/m ²) (mean \pm SD)	23.3 \pm 4.2	24.1 \pm 2.3	22.2 \pm 3.6	22.6 \pm 2.1	20.7 \pm 2.6	21.2 \pm 1.1
Smoke						
No	29 (55.8%)	8 (72.7%)	76 (56.7%)	8 (38.1%)	44 (60.3%)	4 (36.4%)
Yes	15 (28.8%)	2 (18.2%)	13 (9.7%)	4 (19%)	18 (24.6%)	5 (45.4%)
Ex-smoker	8 (15.4%)	1 (9.1%)	45 (33.6%)	9 (42.8%)	11 (15.1%)	2 (18.2%)
Menstrual cycle:						
Regular	47 (90.4%)	11 (100%)	112 (83.6%)	18 (85.7%)	64 (87.7%)	11 (100%)
Irregular	6 (11.5%)	0	22 (16.4%)	3 (14.3%)	9 (12.3%)	0
Oral contraceptive use:						
n (%)Years	3.5 \pm 4.4	2.1 \pm 4	6.1 \pm 5.1	4.7 \pm 6.9	4.7 \pm 4.4	5.2 \pm 3.8
Births, n (%)						
0	22 (42.3%)	8 (72.7%)	53 (39.5%)	9 (42.8%)	48 (65.7%)	9 (81.8%)
1	25 (48.1%)	2 (18.2%)	67 (50%)	7 (33.3%)	18 (24.7%)	2 (18.2%)
\geq 2	5 (9.6%)	1 (9.1%)	14 (10.5%)	5 (23.8%)	7 (9.6%)	0

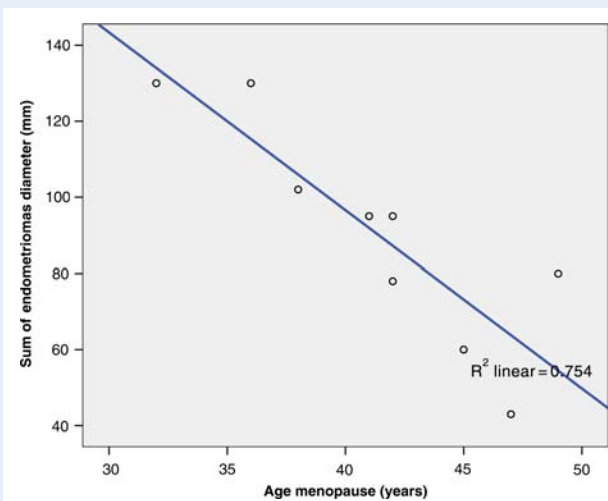


Figure 2 In case of bilateral ovarian endometriomas linear regression analysis, with curve estimation of the relationship between age at onset of menopause and sum of endometrioma diameters, demonstrated a significant linear correlation ($R^2 = 0.754$, $P = 0.002$; o, observed; —, linear).

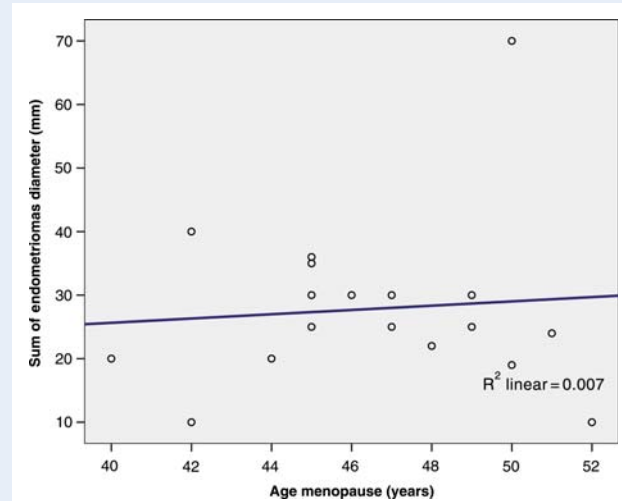


Figure 3 In case of unilateral ovarian endometriomas, linear regression analysis, with curve estimation of the relationship between age at onset of menopause and sum of endometrioma diameters, did not demonstrate a significant linear correlation ($R^2 = 0.007$, $P = 0.738$; o, observed; —, linear).

et al., 2007; Ramón *et al.*, 2011). Active peritoneal endometriotic implants are characterized by neovascularization and fibrosis formation. These biological differences might explain different regulation for various endometriotic lesions (Ramón *et al.*, 2011). Patients with peritoneal endometriosis and no ovarian involvement might represent

a subgroup of patients with an increased risk for earlier menopause, not related to ovarian surgery.

The effect of surgical injury on ovarian residual volume, ovarian artery blood flow and folliculogenesis after surgery for endometrioma treatment has been widely investigated. Several publications suggest

modifications of the cycle after endometrioma/s surgery (Busacca et al., 2006; Busacca and Vignali, 2009; Hirokawa et al., 2011).

Either the procedure of cystectomy itself or the surgical technique used has been blamed to cause ovarian dysfunction after surgery for ovarian endometriosis. The more suitable surgical approach for ovarian endometrioma was debated for a long time. Ablative techniques have been practically abandoned after the results of two randomized controlled trials, which observed better outcomes after cyst excision compared with cyst ablation using bipolar current (Beretta et al., 1998; Alborzi et al., 2004; Hart et al., 2008; Pellicano et al., 2008).

There are few published retrospective and comparative studies in favor of drainage and ablation or with similar cumulative clinical pregnancy rates compared with those observed after cystectomy (Sutton et al., 1997; Hemmings et al., 1998; Jones and Sutton, 2002; Sutton and Jones, 2002).

Some authors strongly suggest a potential role for electrosurgery in seriously impairing ovarian function. A retrospective study compared 47 consecutive women with a single ovary who underwent laparoscopic excisional surgery for ovarian endometrioma. In 21 patients a bipolar electrocoagulation was performed, whereas in 26 the ovary was sutured, and increased basal FSH levels were detected during the follicular phase in the former group. The authors concluded that bipolar electrocoagulation of the ovarian parenchyma after laparoscopic stripping of an endometriotic ovarian cyst might adversely affect ovarian function (Fedele et al., 2004).

A prospective non-randomized study compared laparoscopic ovarian cystectomy using bipolar or ultrasonic scalpel electrocoagulation and laparotomic ovarian cystectomy using sutures in 191 patients undergoing excision of benign ovarian cyst. The authors described changes in basal antral follicle number, peak systolic velocity and mean ovarian diameter of the operated ovary. A significant decrease of ovarian reserve in the bipolar group and the ultrasonic scalpel group was observed when comparing them with the suture group during a 12-month follow-up period. They concluded that electrocoagulation after laparoscopic excision of ovarian cysts is associated with reduction in ovarian reserve, which is partly a consequence of the damage to the ovarian vascular system (Li et al., 2009).

Obviously ovarian damage clearly depends on the surgical technique. In our study, all surgeries were performed by two laparoscopists (M.E.C., G.S.), and women with ovarian endometrioma/s were treated by laparoscopic stripping of the pseudocapsule, and complete excision of pelvic endometriotic lesions was performed using scissors or bipolar coagulation. Furthermore, the same surgeons are Specialist in Reproductive Pathophysiology, thus all the surgical procedures in patients of reproductive age were conducted with a cautious technique, and a very selective, gentle and careful bipolar coagulation of the bleeders after stripping the pseudocapsule was performed to avoid unnecessary trauma to healthy ovarian tissue and to the hilar vessels.

Some recent studies investigating endometrioma cyst walls after laparoscopic stripping, observed that ovarian tissue was inadvertently removed together with the cyst wall (Hachisuga and Kawarabayashi, 2002). In no case did this tissue demonstrate the normal follicular pattern seen in healthy ovaries (Muzii et al., 2002; Alborzi et al., 2009).

Whereas a direct proportional relationship between endometrioma size and the amount of ovarian parenchyma removed during

cystectomy has been reported (Roman et al., 2010), Somigliana et al. (2003) reported that the diameter of the cyst did not appear to play a relevant role in determining the number of follicles available for IVF procedures following ovarian cystectomy. Hirokawa's results also indicated no significant correlation between the cyst diameters and the rates of decline of serum anti-Mullerian hormone levels (Hirokawa et al., 2011).

In our study, simple linear regression analyses showed a significant relationship between the preoperative ovarian endometriomas total diameter and age at menopause in women submitted to surgery for bilateral ovarian endometriomas ($R^2 = 0.754$, $P = 0.002$). A larger size of ovarian endometriomas was associated with a younger age at menopause onset.

These data indirectly confirm that the amount of ovarian parenchyma lost at the time of surgery increases proportionally with increases in cyst diameter. Consequently the ovarian damage is dependent on the endometrioma size. The same relationship was not confirmed in case of unilateral ovarian endometrioma: in these cases, the contralateral intact ovary might adequately compensate for the reduced function of the affected one (Benaglia et al., 2010). Thus, the endometrioma-related damage to ovarian reserve become clinically evident in women surgically treated for bilateral endometriomas.

Endometriosis affects 6–10% of women of reproductive age (Giudice, 2010), 17–44% of patients with this disease have ovarian endometrioma and both ovaries are involved in 19–28% of cases (Vercellini et al., 1998; Prefumo et al., 2002; Al-Fozan and Tulandi, 2003). Thus bilateral endometrioma, although less frequent, is not a rare condition. In our data, 27.8% of patients were operated on for bilateral ovarian endometriomas.

The current study has some limitations that must be taken into account. Clearly, the ideal case-control study to detect whether surgery rather than endometriosis itself has any impact on ovarian aging would be to compare women with endometriomas that had, or had not, been previously excised. In our study, only 43 (14.2%) women reached the menopause and, in addition, patients who were not able to come to periodic visits were contacted by telephone. Another limitation of this study is the high drop-out rate of our participants (44.5%). Obviously, the high drop-out rate led to a lower statistical power but we should also consider the long-term follow-up of the study.

Endometriosis is a chronic disease that affects women throughout their reproductive life. Thus studies with a follow-up relatively short compared with the duration of disease are not rational and tend to underestimate the effects of the treatment. Consequently, longer term follow-up is crucial to better understand this enigmatic disease.

Factors that affect the timing of menopause may have important clinical implications because an early age at menopause has been associated with increased cardiovascular mortality and stroke, bone fracture and colorectal cancer risks. Quality of life may be significantly decreased, whereas sexual dysfunction and neurological disease may be increased later in life (Broekmans et al., 2009). Thus, it is important to recognize factors affecting menopause as a mean of identifying women and quantifying the risk for these conditions in order to prevent its complications. Further studies with larger samples and long-term follow-up are needed to confirm our finding and provide more information about factors involved in determining age at menopause in women with endometriosis.

To our knowledge, this is the first study examining the age at menopause in women with a history of surgery for endometriosis. Both ovarian surgery for endometriomas and endometriosis as a disease appear to influence age at menopause. Ovarian surgery might be an additional risk factor. All women with endometriosis included in our study group showed a younger age at menopause when compared with the reference Italian women. Moreover, surgery for bilateral ovarian endometriomas might significantly increase the risk for POF. This risk appears directly related to the size of ovarian endometriomas.

Authors' roles

M.E.C. performed surgeries, played a role in major contribution to conception and design, and interpretation of data, drafting the article and final approval of the version to be published; F.R. made a substantial contribution to conception and design, the acquisition, analysis of data, drafting and revising the article critically, and final approval of the version to be published; G.M. helped with the acquisition and analysis of the data; C.B. helped with the conception of the study, revised the article critically, and approved the final version of the manuscript to be published; A.P. helped in interpretation of data, revised the article critically, and approved the final version of the manuscript to be published; G.S. performed surgeries, revised the article critically, and final approval of the version to be published.

References

- Alborzi S, Momtahan M, Parsanezhad ME, Dehbashi S, Zolghadri J, Alborzi S. A prospective, randomized study comparing laparoscopic ovarian cystectomy versus fenestration and coagulation in patients with endometriomas. *Fertil Steril* 2004;**82**:1633–1637.
- Alborzi S, Foroughinia L, Kumar PV, Asadi N, Alborzi S. A comparison of histopathologic findings of ovarian tissue inadvertently excised with endometrioma and other kinds of benign ovarian cyst in patients undergoing laparoscopy versus laparotomy. *Fertil Steril* 2009;**92**:2004–2007.
- Al-Fozan H, Tulandi T. Left lateral predisposition of endometriosis and endometrioma. *Obstet Gynecol* 2003;**101**:164–166.
- Almog B, Shehata F, Sheizaf B, Tan SL, Tulandi T. Effects of ovarian endometrioma on the number of oocytes retrieved for *in vitro* fertilization. *Fertil Steril* 2011;**95**:525–527.
- Benaglia L, Somigliana E, Vighi V, Ragni G, Vercellini P, Fedele L. Rate of severe ovarian damage following surgery for endometriomas. *Hum Reprod* 2010;**25**:678–682.
- Beretta P, Franchi M, Ghezzi F, Busacca M, Zupi E, Bolis P. Randomized clinical trial of two laparoscopic treatments of endometriomas: cystectomy versus drainage and coagulation. *Fertil Steril* 1998;**70**:1176–1180.
- Broekmans FJ, Soules MR, Fauser BC. Ovarian aging: mechanisms and clinical consequences. *Endocr Rev* 2009;**30**:465–493.
- Bulun SE. Endometriosis. *N Engl J Med* 2009;**360**:268–279.
- Busacca M, Vignali M. Endometrioma excision and ovarian reserve: a dangerous relation. *J Minim Invasive Gynecol* 2009;**16**:142–148.
- Busacca M, Riparini J, Somigliana E, Oggioni G, Izzo S, Vignali M, Candiani M. Postsurgical ovarian failure after laparoscopic excision of bilateral endometriomas. *Am J Obstet Gynecol* 2006;**195**:421–425.
- Canis M, Rabischong B, Houle C, Botchorishvili R, Jardon K, Safi A, Wattiez A, Mage G, Pouly JL, Bruhat MA. Laparoscopic management of adnexal masses: a gold standard? *Curr Opin Obstet Gynecol* 2002;**14**:423–428.
- Daniell JF, Kurtz BR, Gurley LD. Laser laparoscopic management of large endometriomas. *Fertil Steril* 1991;**55**:692–695.
- de Ziegler D, Borghese B, Chapron C. Endometriosis and infertility: pathophysiology and management. *Lancet* 2010;**376**:730–738.
- Ding GL, Chen XJ, Luo Q, Dong MY, Wang N, Huang HF. Attenuated oocyte fertilization and embryo development associated with altered growth factor/signal transduction induced by endometriotic peritoneal fluid. *Fertil Steril* 2010;**93**:2538–2544.
- Di Prospero F, Micucci G. Is operative laparoscopy safe in ovarian endometriosis? *Reprod Biomed Online* 2009;**18**:167.
- Donnez J, Nisolle M, Gillet N, Smets M, Bassil S, Casanas-Roux F. Large ovarian endometriomas. *Hum Reprod* 1996;**11**:641–646.
- Esinler I, Bozdag G, Aybar F, Bayar U, Yarali H. Outcome of *in vitro* fertilization/intracytoplasmic sperm injection after laparoscopic cystectomy for endometriomas. *Fertil Steril* 2006;**85**:1730–1735.
- Fedele L, Bianchi S, Zanonato G, Bergamini V, Berlanda N. Bipolar electrocoagulation versus suture of solitary ovary after laparoscopic excision of ovarian endometriomas. *J Am Assoc Gynecol Laparosc* 2004;**11**:344–347.
- Garcia-Velasco JA, Somigliana E. Management of endometriomas in women requiring IVF: to touch or not to touch. *Hum Reprod* 2009;**24**:496–501.
- Gilbert-Estellés J, Ramón LA, España F, Gilbert J, Vila V, Réganon E, Castelló R, Chirivella M, Estellés A. Expression of angiogenic factors in endometriosis: relationship to fibrinolytic and metalloproteinase systems. *Hum Reprod* 2007;**22**:2120–2127.
- Giudice LC. Clinical practice. Endometriosis. *N Engl J Med* 2010;**362**:2389–2398.
- Hachisuga T, Kawarabayashi T. Histopathological analysis of laparoscopically treated ovarian endometriotic cysts with special reference to loss of follicles. *Hum Reprod* 2002;**17**:432–435.
- Hart RJ, Hickey M, Maouris P, Buckett W. Excisional surgery versus ablative surgery for ovarian endometriomata. *Cochrane Database Syst Rev* 2008;CD004992.
- Hemmings R, Bissonnette F, Bouzayen R. Results of laparoscopic treatments of ovarian endometriomas: laparoscopic ovarian fenestration and coagulation. *Fertil Steril* 1998;**70**:527–529.
- Hirokawa W, Iwase A, Goto M, Takikawa S, Nagatomo Y, Nakahara T, Bayasula B, Nakamura T, Manabe S, Kikkawa F. The post-operative decline in serum anti-Müllerian hormone correlates with the bilaterality and severity of endometriosis. *Hum Reprod* 2011;**26**:904–910.
- Jones KD, Sutton CJ. Pregnancy rates following ablative laparoscopic surgery for endometriomas. *Hum Reprod* 2002;**17**:782–785.
- Karita M, Yamashita Y, Hayashi A, Yoshida Y, Hayashi M, Yamamoto H, Tanabe A, Terai Y, Ohmichi M. Does advanced-stage endometriosis affect the gene expression of estrogen and progesterone receptors in granulosa cells? *Fertil Steril* 2011;**95**:889–894.
- Li CZ, Liu B, Wen ZQ, Sun Q. The impact of electrocoagulation on ovarian reserve after laparoscopic excision of ovarian cysts: a prospective clinical study of 191 patients. *Fertil Steril* 2009;**92**:1428–1435.
- Mier-Cabrera J, Jiménez-Zamudio L, García-Latorre E, Cruz-Orozco O, Hernández-Guerrero C. Quantitative and qualitative peritoneal immune profiles, T-cell apoptosis and oxidative stress-associated characteristics in women with minimal and mild endometriosis. *BJOG* 2011;**118**:6–16.
- Muzii L, Bianchi A, Crocè C, Mancini N, Panici PB. Laparoscopic excision of ovarian cysts: is the stripping technique a tissue-sparing procedure? *Fertil Steril* 2002;**77**:609–614.

- Muzii L, Bellati F, Bianchi A, Palaia I, Mancini N, Zullo MA, Angioli R, Panici PB. Laparoscopic stripping of endometriomas: a randomized trial on different surgical techniques. Part II: pathological results. *Hum Reprod* 2005;**20**:1987–1992.
- Nisolle M, Donnez J. Peritoneal endometriosis, ovarian endometriosis and adenomyotic nodules of the rectovaginal septum are three different entities. *Fert Steril* 1997;**68**:585–596.
- Parazzini F; Progetto Menopausa Italia Study Group. Determinants of age at menopause in women attending menopause clinics in Italy. *Maturitas* 2007;**56**:280–287.
- Pellicano M, Bramante S, Guida M, Bifulco G, Di Spiezio Sardo A, Cirillo D, Nappi C. Ovarian endometrioma: postoperative adhesions following bipolar coagulation and suture. *Fertil Steril* 2008;**89**:796–7999.
- Podgaec S, Abrao MS, Dias JA Jr, Rizzo LV, de Oliveira RM, Baracat EC. Endometriosis: an inflammatory disease with a Th2 immune response component. *Hum Reprod* 2007;**22**:1373–1379.
- Practice Committee of the American Society for Reproductive Medicine. Treatment of pelvic pain associated with endometriosis. *Fertil Steril* 2006;**86**:S18–S27.
- Prefumo F, Todeschini F, Fulcheri E, Venturini PL. Epithelial abnormalities in cystic ovarian endometriosis. *Gynecol Oncol* 2002;**84**:280–284.
- Ramón LA, Braza-Boils A, Gilibert-Estellés J, Gilibert J, España F, Chirivella M, Estellés A. microRNAs expression in endometriosis and their relation to angiogenic factors. *Hum Reprod* 2011;**26**:1082–1090.
- Revised American Society for Reproductive Medicine classification of endometriosis: 1996. *Fertil Steril* 1997;**67**:817–821.
- Roman H, Tarta O, Pura I, Opris I, Bourdel N, Marpeau L, Sabourin JC. Direct proportional relationship between endometrioma size and ovarian parenchyma inadvertently removed during cystectomy, and its implication on the management of enlarged endometriomas. *Hum Reprod* 2010;**25**:1428–1432.
- Somigliana E, Ragni G, Benedetti F, Borroni R, Vegetti W, Crosignani PG. Does laparoscopic excision of endometriotic ovarian cysts significantly affect ovarian reserve? Insights from IVF cycles. *Hum Reprod* 2003;**18**:2450–2453.
- Somigliana E, Arnoldi M, Benaglia L, Iemmello R, Nicolosi AE, Ragni G. IVF-ICSI outcome in women operated on for bilateral endometriomas. *Hum Reprod* 2008;**23**:1526–1530.
- Sutton CJ, Jones KD. Laser laparoscopy for endometriosis and endometriotic cysts. *Surg Endosc* 2002;**16**:1513–1517.
- Sutton CJ, Ewen SP, Jacobs SA, Whitelaw NL. Laser laparoscopic surgery in the treatment of ovarian endometriomas. *J Am Assoc Gynecol Laparosc* 1997;**4**:319–323.
- Taylor RN, Lebovic DI. Endometriosis. In: Strauss JF III, Barbieri RL (eds). *Yen and Jaffe's Reproductive Endocrinology*. Philadelphia: Saunders-Elsevier, 2009,577–595.
- Vercellini P, Aimi G, De Giorgi O, Maddalena S, Carinelli S, Crosignani PG. Is cystic ovarian endometriosis an asymmetric disease? *Br J Obstet Gynaecol* 1998;**105**:1018–1021.
- Woad KJ, Watkins WJ, Prendergast D, Shelling AN. The genetic basis of premature ovarian failure. *Aust N Z J Obstet Gynaecol* 2006;**46**:242–244.
- World Health Organization Scientific Group. *Research on the Menopause*. Geneva, Switzerland: World Health Organization, 1981. WHO Technical Report Series, No. 670.