UNIVERSITÀ DEGLI STUDI FIRENZE

FLORE
Repository istituzionale dell'Università degli Studi di Firenze

EANM guidelines for ventilation/perfusion scintigraphy: Part 1. Pulmonary imaging with ventilation/perfusion single photon emission

Questa è la Versione finale referata (Post print/Accepted manuscript) della seguente pubblicazione:

Original Citation:

EANM guidelines for ventilation/perfusion scintigraphy: Part 1. Pulmonary imaging with ventilation/perfusion single photon emission tomography / M. Bajc; J.B. Neilly; M. Miniati; K. Schuemichen; M. Meignan; B. Jonson: EANM Committee.. - In: EUROPEAN JOURNAL OF NUCLEAR MEDICINE AND MOLECULAR IMAGING. - ISSN 1619-7070. - STAMPA. - 36:(2009), pp. 1356-1370. [10.1007/s00259-009-1170-5]

Availability:

This version is available at: 2158/774307 since:

Published version:

DOI: 10.1007/s00259-009-1170-5

Terms of use:

Open Access

La pubblicazione è resa disponibile sotto le norme e i termini della licenza di deposito, secondo quanto stabilito dalla Policy per l'accesso aperto dell'Università degli Studi di Firenze (https://www.sba.unifi.it/upload/policy-oa-2016-1.pdf)

Publisher copyright claim:

(Article begins on next page)

12 October 2024

Eur J Nucl Med Mol Imaging (2009) 36:1356–1370
DOI 10.1007/s00259-009-1170-5

GUIDELINES

EANM guidelines for ventilation/perfusion scintigraphy

Part 1. Pulmonary imaging with ventilation/perfusion single photon emission tomography

M. Bajc · J. B. Neilly · M. Miniati · C. Schuemichen · M. Meignan · B. Jonson

Published online: 27 June 2009
© EANM 2009

Abstract Pulmonary embolism (PE) can only be diagnosed with imaging techniques, which in practice is performed using ventilation/perfusion scintigraphy (V/P_{SCAN}) or multidetector computed tomography of the pulmonary arteries (MDCT). The epidemiology, natural history, pathophysiology and clinical presentation of PE are briefly reviewed. The primary objective of Part 1 of the Task Group's report was to develop a methodological approach to and interpretation criteria for PE. The basic principle for the diagnosis of PE based upon V/P_{SCAN} is to recognize lung segments or subsegments without perfusion but preserved ventilation, i.e. mismatch. Ventilation studies are in general performed after inhalation of Krypton or technetium-labelled aerosol of diethylene triamine pentaacetic acid (DTPA) or Technegas. Perfusion studies are performed after intravenous injection of macroaggregated human albumin. Radiation exposure using documented isotope doses is 1.2–2 mSv. Planar and tomographic techniques (V/P_{PLANAR} and V/P_{SPECT}) are analysed. V/P_{SPECT} has higher sensitivity and specificity than V/P_{PLANAR}. The interpretation of either V/P_{PLANAR} or V/P_{SPECT} should follow holistic principles rather than obsolete probabilistic rules. PE should be reported when mismatch of more than one subsegment is found. For the diagnosis of chronic PE, V/P_{SCAN} is of value. The additional diagnostic yield from V/P_{SCAN} includes chronic obstructive lung disease (COPD), heart failure and pneumonia. Pitfalls in V/P_{SCAN} interpretation are considered. V/P_{SPECT} is strongly preferred to V/P_{PLANAR} as the former permits the accurate diagnosis of PE even in the presence of comorbid diseases such as COPD and pneumonia. Technegas is preferred to DTPA in patients with COPD.

Keywords Pulmonary embolism · Radioncuclide imaging · Ventilation perfusion scintigraphy · Single photon emission tomography · Multidetector CT scan'

Abbreviations

COPD	Chronic obstructive pulmonary disease
DTPA	Diethylene triamine pentaacetic acid
DVT	Deep venous thrombosis
MAA	Macroaggregated human albumin
MDCT	Multidetector computed tomography of the pulmonary arteries
PA	Contrast-enhanced pulmonary angiography

M. Bajc (✉) · B. Jonson
Department of Clinical Physiology, Lund University Hospital,
S-221 85 Lund, Sweden
e-mail: Marika.bajc@med.lu.se

B. Jonson
e-mail: Bjorn.Jonson@med.lu.se

J. B. Neilly
University Medical Unit and Department of Nuclear Medicine,
Glasgow Royal Infirmary,
Glasgow, G31 2ER Scotland, UK
e-mail: jneilly@clinmed.gla.ac.uk

M. Miniati
Department of Medical and Surgical Critical Care,
University of Florence,
Viale Morgagni 85, 50134 Florence, Italy
e-mail: Massimo.Miniati@unifi.it

C. Schuemichen
Clinic for Nuclear Medicine, University of Rostock,
Gertrudenplatz 1, DE–18057 Rostock, Germany
e-mail: carl.schuemichen@med.uni-rostock.de

M. Meignan
Department of Nuclear Medicine,
Centre Hospitalo Universitaire Henri Mondor, Universite Paris 12,
94000 Créteil, France
e-mail: michel.meignan@hmn.aphp.fr

PE	Pulmonary embolism
VTE	Venous thromboembolism
V/P_{PLANAR}	Ventilation/perfusion scintigraphy with planar imaging
V/P_{SCAN}	Ventilation/perfusion scintigraphy
V/P_{SPECT}	Ventilation/perfusion single photon emission computed tomography

Introduction

PE is an important and treatable illness caused by migration of thrombus to the pulmonary circulation commonly from the veins of the lower extremities. Untreated, PE can cause death [1] or lead to chronic thromboembolic pulmonary hypertension [2]. Appropriate treatment can prevent recurrence of PE and facilitate resolution of existing clot, so aiding recovery. However, treatments, which include heparin, oral anticoagulants and thrombolytic agents, have well-documented side effects. Therefore it is imperative that early diagnosis of PE is made and that treatment is instituted when appropriate.

While there are nonthrombotic causes of PE such as septic, fat, amniotic fluid, and air emboli, the term PE in this article is used to refer to thrombotic emboli. This is the area where radionuclide lung scanning has been most studied. This article explores the role of V/P_{SCAN} and its utility in the accurate diagnosis of PE due to thrombotic disease. Moreover, the potential role of V/P_{SPECT} for the diagnosis of other cardiopulmonary diseases is presented as well as its suitability for follow-up and research.

Epidemiology

The incidence of PE is notoriously difficult to establish due to inaccuracies in hospital discharge records, but is estimated to be in the region of 100 cases per 100,000 person years [3]. This estimate appears to be stable over time since the incidence was the same in the 1980s as in the 1990s in the US [4]. In Malmö, Sweden, the prevalence of PE at autopsy has been found to be 18% [5]. In 13% of autopsies, PE was considered to be the main or contributory cause of death. In the absence of risk factors, PE is rare in children under 15 years of age (<5 per 100,000). It increases dramatically after the age of 60 years [3]. The incidence of VTE is similar in males and females. Risk factors associated with the development of VTE are well documented [6] and include inherited and acquired factors. Amongst the acquired factors, underlying malignancy and recent immobilization or surgery are the most important and well-known ones. A more recently recognized risk factor is long-distance flights, even in healthy individuals [7].

Natural history of PE

Early studies documented the natural history of VTE. Using fibrinogen uptake, Kakkar et al. found that DVT developed in 30% of 132 patients undergoing surgery without prophylaxis [8]. DVT developed in the calf veins in the majority, and propagated to the proximal leg veins in 13%. PE developed in 44% of patients with proximal DVT. Further evidence that DVT and PE are distinct manifestations of the same disease process, referred to as VTE, comes from the observation that in the majority of patients with PE, DVT can be detected using sensitive methods. In patients with proven leg vein DVT, 40% have asymptomatic PE [9]. However, while there is homology within VTE, there are important epidemiological differences between DVT and PE. Mortality is higher for PE than for DVT [3]. In the International Cooperative Embolism Registry [10] set up to determine baseline mortality rates and mechanisms of death, the 3-month overall mortality rate was 15% and the factors that were significantly associated with increased mortality were systolic arterial hypotension, congestive heart failure, cancer, tachypnoea, right ventricular hypokinesia, COPD, and age >70 years. Resolution of PE is variable. It has been reported that a majority of patients have unresolved PE at 6 months from diagnosis [11]. Others have reported rapid resolution of a large PE within hours of the onset of heparin therapy [12]. Fredin and Arborelius noted complete restoration of lung perfusion in patients with PE within 1 week of diagnosis [13]. On the basis of this rapidly changing pattern of perfusion in PE, Coakley recommended that imaging tests for PE diagnosis should be carried out as soon as possible, preferably within 24 h after onset of symptoms [14].

Pathophysiology of PE

The pathophysiology of PE has been reviewed [15, 16]. Ventilation of unperfused regions will cause increased dead space [17]. This is one reason for dyspnoea. Hypoxia, often seen in major PE, is caused by several mechanisms. Emboli occluding pulmonary end arteries may lead to haemorrhage, pleuritic pain, pleural effusion and atelectasis. The lung has no pain fibres. Pain with PE indicates involvement of parietal pleura.

The haemodynamic effects of major PE on the circulation have been recently reviewed [18]. Increased pulmonary vascular resistance may lead to right ventricle strain and failure, electromechanical dissociation, hypotension syncope and sudden death. An increase in right atrial pressure can lead to right to left shunt through a patent foramen ovale that contributes to hypoxaemia. The shunt can also lead to paradoxical emboli, implying that thrombus of venous origin

causes infarctions in the major circulation, commonly the brain [19].

Clinical presentation of PE

The clinical spectrum of PE in humans ranges from asymptomatic to sudden death. Various studies have shown that PE may be clinically silent [9]. The majority of patients with PE present with recognized patterns of symptoms that may include unexplained breathlessness, chest pain (central or pleuritic), cough, haemoptysis, syncope, palpitations, tachypnoea, tachycardia (heart rate >100 bpm), cyanosis, fever, hypotension (systolic blood pressure <100 mmHg), right heart failure, pulmonary hypertension and leg swelling. However, these clinical features are also common in patients who turn out not to have PE [20]. These clinical features may develop abruptly or insidiously over days and weeks. While certain symptoms and signs are more commonly observed in PE than in other conditions, it is not possible to confirm a diagnosis of PE on clinical features alone. The diagnosis PE must be confirmed or refuted on the basis of a conclusive imaging test.

Objectives

The primary objective of the Task Group was to develop guidelines for the use of V/P_{SCAN} for the diagnosis and follow-up of PE. A further objective was to promote its rational use in routine clinical practice using state of the art methodology. In this first part of the Guidelines, the principles and techniques for V/P_{SPECT} are presented, as well as its clinical utility for diagnosis of PE and additional cardiopulmonary diagnoses.

Imaging tests for the diagnosis of PE

As detailed above, PE is a disease with a high mortality if left untreated. Treatment is associated with significant risks. The diagnosis cannot be established solely on the basis of clinical observations or on the outcome of simple investigations such as ECG, chest plain radiography or blood chemistry. It follows that imaging tests are required to confirm or refute a diagnosis of PE. A number of imaging tests have been employed for this purpose as follows:

1. Conventional PA, previously regarded as the gold standard.
2. V/P_{SCAN} was for a long time the principal diagnostic method of choice. Occasionally, perfusion-only lung scanning is performed.
3. MDCT angiography is now frequently cited as the primary diagnostic method for the diagnosis of PE.
4. Magnetic resonance pulmonary angiography is still at an early stage of development.

In a study by Baile et al. using a methacrylate cast of the porcine pulmonary vessels as the independent standard, PA had a sensitivity of only 87 % and a positive predictive value of 88% [21]. They concluded that the use of PA as the gold standard can be misleading. Additionally, PA is invasive, difficult to perform and not readily available. Interpretation is complicated by wide interobserver variability [22, 23]. PA is now rarely used in routine clinical practice. Still, in special cases, PA has a role in centres with highly qualified angiographers. Methods based upon magnetic resonance are not yet established and are not discussed further.

V/P_{SCAN} for the diagnosis of PE is universally available but imaging protocols and interpretative strategies show large variation. It is important to analyse such variations as a basis for guidelines with the intention of standardizing methods for imaging and interpretation throughout Europe.

Basic principles of PE diagnosis

V/P_{SCAN} exploits the unique pulmonary arterial segmental anatomy. Each bronchopulmonary segment is supplied by a single end-artery (Fig. 1). In principle conical bronchopulmonary segments have their apex towards the hilum and base projecting onto the pleural surface. Occlusive thrombi affecting individual pulmonary arteries therefore produce characteristic lobar, segmental or subsegmental peripheral wedge-shaped defects with the base projecting to the lung periphery (Fig. 2).

V/P mismatch Within bronchopulmonary segment(s) affected by PE, ventilation is usually preserved. This pattern of preserved ventilation and absent perfusion within a lung segment gives rise to the fundamental rubric for PE diagnosis using V/P_{SCAN} known as V/P mismatch. At a later stage, when emboli become partly resolved or recanalization occurs, the pattern of V/P mismatch becomes less distinct. It is generally accepted that a normal pulmonary perfusion pattern excludes PE adequately [24–26]. PE are commonly multiple, most likely because emboli fragment when passing through the right heart and main pulmonary arteries. PE can be a single event or a recurring process giving rise to multiple emboli over short or long periods of time. It is important to note that V/P mismatch is not caused exclusively by PE. V/P mismatch involving pulmonary, lobar, segmental or subsegmental arteries may be caused by other disorders such as congenital pulmonary vascular abnormalities, venoocclusive disease, vasculitis, lung cancer or tuberculous mediastinal adenopathy [27, 28].

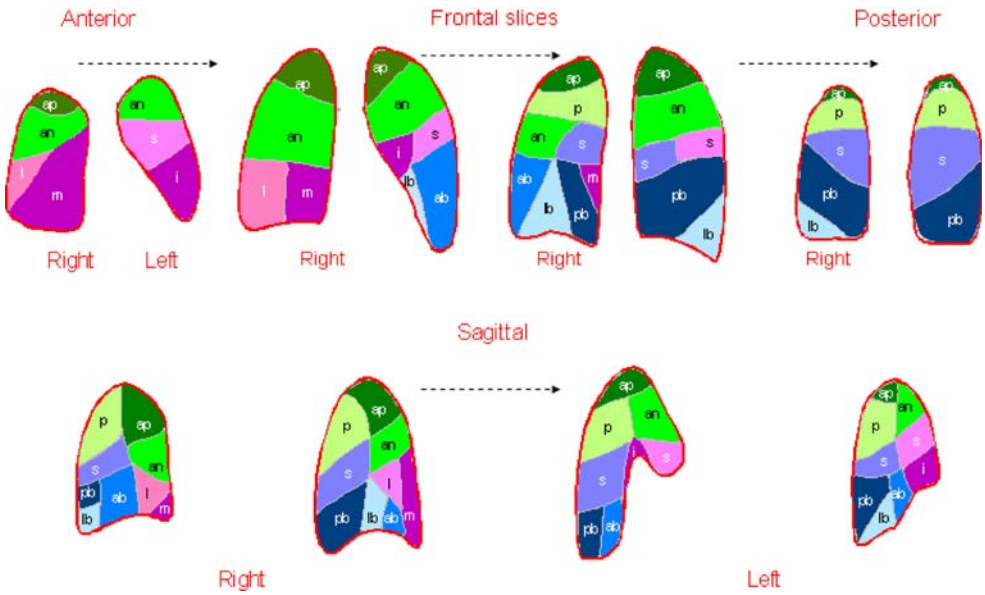

Fig. 1 Segmental map of the lungs as frontal slices from anterior to posterior and sagittal slices from right periphery to left periphery

V/P match It has long been recognized that the pulmonary arterial circulation can be affected by intrinsic disorders of the lung, other than PE. In these lung disorders, it is usually the case that both ventilation and perfusion are affected. Perfusion defects associated with ventilation defects are usually caused by disorders of the airways or the lung parenchyma. Such patterns are referred to as V/P match or in cases where ventilation is more severely affected than perfusion, reversed V/P mismatch.

The diagnosis of PE using V/P_{SCAN} is therefore based upon the finding of V/P mismatch. The ventilation scan maps regional ventilation and helps define lung borders, thereby facilitating the recognition of peripheral perfusion defects. The ventilation scan may also provide additional information about cardiopulmonary disorders other than PE. For example, in COPD, the distribution of ventilation is uneven and in aerosol studies focal deposition is often observed in central or peripheral airways. Pneumonias cause regional ventilation defects, usually more extensive than the associated perfusion defects. Preserved perfusion along the pleural border, recognized as the "stripe sign" may be observed [29, 30].

A combined ventilation and perfusion study increases the specificity for PE diagnosis and allows recognition of alternative pathology. It is therefore recommended that in PE diagnosis, a combined 1-day protocol is used. Otherwise, up to 60% false-positive results may occur in elderly patients, since obstructive airway disease increases significantly with age [31]. By contrast, ventilation scans are often normal in young healthy individuals, for example in pregnancy. To cut down on radiation exposure, a ventilation scan can be avoided in the majority of patients in the first trimester of pregnancy.

Ventilation scintigraphy

For mapping regional ventilation the following products are used: inert gases ^{133}Xe and ^{81m}Kr, and radiolabelled aerosols ^{99m}Tc-DTPA and ^{99m}Tc-labelled Technegas.

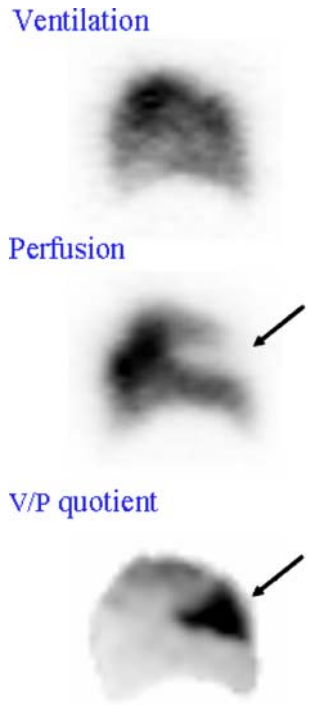

Fig. 2 Sagittal slice of the left lung in a patient with PE. The perfusion defect is wedge-shaped (*arrow*). Ventilation is preserved. The abnormality is highlighted in the V/P quotient image (*arrow*)

^{133}Xe

^{133}Xe is historically the agent that was used for ventilation studies [32, 33]. It has a half-life of 5 days and allows studies of regional ventilation. In the PIOPED I study, the simple single-breath technique was used in most cases [34]. ^{131}Xe was inhaled and during the first 20 s one image was obtained from the posterior view. Due to the low energy of ^{131}Xe (81 keV) insufficient information was obtained from anterior parts of the lung. Frequently, perfusion defects caused by obstruction will be regarded as mismatch, leading to a false-positive PE diagnosis [35]. The availability of ^{133}Xe in Europe is limited and it is hardly used for the diagnosis of PE.

^{81m}Kr

^{81m}Kr is a gas produced from a generator of rubidium (^{81}Ru) [36]. This gas has the ideal gamma energy of 193 keV and a half-life of 13 s. The short half-life implies that inhaled ^{81m}Kr disappears from the alveolar space at a much faster rate by decay than by exhalation. When a patient is breathing air with ^{81m}Kr at a normal respiratory rate, the regional alveolar ^{81m}Kr concentration is at steady state, closely proportional to regional ventilation. Deviation from proportionality occurs in lung compartments with very high or low regional ventilation in relation to resident alveolar volume [37]. This deviation occurs in young children with a high ventilatory rate and a high ventilation/volume ratio [38]. During steady-state ^{81m}Kr ventilation, multiple planar imaging or SPECT acquisition is feasible. Very recently, V/P_{SPECT} in combination with low-dose CT has been described [39].

^{81m}Kr is a true gas that does not cause artefacts due to central airway deposition. An advantage is that ventilation and perfusion can be imaged simultaneously as ^{81m}Kr has higher gamma energy than ^{99m}Tc, which is used as a perfusion marker (140 keV) [40–42]. As ^{81}Ru has a half-life of 4.6 h, the generator can be used for 1 day only. Limited access, high cost and the need for a daily generator explains why ^{81m}Kr is not widely used. However, ^{81m}Kr remains a valuable alternative to aerosols. Very low radiation exposure makes ^{81m}Kr particularly suitable for use in children [38].

Aerosols

For ventilation scintigraphy, radioaerosols are usually used. An aerosol is a relatively time-stable two-phase system consisting of particles suspended in gas (air). The radiolabelled particles may be liquid, solid or a combination of the two. The percentage of particles remaining in the lung after inhalation (deposition fraction), depends on the aerodynamic properties of the particles, mainly their size. Deposition fraction is up to 50% with ultrafine nanoparticles (diameter 0.02). These are deposited predominantly in the alveolar region by diffusion [43]. The deposition fraction decreases to 25% with nanoparticles of diameter 0.1 μm [44]. The lowest deposition fraction is found with particles of diameter 0.45 μm [43]. At this particle size, the aerosol is particularly stable because diffusion and sedimentation as deposition mechanisms balance each other. These fine particles are still able to penetrate to the alveolar region [45].

Another deposition mechanism is impaction that occurs with particles of diameter >1 μm in the lower respiratory tract. Particles of diameter >5 μm impact in the upper airways. Even small particles may impact with turbulent flow at stenoses. This leads to hot spots, indicative of obstructive airway disease. Breathing pattern is also of importance for aerosol deposition [46]. At slow tidal breathing even relatively large particles may reach the lung periphery [47].

The radioactivity carried by each liquid particle is proportional to its volume, which increases with the cube of the diameter. Doubling the diameter increases the volume by a factor of eight. The deposition pattern depends not only upon particle size but also on, for example, particle shape. The composite property of a particle is therefore expressed as its aerodynamic diameter. The two most important characteristics of an aerosol are mass median aerodynamic diameter (MMAD) and dispersion expressed as its geometric standard deviation. MMAD should preferably be <1.2 μm [48–51]. A further complicating issue is that liquid particles are hydrophilic and grow in size in the humidity of airways.

Several nebulizers producing liquid aerosols are available on the market. The MMAD of the droplets should be as low as possible. The maximum droplet size inhaled by the patient should not exceed 2 μm. Because of the complex physics behind aerosol deposition patterns, the performance of a nebulizer must be clinically tested. Poor performance is characterized by a high degree of deposition in conducting airways. In patients with obstructive airway disease, a predominant central deposition and hot spots may severely hamper interpretation of ventilation scintigraphy. Using the best available nebulizers this problem occurs in rather few patients.

The most commonly used radiolabelled liquid aerosol is ^{99m}Tc-DTPA. ^{99m}Tc-DTPA is cleared from the alveolar region by transepithelial diffusion [52]. The biological half-life varies from 80±20 min in healthy nonsmokers to 45±8 min in healthy passive smokers and 24±9 min in healthy smokers [53]. Resorbed ^{99m}Tc-DTPA is excreted via glomerular filtration in the kidneys.

The pulmonary clearance rate of ^{99m}Tc-DTPA is an index of the alveolar epithelial membrane integrity [53, 54]. Increased clearance, leads to a shorter half-life and occurs with alveolar inflammatory activity of any kind such as alveolitis of an allergic or toxic nature. For diagnostic use, the clearance of ^{99m}Tc-DTPA can be evaluated using planar

or tomographic scintigraphy [55, 56]. Continuous recording over 20–45 min allows more detailed analysis for evaluation of biphasic clearance in disease [57–59].

Technegas is an aerosol comprising extremely small ^{99m}Tc-labelled solid graphite particles generated at high temperature [60, 61]. Technegas particles have a diameter of about 0.005–0.2 µm [62] and are hydrophobic but tend to grow by aggregation, and should therefore be used within 10 min of generation. The graphite particles are slowly cleared from the alveolar region by resorption. The biological half-life is 135 h [63]. Ventilation studies with ^{99m}Tc-Technegas and with ^{81m}Kr give comparable information [64–68]. However, hot spots are rarely seen with ^{99m}Tc-Technegas in patients with airway obstruction [66, 69]. Using ^{99m}Tc-Technegas has minimized the problem of hotspots in patients with obstructive lung disease and is according to clinical experience better than the best liquid aerosols.

Perfusion scintigraphy

^{99m}Tc-MAA

Perfusion scintigraphy is accomplished by microembolization with radiolabelled particles injected into a peripheral vein. The commercially used particles are MAA which are labelled with ^{99m}Tc. They are 15–100 µm in size and lodge in the pulmonary capillaries and in the precapillary arterioles. The particle distribution accurately defines regional lung perfusion. When performing the study, an important factor is the number of particles injected. A minimum of 60,000 particles is required to obtain uniform distribution of activity reflecting regional perfusion [70]. Normally, about 400,000 labelled particles are injected. Bearing in mind that there are over 280 billion pulmonary capillaries and 300 million precapillary arterioles, the administration of up to 400,000 particles will result in obstruction of only a very small fraction of pulmonary vessels. A reduction in the number of particles administered to between 100,000 and 200,000 is recommended in patients with known pulmonary hypertension, right to left heart shunt or after a single lung transplantation. In infants and children the number of particles may be further reduced in accordance with weight [38].

Quality control and injection practice

Radiochemical purity should be determined as it may vary widely. As particles tend to settle on standing, the vial should be shaken gently before use. Withdrawal of blood into the syringe should be avoided as this will cause aggregation of MAA particles that may result in perfusion artefacts. The suspension containing ^{99m}Tc-MAA should be given by slow intravenous bolus injection over 30 s while the patient breathes at normal tidal volumes. This will ensure that the particles are infused over several respiratory cycles facilitating uniform distribution within the pulmonary circulation.

Radiation activity and radiation exposure

A key objective of imaging in PE is to minimize radiation exposure without sacrificing image quality and diagnostic accuracy. The amounts of radiation involved must be considered together with imaging protocols. Table 1 gives basic data of relevance.

The biological half-life of ^{99m}Tc-DTPA is 55–108 min [51] and of ^{99m}Tc-Technegas is 135 h [63].

Pregnancy

Pregnancy, particularly during the first trimester, poses unique circumstances in relation to radiation hazards [75]. In pregnant women, the interpretation of lung perfusion scintigraphy is usually straightforward because of the low frequency of comorbid pulmonary disorders [76]. Therefore, to minimize radiation, a 1- to 2-day protocol is suggested. Perfusion-only scans should be performed on day 1, using a reduced dose of ^{99m}Tc-MAA. In most patients PE can be excluded on the basis of a normal perfusion pattern. When the perfusion pattern is abnormal but not diagnostic of PE, subcutaneous low molecular

Table 1 Data on radiation exposure in adults

Reference	Radiopharmaceutical	Administered activity (MBq)	Critical organ, dose (mGy/MBq)	Effective dose (mSv/MBq)
[71]	^{99m}Tc-MAA	40–120	Lungs, 0.067	0.017
[72]	^{99m}Tc-DTPA	20–30	Bladder, 0.047	0.007
[73]	Technegas	20–30	Lungs, 0.11	0.015
[74]	^{81m}Kr	40–400	Lungs, 0.0068	0.0007

heparin can be given until a ventilation study is performed on day 2, using an activity deposited in the lung of 20–30 MBq. After the first trimester the standard 1-day protocol or the 1- to 2-day protocol can be used.

Imaging protocols

V/P_{PLANAR} compared to V/P_{SPECT}

V/P_{SCAN} may be carried out using V/P_{PLANAR} or V/P_{SPECT}. There are compelling reasons for the introduction of V/P_{SPECT}. An occlusive clot in a segmental artery causes on average a perfusion defect large enough to be detected on the basis of six to eight planar images, despite the low resolution of V/P_{PLANAR} and motion artefacts [77]. However, difficulties arise, mainly in medial segments which are located adjacent to the mediastinum and are poorly visualized on the outer contour of the lung. Detection of ventilation and perfusion defects at the subsegmental level is possible by planar imaging, but is considerably better by SPECT (Fig. 3). In a pig model with artificial subsegmental emboli, the sensitivity of V/P_{PLANAR} was 67% and of V/P_{SPECT} was 93% [78]. In clinical studies, Bajc et al. identified 53% more mismatched regions with SPECT [79]. In a study by Collart et al., V/P_{SPECT} increased the specificity for PE from 78% to 96% at similar sensitivities [80]. Reinartz et al. found a sensitivity and specificity of 0.76 and 0.85, respectively, with V/P_{PLANAR} compared to 0.97 and 0.91 with V/P_{SPECT} [81].

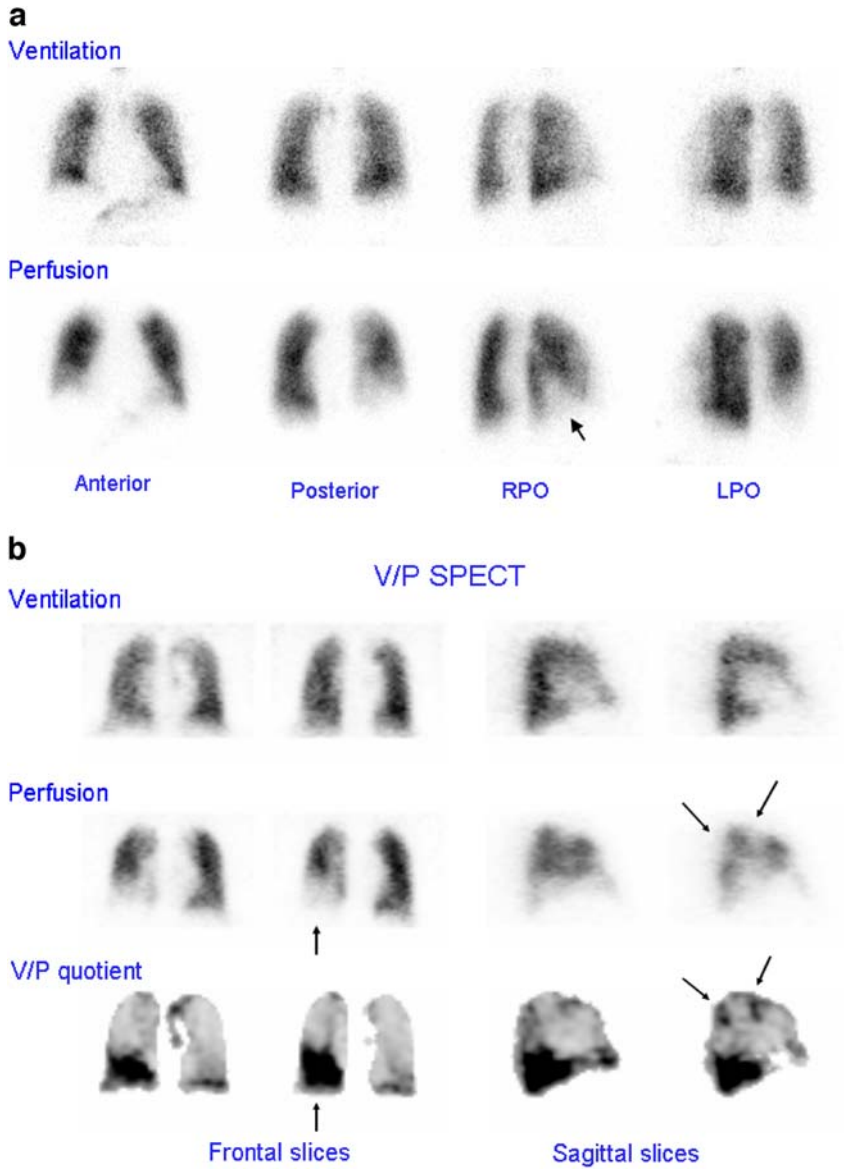

Fig. 3 Planar (**a**) and SPECT (**b**) studies in the same patient

V/P_{SCAN}: the value of ventilation scintigraphy

V/P_{SCAN} should be performed using a 1-day protocol for the following reasons. PE is an acute and life-threatening disease that should be diagnosed and treated without delay. To save time and resources, protocols for both V/P_{PLANAR} and V/P_{SPECT} with very low isotope doses have been designed to allow a complete study from referral to report within 1 h [56, 79, 82]. The gamma camera and the staff are then only engaged on one occasion and then for a short time, which not infrequently is a logistical prerequisite for a 1-day protocol. Furthermore, after a ventilation scan with very low activity, moderate activity yields optimal perfusion image quality, which is a central issue. With the recommended protocol, the total radiation dose is lower than in many current protocols.

Outpatient therapy for PE has been shown to be safe [83–85]. The advantages include among others saving in cost. Full safe outpatient treatment calls for immediate diagnosis that depends on a 1-day V/P protocol. A further value of ventilation scintigraphy is that it allows a delineation of the lung that is independent of the perfusion pattern. Perfusion defects, particularly in the middle lobe and the lingula, may be overlooked in the absence of ventilation images [86].

Interpretation of V/P_{SPECT} is facilitated by V/P quotient images, the acquisition of which requires that the ventilation study is immediately followed by the perfusion study [55, 79]. In the presence of perfusion perturbations, ventilation scintigraphy is a prerequisite for the diagnosis of PE particularly when combined with other lung diseases as well as to provide an explanation of the patient's symptoms.

V/P_{PLANAR} acquisition

If V/P_{SPECT} is not feasible, planar imaging is performed with at least four views (anterior, posterior, left and right posterior oblique). Preferably six to eight projections are used. The recommended matrix size is 256×256, used with a high-resolution, low-energy collimator; 500–1,000 kcounts per view is recommended. For further details see Tagil et al. [56].

Perfusion-only scintigraphy

Perfusion defects are caused by a variety of lung diseases and are considered nonspecific. The sensitivity and specificity of the perfusion scan alone in the diagnosis or exclusion of PE was reappraised by Miniati et al. in the PISA-PED study [87]. In that study, 890 patients with suspected PE were evaluated. Pulmonary angiography (selective or superselective) was in most cases used as reference. Perfusion scans were independently attributed to one of four predetermined categories: (1) normal (no perfusion defects); (2) near-normal (impressions caused by enlarged heart, hila, or mediastinum seen in an otherwise normal scan); (3) abnormal, suggestive of pulmonary embolism (single or multiple wedge-shaped perfusion defects); and (4) abnormal, not suggestive of pulmonary embolism (single or multiple perfusion defects other than wedge-shaped). The perfusion scan yielded a sensitivity of 86%, and a specificity of 93% in relation to angiography. Recently, the PISA-PED criteria were used to rate 889 perfusion scans from the PIOPED II trial. Lung scans were examined by two independent readers. The weighted sensitivity of the perfusion scan was 82%, and the weighted specificity 96% [88].

Perfusion-only scintigraphy is recommended during pregnancy and in patients with suspected massive PE.

V/P_{SPECT} acquisition

In order to minimize vertical ventilation and perfusion gradients, inhalation of aerosols and intravenous injections of MAA should be performed in the supine position. During inhalation, activity over the lungs should be monitored to ensure adequacy of pulmonary deposition.

For V/P_{SPECT}, a large field-of-view dual or triple head gamma camera is needed to limit acquisition time and the risk of patient movement. In a systematic study, Palmer et al. tested the relationships between activities, acquisition times, collimators and matrices for optimal SPECT imaging [55]. A 1 to 4 activity ratio between ventilation and perfusion was found to be optimal. An ideal combination was 25–30 MBq for ventilation studies and 100–120 MBq for perfusion studies. Images should be acquired using a 64×64 matrix and a general purpose collimator and a total acquisition time of 20 min. In clinical practice this strategy has proved to be feasible and adequate in several recent studies [79, 89–92].

Many centres are using much higher doses. To reduce radiation exposure to the lowest level possible with maintained diagnostic safety is, on the basis of ethical concerns and good medical practice, a crucial issue. Therefore, the activities and acquisition protocol of Palmer et al. are recommended [55].

The total number of projections is 128 (64 with each camera head). For ventilation SPECT study each projection takes 10 s. The perfusion study is undertaken immediately after the ventilation SPECT acquisition without patient movement, each projection lasting 5 s. During the examination the patient remains in the supine position, carefully maintained between ventilation and perfusion acquisitions. The total immobilization time of 20 min is well tolerated even by critically ill patients. The procedure is practical for the staff.

V/P_{SPECT} reconstruction and display

Iterative reconstruction using OSEM (ordered-subset expectation maximization) with, for example, eight subsets and two iterations is recommended [55, 79, 93]. Standard software can be used for this as well as for image presentation in the frontal, sagittal and transverse projections as well as for presentation of rotating 3-D images.

A further option is to calculate and display V/P quotient images. Based upon acquisition in which the patient is examined without movement between ventilation and perfusion imaging, ventilation background may be subtracted from perfusion tomograms [55, 79]. After normalization of the ventilation to perfusion count rates, a ventilation/perfusion quotient is calculated ($V/P_{quotient}$). The $V/P_{quotient}$ images facilitate diagnosis and quantification of PE extension, particularly in complex cases. Notably, as attenuation is similar for ventilation and perfusion studies, $V/P_{quotient}$ images make attenuation correction less important.

Interpretation of V/P_{SCAN}

Diagnosis of acute PE

Probabilistic interpretation based upon simplistic criteria were promoted through the PIOPED I study [34]. The terms used were high, intermediate, low and very low probability V/P_{SCAN}, and indeterminate (nondiagnostic) examinations. Such or similar terminology is extremely rare in other clinical contexts. This language has not gained acceptance in other fields. The most likely reason is that in clinical practice this strategy is inherently impracticable. According to Bayes' theorem, probability cannot be defined from a single test without taking into account prior probability. Furthermore, the PIOPED I criteria were formulated and applied on the basis of techniques that are today obsolete. For example, regional ventilation was mapped from a posterior planar acquisition following the inhalation of ^{133}Xe. Additionally, an abnormal chest radiograph or ventilation scintigram implied that the scintigraphy was categorized as nondiagnostic, which is unwarranted as shown by more recent studies [82, 90, 93]. In the PIOPED study, direct comparison of conventional PA and planar ventilation scintigraphy, using ^{133}Xe for ventilation, yielded poor results with agreement as low as 50% [34]. Therefore the PIOPED criteria were fundamentally flawed.

Interpretation of imaging tests such as V/P_{SPECT} and V/P_{PLANAR} should be based upon:

- Basic criteria for reading the images
- Knowledge and experience of the interpreter according to the principle of "gestalt" [94, 95]
- Pretest probability in accordance with the principle of Holistic interpretation

Furthermore, to be clinically useful, interpretation of an imaging test should be affirmative or negative with respect to PE (PE: yes or no) and should not be based on probability categories [77].

The recommended basic criteria for reading V/P_{SPECT} and V/P_{PLANAR} are the following:

No PE is reported if there is (are):

- Normal perfusion pattern conforming to the anatomic boundaries of the lungs
- Matched or reversed mismatch V/P defects of any size, shape or number in the absence of mismatch
- Mismatch that does not have a lobar, segmental or subsegmental pattern

PE is reported if there is:

- V/P mismatch of at least one segment or two subsegments that conforms to the pulmonary vascular anatomy

Nondiagnostic for PE is reported if there are:

- Multiple V/P abnormalities not typical of specific diseases.

The fundamental assumption behind these criteria is the fact that in those patients with a clinical suspicion of PE, PE is the principal cause of lobar, segmental or subsegmental V/P mismatch. Howarth et al. stated that for diagnosis of PE "more than 0.5 segment of ventilation/perfusion mismatch is sufficient" [96]. Crucially, the shape of a mismatch should be pleural based and should conform to known subsegmental and segmental vascular anatomy as stressed in the PISA-PED study [87]. Applying these principles of interpretation, recent V/P_{SPECT} studies amounting to over 3,000 cases have shown negative predictive values of 97–99%, sensitivities of 96–99%, and specificities of 91–98% for PE diagnosis. Rates of nondiagnostic findings were 1–3% [81, 82, 90, 93]. The experience of the interpreter is involved in the process that carries the name gestalt [94, 95]. Another term frequently used is holistic interpretation, which implies that clinical information and laboratory tests are taken into account together with all observed signs and patterns in ventilation and perfusion scintigrams. Schemes for clinical probabilities may be of significant value [97–99]. This is further underlined in Part 2 of these guidelines [100].

Chronic PE

Chronic PE is a distinct entity. Its clinical presentation is often insidious. It is progressive and without treatment has a poor prognosis [101, 102]. Mortality is related to pulmonary

hypertension, right heart failure and arrhythmia. V/P_{SCAN} is conventionally a mainstay in the diagnosis of chronic thromboembolic pulmonary hypertension [103–105]. Recently, a group from Hammersmith Hospital reported a head to head comparison between MDCT and V/P_{PLANAR} in patients with pulmonary hypertension. MDCT had a sensitivity of 51% while the sensitivity of V/P_{PLANAR} was 96–97% at a specificity of 90%, confirming previous data [106]. The authors concluded that "ventilation/perfusion scintigraphy, which is widely available and easy to perform, has a higher sensitivity than MDCT as well as very good specificity in detecting chronic pulmonary thromboembolic disease as a potential curable cause of PH". Figure 4 illustrates typical V/P_{SPECT} findings in patients with pulmonary hypertension caused by chronic PE, not recognized by MDCT.

Additional diagnostic outcomes

In addition to the diagnosis of PE, V/P_{SCAN} may provide evidence of other pathologies, such as COPD, left heart failure and pneumonia. The frequency of additional findings using V/P_{SPECT} has been reported to be 39% among patients without PE, and 22% among patients with PE [90]. COPD is characterized on V/P_{SCAN} by matched ventilation and perfusion defects. Frequently, ventilation defects are more pronounced than perfusion defects. This is known as reverse mismatch [107, 108]. A significant correlation between the degree of abnormalities on aerosol ventilation imaging and pulmonary function tests has been reported [109]. PE is quite frequent in COPD [110, 111] and accounts for up to 10% of deaths in patients with stable COPD [112]. PE can be diagnosed using V/P_{SPECT} in patients with coexisting COPD (Fig. 5).

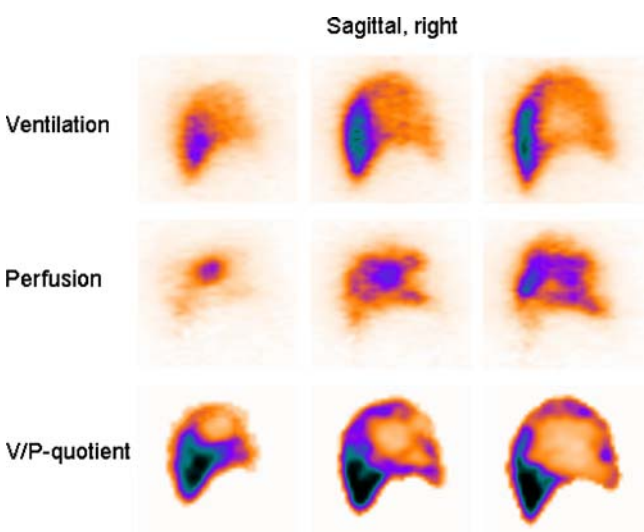

Fig. 4 Sagittal slices of the right lung in a patient with pulmonary hypertension. Multiple perfusion defects are seen in ventilated areas, highlighted in the V/P quotient images. MDCT was normal in this patient

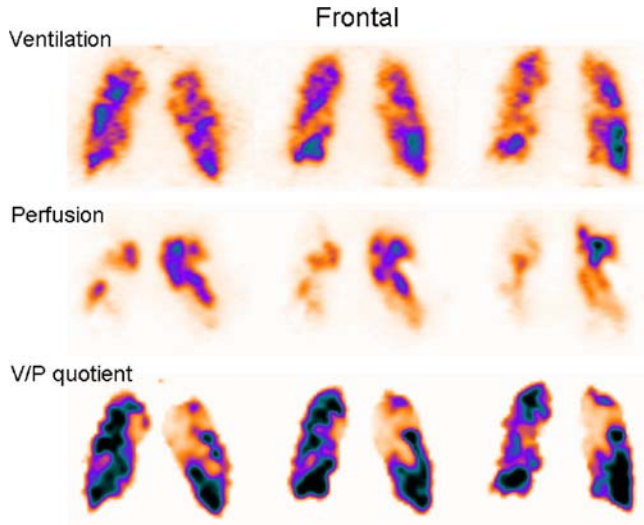

Fig. 5 Frontal slices in a patient with COPD and PE. Ventilation is very uneven in the whole lung. In addition, multiple perfusion defects are seen in ventilated areas. Mismatch is highlighted in $V/P_{quotient}$ images

In left heart failure, perfusion is redistributed towards upper lung regions (Fig. 6) [92, 113, 114]. In a recent study based on V/P_{SPECT} in consecutive patients with suspected PE, ^{99m}Tc-MAA was injected with the patient in the supine position. Redistribution of perfusion towards ventral lung regions was observed in 15% of the patients, indicating left heart failure [92]. The positive predictive value for heart failure was 88% or higher. In heart failure, ventilation is usually redistributed to a lesser extent than perfusion, V/P mismatch may be observed in dorsal regions. This V/P mismatch has a nonsegmental diffuse pattern and should not be misinterpreted as PE.

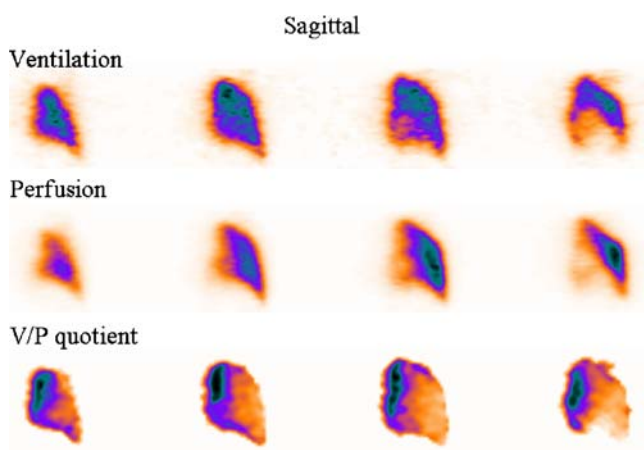

Fig. 6 Sagittal slices from the right lung. Antigravitational redistribution of perfusion is pronounced. Ventilation is less affected causing mismatch. Note that the pattern is not of a segmental character

Pneumonia is characterized by a matched ventilation/perfusion pattern [115]. Ventilation defects usually exceed perfusion defects, causing reverse mismatch [115, 116]. A valuable sign of pneumonia is the 'stripe sign' that refers to maintained perfusion along the pleural surface, peripheral to a central matched defect (Fig. 7) [29, 30]. V/P_{SPECT} facilitates the identification of the stripe sign [89, 117].

Pitfalls in the interpretation of V/P_{SCAN}

As with any diagnostic test, it is vital that the clinician reporting the lung scan is aware of a number of sources of error. These include the following:

- Technical artefacts may arise from preinjection handling of the ^{99m}Tc-MAA. Drawing blood into the syringe containing the solution of ^{99m}Tc -MAA may cause aggregation of particles, creating hot spots in the images. A similar result may arise from failure to resuspend ^{99m}Tc-MAA particles prior to administration.
- Planar imaging may underestimate the presence or extent of perfusion abnormalities due to superposition of lung regions with normal perfusion. This is reflected as shine-through masking of embolized regions. This problem is eliminated by V/P_{SPECT} (Fig. 3).
- Technegas is preferred over liquid aerosols in patients with COPD. In rare patients with emphysema, Technegas particles are trapped in bullae causing a pattern that may be mistaken for a mismatch [81].
- Mismatched perfusion defects, which do not have a clear segmental character, may be seen in older, partly resolved PE, but are not the result of acute PE. Moreover, nonsegmental mismatched defects are observed in a number of lung disorders including lung cancer, mediastinal lymphadenopathy, postradiation pneumonitis/fibrosis and heart failure. V/P_{SPECT} facilitates the identification of segmental perfusion defects, which are particularly well visualized using rotating 3-D volume images.
- It has been argued that V/P_{SCAN} may fail to detect PE when the thromboembolism causes only partial vascular occlusion with few haemodynamic effects [118]. However, it is generally accepted that a negative V/P_{SPECT} scan excludes PE. Accordingly, this potential problem has low clinical significance. An explanation for this may be that nonocclusive emboli are paralleled by occlusive PE in other regions leading to diagnosis. On the other hand, if a partly occluding embolus is recognized (segmental perfusion clearly reduced but not absent while ventilation is normal), the finding should be reported as PE.
- Unilateral absence of perfusion in a whole lung with preserved ventilation and without any V/P mismatch in the other lung is generally not due to PE [94, 119]. In such cases, a CT scan of the thorax may reveal the presence of other pathologies such as tumour and other mediastinal processes, congenital pulmonary vascular abnormalities or aortic aneurysm.

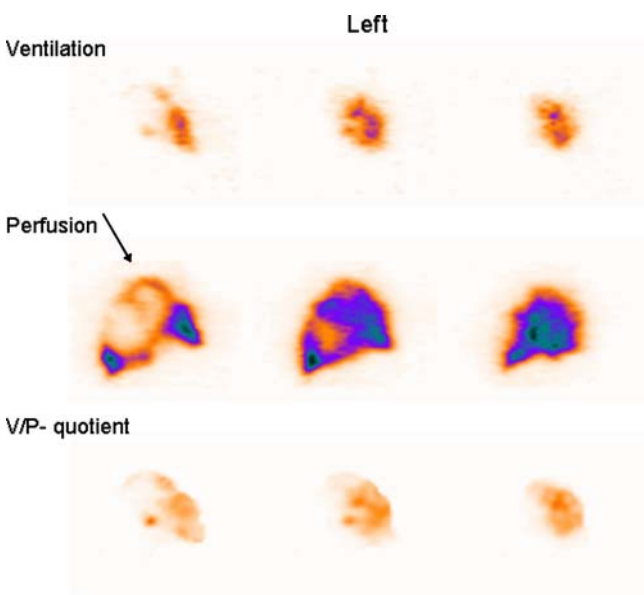

Fig. 7 Sagittal slices of the left lung in a patient with extensive pneumonia in whom the chest radiograph was interpreted as atelectasis. The left lung shows nearly absent ventilation in areas with much better perfusion (*arrow* stripe sign). V/P quotient highlights reversed mismatch

Conclusion

V/P_{SPECT} is strongly recommended as it allows the diagnosis of PE to be made with accuracy even in the presence of diseases such as COPD and pneumonia. Technegas is preferred over DTPA in patients with COPD. When available, ^{81m}Kr is advantageous. The radiation dose should be reduced as much as possible without clinically significant image deterioration. This implies 30 MBq of ^{99m}Tc-aerosol for the ventilation scan preceding 100–120 mBq for the perfusion scan both for V/P_{PLANAR} and V/P_{SPECT}. In pregnancy only a perfusion scan is recommended. Probabilistic interpretation is obsolete and should be replaced by holistic interpretation. A fundamental criterion for PE is mismatch in more than one subsegment.

Acknowledgments We would like to thank the EANM Dosimetry Committee for their contribution, and Medan Rehani, chair of the Task Group on Radiation Protection, IAEA, for sharing his knowledge and for fruitful discussions.

Conflicts of interest None.

References

1. Barritt DW, Jordan SC. Anticoagulant drugs in the treatment of pulmonary embolism. A controlled trial. Lancet 1960;1:1309–12. doi:10.1016/S0140-6736(60)92299-6.
2. Coulden R. State-of-the-art imaging techniques in chronic thromboembolic pulmonary hypertension. Proc Am Thorac Soc 2006;3:577–83. doi:10.1513/pats.200605-119LR.
3. White RH. The epidemiology of venous thromboembolism. Circulation 2003;107:I4–8. doi:10.1161/01.CIR.0000078468.11849.66.
4. Heit JA. The epidemiology of venous thromboembolism in the community: implications for prevention and management. J Thromb Thrombolysis 2006;21:23–9. doi:10.1007/s11239-006-5572-y.
5. Nordstrom M, Lindblad B. Autopsy-verified venous thromboembolism within a defined urban population – the city of Malmo, Sweden. APMIS 1998;106:378–84.
6. Tapson VF. Acute pulmonary embolism. N Engl J Med 2008;358:1037–52. doi:10.1056/NEJMra072753.
7. Lehmann R, Suess C, Leus M, Luxembourg B, Miesbach W, Lindhoff-Last E, et al. Incidence, clinical characteristics, and long-term prognosis of travel-associated pulmonary embolism. Eur Heart J 2009;30:233–41.
8. Kakkar VV, Howe CT, Flanc C, Clarke MB. Natural history of postoperative deep-vein thrombosis. Lancet 1969;2:230–2. doi:10.1016/S0140-6736(69)90002-6.
9. Moser KM, Fedullo PF, LitteJohn JK, Crawford R. Frequent asymptomatic pulmonary embolism in patients with deep venous thrombosis. JAMA 1994;271:223–5. doi:10.1001/jama.271.3.223.
10. Goldhaber SZ, Visani L, De Rosa M. Acute pulmonary embolism: clinical outcomes in the International Cooperative Pulmonary Embolism Registry (ICOPER). Lancet 1999;353:1386–9. doi:10.1016/S0140-6736(98)07534-5.
11. Nijkeuter M, Hovens MM, Davidson BL, Huisman MV. Resolution of thromboemboli in patients with acute pulmonary embolism: a systematic review. Chest 2006;129:192–7. doi:10.1378/chest.129.1.192.
12. James W, Menn S. Rapid resolution of pulmonary embolism in man. Wis Med J 1978;128:60–4.
13. Fredin H, Arborelius M Jr. Scintigraphic evaluation of pulmonary embolism after total hip replacement, using a dry 99mTc-microaerosol for regional ventilation. Eur J Nucl Med 1982;7:494–9. doi:10.1007/BF00257214.
14. Coakley AJ. Timing of VQ ventilation perfusion scanning. Eur J Nucl Med 1995;22:1099–100.
15. Goldhaber SZ, Elliott CG. Acute pulmonary embolism: part I: epidemiology, pathophysiology, and diagnosis. Circulation 2003;108:2726–9. doi:10.1161/01.CIR.0000097829.89204.0C.
16. Lee CH, Hankey GJ, Ho WK, Eikelboom JW. Venous thromboembolism: diagnosis and management of pulmonary embolism. Med J Aust 2005;182:569–74.
17. Eriksson L, Wollmer P, Olsson CG, Albrechtsson U, Larusdottir H, Nilsson R, et al. Diagnosis of pulmonary embolism based upon alveolar dead space analysis. Chest 1989;96:357–62. doi:10.1378/chest.96.2.357.
18. Torbicki A, Perrier A, Konstantinides S, Agnelli G, Galie N, Pruszczyk P, et al. Guidelines on the diagnosis and management of acute pulmonary embolism: the Task Force for the Diagnosis and Management of Acute Pulmonary Embolism of the European Society of Cardiology (ESC). Eur Heart J 2008;29:2276–315.
19. Meacham RR 3rd, Headley AS, Bronze MS, Lewis JB, Rester MM. Impending paradoxical embolism. Arch Intern Med 1998;158:438–48. doi:10.1001/archinte.158.5.438.
20. Miniati M, Prediletto R, Formichi B, Marini C, Di Ricco G, Tonelli L, et al. Accuracy of clinical assessment in the diagnosis of pulmonary embolism. Am J Respir Crit Care Med 1999;159:864–71.
21. Baile EM, King GG, Muller NL, D'Yachkova Y, Coche EE, Pare PD, et al. Spiral computed tomography is comparable to angiography for the diagnosis of pulmonary embolism. Am J Respir Crit Care Med 2000;161:1010–5.
22. Schoepf UJ, Costello P. CT angiography for diagnosis of pulmonary embolism: state of the art. Radiology 2004;230:329–37. doi:10.1148/radiol.2302021489.
23. Stein PD, Henry JW, Gottschalk A. Reassessment of pulmonary angiography for the diagnosis of pulmonary embolism: relation of interpreter agreement to the order of the involved pulmonary arterial branch. Radiology 1999;210:689–91.
24. Hull RD, Raskob GE, Coates G, Panju AA. Clinical validity of a normal perfusion lung scan in patients with suspected pulmonary embolism. Chest 1990;97:23–6. doi:10.1378/chest.97.1.23.
25. Moser KM, Guisan M, Cuomo A, Ashburn WL. Differentiation of pulmonary vascular from parenchymal diseases by ventilation-perfusion scintiphotography. Ann Intern Med 1971;75:597–605.
26. van Beek EJ, Kuyer PM, Schenk BE, Brandjes DP, ten Cate JW, Buller HR. A normal perfusion lung scan in patients with clinically suspected pulmonary embolism. Frequency and clinical validity. Chest 1995;108:170–3. doi:10.1378/chest.108.1.170.
27. Li DK, Seltzer SE, McNeil BJ. V/Q mismatches unassociated with pulmonary embolism: case report and review of the literature. J Nucl Med 1978;19:1331–3.
28. Palevsky HI, Alavi A. A noninvasive strategy for the management of patients suspected of pulmonary embolism. Semin Nucl Med 1991;21:325–31. doi:10.1016/S0001-2998(05)80135-7.
29. Sostman HD, Gottschalk A. Prospective validation of the stripe sign in ventilation-perfusion scintigraphy. Radiology 1992;184: 455–9.
30. Sostman HD, Ravin CE, Sullivan DC, Mills SR, Glickman MG, Dorfman GS. Use of pulmonary angiography for suspected pulmonary embolism: influence of scintigraphic diagnosis. AJR Am J Roentgenol 1982;139:673–7.
31. Creutzig H, Gonda S, Creutzig A, Reilmann H, Hundeshagen H. Frequencies of segmental perfusion and ventilation abnormalities in lung scintigraphy. Eur J Nucl Med 1983;8:401–3.
32. Dollery CT, Gillam PM. The distribution of blood and gas within the lungs measured by scanning after administration of 133Xe. Thorax 1963;18:316–25. doi:10.1136/thx.18.4.316.
33. Knipping HW, Bolt W, Venrath H, Valentin H, Ludes H, Endler P. A new method of heart and lung function testing, the regional functional analysis in the lung and heart clinic by the radioactive noble gas xenon 133 (isotope thoracography). Dtsch Med Wochenschr 1955;80:1146–7.
34. The PIOPED Investigators. Value of the ventilation/perfusion scan in acute pulmonary embolism. Results of the prospective investigation of pulmonary embolism diagnosis (PIOPED). JAMA 1990;263:2753–9. doi:10.1001/jama.263.
35. Schümichen C, Krause T, Reinartz P. Leitlinie für die Lungenszintigraphie (Version 2). In: Eckardt J, Geworski L, Lerch H, Reiners C, Schober O: Empfehlungen zur Qualitätskontrolle in der Nuklearmedizin. Schattauer Stuttgart, 2009, 71–82.
36. Fazio F, Jones T. Assessment of regional ventilation by continuous inhalation of radioactive krypton-81m. BMJ 1975;3:673–6. doi:10.1136/bmj.3.5985.673.
37. Valind SO, Rhodes CG, Jonson B. Quantification of regional ventilation in humans using a short-lived radiotracer – theoretical evaluation of the steady-state model. J Nucl Med 1987;28:1144–54.
38. Ciofetta G, Piepsz A, Roca I, Fisher S, Hahn K, Sixt R, et al. Guidelines for lung scintigraphy in children. Eur J Nucl Med Mol Imaging 2007;34:1518–26. doi:10.1007/s00259-007-0485-3.
39. Gutte H, Mortensen J, Jensen C, Johnbeck C, von der Recke P, Petersen C, et al. Detection of pulmonary embolism with

combined ventilation/perfusion SPECT and low dose CT: head-to-head comparison with CT-angiography. J Nucl Med 2009; in press
40. Itti E, Nguyen S, Robin F, Desarnaud S, Rosso J, Harf A, et al. Distribution of ventilation/perfusion ratios in pulmonary embolism: an adjunct to the interpretation of ventilation/perfusion lung scans. J Nucl Med 2002;43:1596–602.
41. Ohno Y, Koyama H, Takenaka D, Nogami M, Kotani Y, Nishimura Y, et al. Coregistered ventilation and perfusion SPECT using krypton-81m and Tc-99m-labeled macroaggregated albumin with multislice CT utility for prediction of postoperative lung function in non-small cell lung cancer patients. Acad Radiol 2007;14:830–8. doi:10.1016/j.acra.2007.03.013.
42. Sando Y, Inoue T, Nagai R, Endo K. Ventilation/perfusion ratios and simultaneous dual-radionuclide single-photon emission tomography with krypton-81m and technetium-99m macroaggregated albumin. Eur J Nucl Med 1997;24:1237–44. doi:10.1007/s002590050147.
43. Oberdorster G. Pulmonary effects of inhaled ultrafine particles. Int Arch Occup Environ Health 2001;74:1–8. doi:10.1007/s004200000185.
44. Jaques PA, Kim CS. Measurement of total lung deposition of inhaled ultrafine particles in healthy men and women. Inhal Toxicol 2000;12:715–31. doi:10.1080/08958370050085156.
45. O'Callaghan C, Barry PW. The science of nebulised drug delivery. Thorax 1997;52(Suppl 2):S31–44.
46. Dolovich MA. Influence of inspiratory flow rate, particle size, and airway caliber on aerosolized drug delivery to the lung. Respir Care 2000;45:597–608.
47. Bennett WD, Mitzner W. Use of aerosols to measure in vivo volume-dependent changes in lung air space dimensions. J Appl Physiol 1985;59:875–83.
48. Agnew JE, Francis RA, Pavia D, Clarke SW. Quantitative comparison of 99Tcm-aerosol and 81Krm ventilation images. Clin Phys Physiol Meas 1982;3:21–30. doi:10.1088/0143-0815/3/1/002.
49. Isawa T, Lee BT, Hiraga K. High-resolution electron microscopy of technegas and pertechnegas. Nucl Med Commun 1996;17:147–52.
50. Senden TJ, Moock KH, Gerald JF, Burch WM, Browitt RJ, Ling CD, et al. The physical and chemical nature of technegas. J Nucl Med 1997;38:1327–33.
51. Strong JC, Agnew JE. The particle size distribution of technegas and its influence on regional lung deposition. Nucl Med Commun 1989;10:425–30. doi:10.1097/00006231-198906000-00008.
52. Bondesson E, Bengtsson T, Nilsson LE, Wollmer P. Site of deposition and absorption of an inhaled hydrophilic solute. Br J Clin Pharmacol 2007;63:722–31. doi:10.1111/j.1365-2125.2006.02835.x.
53. Beadsmoore C, Cheow HK, Szczepura K, Ruparelia P, Peters AM. Healthy passive cigarette smokers have increased pulmonary alveolar permeability. Nucl Med Commun 2007;28:75–7. doi:10.1097/MNM.0b013e328013eb1e.
54. Rinderknecht J, Shapiro L, Krauthammer M, Taplin G, Wasserman K, Uszler JM, et al. Accelerated clearance of small solutes from the lungs in interstitial lung disease. Am Rev Respir Dis 1980;121:105–17.
55. Palmer J, Bitzen U, Jonson B, Bajc M. Comprehensive ventilation/perfusion SPECT. J Nucl Med 2001;42:1288–94.
56. Tagil K, Evander E, Wollmer P, Palmer J, Jonson B. Efficient lung scintigraphy. Clin Physiol 2000;20:95–100. doi:10.1046/j.1365-2281.2000.00232.x.
57. Evander E, Wollmer P, Valind S, Sornmo L, John J, Jonson B. Biexponential pulmonary clearance of 99mTc-DTPA induced by detergent aerosol. J Appl Physiol 1994;77:190–6.
58. Kotzerke J, van den Hoff J, Burchert W, Wagner TF, Emter M, Hundeshagen H. A compartmental model for alveolar clearance of pertechnegas. J Nucl Med 1996;37:2066–71.
59. Van der Wall H, Murray IP, Jones PD, Mackey DW, Walker BM, Monaghan P. Optimising technetium 99m diethylene triamine penta-acetate lung clearance in patients with the acquired immunodeficiency syndrome. Eur J Nucl Med 1991;18:235–40.
60. Burch WM, Sullivan PJ, Lomas FE, Evans VA, McLaren CJ, Arnot RN. Lung ventilation studies with technetium-99m Pseudogas. J Nucl Med 1986;27:842–6.
61. Burch WM, Tetley IJ, Gras JL. Technetium-99m 'pseudogas' for diagnostic studies in the lung. Clin Phys Physiol Meas 1984;5:79–85. doi:10.1088/0143-0815/5/2/003.
62. Lemb M, Oei TH, Eifert H, Gunther B. Technegas: a study of particle structure, size and distribution. Eur J Nucl Med 1993;20:576–9. doi:10.1007/BF00176550.
63. Kawakami K, Iwamura A, Goto E, Mori Y, Abe T, Hirasawa Y, et al. Kinetics and clinical application of 99mTc-technegas. Kaku Igaku 1990;27:725–33.
64. Cook G, Clarke SE. An evaluation of Technegas as a ventilation agent compared with krypton-81m in the scintigraphic diagnosis of pulmonary embolism. Eur J Nucl Med 1992;19:770–4. doi:10.1007/BF00182818.
65. Hartmann IJ, Hagen PJ, Stokkel MP, Hoekstra OS, Prins MH. Technegas versus (81m) Kr ventilation-perfusion scintigraphy: a comparative study in patients with suspected acute pulmonary embolism. J Nucl Med 2001;42:393–400.
66. James JM, Lloyd JJ, Leahy BC, Church S, Hardy CC, Shields RA, et al. 99Tcm-Technegas and krypton-81m ventilation scintigraphy: a comparison in known respiratory disease. Br J Radiol 1992;65:1075–82.
67. Magnant J, Vecellio L, de Monte M, Grimbert D, Valat C, Boissinot E, et al. Comparative analysis of different scintigraphic approaches to assess pulmonary ventilation. J Aerosol Med 2006;19:148–59. doi:10.1089/jam.2006.19.148.
68. Peltier P, De Faucal P, Chetanneau A, Chatal JF. Comparison of technetium-99m aerosol and krypton-81m in ventilation studies for the diagnosis of pulmonary embolism. Nucl Med Commun 1990;11:631–8. doi:10.1097/00006231-199009000-00006.
69. Inoue T, Watanabe N, Oriuchi N, Tateno M, Tomiyoshi K, Mitomo O, et al. Clinical evaluation of lung scintigraphy with 99mTc-technegas. Nippon Igaku Hoshasen Gakkai Zasshi 1990;50:1590–600.
70. Heck LL, Duley JW Jr. Statistical considerations in lung imaging with 99mTc albumin particles. Radiology 1974;113:675–9.
71. ICRP. Radiation dose to patients from radiopharmaceuticals (addendum 2 to ICRP 53). Ann ICRP 1998;28:1–126.
72. ICRP. Radiation dose to patients from radiopharmaceuticals, publication 53. Oxford, New York: ICRP; 1988. p. 121.
73. Stabin MG, Gelfand MJ. Dosimetry of pediatric nuclear medicine procedures. Q J Nucl Med 1998;42:93–112.
74. Camps JA, Zuur C, Blokland JA, Broerse JJ, Pauwels EK. A breathing lung phantom for 81mKr lung ventilation studies its use in dosimetry and quality control. Eur J Nucl Med 1988;14:529–32. doi:10.1007/BF00286770.
75. Hurwitz LM, Yoshizumi T, Reiman RE, Goodman PC, Paulson EK, Frush DP, et al. Radiation dose to the fetus from body MDCT during early gestation. AJR Am J Roentgenol 2006;186:871–6. doi:10.2214/AJR.04.1915.
76. Scarsbrook AF, Bradley KM, Gleeson FV. Perfusion scintigraphy: diagnostic utility in pregnant women with suspected pulmonary embolic disease. Eur Radiol 2007;17:2554–60. doi:10.1007/s00330-007-0607-0.
77. Schuemichen C. Pulmonary embolism: is multislice CT the method of choice? Against. Eur J Nucl Med Mol Imaging 2005;32:107–12. doi:10.1007/s00259-004-1679-6.
78. Bajc M. Value of ventilation/perfusion SPECT detecting extensive pulmonary embolism in a patient with pneumonia. Thromb Haemost 2005;93:993–4.

79. Bajc M, Olsson CG, Palmer J, Jonson B. Quantitative ventilation/perfusion SPECT (QV/PSPECT): a primary method for diagnosis of pulmonary embolism. In: Freeman LM, editor. Nuclear Medicine Annual. Philadelphia: Lippincott Williams & Wilkins; 2004. p. 173–86.
80. Collart JP, Roelants V, Vanpee D, Lacrosse M, Trigaux JP, Delaunois L, et al. Is a lung perfusion scan obtained by using single photon emission computed tomography able to improve the radionuclide diagnosis of pulmonary embolism? Nucl Med Commun 2002;23:1107–13. doi:10.1097/00006231-200211000-00011.
81. Reinartz P, Wildberger JE, Schaefer W, Nowak B, Mahnken AH, Buell U. Tomographic imaging in the diagnosis of pulmonary embolism: a comparison between V/Q lung scintigraphy in SPECT technique and multislice spiral CT. J Nucl Med 2004;45:1501–8.
82. Lemb M, Pohlabeln H. Pulmonary thromboembolism: a retrospective study on the examination of 991 patients by ventilation/perfusion SPECT using Technegas. Nucl Med (Stuttg) 2001;40:179–86.
83. Davies CW, Wimperis J, Green ES, Pendry K, Killen J, Mehdi I, et al. Early discharge of patients with pulmonary embolism: a two-phase observational study. Eur Respir J 2007;30:708–14. doi:10.1183/09031936.00140506.
84. Olsson CG, Bitzen U, Olsson B, Magnusson P, Carlsson MS, Jonson B, et al. Outpatient tinzaparin therapy in pulmonary embolism quantified with ventilation/perfusion scintigraphy. Med Sci Monit 2006;12:PI9–13.
85. Tapson VF, Huisman MV. Home at last? Early discharge for acute pulmonary embolism. Eur Respir J 2007;30:613–5. doi:10.1183/09031936.00098007.
86. Meignan MA. Lung ventilation/perfusion SPECT: the right technique for hard times. J Nucl Med 2002;43:648–51.
87. Miniati M, Pistolesi M, Marini C, Di Ricco G, Formichi B, Prediletto R, et al. Value of perfusion lung scan in the diagnosis of pulmonary embolism: results of the Prospective Investigative Study of Acute Pulmonary Embolism Diagnosis (PISA-PED). Am J Respir Crit Care Med 1996;154:1387–93.
88. Sostman HD, Miniati M, Gottschalk A, Matta F, Stein PD, Pistolesi M. Sensitivity and specificity of perfusion scintigraphy combined with chest radiography for acute pulmonary embolism in PIOPED II. J Nucl Med 2008;49:1741–8. doi:10.2967/jnumed.108.052217.
89. Bajc M, Jonson B. Lung. In: Biersack HJ, Freeman LM, editors. Clinical nuclear medicine. Berlin Heidelberg: Springer-Verlag; 2007. p. 118–37.
90. Bajc M, Olsson B, Palmer J, Jonson B. Ventilation/perfusion SPECT for diagnostics of pulmonary embolism in clinical practise. J Intern Med 2008;264:379–87.
91. Bajc M, Olsson CG, Olsson B, Palmer J, Jonson B. Diagnostic evaluation of planar and tomographic ventilation/perfusion lung images in patients with suspected pulmonary emboli. Clin Physiol Funct Imaging 2004;24:249–56. doi:10.1111/j.1475-097X.2004.00546.x.
92. Jogi J, Palmer J, Jonson B, Bajc M. Heart failure diagnostics based on ventilation/perfusion single photon emission computed tomography pattern and quantitative perfusion gradients. Nucl Med Commun 2008;29:666–73. doi:10.1097/MNM.0b013e328302cd26.
93. Leblanc M, Leveillee F, Turcotte E. Prospective evaluation of the negative predictive value of V/Q SPECT using 99mTc-Technegas. Nucl Med Commun 2007;28:667–72. doi:10.1097/MNM.0b013e32827a8e99.
94. Freeman LM, Krynyckyi B, Zuckier LS. Enhanced lung scan diagnosis of pulmonary embolism with the use of ancillary scintigraphic findings and clinical correlation. Semin Nucl Med 2001;31:143–57. doi:10.1053/snuc.2001.21273.
95. Hagen PJ, Hartmann IJ, Hoekstra OS, Stokkel MP, Teule GJ, Prins MH. How to use a gestalt interpretation for ventilation-perfusion lung scintigraphy. J Nucl Med 2002;43:1317–23.
96. Howarth DM, Booker JA, Voutnis DD. Diagnosis of pulmonary embolus using ventilation/perfusion lung scintigraphy: more than 0.5 segment of ventilation/perfusion mismatch is sufficient. Intern Med J 2006;36:281–8. doi:10.1111/j.1445-5994.2006.01070.x.
97. Miniati M, Bottai M, Monti S, Salvadori M, Serasini L, Passera M. Simple and accurate prediction of the clinical probability of pulmonary embolism. Am J Respir Crit Care Med 2008;178:290–4. doi:10.1164/rccm.200802-207OC.
98. Perrier A, Roy PM, Aujesky D, Chagnon I, Howarth N, Gourdier AL, et al. Diagnosing pulmonary embolism in outpatients with clinical assessment, D-dimer measurement, venous ultrasound, and helical computed tomography: a multicenter management study. Am J Med 2004;116:291–9. doi:10.1016/j.amjmed.2003.09.041.
99. Wells PS, Anderson DR, Rodger M, Stiell I, Dreyer JF, Barnes D, et al. Excluding pulmonary embolism at the bedside without diagnostic imaging: management of patients with suspected pulmonary embolism presenting to the emergency department by using a simple clinical model and d-dimer. Ann Intern Med 2001;135:98–107.
100. Bajc M, Neilly B, Miniati M, Schuemichen C, Meignan M, Jonson B. EAMN Guidelines for ventilation/perfusion scintigraphy, Part 2. Algorithms and clinical considerations for diagnosis of pulmonary emboli with V/P SPECT and MDCT. Eur J Nucl Med Mol Imaging 2009; doi:10.1007/s00259-009-1169-y.
101. Lewczuk J, Piszko P, Jagas J, Porada A, Wojciak S, Sobkowicz B, et al. Prognostic factors in medically treated patients with chronic pulmonary embolism. Chest 2001;119:818–23. doi:10.1378/chest.119.3.818.
102. Riedel M, Stanek V, Widimsky J, Prerovsky I. Longterm follow-up of patients with pulmonary thromboembolism. Late prognosis and evolution of hemodynamic and respiratory data. Chest 1982;81:151–8. doi:10.1378/chest.81.2.151.
103. Lisbona R, Kreisman H, Novales-Diaz J, Derbekyan V. Perfusion lung scanning: differentiation of primary from thromboembolic pulmonary hypertension. AJR Am J Roentgenol 1985;144:27–30.
104. Moser KM, Page GT, Ashburn WL, Fedullo PF. Perfusion lung scans provide a guide to which patients with apparent primary pulmonary hypertension merit angiography. West J Med 1988;148:167–70.
105. Tunariu N, Gibbs SJ, Win Z, Gin-Sing W, Graham A, Gishen P, et al. Ventilation-perfusion scintigraphy is more sensitive than multidetector CTPA in detecting chronic thromboembolic pulmonary disease as a treatable cause of pulmonary hypertension. J Nucl Med 2007;48:680–4. doi:10.2967/jnumed.106.039438.
106. Worsley DF, Palevsky HI, Alavi A. Ventilation-perfusion lung scanning in the evaluation of pulmonary hypertension. J Nucl Med 1994;35:793–6.
107. Chapman CN, Sziklas JJ, Spencer RP, Rosenberg RJ. Pulmonary perfusion "without ventilation". J Nucl Med 1983;24:1149–50.
108. Sostman HD, Neumann RD, Gottschalk A, Greenspan RH. Perfusion of nonventilated lung: failure of hypoxic vasoconstriction? AJR Am J Roentgenol 1983;141:151–6.
109. Garg A, Gopinath PG, Pande JN, Guleria JS. Role of radio-aerosol and perfusion lung imaging in early detection of chronic obstructive lung disease. Eur J Nucl Med 1983;8:167–71. doi:10.1007/BF00252889.
110. Mispelaere D, Glerant JC, Audebert M, Remond A, Sevestre-Pietri MA, Jounieaux V. Pulmonary embolism and sibilant types

of chronic obstructive pulmonary disease decompensations. Rev Mal Respir 2002;19:415–23.
111. Tillie-Leblond I, Marquette CH, Perez T, Scherpereel A, Zanetti C, Tonnel AB, et al. Pulmonary embolism in patients with unexplained exacerbation of chronic obstructive pulmonary disease: prevalence and risk factors. Ann Intern Med 2006;144:390–6.
112. Schonhofer B, Kohler D. Prevalence of deep-vein thrombosis of the leg in patients with acute exacerbation of chronic obstructive pulmonary disease. Respiration 1998;65:173–7. doi:10.1159/000029254.
113. Friedman WF, Braunwald E. Alterations in regional pulmonary blood flow in mitral valve disease studied by radioisotope scanning. A simple nontraumatic technique for estimation of left atrial pressure. Circulation 1966;34:363–76.
114. Pistolesi M, Miniati M, Bonsignore M, Andreotti F, Di Ricco G, Marini C, et al. Factors affecting regional pulmonary blood flow in chronic ischemic heart disease. J Thorac Imaging 1988;3:65–72.
115. Li DJ, Stewart I, Miles KA, Wraight EP. Scintigraphic appearances in patients with pulmonary infection and lung scintigrams of intermediate or low probability for pulmonary embolism. Clin Nucl Med 1994;19:1091–3. doi:10.1097/00003072-199419120-00011.
116. Carvalho P, Lavender JP. The incidence and etiology of the ventilation/perfusion reverse mismatch defect. Clin Nucl Med 1989;14:571–6. doi:10.1097/00003072-198908000-00004.
117. Pace WM, Goris ML. Pulmonary SPECT imaging and the stripe sign. J Nucl Med 1998;39:721–3.
118. Schümichen C. V/Q-scanning/SPECT for the diagnosis of pulmonary embolism. Respiration 2003;70:329–42. doi:10.1159/000072892.
119. Cei M, Mumoli N, Mariotti F, Pardelli R. The importance of clinical suspicion in diagnosing pulmonary embolism: a case of false-positive high probability radionuclide perfusion lung scan. Eur J Emerg Med 2004;11:234–6. doi:10.1097/01.mej.0000134839.34865.1f.