



UNIVERSITÀ
DEGLI STUDI
FIRENZE

FLORE

Repository istituzionale dell'Università degli Studi di Firenze

Dendritic cells: ultrastructural and immunophenotypical changes upon nb-UVB in vitiligo skin.

Questa è la Versione finale referata (Post print/Accepted manuscript) della seguente pubblicazione:

Original Citation:

Dendritic cells: ultrastructural and immunophenotypical changes upon nb-UVB in vitiligo skin / Prignano F; Ricceri F; Bianchi B; Guasti D; Bonciolini V; Lotti T; Pimpinelli N. - In: ARCHIVES OF DERMATOLOGICAL RESEARCH. - ISSN 0340-3696. - STAMPA. - 303:(2011), pp. 231-238. [10.1007/s00403-010-1109-5]

Availability:

This version is available at: 2158/770854 since:

Published version:

DOI: 10.1007/s00403-010-1109-5

Terms of use:

Open Access

La pubblicazione è resa disponibile sotto le norme e i termini della licenza di deposito, secondo quanto stabilito dalla Policy per l'accesso aperto dell'Università degli Studi di Firenze (<https://www.sba.unifi.it/upload/policy-oa-2016-1.pdf>)

Publisher copyright claim:

(Article begins on next page)

Dendritic cells: ultrastructural and immunophenotypical changes upon nb-UVB in vitiligo skin

Francesca Prignano · F. Ricceri · B. Bianchi ·
D. Guasti · V. Bonciolini · T. Lotti ·
N. Pimpinelli

Received: 5 July 2010/Revised: 29 November 2010/Accepted: 30 November 2010/Published online: 21 December 2010
© Springer-Verlag 2010

Abstract The role of dendritic cells in vitiligo is still unclear. Few studies have provided contradictory results about their quantitative variation and no data exist concerning their immunophenotypical distribution in diseased skin. The purpose of our study was to analyze the presence, the distribution, the immunophenotypical markers and the effects of nb-UVB therapy on dendritic cells in non-lesional, perilesional, and lesional vitiligo skin. Punch-biopsies of 6 mm were taken from lesional, perilesional, and non-lesional skin of 12 patients affected by non-segmental vitiligo, treated with nb-UVB. An immunohistochemical and an ultrastructural analysis were performed. Immunohistochemical and ultrastructural analysis showed both quantitative and qualitative modifications of Langerhans cells. Nb-UVB therapy, one of the most effective treatments for the disease, was able to reduce the Langerhans cells number and to redistribute main dendritic subsets. This study underlines the importance of dendritic cells, Langerhans cells in particular, in non-segmental vitiligo, in its pathogenesis and in its better therapeutical approach.

Keywords Vitiligo · Dendritic cells · Narrow band-UVB · Immunophenotype

Introduction

Vitiligo is an acquired hypomelanotic disease characterized by loss of melanocytes that can be observed in 0.5–2% of the population [8, 20]. Despite much research, its pathophysiological mechanism is not fully clear. There are three main hypotheses that consider different factors as causes of melanocytes' destruction: autoimmune, biochemical, and neuronal theory. The latter is still considered as the most suitable one to explain the pathogenesis of segmental vitiligo (a localized type of vitiligo with a segmental distribution); it suggests the release of some chemical mediators from peripheral nerve endings as a cause of the decreased melanin production [6]. The autoimmune hypothesis proposes that a breakdown of tolerance, with activation of both the humoral and the cellular arm of immune system, may be the cause of melanocytes destruction [13]. The biochemical theory ascribes the destruction of melanocytes to autocytotoxic metabolites, which derive from the synthesis of melanin. Several studies prove the presence of oxidative stress and the accumulation of free radicals in the epidermal layer of affected skin, and recently antioxidant enzymes and lipid peroxidation have been detected in the tissues of vitiligo patients [2, 4]. Le Poole et al. in 1993 worked out the “convergence theory”, which suggests the synergistic role of all the above-mentioned factors and cells in the pathogenesis of vitiligo [9].

Recently, supported by the concept of “epidermal-melanin unit” proposed by Fitzpatrick and Breathnach, a new theory has been proposed: the eclectic hypothesis [5, 7]. Eclectic hypothesis considers vitiligo as the expression of a change in the normal communication network, involving melanocytes, keratinocytes, antigen-presenting cells, mast cells, and fibroblasts. The formation of an adverse microenvironment for the melanocytes survival

F. Prignano (✉) · F. Ricceri · B. Bianchi · V. Bonciolini ·
T. Lotti · N. Pimpinelli
Division of Clinical, Preventive and Oncology Dermatology,
Department of Critical Care Medicine and Surgery, University
of Florence, P.za Indipendenza, 11, 50129 Florence, Italy
e-mail: francesca.prignano@unifi.it

D. Guasti
Department of Human Anatomy, Histology and Forensic
Medicine, University of Florence, Florence, Italy

has been related to growth factors, cytokines, inflammatory mediators, and adhesion molecules [7].

The histopathological data on vitiligo could be useful to find answers to many questions which are still unresolved. As a lot of studies have provided contradictory results about the quantitative variation of Langerhans cells in the vitiligo-affected skin [12] and no previous data exist concerning the immunophenotypical distributions of specific markers of dendritic cells, we focused our attention on defining the ultrastructural features of lesional, perilesional, and non-lesional skin from vitiligo patients with a similar clinical history concerning the lesions' extension, duration of the disease, and absence of autoimmunity. We observed an increase of dendritic cells in lesional and perilesional vitiligo skin, with ultrastructural alterations in their mitochondria especially in perilesional skin [17]. The purpose of our study was to evaluate the effects of nb-UVB (narrow band-B ultraviolet)—at present one of the most effective therapies for vitiligo—on dendritic cells in lesional and perilesional vitiligo skin [1, 10, 11].

Materials and methods

Punch-biopsies of 6 mm were taken from lesional, perilesional, and non-lesional skin of 12 patients affected by non-segmental generalized vitiligo with a similar clinical history (lesions extension, ongoing of the disease and absence of circulating autoantibodies) (Table 1).

A written informed consensus was obtained from all patients and procedures were carried out in accordance with the ethical standards of the Committee on Human Experimentation of the Department of the Dermatological Science and the Declaration of Helsinki.

Each patient underwent three biopsies (from lesional, perilesional, and non-lesional vitiligo skin) before and after nb-UVB phototherapy (total-body exposure by 0.21 J/cm² for body surface, three times a week for 2 months). Lesional, perilesional and non-lesional skin are defined as clinically affected skin (lesional), skin along the edge of the white patch (perilesional) and clinically unaffected, the normally pigmented skin (non-lesional).

All biopsies were divided in two parts in order to perform both immunohistochemical and ultrastructural study.

Immunohistochemical study

Immunostaining was carried out on each half of the six punch-biopsies, we obtained from lesional, perilesional and non-lesional vitiligo skin before and after nb-UVB exposure, using an APAAP (alkaline-phosphatase–anti-alkaline-phosphatase) method and mouse monoclonal anti-human antibodies (MoAb) as primary reagents. All biopsies were frozen at –80°C and then 5- μ m serial cryostat sections were cut and fixed in ice-cold acetone for 4 min prior to staining.

Thereafter, the sections were incubated with human serum of AB group followed by primary MoAb for 2 h at room temperature and avoiding light exposure. The sections were accurately washed and incubated for 40 min with rabbit's anti-mouse immunoglobulin antiserum (RAM, 1:30) (Dako, Glostrup, Denmark) and processed with the APAAP complex (1:50) (Laborometrics, Milan, Italy). RAM/APAAP incubation was repeated twice to improve the labeling. Binding of the complex was revealed by hexazotized new fuchsin as a chromogenic substrate (Merck, Darmstadt, Germany). The sections were then counterstained with Mayer's hematoxylin. Control sections

Table 1 Clinical data of vitiligo patients

Patients	Age	Age of onset	Biopsy site (lesional and perilesional skin)	Biopsy site (non-lesional skin)
n. 1	58	53	Hand	Abdomen
n. 2	62	56	Abdomen	Trunk
n. 3	46	41	Trunk	Hand
n. 4	35	30	Trunk	Trunk
n. 5	41	35	Hand	Abdomen
n. 6	34	28	Hand	Abdomen
n. 7	25	20	Trunk	Hand
n. 8	19	15	Abdomen	Trunk
n. 9	36	30	Hand	Trunk
n. 10	37	32	Trunk	Hand
n. 11	22	16	Abdomen	Trunk
n. 12	43	39	Trunk	Trunk

Table 2 Monoclonal antibodies used in this study

MoAb type	Cellular subset selected	MoAb meaning
CD1a	APC ^a	Non-peptide antigens ^c presentation to lymphocytes
HLA-DR	APC ^b	Peptide antigens presentation to lymphocytes
CD83	Langerhans cells	Maturation marker
CD86	Dendritic cells	Activation marker (co-stimulation complex B7)
Langerin	Langerhans cells	Non-peptide antigens ^c presentation to lymphocytes
CD68	Monocytes (including tissue macrophages)	Endocytosis and/or lysosomal traffic

^a APC: antigen-presenting cell, particularly Langerhans cells

^b APC: antigen-presenting cell, particularly dendritic cells, macrophages and B lymphocytes

^c Non-peptide antigens includes lipid and carbohydrate antigens

were incubated with normal mouse IgG. The MoAbs used in this study are summarized in Table 2.

Electron microscopy

Half of each biopsy obtained from non-nb-UVB-exposed and nb-UVB-exposed skin, and from vitiligo lesional, perilesional, and non-lesional skin was fixed in a mixture of 2% formaldehyde and 2.5% glutaraldehyde in 0.1 mmol/l cacodylate buffer, pH 7.4, at 5°C for 3 h, followed by postfixation in 1% OsO₄ in phosphate buffer, pH 7.4 at room temperature for 2 h. The specimens were dehydrated in a graded acetone series, passed through propylene-oxide and embedded in Epon 812. A sequential number of semi-thin sections were stained with uranylacetate, followed by bismuth subnitrate or lead citrate, and examined in a Jeol 1010 (Tokyo, Japan) at 80 kV.

Results

Immunohistochemical analysis

A total of 432 sections were obtained and analyzed by two examiners. Number and distribution (in epidermis and dermis) of marked cells in three different fields of non-exposed and nb-UVB-exposed vitiligo skin were studied. The result of the count was expressed as an average value for each MoAb apart. We proposed both the average values of cells count distinguishing before and after phototherapy (Table 3), and their percentage variations (Table 4).

In non-lesional skin we did not report significant modifications of the expression of the proteins (both in the epidermis and in the dermis) after nb-UVB phototherapy, with the exception of anti-CD1a (reduction of 3% in the epidermis and increased of 11% in the dermis) and anti-HLA-DR (increased both in the epidermis and in the dermis (Figs. 1, 2a, b).

In perilesional vitiligo skin (Figs. 1, 2c, d) upon nb-UVB, in the epidermis, CD1a and Langerin were increased of 24 and 75%, respectively, while HLA-DR showed a reduction of 50%. In the dermis the immunophenotypical markers maintained the same distribution as in vitiligo lesional skin, while the markers for CD1a and HLA-DR, but not for Langerin, were reduced. Langerin positive cells were reduced of 60% after treatment; there was also a reduction of CD68 positive cells.

In the epidermis of lesional skin all MoAb were less expressed after nb-UVB phototherapy with the exception of anti-HLA-DR antibody. Particularly CD1a and Langerin showed both a reduction of about 70% and they could be considered as the quantitative distribution index of Langerhans cells, while the reductions of CD83 and CD86 were 43 and 57%, respectively. In the dermis, the markers as CD1a, HLA-DR and Langerin, were more expressed after phototherapy, about 40, 60 and 70%, respectively. Upon nb-UVB treatment there was a decrease of CD68+ cells both in epidermis and dermis. CD68+ cells in the dermis of lesional skin underwent a minor depletion being the 70% (Figs. 1, 2e, f).

Ultrastructural analysis

Before nb-UVB therapy, in non-lesional vitiligo skin we did not find any relevant alterations. The basal keratinocytes showed a well differentiated phenotype and a normal and well oriented cytoskeleton within their cytoplasm (Fig. 3a). The anchoring fibrils were well preserved (Fig. 3b). The epidermal-melanin unit was represented by a steady number of melanocytes and keratinocytes and there were signs of melanogenesis, as shown by the high member of melanosomes in all phases of differentiation. Langerhans cells showed the typical indented nucleus and a rough endoplasmic reticulum, Golgi apparatus and some mitochondria within the cytoplasm. The mitochondria were more numerous in some cells than in others, with a well preserved ultrastructure.

Table 3 Statistical analysis of histologic evaluation before and after nb-UVB treatment

	CD1a		HLA-DR		CD83		CD86		Langerin		CD68	
	Epid	Der	Epid	Der	Epid	Der	Epid	Der	Epid	Der	Epid	Der
Non-lesional skin												
Before												
Mean	6.2	1.8	1.5	6	4	1.5	1.5	0	2	0	0	0
SD	0.1	0.2	2.1	2.8	2.8	0.8	2.1	0	2.8	0	0	0
After												
Mean	6	2	2	9	4	1.5	1.5	0	3	0	0	0
SD	0.7	0.8	0.7	7.7	1.4	0.3	1	0	5.6	0	0	0
<i>p</i> value			0.29	0.14	0.01	0.01	0.34		0.18			
Perilesional skin												
Before												
Mean	9.6	3.3	6.6	6.3	2	0.6	1.6	0	4	4	3	5.2
SD	0.7	5.6	1.4	8.5	2.8	1.1	2.8	0	2.7	2.7	3.3	5.3
After												
Mean	12	4.5	3.5	9	0	0	1	0	7	1	0	0
SD	4.2	0.7	0.7	7	0	0	1.4	0	5.6	0	0	0
<i>p</i> value	0.24	0.33	0.01	0.47	0.25	0.21	0.31		0.29	0.07	0.1	0.09
Lesional skin												
Before												
Mean	13	5.8	3.7	7.3	5.3	3	2.3	0	11	1.5	1.5	3.3
SD	2.2	4.3	1.7	3.7	6.8	2.5	2.5	0	2.5	1.5	2.6	4.1
After												
Mean	4	8	4	11.5	3	5	1	0.5	3.5	2.5	0	1
SD	1.4	5.6	5.6	7.8	4.2	7.1	1.4	0.7	0.7	3.5	0	1.4
<i>p</i> value	0.008	0.34	0.46	0.39	0.35	0.29	0.25	0.25	0.01	0.37	0.19	0.21

Epid Epidermis, *Der* dermis

Table 4 The percentage variations (each value is expressed as percentage)

	CD1a		HLA-DR		CD83		CD86		Langerin		CD68	
	Epid	Derm	Epid	Derm	Epid	Derm	Epid	Derm	Epid	Derm	Epid	Derm
Non-lesional skin	↓3	↑11	↑33	↑50	↔	↔	↔	↔	↔	↔	↔	↔
Perilesional skin	↑24	↑36	↓48	↑43	↓100	↓100	↓41	↔	↑75	↓60	↓100	↓100
Lesional skin	↓69	↑38	↑19	↑58	↓43	↑25	↓57	↑0.5	↓68	↑67	↓100	↓70

↓ Reduction, ↑ increase, ↔ no variation

The basal membrane in perilesional vitiligo skin appeared well developed, with focal interruptions. The epidermal cells of the basal and suprabasal layers presented ultrastructural alterations of their mitochondria consistent with the results of one of our previous work [17]. Langerhans cells of perilesional skin presented a tendency to distribute in the suprabasal layer. They were numerous and displayed rarefied chromatin in their nucleus with tendency to lose their typical nuclear indentation. The mitochondria of these cells appeared numerous and with ultrastructural

alterations, that consisted in rarefactions or disruption of their membranes, till the total disappearance of the cristae (Fig. 4a). Sometime, close to Golgi apparatus or close to the cytoplasmic membrane was possible to appreciate the presence of the Birbeck granules (Fig. 4b), which not always reached the typical racket-like shape, as distinctive feature of terminal differentiation.

In lesional vitiligo skin the basal membrane appeared well preserved; basal and suprabasal keratinocytes presented no cytoskeletal alterations or reorganization of

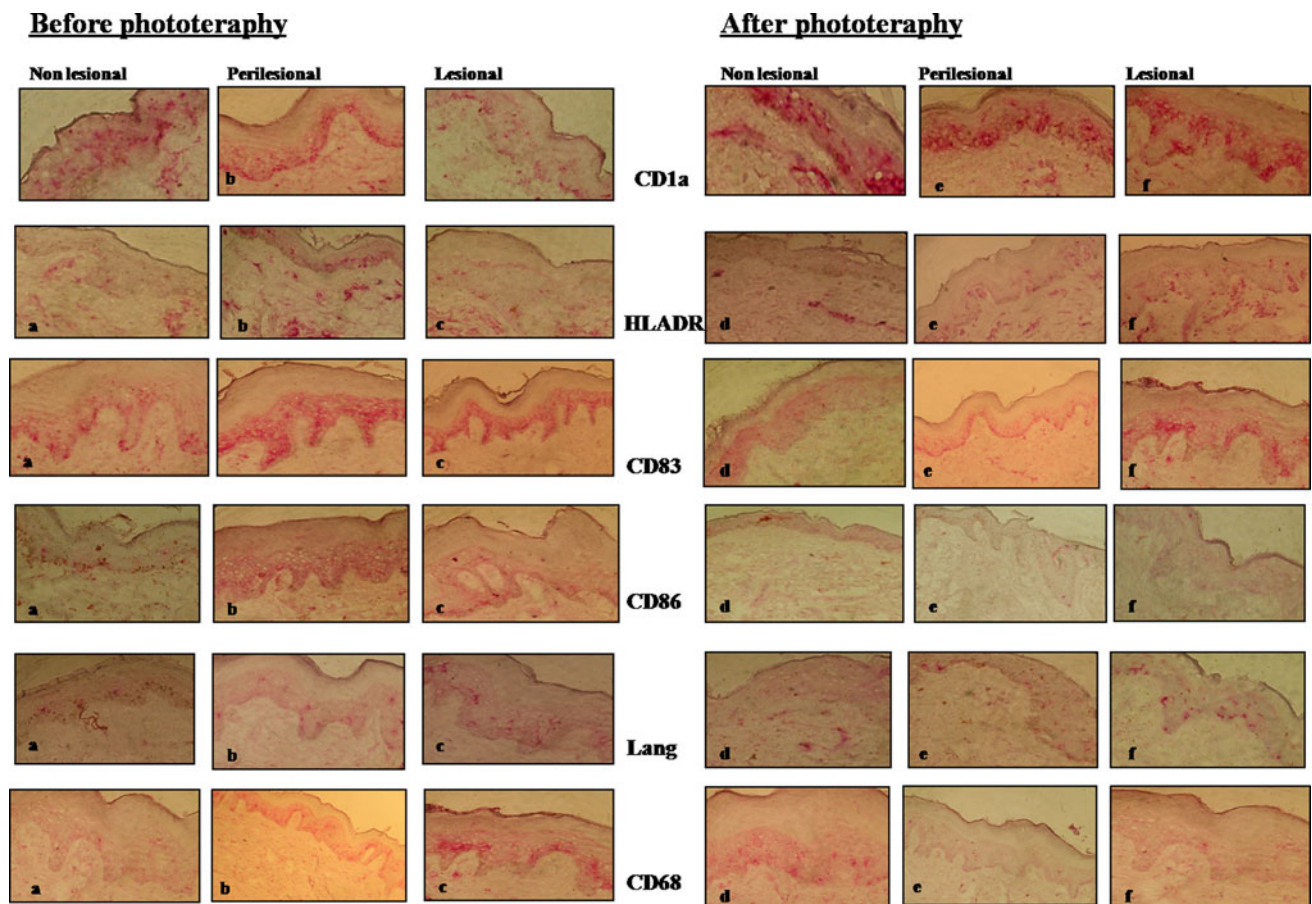


Fig. 1 Immunohistochemical results of non-lesional (a, d), perilesional (b, e) and lesional (c, f) of vitiligo skin before and after nb-UVB with the main monoclonal antibodies used in the study

intracytoplasmic organelles with a widening of intercellular space in the basal layer. Melanocytes were never detected in any of the observed fields. The most important ultrastructural alterations concerned Langerhans cells; they were numerous in the basal layer, with a tendency to distribute also in the suprabasal layer. Some of them presented an indented nucleus, a rough endoplasmic reticulum (RER), a well developed Golgi apparatus and mitochondria with ultrastructural alterations of their membranes. Only in very few of them it was possible to observe the typical Birbeck granule. There were also dendritic cells with a less differentiated phenotype, with many mitochondria within the cytoplasm and some of them with ultrastructural alterations.

After nb-UVB therapy, in the non-lesional vitiligo skin there were signs of increased melanogenesis in melanocytes with many melanosomes within the keratinocytes. There were no other modifications compared to the pre-nb-UVB treatment. Also perilesional vitiligo skin showed some signs of melanogenesis activation: a lot of melanosomes were observed in the epidermal-melanin unit of basal and suprabasal layers (Fig. 5) particularly between

the basal and spinous layer. Langerhans cells preserved all the ultrastructural alterations observed in perilesional vitiligo skin, with their mitochondria partially destroyed losing the integrity of their membranes.

In the lesional nb-UVB-exposed skin, the epidermal cells presented more melanosomes in their cytoplasm. As before phototherapy the intercellular spaces were enlarged. In their cytoplasm there were a lot of mitochondria, which were outnumber compared to other intracytoplasmic organelles, both in keratinocytes and in Langerhans cells. Furthermore most of Langerhans cells were devoid of Birbeck granules [17].

Discussion

This study focuses on the pathogenetic involvement of dendritic cells, specifically Langerhans cells, in vitiligo. In a previous study [17] we have demonstrated their heterogeneous distribution in lesional, perilesional and non-lesional vitiligo skin. According with these results we wanted to investigate their modifications after nb-UVB.

Fig. 2 **a** Epidermis of non-lesional skin—comparison between MoAb expression before and after phototherapy. **b** Dermis of non-lesional skin—comparison between MoAb expression before and after phototherapy. **c** Epidermis of perilesional skin—comparison between MoAb expression before and after phototherapy. **d** Dermis of perilesional skin—comparison between MoAb expression before and after phototherapy. **e** Epidermis of lesional skin—comparison between MoAb expression before and after phototherapy. **f** Dermis of lesional skin—comparison between MoAb expression before and after phototherapy

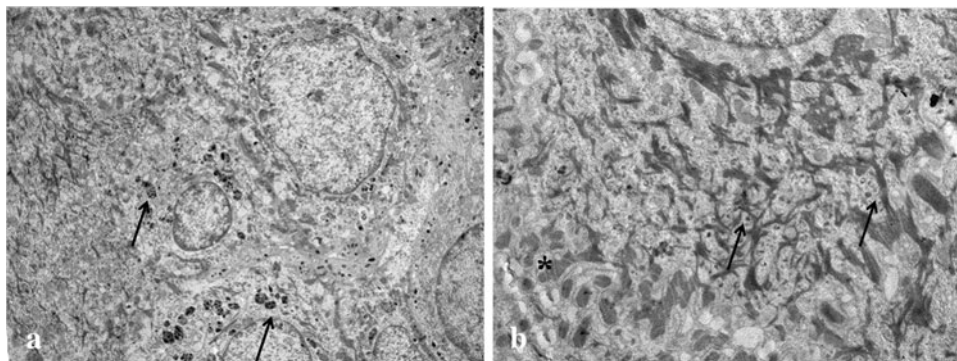
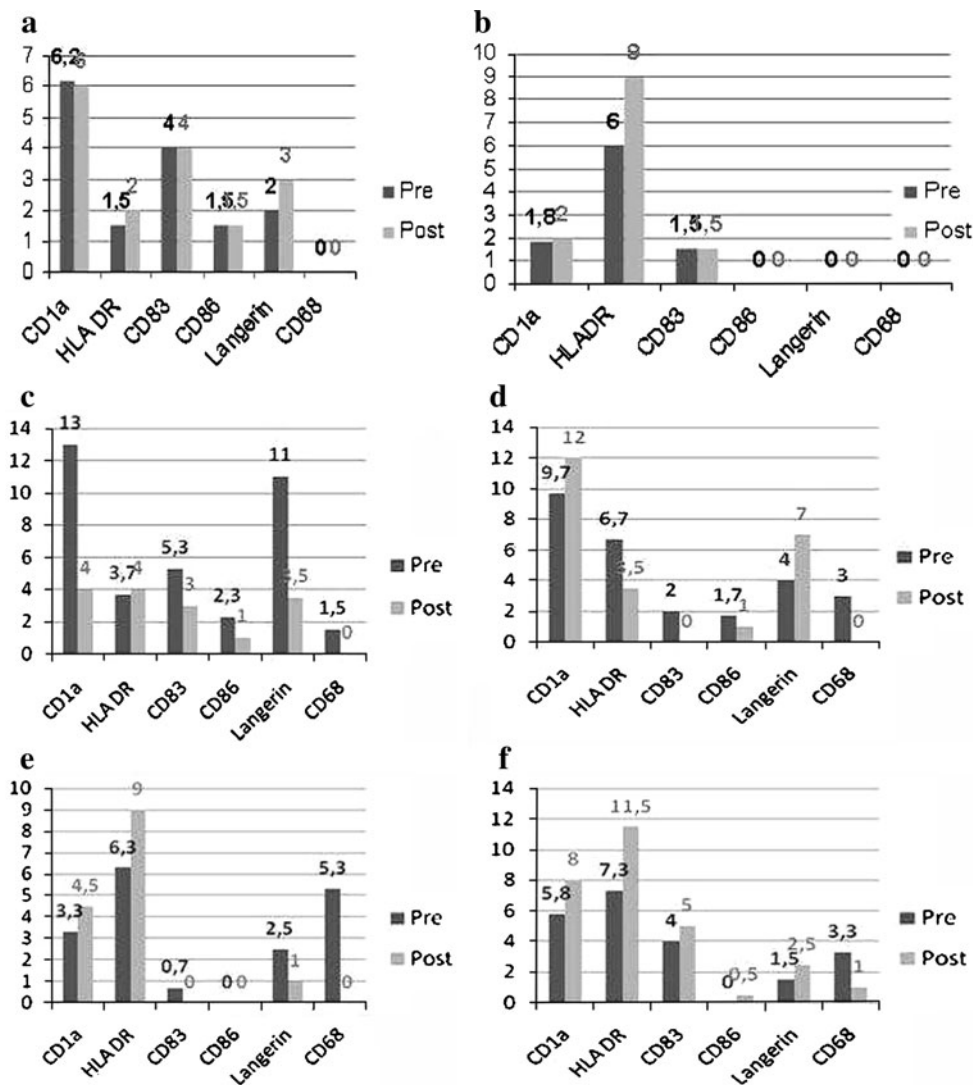


Fig. 3 **a** Electron microscopy; magnification $\times 6,000$. Non-lesional vitiligo skin pre-nb-UVB. Basal and suprabasal keratinocytes in a well differentiated condition and many melanosomes (*arrow*) within

their cytoplasm. **b** Electron microscopy; magnification $\times 12,000$. Non-lesional vitiligo skin pre-nb-UVB. Anchoring fibrils (*arrow*) and desmosomes (*asterisk*) appear well preserved

The first result is about the quantitative modification of dendritic cells in non-lesional, perilesional, and lesional vitiligo skin after nb-UVB. In the epidermis of lesional skin, both CD1a and Langerin were reduced of 70% (69 and 68%, respectively). This data was associated with an

increase of Langerin in the dermis of the lesional vitiligo skin (67%). Therefore, in accordance with the “redistribution of Langerhans cells” theory [13], we suppose that after nb-UVB phototherapy, Langerhans cells migrate from epidermis to dermis in order to reach the draining lymph

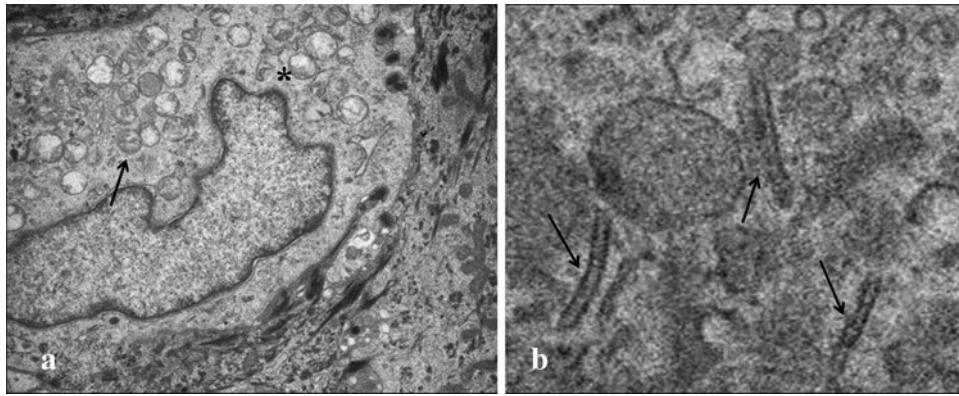


Fig. 4 a Electron microscopy; magnification $\times 8,000$. Perilesional vitiligo skin pre-nb-UVB. A Langerhans cell with numerous mitochondria. Most of them presented ultrastructural modifications: from disruptions of their membranes (*arrow*) till disappearance of the

cristae (*asterisk*). **b** Electron microscopy; magnification $\times 30,000$. Perilesional vitiligo skin pre-nb-UVB. A detail of a Langerhans cell: Birbeck granules (*arrow*) in the peri-Golgian area

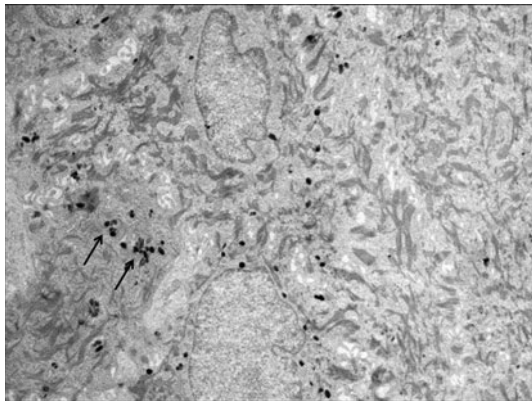


Fig. 5 Electron microscopy; magnification $\times 8,000$. Perilesional vitiligo skin post-nb-UVB. Many melanosomes—all in a well differentiated status—within basal and suprabasal keratinocytes

nodes. More exactly there is a reduced expression of CD86 both in lesional and perilesional vitiligo skin. CD86 in combination with CD80 form the “B7 complex”, which is used by Langerhans cells as a co-stimulatory molecule to lymphocytes for the antigen presentation process. Therefore, the reduction of CD86 expression is indicative of an impaired state of the functional activity of Langerhans cells [19, 21]. Another important and new data is the depletion of tissue macrophages after nb-UVB phototherapy. The expression of CD68 is reduced in epidermis of lesional and perilesional skin. On the other hand in the dermis there is a partial decrease (70 vs. 100%) and this could be explained as an “attenuation” of nb-UVB by the stratum corneum of the skin.

The second result is related to the distribution of some immunophenotypical markers of dendritic cells, confirmed by both immunohistochemical and electron microscopy data. Nb-UVB are known to reduce Langerhans cells functions but they can also induce their immunophenotypical

modifications. In the immunohistochemical analysis, we have showed a reduced expression of CD83 in lesional and perilesional skin (in the epidermis of 45 and 100%, respectively and also in the dermis of perilesional skin of 100%). At the same time, by electron microscopy we have not found any morphological signs of terminal differentiation of Langerhans cells. Specifically, it was not possible to detect the presence of the typical Birbeck granule in lesional skin. After nb-UVB exposure, in fact, there is a replacement of Langerhans cells, which have migrated to the dermis, by immature precursors [15]. This CD83 expression reduction, on the other hand, was not observed in the lesional dermis of vitiligo skin where there is an increase of 25%. A possible explanation is that in perilesional vitiligo dermis there is a particular dendritic subset (as in other inflammatory conditions) [18], which is Langerin+, CD103+ and devoid of Birbeck granules. We cannot exclude an immature immunophenotyping of this subset of dendritic cells, which could be an explanation for the increasing in CD83 expression. Finally according to our data, we suggest an involvement of this dendritic subset in the pathogenesis of vitiligo. Previous studies [12, 14, 17] have demonstrated an increase of Langerhans cells in vitiligo skin without clearing the subset involved. We have already shown in another skin disease [16] the relevance of dendritic cells in the pathogenesis, defying their role consistent with the numerous subsets. We are not able to stress exactly which is the definitive role of these cells in the pathogenesis of vitiligo; surely the identification of another dendritic subset other than Langerhans cells is relevant. In other conditions these langerin+CD103+ dendritic cells stimulate naive T cells to proliferate and produce IFN-gamma and IL-17. This process is particularly strong in presence of GM-CSF. They are efficient in presenting viral antigens (especially) but they are also very efficient in presenting skin-derived self-antigens [3]. We also found a

particular immunophenotypical change of Langerhans cells after nb-UVB exposure in a switch to the preferential presentation of antigens other than peptides, probably lipid or carbohydrate antigens. This occurrence could be better described as “antigenic redistribution” of Langerhans cells. It is particularly evident in the epidermis of perilesional skin, where we showed an increase of CD1a and Langerin expression, by 24 and 75%, respectively, molecules which are normally not used to present peptide antigens, but lipidic or carbohydrate ones [11]. We can speculate that this “antigenic redistribution” of Langerhans cells is an exclusive effect of nb-UVB phototherapy, because no other immunomodulating treatment has demonstrated a similar result as far as we know.

In conclusion, our study underlines the importance of dendritic cells, specifically Langerhans cells, in the pathogenesis of non-segmental vitiligo. Nb-UVB, one of the most used therapy for vitiligo, is effective because (next to all the other biological activities) it reduces the number of pre-existing Langerhans cells and redistributes the dendritic subsets.

References

1. Abdulla SJ, Desgroseilliers JP (2008) Treatment of vitiligo with narrow-band ultraviolet B: advantages and disadvantages. *J Cutan Med Surg* 12(4):174–179
2. Becatti M, Prignano F, Fiorillo C et al (2010) The involvement of Smac/DIABLO, p53, NF- κ B, and MAPK pathways in apoptosis of keratinocytes from perilesional vitiligo skin: protective effects of curcumin and capsaicin. *Antioxid Redox Signal* 13(9):1309–1321
3. Bedoui S, Whitney PG, Waithman J et al (2009) Cross-presentation of viral and self antigens by skin-derived CD103+ dendritic cells. *Nat Immunol* 10(5):488–495
4. Dammak I, Boudaya S, Abdallah FB, Turki H, Attia H, Hentati B (2009) Antioxidant enzymes and lipid peroxidation at the tissue level in patients with stable and active vitiligo. *Int J Dermatol* 48:476–480
5. Fitzpatrick TB, Breathnach AS (1963) Die epidermale Melanin-Einheit-system. *Dermatol Wochenschr* 147:635–642
6. Grimes PE (2004) White patches and bruised souls: advances in the pathogenesis and treatment of vitiligo. *J Am Acad Dermatol* 51:85–87
7. Hautmann G, Moretti S, Lotti T, Hercogovà J (2004) Pathogenesis of vitiligo: evidence for a possible ongoing disorder of the cutaneous microenvironment. In: Lotti T, Hercogovà J (eds) *Vitiligo: new data and hypotheses*. Marcel-Dekker, New York, pp 99–121
8. Huggings RH, Schwartz RA, Janniger CK (2005) Vitiligo. *Acta Dermatoven APA* 14(4):137–142, 144–145
9. Le Poole IC, Das PK, van den Wijngaard RMJGJ et al (1993) Review of the etiopathomecanism of vitiligo: a convergence theory. *Exp Dermatol* 2:145–153
10. Lotti T, Berti S, Moretti S (2009) Vitiligo therapy. *Expert Opin Pharmacother* 10(17):2779–2785
11. Lotti T, Prignano F, Buggiani G (2007) New and experimental treatments of vitiligo and other hypomelanoses. *Dermatol Clin* 25:393–400
12. Montes LF, Abulafia J, Wilborn WH et al (2003) Value of histopathology in vitiligo. *Int J Dermatol* 42:57–61
13. Ongena K, Van Geel N, Naeyaert JM (2003) Evidence for an autoimmune pathogenesis of vitiligo. *Pigment Cell Res* 16:90–100
14. Panuncio AL, Vignale R (2003) Ultrastructural studies in stable vitiligo. *Am J Dermatopathol* 25(1):16–20
15. Pradhan S, Kyung Kim H, Thrash CJ et al (2008) A critical role for the proapoptotic protein Bid in ultraviolet-induced immune suppression and cutaneous apoptosis. *J Immunol* 181:3077–3088
16. Prignano F, Domenici L, Carli P et al (1999) Langerhans cell Histiocytosis of the vulva: an ultrastructural study. *Ultrastruct Pathol* 23:127–132
17. Prignano F, Pescitelli L, Becatti M et al (2009) Ultrastructural and functional alterations of mitochondria in perilesional vitiligo skin. *J Dermatol Sci* 54:157–167
18. Prignano F, Ricceri F, Bianchi B et al (2009) Quantity, distribution and immunophenotypical modification of dendritic cells upon biological treatments in psoriasis. *Int J Immunopathol Pharmacol* 22(2):379–387
19. Rattis FM, Concha M, Delbiez-Gauthier C et al (1998) Effects of Ultraviolet B radiation on human Langerhans cells: functional alteration of CD86 upregulation and induction of apoptotic cell death. *J Invest Dermatol* 3:373–379
20. Taieb A, Picardo M (2007) The definition and assessment of vitiligo: a consensus report of vitiligo European Task Force. *Pigment Cell Res* 20:27–35
21. Weiss JM, Renkl AC, Denfeld RW et al (1995) Low-dose UVB radiation perturbs the functional expression of B7.1 and B7.2 costimulatory molecules on human Langerhans cells. *Eur J Immunol* 25:2858–2862