



UNIVERSITÀ
DEGLI STUDI
FIRENZE

FLORE

Repository istituzionale dell'Università degli Studi di Firenze

Wide-area 308-nm phototherapy with nonlaser light in the treatment of psoriasis: results of a pilot study.

Questa è la Versione finale referata (Post print/Accepted manuscript) della seguente pubblicazione:

Original Citation:

Wide-area 308-nm phototherapy with nonlaser light in the treatment of psoriasis: results of a pilot study / Mavilia L;Campolmi P;Rossi R;Mori M;Pimpinelli N;Cappugi P. - In: BRITISH JOURNAL OF DERMATOLOGY. - ISSN 0007-0963. - STAMPA. - 152:(2005), pp. 1376-1377. [10.1111/j.1365-2133.2005.06612.x]

Availability:

The webpage <https://hdl.handle.net/2158/771645> of the repository was last updated on

Published version:

DOI: 10.1111/j.1365-2133.2005.06612.x

Terms of use:

Open Access

La pubblicazione è resa disponibile sotto le norme e i termini della licenza di deposito, secondo quanto stabilito dalla Policy per l'accesso aperto dell'Università degli Studi di Firenze (<https://www.sba.unifi.it/upload/policy-oa-2016-1.pdf>)

Publisher copyright claim:

La data sopra indicata si riferisce all'ultimo aggiornamento della scheda del Repository FloRe - The above-mentioned date refers to the last update of the record in the Institutional Repository FloRe

(Article begins on next page)

limited to the lower parts of the epidermis where mild cytological atypia is also seen. At the sides of the lesions inward turning of the rete pegs is seen but there are no other findings supportive of human papillomavirus infection. These particular histological findings reflect the unusual clinical appearance of these rather punctate keratotic lesions which do not fit into the ordinary categories of solar keratoses or Bowen's disease seen on sun-exposed sites. Sunbed-related NMSC has been reported but no reports have described the distinct appearance and histology of these dysplastic lesions which could be synonymous with sunbed use.

Department of Dermatology, F. ISMAIL
The Royal London Hospital, London E1 1BB, U.K. E.A. O'TOOLE
*Department of Dermatology, J.M. MCGREGOR
Basildon and Thurrock General Hospitals, U.K. S.M. KHORSHID*
E-mail: f.ismail@qmul.ac.uk

References

- 1 International Agency for Research on Cancer. *Solar and Ultraviolet Radiation and Human Exposure*. Lyon: IARC, 1992.
- 2 Sterenbourg HJ, van der Leun JC. Tumorigenesis by a long wavelength UVA source. *Photochem Photobiol* 1990; **51**:325–30.
- 3 De Laat JMT, De Gruijl FR. The role of UVA in the aetiology of non-melanoma skin cancer. *Cancer Surv* 1996; **26**:173–91.
- 4 Woollons A, Kipp C, Young AR et al. The 0.8% ultraviolet B content of an ultraviolet A sunlamp induces 75% of cyclobutane pyrimidine dimers in human keratinocytes *in vitro*. *Br J Dermatol* 1999; **140**:1023–30.
- 5 Speight EL, Dahl MG, Farr PM. Actinic keratosis induced by use of sunbed. *Br Med J* 1994; **308**:415.
- 6 Lever LR, Lawrence CM. Non-melanoma skin cancer associated with the use of a tanning bed. *N Engl J Med* 1995; **332**:1450–1.
- 7 Roest MAB, Keane FM, Agnew K et al. Multiple squamous skin carcinomas following excess sunbed use. *J R Soc Med* 2001; **94**:636–7.
- 8 Karagas MR, Stannard VA, Mott LA et al. Use of tanning devices and risk of basal cell and squamous cell skin cancers. *J Natl Cancer Inst* 2002; **94**:224–6.
- 9 van Praag MC, Bavinck JN, Bergman W et al. PUVA keratosis. A clinical and histopathologic entity associated with an increased risk of nonmelanoma skin cancer. *J Am Acad Dermatol* 1993; **28**:412–17.

Conflicts of interest: none declared.

Wide-area 308-nm phototherapy with nonlaser light in the treatment of psoriasis: results of a pilot study

DOI: 10.1111/j.1365-2133.2005.06612.x

SIR, The phototherapy-based treatment of psoriasis has been greatly updated during the last decade. Among the newly introduced devices, the 308-nm excimer laser¹ has proved to

be effective in terms of rapidity of action and stability of remissions.^{2,3} For about 3 years⁴ we have been using a 308-nm XeCl monochromatic excimer light (MEL) (Excilite®; Deka Mela, Florence, Italy), able to generate 308-nm ultraviolet (UV) B radiation, to produce a power density of 50 mW cm⁻² at a distance of 15 cm from source (decreasing to about 40 mW cm⁻² at the periphery of the spot), and to have a maximum irradiating area of 504 cm² (36 × 14 cm).

Following the experience of Asawanonda et al.,⁵ we started a new protocol based on multiples of the minimal erythema dose (MED). Before treatment, all patients were phototested to determine the MED of 308-nm UVB by exposing a small area of uninvolved skin on the buttocks to a geometric dose range between 150 and 500 mJ cm⁻² (3–10 s). Sixty-nine patients (44 men and 25 women) aged between 18 and 77 years, with Fitzpatrick skin type I–IV, affected by both localized (< 30% of total skin) and diffuse psoriasis vulgaris (> 30% of total skin), were enrolled in this pilot study. Patients were required to discontinue any topical treatment for 4 weeks, and any phototherapy-based or systemic treatment for at least 3 months before enrolment. The psoriasis severity was evaluated according to the Psoriasis Area and Severity Index (PASI 12–36). The dose at the first application varied from 2 to 4 MED, depending on the skin area to be treated and the features (thickness, scaling and erythema) of the psoriatic lesion (Table 1). Subsequent doses were increased by 150–500 mJ cm⁻² (3–10 s) during the following sessions (one every 7–14 days), inversely depending on the erythema grading related to the preceding application (the less erythema, the higher increase). The lamp was always located at a distance of 15 cm from the skin area to be treated. Both patients and operators always wore protective goggles. Unaffected skin was always protected with white paper towels or a total-block sunscreen cream. No additional treatments, except an emollient cream under occlusive dressing, were used by the patients during the study period. No mineral oil, usually used in excimer laser treatment, was applied in our protocol. Clinical evaluation was performed once monthly during and after the treatment period up to a maximum follow-up of 13 months.

Complete remission was defined as 76–100% improvement in PASI, partial remission as 51–75% improvement, minimal response as 26–50% improvement and no response as 0–25% improvement. Thirty of the 44 patients with localized psoriasis

Table 1 Initial light dose at different cutaneous areas

2 MED	Lesions of lower limbs in patients with vascular problems
2.5 MED	Lesions at areas such as lower limbs, buttocks, abdomen, breastbone area, extensor side of upper limbs, face and scalp (with shaved hair)
3 MED	Lesions of back and of dorsal side of arms and hands
4 MED	Lesions of elbows and knees
MED, minimal erythema dose.	

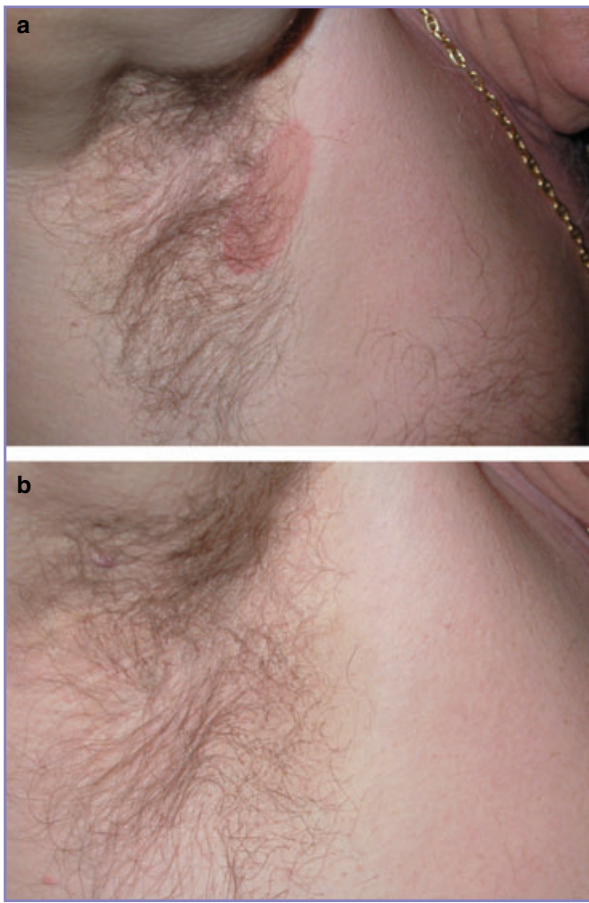


Fig 1. Psoriasis inversa of the axilla (a) before treatment and (b) 4 months after last monochromatic excimer light treatment (two treatments, 0.6 and 0.75 mW cm⁻²).

(Fig. 1) achieved complete remission (68%), 10 experienced partial remission (23%), three showed a minimal response (7%) and only one showed no response (2%); eight of the 25 patients with diffuse psoriasis achieved complete remission (32%), 12 obtained partial remission (48%), three showed a minimal response (12%) and two showed no response (8%). In the localized psoriasis group, the number of sessions varied from one to eight (mean 5.2, median 5.5), and remissions lasted from 2 to 13 months (mean 4.2, median 4.5). In the diffuse psoriasis group, the number of sessions varied from two to 10 (mean 5.8, median 6), and remissions lasted from 1 to 5 months (mean 3.5, median 3.5). The most common side-effects were minimal erythema and itching, with mild and transient hyperpigmentation. These were recorded in all patients, but were well tolerated (no drop-outs). Only three lesions showed blisters after the first or second session. Although the treatment of those lesions was stopped, remission was quickly achieved and lasted up to 1 year.

When compared with traditional phototherapy, MEL can selectively treat single psoriatic lesions, thus sparing clinically unaffected skin, and can achieve clinical remission very

quickly with one treatment every 7–14 days. Its major advantages over the 308-nm excimer laser devices are both its lower cost (about 65 000 vs. more than 80 000 euros) and its ability to give uniform irradiation of a 50-times wider area (504 cm²) in a single exposure. Data in the literature indicate that MEL may be an effective alternative to traditional phototherapy.^{6,7} Our preliminary results suggest that MEL phototherapy may prove to be very useful,^{8–10} especially for localized psoriasis. The best protocol in terms of ratio between risks (burns) and benefits (rapidity and stability of remission) remains to be identified.

Acknowledgments

This study was supported by the Ente Cassa di Risparmio di Firenze. We are grateful to Mrs Mary Forrest for revising the manuscript.

Department of Dermatological Sciences and
*Physical Therapy Unit, University of Florence,
Via della Pergola 58, 50121 Florence, Italy
E-mail: mavluc@hotmail.com

L. MAVILIA*
P. CAMPOLMI*
R. ROSSI*
M. MORI*
N. PIMPINELLI
P. CAPPUGI*

References

- 1 Bonis B, Kemeny L, Dobozy Z et al. 308-nm UVB excimer laser for psoriasis. *Lancet* 1997; **350**:1522.
- 2 Trehan M, Taylor CR. High-dose 308-nm excimer laser for the treatment of psoriasis. *J Am Acad Dermatol* 2002; **46**:732–7.
- 3 Feldman SR, Mellen BG, Housman TS et al. Efficacy of the 308-nm excimer laser for treatment of psoriasis: results of a multicenter study. *J Am Acad Dermatol* 2002; **46**:900–6.
- 4 Campolmi P, Bonan P, Mavilia L, Cappugi P. Luce monocromatica ad eccimeri. In: *Laser e Sorgenti Luminose in Dermatologia* (Campolmi P, Bonan P, Cannarozzo G, eds). Milan: Masson, 2003; 155–8.
- 5 Asawanonda P, Anderson RR, Chang Y, Taylor CR. 308 excimer laser for the treatment of psoriasis. A dose–response study. *Arch Dermatol* 2000; **136**:619–24.
- 6 Leone G, Iacovelli P, Paro Vidolin A, Picardo M. Monochromatic excimer light 308 nm in the treatment of vitiligo: a pilot study. *J Eur Acad Dermatol Venereol* 2003; **17**:531–7.
- 7 Mori M, Campolmi P, Mavilia L et al. Monochromatic excimer light (308 nm) in patch-stage IA mycosis fungoides. *J Am Acad Dermatol* 2004; **50**:943–5.
- 8 Campolmi P, Mavilia L, Lotti TM et al. 308 nm monochromatic excimer light for the treatment of palmoplantar psoriasis. *Int J Immunopathol Pharmacol* 2002; **13** (Suppl. 1):11–13.
- 9 Cappugi P, Mavilia L, Mavilia C et al. 308 nm monochromatic excimer light in psoriasis: clinical evaluation and study of cytokine levels in the skin. *Int J Immunopathol Pharmacol* 2002; **13** (Suppl. 1):14–19.
- 10 Bianchi B, Campolmi P, Mavilia L et al. Monochromatic excimer light (308 nm): an immunohistochemical study of cutaneous T cells and apoptosis-related molecules in psoriasis. *J Eur Acad Dermatol Venereol* 2003; **17**:408–13.

Conflicts of interest: none declared.