

Gestational diabetes insipidus: a morphological study of the placenta

F. CASTIGLIONE, A.M. BUCCOLIERO, F. GARBINI, C.F. GHERI, D. MONCINI, G. POGGI, V. SALADINO, D. ROSSI DEGL'INNOCENTI, R.G. GHERI*, G.L. TADDEI

Department of Human Pathology and Oncology, University of Florence, School of Medicine, Florence; * Unit of Endocrinology San Giuseppe Hospital Empoli, Italy

Key words

Gestational diabetes insipidus • Morphological study of placenta

Summary

Gestational diabetes insipidus (GDI) refers to the state of excessive water intake and hypotonic polyuria. Those cases manifesting in pregnancy and referred to as GDI may persist thereafter or may be a transient latent form that resolves after delivery. Microscopic examination of affected subjects

has not been previously reported. In the literature, there are various case reports and case series on diabetes insipidus in pregnancy. In this study, we present a case that had transient diabetes insipidus during pregnancy in which the placenta was examined.

Introduction

Gestational diabetes insipidus (GDI) is a rare endocrinopathy complicating pregnancy with an incidence of approximately four in every 100,000 pregnancies^{1,2}. Polyuria, polydypsia, excessive thirst and dehydration are the main features of the disease. The aetiology is thought to depend on excessive vasopressinase activity, a placental enzyme that degrades arginine vasopressin (AVP), but not 1-deamino-8-d-arginine vasopressin (dDAVP), which is a synthetic form with a different N-terminal³. GDI can be categorized into two groups depending on the response to arginine vasopressin (AVP) and dDAVP: vasopressin-resistant and dDAVP resistant (nephrogenic), and vasopressin and dDAVP-sensitive (central)^{1,3}.

Although there is an increase in AVP levels in pregnancy to maintain sufficient antidiuretic activity, decreased renal effect due to its increased catabolism by placental vasopressinase may result in and is the main cause of GDI⁴. Another factor contributing to the pathophysiology is transient liver dysfunction in which vasopressinase degradation in liver is decreased, explaining its association with acute fatty liver during pregnancy and HELLP syndrome⁵. Microscopic examination of the

placenta in affected subjects has not been previously reported. In the literature, there are various case reports and case series regarding diabetes insipidus in pregnancy. Herein, we present a case of transient diabetes insipidus in pregnancy in whom placental examination was performed.

Case report

A 36-year-old Caucasian patient was referred in the 33rd week of gestation with symptoms of polyuria, polydypsia, inability to tolerate oral intake, weight loss and fatigue that began in the third trimester and worsened with time. The prenatal course was uncomplicated until 30 weeks; after that time, urination and oral intake progressively increased to the degree that upon presentation, she could not tolerate a sufficient quantity of water to quench her thirst. Her past medical story was unremarkable. The woman had 2 previous pregnancies: the first physiological, and the second was a twin pregnancy with foetal intrauterine death in the 20th week. The family history was unremarkable for endocrinopathies and liver disease. No therapy was given during pregnancy, and her symptoms resolved in the third week

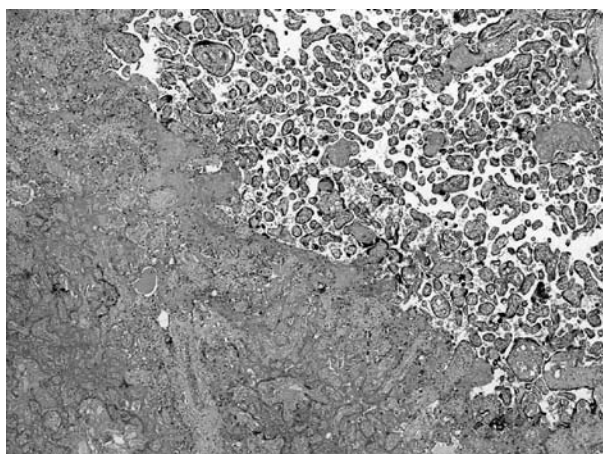
Correspondence

Francesca Castiglione, Department of Human Pathology and Oncology, University of Florence, School of Medicine, viale GB Morgagni 85, 50134 Florence, Italy - Tel. +39 055 4478121 - Fax +39 055 4379868

of puerperium. Ultrasonography at 35th weeks of gestation showed a normal amniotic fluid index and foetal biometry. Physical and gynaecological examinations were unremarkable. Blood pressure was 105/75 mmHg and the pulse rate 90/min. The general condition of the patient was moderate, skin turgor was reduced and her mouth was completely dry. The patient was admitted to the hospital for further assessment. The therapy with dDAVP was begun. The planned caesarean section at 37 weeks of gestation was performed under combined spinal-epidural anaesthesia with oral dDAVP. A female foetus of 2,600 g was delivered after one minute the Apgar score of the fetus was 9. The postoperative course was uneventful. dDAVP treatment was continued until symptoms subsided.

After delivery, the placenta was evaluated macroscopically by the pathologist and then fixed in 10% buffered formalin and embedded in paraffin. The placenta was 500 g with a placental weight index of 5.2 (foetal weight/placental weight), which is slightly less than normal (6.2). Macroscopic evaluation showed a placenta disc of cm 21 x 19 x 2.6. The umbilical cord inserted eccentrically into the placenta disc. The maternal surface of the placenta was dark red, shiny and coarsely folded into regular lobulations. The foetal surface of the chorionic plate was covered by glistening, transparent amnion. Membranes normally arise from the margin of the disc. Chorionic arteries and veins branched from the umbilical cord. There were three umbilical vessels. The funicle was 27 cm in length and 1.2 cm in diameter. Ten sections of placental tissue, 2 umbilical cord and 2 of the amniotic membrane were processed for microscopic examination after haematoxylin-eosin staining. Microscopic evaluation revealed both old and recent infarcts in 15% of the placenta (Fig. 1). Fibrinoid necrosis was detected in 10% of placenta (Figs. 2, 3). Scattered areas of placental "Tenney-Parker" changes were present in 3 of the 10 sections (over 20%) (Fig. 4). Chorioamnionitis and umbilical cord alterations were absent.

Fig. 1. Placental infarct.



Figs. 2-3. Areas of increased perivillous fibrin.

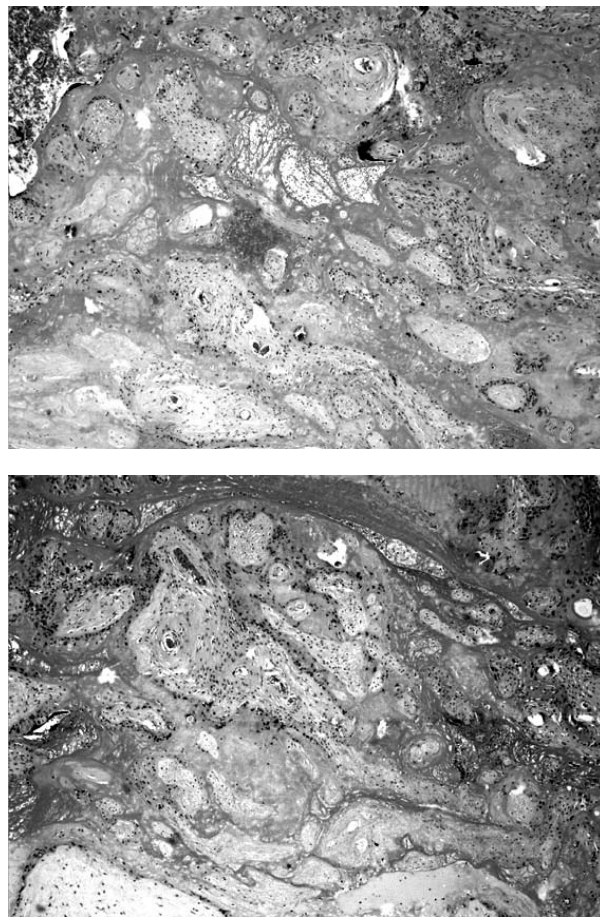
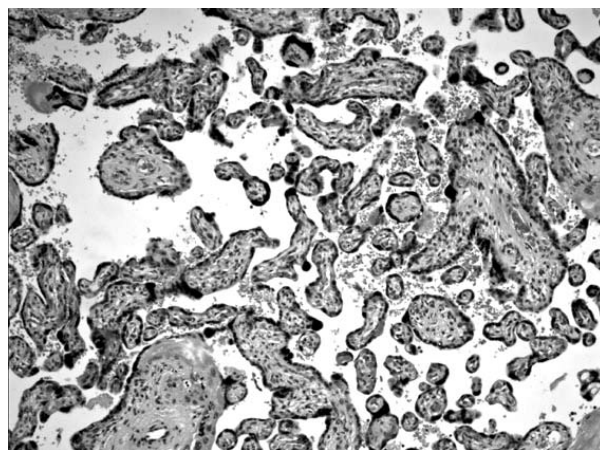


Fig. 4. "Tenney-Paeker changes" are evident.



Discussion

Gestational diabetes insipidus refers to the state of excessive water intake and hypotonic polyuria. Those manifesting in pregnancy and referred to as GDI may persist thereafter or may be a transient latent form that

resolves after delivery. It may be associated with pre-eclampsia, acute fatty liver during pregnancy or HELLP syndrome^{3,6}. There are no descriptions in literature of placental morphology in GDI, perhaps because of the rarity of the disease or to the delay in sample delivery to the pathologist. It is complex to understand the peculiar aspects of this pathology. The placenta examined was a placenta at 37 weeks, presenting focal areas suggesting advanced villous maturation, infarcts and fibrin deposits. These were frequent after 30 week or so, perhaps non-specific in a GDI placenta. The placental infarct was a localized region of villi ischemic necrosis, which

is surrounded by coagulated blood. Small infarcts (less than 3 cm) are found in about one-fourth of placentas from uncomplicated pregnancies. Placenta infarcts occur when maternal blood flow through the spiral arteries is insufficient. A small infarct of less than 3 cm in diameter near the placental margin is a common occurrence, and as an isolated finding has no clinical significance. This alteration is often present in placenta after 35 weeks of pregnancy, and is thus not specific of this pathology⁷. We consider placenta exam useful in GDI to determine if these findings are occasional or consistent with similar cases.

References

- ¹ Durr JA. *Diabetes insipidus in pregnancy*. Am J Kidney Dis 1987;9:276-83.
- ² El-Hennawy AS, Bassi T, Koradia N, Bocirnea. *A Transient gestational diabetes insipidus: report of two cases and review of pathophysiology and treatment*. J Matern Fetal Neonatal Med 2003;14:349-52.
- ³ Jin-No Y, Kamiya Y, Okada M, Watanabe O, Ogasawara M, Fujinami T. *Pregnant woman with transient diabetes insipidus resistant to 1-desamino-8-D-arginine vasopressin*. Endocr J 1998;45:693-6.
- ⁴ Lindheimer MD, Barron WM, Davison JM. *Idiopathic acute fatty liver of pregnancy associated with transient diabetes insipidus. Case report*. Br J Obstet Gynaecol 1987;94:823-4.
- ⁵ Yamanaka Y, Takeuchi K, Konda E, Samoto T, Satou A, Mizudori M, et al. *Transient postpartum diabetes insipidus in twin pregnancy associated with HELLP syndrome*. J Perinat Med 2002;30:273-5.
- ⁶ Harper M, Hatjis CG, Appel RG, Austin WE. *Vasopressin-resistant diabetes insipidus, liver dysfunction, hyperuricemia and decreased renal function. A case report*. J Reprod Med 1987;32:862-5.
- ⁷ Salafia CM, Pezzullo JC, López-Zeno JA, Simmens S, Minior VK, Vintzileos AM. *Placental pathologic features of preterm preeclampsia*. Am J Obstet Gynecol 1995;173:1097-105.